

Follicular Dendritic Cell Sarcoma of the Tonsil

Young Gyu Eun,¹ Sung Wan Kim,² and Kee Hwan Kwon²

¹Department of Otolaryngology-Head and Neck Surgery, Masan Samsung Hospital, Sungkyunkwan University School of Medicine, Masan;

²Department of Otolaryngology-Head and Neck Surgery, School of Medicine, Kyung Hee University, Seoul, Korea.

Received: November 18, 2008

Revised: January 30, 2009

Accepted: January 30, 2009

Corresponding author: Dr. Kee Hwan Kwon,
Department of Otolaryngology-Head and
Neck Surgery, School of Medicine,
Kyung Hee University, 1 Hoegi-dong,
Dongdaemun-gu, Seoul 130-702, Korea.
Tel: 82-2-958-8474, Fax: 82-2-958-8470
E-mail: entkhkwon@empal.com

· The authors have no financial conflicts of
interest.

Follicular dendritic cell sarcoma (FDCS) is unusual, and those with an extranodal origin in the head and neck region are extremely rare. To date, no cases of tumors featuring the characteristics of follicular dendritic cells were reported in Korea. We report a new case of FDCS of the tonsils in a 65-year-old man. A diagnostic tonsillectomy was performed. Based on histopathologic and immunohistochemical findings, the patient was diagnosed with FDCS. Adjuvant radiotherapy was performed due to a high mitotic count. The patient survived with a 2-year disease free period. The differential diagnosis of a tonsillar mass must include FDCS. In cases in which FDCS is suspected on histopathologic examination, an immunohistochemical study is essential for the diagnosis.

Key Words: Follicular dendritic cell, sarcoma, tonsil, immunohistochemistry

INTRODUCTION

Follicular dendritic cells belong to the accessory immune system, and they are normally present in the germinal center of primary and secondary follicles. Their major functions include serving as antigen-presenting cells and playing a major role in the induction and maintenance of the humoral immune response. Tumors featuring the characteristics of follicular dendritic cells were first described in four cases reported by Monda, et al.¹ in 1986. Since then, approximately 70 cases have been reported, most of which are known to be of lymph node origin. However, 24 cases with an extranodal origin were identified in the head and neck region.²⁻⁹ To date, however, no Korean cases of tumors featuring the characteristics of follicular dendritic cells have been reported. We report a case of this rare entity which developed in the tonsil, in which the diagnosis and treatment were difficult. Here, we present our case with a review of the literature.

CASE REPORT

A 65-year-old male patient visited us with a 1-week-history of discomfort when swallowing food. A physical examination showed a 1 × 1 cm round mass on the surface of the right tonsil (Fig. 1). This mass had an irregular surface but had no necrotic or ulcerative areas. A neck examination revealed no enlarged lymph nodes. Diagnostic tonsillectomy was performed. There was no gross evidence of a residual tumor in the right tonsillar fossa after surgery. The resected right tonsillar tissue was 3 × 2 × 1.7 cm in size (Fig. 2).

© Copyright:

Yonsei University College of Medicine 2010

This is an Open Access article distributed under the terms of the Creative Commons Attribution Non-Commercial License (<http://creativecommons.org/licenses/by-nc/3.0>) which permits unrestricted non-commercial use, distribution, and reproduction in any medium, provided the original work is properly cited.

Histopathological examination of the excised tonsil showed infiltrating tumor tissue and small intermingled residual lymphocytes. The tumor tissue consisted of spindle to ovoid cell proliferation forming fascicles, storiform patterns, and whorls, including 360 degree whorls. Individual neoplastic cells showed elongated vesicular nuclei with distinct nucleoli, plump, slightly eosinophilic cytoplasm, and indistinct cell borders (Fig. 2). Microcystic changes containing hemorrhage and occasional multinucleated cells were also seen. Mitotic figures were counted to 16/10 HPF. Immunohistochemical findings of the neoplastic cells are positive for CD21 and negative for CK, LCA, CD20, CD3, ALK-1, CD56, CD68, CD30, and S100 (Fig. 2). Based on histopathologic and immunohistochemical findings, the patient was diagnosed with follicular dendritic cell sarcoma (FDCS). Neck computed tomography (CT) and magnetic resonance image (MRI) after the tonsillectomy showed no remaining tumor and no abnormal findings on the surrounding structures. Subsequent staging with positron emission tomography/computed tomography of the neck, thorax, and abdomen revealed no

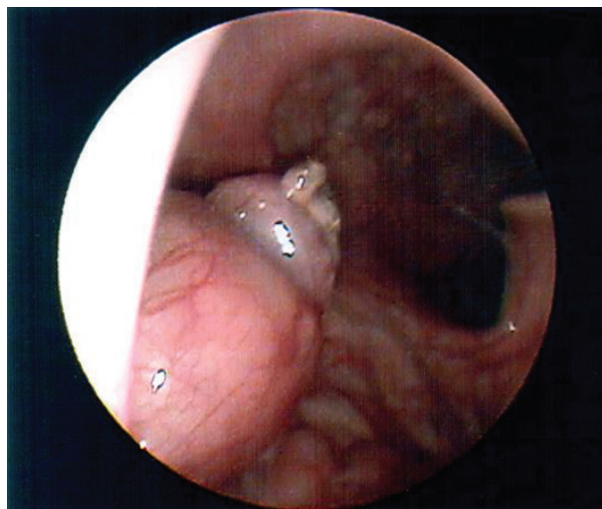


Fig. 1. Preoperative endoscopic finding shows irregular round mass in right tonsil (superior view).

regional or distant metastasis. Since this intermediate-grade malignancy is associated with a high risk of local recurrence, we prescribed radiotherapy at the primary site as adjunctive therapy. Postoperative radiotherapy of 5,400 cGy with 180 cGy fractions delivered over 6 weeks was applied to the right tonsillar region. The patient survived with a 2-year disease free period.

DISCUSSION

FDCS is a rare neoplasm arising not only from lymph nodes but also extranodally, either as acquired lymphoid tissue or as part of the organized constitutive lymphoid tissue. In most cases, the tumor occurs in the lymph nodes of the neck, mediastinum, and axilla. In approximately 30% of cases, the tumor develops in such extranodal sites as the liver, tonsil, and intra-abdominal soft tissue.¹⁰ A similar prevalence was seen between male and female patients, and the median age of the patients was 47 years with a wide age range of 14-77 years.^{11,12} FDCS is typically described as a painless, slow-growing, well-circumscribed mass. A histopathological diagnosis of FDCS can be made homogeneously. Microscopically, FDCS is composed of oval to spindle cells with eosinophilic cytoplasm arranged in sheets, fascicles, and whorls, sometimes admixed with foci showing a storiform pattern of growth, suggesting a diagnosis of sarcoma. Tumor cells are typically characterized by mixtures of small lymphocytes, which can lead to a misdiagnosis of lymphoma. Immunophenotypes of FDCS are positive for CD21, CD35, Ki-M4p, and Ki-FDC1p, and are variably positive to vimentin, S-100 protein, CD68 and specific muscle actin (2, 10, 15, 16). Of these, CD21 and CD35 are the most useful antibodies because of their sensitivity and specificity. These antibodies can be used individually, and their sensitivity increases when they are used as a “cocktail”.⁸ In the current case, microscopic findings were consistent with those above and

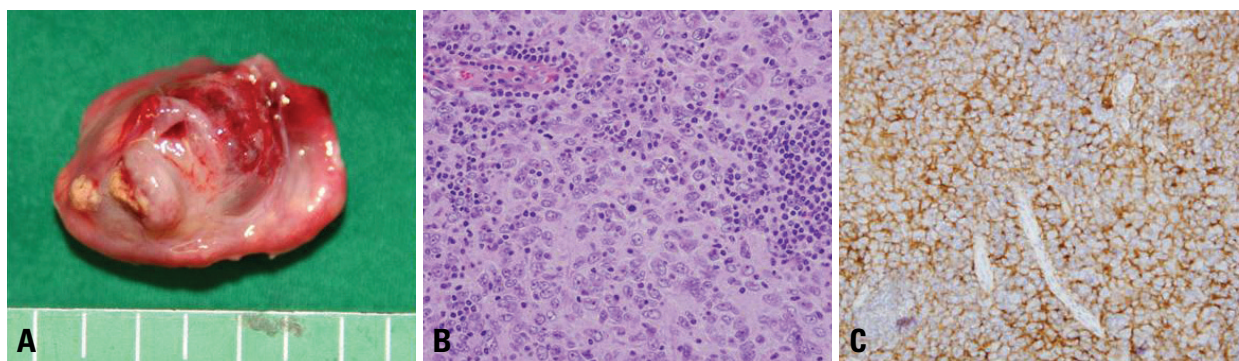


Fig. 2. (A) Surgical specimen shows irregular round mass measuring $3 \times 2 \times 1.7$ cm in size on right tonsil. (B) The tumor tissue consisted of spindle to ovoid cell proliferation forming fascicles, storiform patterns, and whorls. Individual neoplastic cells show elongated vesicular nuclei with distinct nucleoli, plump, slightly eosinophilic cytoplasm, and indistinct cell borders (HE stain $\times 400$). (C) Immunohistochemical findings of the neoplastic cells are positive for CD21 ($\times 400$).

were positive for CD21. This led to the diagnosis.

Differential diagnoses include extracranial meningioma, peripheral nerve sheath tumor, malignant melanoma, ectopic thymoma, metastatic carcinoma, malignant fibrous histiocytoma, large cell lymphoma, and interstitial reticulum cell sarcoma.^{8,9} The diagnosis of FDSC can be made based on microscopic and immunohistochemical findings. In the immunohistochemical study of poorly differentiated tumors, however, markers for FDSC are not generally used. Therefore, in cases in which FDSC occurred in extranodal sites, the diagnosis of these rare tumors cannot be made easily.^{4,6,7}

For the management of tonsillar FDSC, a wide excision of the tumor was performed. In cases in which metastasis to regional lymph nodes is suspected on imaging studies, a neck dissection is recommended.³ In the current case, a neck dissection was not performed because no findings suggestive of metastasis to the neck lymph nodes were observed on imaging studies following the diagnostic tonsillectomy.

Adjuvant radiotherapy or chemotherapy can be applied to cases with adverse pathologic features and in cases of advanced or incompletely resected lesions. FDSC is considered a low- or intermediate-grade malignancy.^{2,3,7-9} Previous reports characterized the criteria for a poor prognosis as follows: tumor size of > 6 cm, nuclear pleomorphism, high mitotic count (≥ 5 per 10 high-power field), intraabdominal location, lack of adjuvant therapy, coagulation necrosis, and significant cellular atypias.^{2,5} In the current case, the adjuvant radiotherapy was performed due to a high mitotic count.

FDSC is a rare tumor which has been frequently described in recent studies and can be misdiagnosed at a high rate in cases which occur in extranodal sites. Accordingly, a histopathologic examination is mandatory in cases in which the mass developed in the tonsils. A differential diagnosis of a tonsillar mass should include FDSC. In cases in which FDSC is suspected on histopathologic examination, an immunohistochemical study is essential for the differential diagnosis.

REFERENCES

1. Monda L, Warnke R, Rosai J. A primary lymph node malignancy with features suggestive of dendritic reticulum cell differentiation. A report of 4 cases. *Am J Pathol* 1986;122:562-72.
2. Chan JK, Fletcher CD, Nayler SJ, Cooper K. Follicular dendritic cell sarcoma. Clinicopathologic analysis of 17 cases suggesting a malignant potential higher than currently recognized. *Cancer* 1997; 79:294-313.
3. Tisch M, Hengstermann F, Kraft K, von Hinüber G, Maier H. Follicular dendritic cell sarcoma of the tonsil: report of a rare case. *Ear Nose Throat J* 2003;82:507-9.
4. Idrees MT, Brandwein-Gensler M, Strauchen JA, Gil J, Wang BY. Extranodal follicular dendritic cell tumor of the tonsil: report of a diagnostic pitfall and literature review. *Arch Otolaryngol Head Neck Surg* 2004;130:1109-13.
5. Perez-Ordóñez B, Erlandson RA, Rosai J. Follicular dendritic cell tumor: report of 13 additional cases of a distinctive entity. *Am J Surg Pathol* 1996;20:944-55.
6. Chan JK, Tsang WY, Ng CS, Tang SK, Yu HC, Lee AW. Follicular dendritic cell tumors of the oral cavity. *Am J Surg Pathol* 1994;18:148-57.
7. Satoh K, Hibi G, Yamamoto Y, Urano M, Kuroda M, Nakamura S. Follicular dendritic cell tumor in the oro-pharyngeal region: report of a case and a review of the literature. *Oral Oncol* 2003; 39:415-9.
8. Domínguez-Malagón H, Cano-Valdez AM, Mosqueda-Taylor A, Hes O. Follicular dendritic cell sarcoma of the pharyngeal region: histologic, cytologic, immunohistochemical, and ultrastructural study of three cases. *Ann Diagn Pathol* 2004;8:325-32.
9. Aydin E, Ozluoglu LN, Demirhan B, Arıkan U. Follicular dendritic cell sarcoma of the tonsil: case report. *Eur Arch Otorhinolaryngol* 2006;263:1155-7.
10. Khalid T, Folman R. Symptoms in cancer patients and an unusual tumor: Case 3. Follicular dendritic cell sarcoma. *J Clin Oncol* 2005;23:9425-6.
11. Gaertner EM, Tsokos M, Derringer GA, Neuhauser TS, Arciero C, Andriko JA. Interdigitating dendritic cell sarcoma. A report of four cases and review of the literature. *Am J Clin Pathol* 2001; 115:589-97.
12. Araújo VC, Martins MT, Salmen FS, Araújo NS. Extranodal follicular dendritic cell sarcoma of the palate. *Oral Surg Oral Med Oral Pathol Oral Radiol Endod* 1999;87:209-14.