

Arylsulfatase B-deficient Mucopolysaccharidosis in Rats

Midori Yoshida,* Junko Noguchi,* Hiroshi Ikadai,* Masakazu Takahashi,† and Sumi Nagase‡

*Imamichi Institute for Animal Reproduction, Ibaraki 300-01, Japan; and †Sasaki Institute, Tokyo 101, Japan

Abstract

A rat colony with mucopolysaccharidosis VI was established and the clinical, pathological, and biochemical features were characterized. Affected rats had facial dysmorphism, dysostosis multiplex, and increased urinary excretion of glucosaminoglycans (GAGs). Ultrastructural studies revealed storage of GAGs throughout the reticuloendothelial cells, cartilage, and other connective tissues, but no deposition was observed in the nervous system. Biochemical analyses demonstrated that the excreted GAG was dermatan sulfate and the activity of hepatic arylsulfatase B was < 5% of the normal mean value. Pedigree analysis showed that the phenotype was inherited as an autosomal recessive single trait. The availability of a rat model of human mucopolysaccharidosis VI should permit the development and evaluation of various strategies to treat the human disease. (*J. Clin. Invest.* 1992. 91:1099–1104.) Key words: glucosaminoglycan • lysosome storage disease • mutant

Introduction

The genetic mucopolysaccharidoses (MPS)¹ are a group of 10 lysosomal storage diseases resulting from defects of specific lysosomal enzymes affecting glucosaminoglycan (GAG) degradation (1–4). MPS VI is characterized by growth retardation, facial abnormalities including frontal bossing, depressed nasal bridge, corneal opacity, hepatosplenomegaly, normal intelligence, and dysostosis multiplex (1–4). The enzyme defect, deficient arylsulfatase B (ASB) activity, results in the accumulation of dermatan sulfate in tissues and fluids of affected individuals (1–4). Recently, the gene encoding human ASB has been isolated and characterized and the first mutations causing MPS VI in unrelated patients have been reported (5, 6). Previously, an animal model of MPS VI was reported in the Siamese cat (7–9). The feline model has been intensively investigated (7–9) and used as a model to develop and evaluate strategies for the treatment of the human counterpart. In this report, the clinical, morphologic, and biochemical features of a newly recognized murine model of MPS VI are described. The availability of a small animal model of this disease should facilitate further evaluation of various therapeutic endeavors.

Address reprint requests to Dr. Midori Yoshida, Imamichi Institute for Animal Reproduction, 1103 Fukaya, Dejima-mura, Niihari-gun, Ibaraki 300-01, Japan.

Received for publication 26 June 1992 and in revised form 21 September 1992.

1. Abbreviations used in this paper: ASA and ASB, arylsulfatases A and B; GAG, glycosaminoglycan; WKS, Wistar King S (rat).

J. Clin. Invest.

© The American Society for Clinical Investigation, Inc.

0021-9738/93/03/1099/06 \$2.00

Volume 91, March 1993, 1099–1104

Methods

Animals. This mutant was detected in 1988 by its facial and skeletal dysmorphism in the Ishibashi hairless (ISH) rat strain (10) and a colony has been established in the Imamichi Institute for Animal Reproduction. The siblings were successively inbred for 10 generations. Affected animals were easily identified by their facial and skeletal dysmorphism.

Materials. Chondroitin sulfate A (chondroitin 4-sulfate) from whale cartilage, chondroitin sulfate C (chondroitin 6-sulfate) from shark cartilage, dermatan sulfates from pig skin, and heparan sulfate from bovine kidney were obtained from Seikagaku Kogyo Co., Tokyo, Japan. Hyaluronidase from bovine testes and mixed chondroitin sulfate sodium salt were purchased from Wako Pure Chemical Industries Ltd., Osaka, Japan. All chemicals for analysis were analytical grade. Celathore cellulose acetate strips were from Cosmo Ltd., Tokyo, Japan. CelloGel was from Chemetron Ltd., Milan, Italy. A TitanGEL isoenzyme incubation chamber was from Helena Laboratories, Beaumont, TX.

Pathological examination. 14 affected animals (12 males, 2 females) and 10 phenotypically normal littermates (8 males, 2 females) from 15 to 24 wk old were studied. For light microscopy, all organs and tissues were fixed in 10% neutral buffered formalin, embedded in paraffin wax, sectioned, and stained with hematoxylin and eosin. Mowry's colloidal iron and alcian blue-peroxidic acid-Schiff stains were used to identify GAG histochemically. To determine the type of stored GAG(s), the tissues sections were digested with hyaluronidase from bovine testis and then stained with colloidal iron. The bone was fixed, immersed in 7% formic acid for 3 d, rinsed in 95% ethanol and tap water, and then processed routinely. For electron microscopy, 1-mm³ sections of each tissue were fixed in 3% glutaraldehyde in 0.1 M phosphate buffer, pH 7.4, postfixed in 1% osmic tetroxide, dehydrated by ethanol, and embedded in Epon. Ultrathin sections were stained with uranyl acetate-lead citrate and examined with a model H 600 electron microscope (Hitachi, Ltd., Tokyo).

Hematological examination. Peripheral blood, smears taken from four affected and four unaffected animals, were stained with Giemsa stain.

Urinary GAG analysis. A spot test for GAGs was performed on the fresh urine from all affected and normal animals, and the comparison was made with standard solution containing 25, 50, or 100 µg/ml mixed chondroitin sulfate sodium salt. Urinary GAGs were measured as uronic acid by the modified method of carbazole reaction (11) and the orcinol method (12) for six affected and three normal rats. Electrophoresis of urinary GAGs precipitated with cetylpyridinium chloride was carried out by the method of Seno and colleagues (13) on Celathore cellulose acetate strips in 0.3 M calcium acetate solution at 1 mA/cm for 3 h. Purified GAGs including chondroitin 4-sulfate, chondroitin 6-sulfate, dermatan sulfate, and heparan sulfate were used as standards. After electrophoresis, the strips were stained with 0.1% toluidine blue in water and washed with 1% acetic acid.

Enzyme assays. The liver from three affected and three control rats used was thawed, cut into small pieces, and washed with cold saline to remove the blood. The hepatic tissues were homogenized in 5 vol of 10 mM sodium phosphate buffer, pH 6.0, containing 0.2% Triton X-100. The homogenates were centrifuged at 17,000 g for 30 min at 4°C, and the supernatants were used for enzyme assays. Arylsulfatase A (ASA) and ASB activities were determined using 4-nitrocatechol sulfate (14) as substrate; α- and β-galactosidase (15), α- and β-mannosidase (16), β-hexosaminidase (17), and β-glucuronidase (18) were measured us-

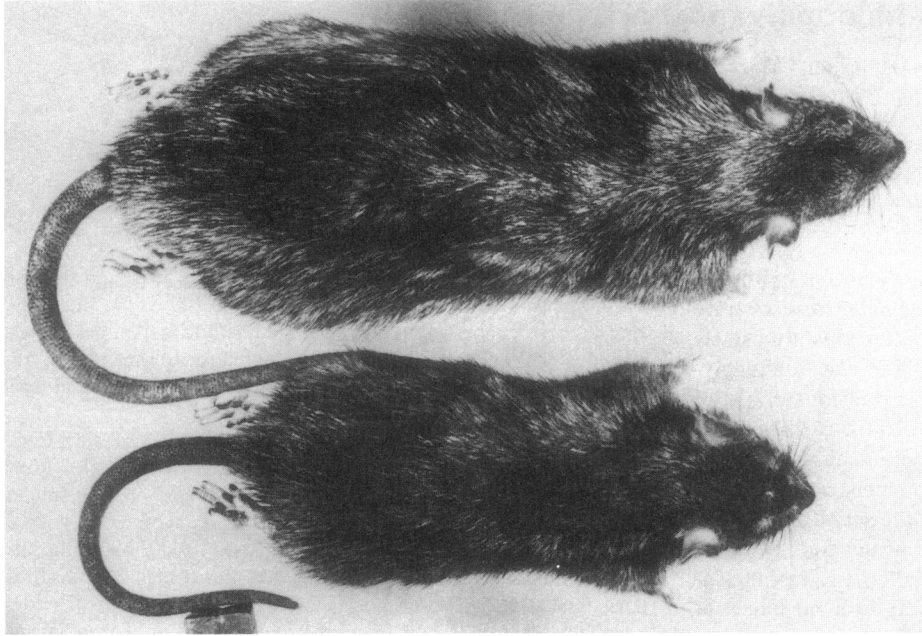


Figure 1. A 13-wk-old ASB-deficient male rat (*bottom*) has shortened nose and tail and is smaller than its normal littermate (*top*).

ing the appropriate 4-methylumbelliferyl- β -D-glycoside as substrate. The electrophoretic separation of ASA and ASB on cellulose acetate was performed essentially according to the method of Osanai and colleagues (19). 15 μ l of each hepatic supernatant was applied as a 4-mm-wide line on cellogel strips (5 \times 6 cm), and electrophoresis was carried out in 0.06M Vernal buffer, pH 8.60, at 1 mA/cm for 45 min. Approximately 2–3 min before completion of electrophoresis, a filter paper, which was preabsorbed 14 mM 4-nitrocatechol-sulfate in 1 M sodium acetate buffer, pH 5.5 or 6.5, was placed into a Titan GEL isoenzyme incubation chamber. At the end of the electrophoresis period the sample strip was removed and blotted lightly. Then the sample strip was layered carefully onto the substrate filter paper and the sandwiched plate was incubated at 37°C for 1 h. After incubation, the cellogel was exposed to the ammonia for visualization of the isoenzyme bands. And then immediately the strip was scanned in a densitometer using a 515-nm filter.

Pedigree analysis. Because the affected animals have poor fertility, the sires and dams producing the affected, designated as carriers, were used for genetic analysis. Carriers in the line were outcrossed with the Wistar King S (WKS) line. The incidence of mutants was observed in the F1, F2, and backcross generations. In the F2 and backcross generations, litters produced by carrier F1 males and females were used for statistical analysis.

Results

Clinical observations. Compared with their normal littermates, affected animals had smaller bodies, shorter limbs, shorter and thicker tails, and a characteristic facial dysmorphia, including broad face, depressed nasal bridge, and a markedly shortened noses (Fig. 1). The affected rats appeared grossly normal at birth; however, after 3 wk of age, the abnormal features became evident. Macroscopically, the corneal opacity was not apparent and no gross neurologic or behavioral features were observed during the life span of the affected animals.

Pathology. Gross examination revealed no obvious organomegaly; however, all vertebrae and long bones were shortened and the ribs were short and broad.

Microscopically, all affected animals showed characteristic changes in the cartilage of the joints and trachea. The articular

cartilage showed an irregular growth plate and proliferation of vacuolated chondrocytes varied in size (Fig. 2). Ultrastructurally, the chondrocytes of the trachea were filled with single membrane-lined vacuoles, which were empty or contained a few fibrils (Fig. 3). The growth plates were widened and irregular. The flattened tracheas observed in some mutants caused by thickened cartilage. The joints of the long bones in the affected animals showed proliferation of vacuolated synovial cells. The osseous tissue did not show marked changes except widened spaces of the osseous cells.

The vacuoles in the cytoplasm were characteristically observed in the macrophage system of all mutant rats. Histochemically, the vacuoles described above showed positive reaction to colloidal iron and alcian blue stains and negative to PAS stain. Furthermore, the vacuoles were not digested by hyaluronidase.

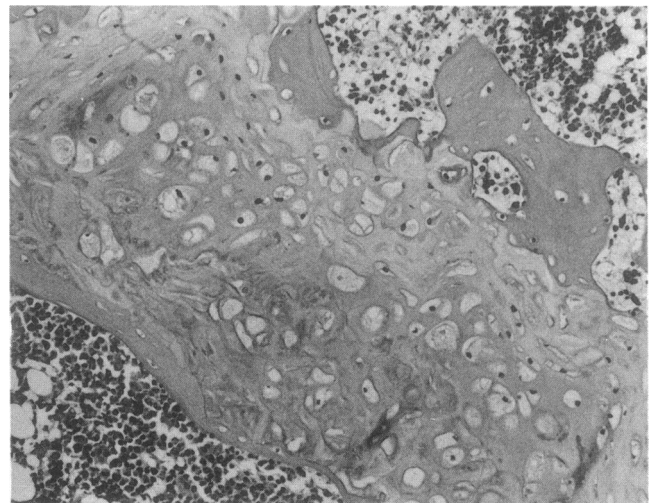


Figure 2. The articular cartilage of a large limb found from a 15-wk-old affected male rat. Extensive vacuolation and proliferation of chondrocytes and irregular growth plate is seen. Hematoxylin-eosin staining. \times 50.

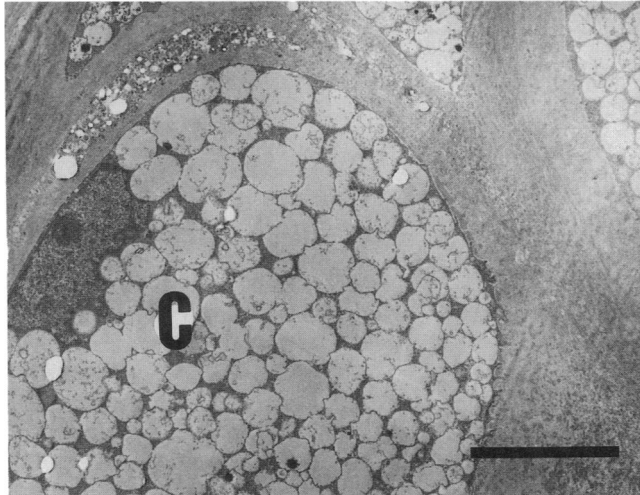


Figure 3. Electron micrographs of the trachea of an affected animal. Cytoplasm of chondrocytes is severely vacuolated. C, chondrocyte. Bar, 5 μ m.

Electronmicroscopically, the Kupffer cells were swollen with membrane-bounded inclusions, which were either empty or contained granular materials (Fig. 4), although the mutant did not show hepatomegaly and/or splenomegaly. The mutant also showed mild vacuolation of the cells in the connective tissue of all organs.

No histological abnormalities were detected in the nervous system including of the brain, spinal cord, and sciatic nerve of the affected animals on paraffin-embedded sections.

Although the corneas of the affected animals did not show any changes in hematoxylin and eosin stain, they were slightly positive when stained with colloidal iron.

In the affected animals, most of the peripheral polymorphonuclear leukocytes contained excessive coarse granules in their cytoplasm (Fig. 5).

Urinary GAG analyses. The GAG spot test on urine from all affected animals was positive, having an intensity comparable to that of a standard solution containing 100 μ g/ml of mixed chondroitin sulfate. In contrast, the urines from all normal animals were negative for GAGs by the spot test.

Total amounts of uronic acid determined by the carbazole and orcinol method in the affected and normal rats were 733 ± 262 and 152 ± 17 μ g/d and 1392 ± 436 and 218 ± 49 μ g/d, respectively.

The electrophoretic patterns revealed that the primary GAG excreted by the affected animals was only dermatan sulfate (Fig. 6).

Enzyme assays. The activities of selected lysosomal hydrolases in the liver from affected animals are shown in Table I. The ASB activity of the affected rats was < 5% of the mean activity in phenotypically normal control rats. There were no significant differences in the activities of other lysosomal hydrolases between the affected and normal animals. Electrophoresis of hepatic ASA and ASB from normal and affected rats revealed very low ASB activity in the affected animals (Fig. 7).

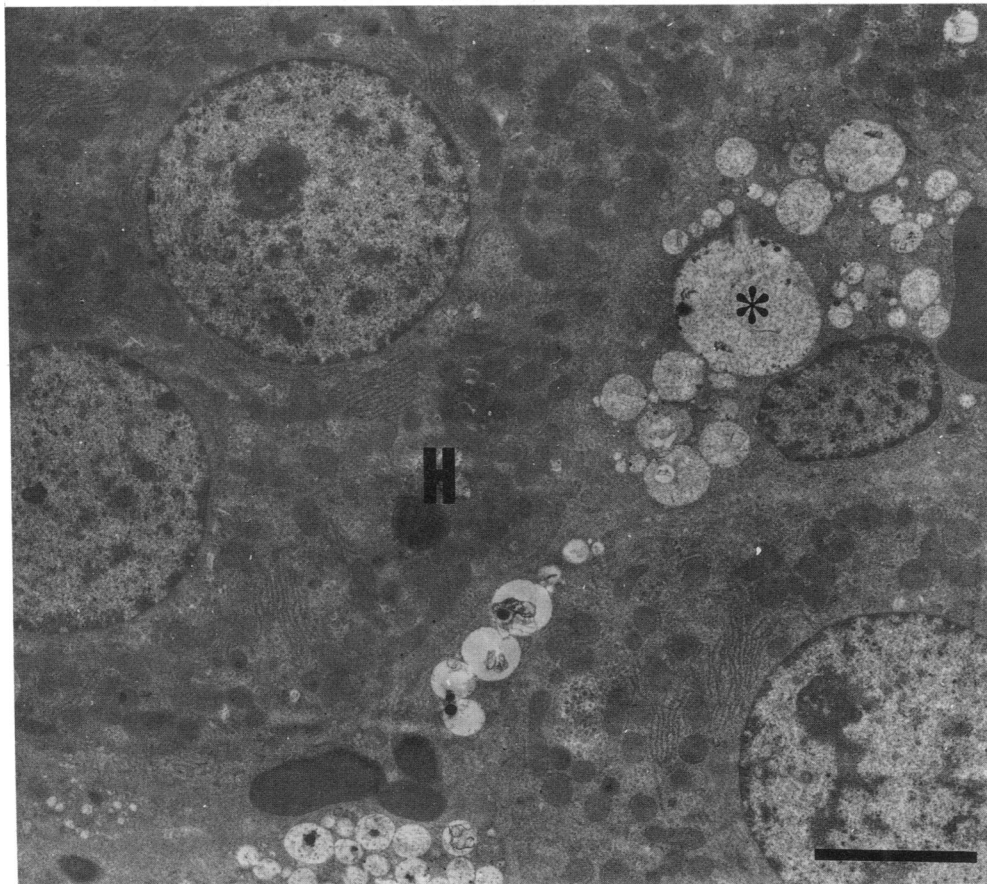


Figure 4. Electron micrographs of the liver of an affected animal. Kupffer cells are distended by cytoplasmic vacuoles. H, hepatocyte. *Membrane-bounded vacuoles in Kupffer cell. Bar, 5 μ m.

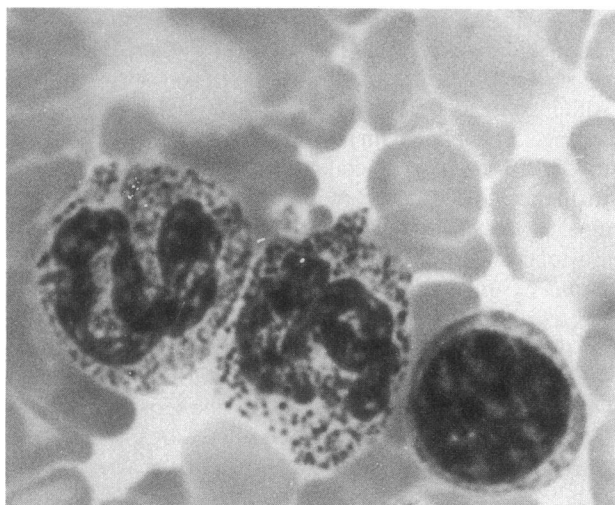


Figure 5. Peripheral leukocytes. Neutrophils with numerous coarse basophilic granular cytoplasmic inclusion bodies. Giemsa stain. $\times 500$.

Pedigree analysis. To determine the mode of inheritance, parents of affected rats were reciprocally outcrossed with an unrelated line. In the F1 generation derived from parental males and outbred females, there were no affected animals (Table II). This finding fits the hypothesis described above, in which F1 animals include dominant homozygotes and hetero-

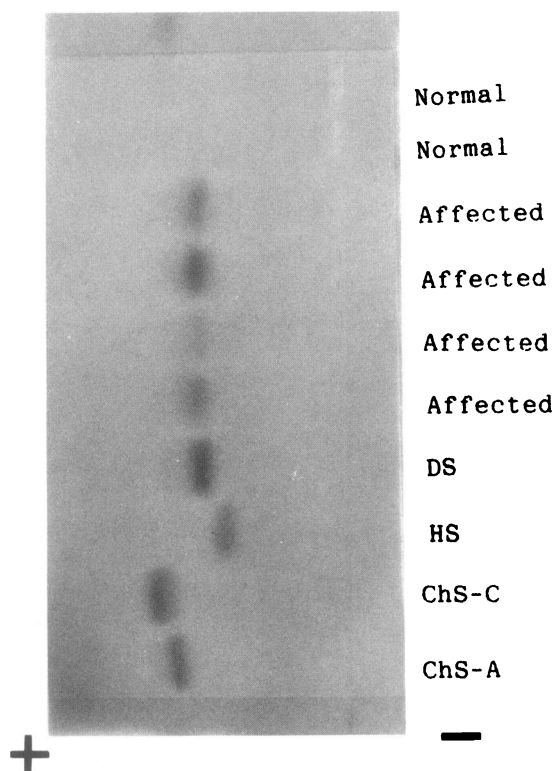


Figure 6. An electrophoretic pattern of urine GAGs on cellulose acetate strip. Electrophoretic mobilities of GAG from affected animal urine correspond to that of dermatan sulfate. The urine of normal rats does not show any spot in electrophoresis. ChSA, chondroitin 4-sulfate; ChSC, chondroitin 6-sulfate; DS, dermatan sulfate; HS, heparan sulfate.

Table I. Lysosomal Enzyme Activities in Liver

No. of rats examined	Affected	Normal
	3	3
<i>nmol/h · mg protein</i>		
ASA	232 \pm 13*	253 \pm 25
ASB	19 \pm 2	375 \pm 37
α -Galactosidase	376 \pm 64	338 \pm 39
β -Galactosidase	1669 \pm 32	1170 \pm 145
β -Glucuronidase	1605 \pm 109	1127 \pm 93
β -Hexosaminidase	1333 \pm 101	544 \pm 32
α -Mannosidase	18.9 \pm 2.4	8.5 \pm 1.1
β -Mannosidase	193 \pm 33	79 \pm 16

* Mean \pm SD.

zygotes. Therefore, the incidences of affected animals in the offspring from matings of proven carrier females with proven carrier males were analyzed. The incidence of affected animals in the offsprings of parents of previous affected and in back-cross generations were consistent with the expected value for autosomal single recessive transmission (Table II).

Discussion

MPS VI (Maroteaux-Lamy syndrome) was first reported by Maroteaux and Lamy in the early 1960s (20, 21). MPS VI resembles MPS I (Hurler syndrome) in physical features, but MPS VI patients have normal intelligence (1-4, 20, 21). MPS VI results from ASB deficiency and is characterized by urinary excretion of excessive amounts of dermatan sulfate and controlled by an autosomal recessive single gene (1, 3, 4).

Until now, however, there is no report of murine or rodent model for human MPS VI, although the feline model has been reported by Haskins and colleagues (7-9, 22-24). A comparison of features in MPS VI between rats and human was shown in Table III. The clinical features of the mutant rats closely resembled those of MPS VI in the human and cat (1, 3, 4, 7-9, 22, 24). Although the corneal clouding, one of features in MPS VI in the human and cat (1, 3, 4, 23), was not grossly apparent in this mutant, slight storage of GAGs in the cornea could be confirmed by the histochemical investigation. Retardation of growth might be caused by the abnormal growth of the cartilage resulting in incomplete endochondral ossification, similar to MPS in humans and cats. Histologically, GAGs stored in the

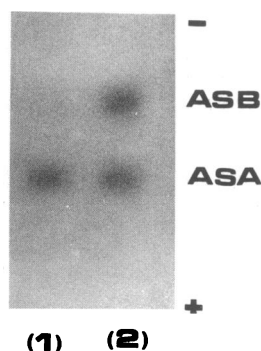


Figure 7. A representation of a cello-gel arylsulfatase isoenzyme strip showing relative position of liver ASA and ASB bands. The liver of the mutant shows deficiency of ASB activity. Lane 1 mutant; Lane 2 phenotypically normal rats.

Table II. Segregation of MPS Rats in Offspring from Crosses with the Unrelated (WKS) Line

Cross	Observed		Expected values from single recessive		χ^2
	Affected	Normal	Affected	Normal	
1. Carrier * males \times WKS females	0	84	0	84	—
2. Carrier F1 males \times carrier F1 females	52	199	62.8	188.2	2.45
3. Carrier males \times carrier F1 females	35	161	49.0	147.0	2.06

* Carrier denotes animals carrying the gene which produces MPS.

Table III. Comparison of Features in MPS VI between Humans and Rats

	Rats	Human
Clinical findings		
Facial dysmorphism	Yes	Yes
Skeletal deformities	Yes	Yes
Corneal clouding	Not apparent at macroscopy	Yes
Intelligence	Normal	Normal
Hepatosplenomegaly	No	Yes
Excretion of urinary GAG	Dermatan sulfate	Dermatan sulfate
Deficiency of lysosomal enzyme	Arylsulfatase B	Arylsulfatase B
GAG stored in tissues	Yes	Yes
Granules of peripheral leukocytes	Yes	Yes
Pedigree analysis	Autosomal single recessive transmission	Autosomal single recessive transmission

cytoplasm of the cells were demonstrated as dermatan sulfate which can not be digested by hyaluronidase (25). GAGs were stored also in the Kupffer cells of the liver, although hepatosplenomegaly was not apparent in the mutant rat. The coarse granules observed the polymorphonuclear leukocytes were similarly reported in MPS VI of cat (8). Thus, the mutant was diagnosed as MPS VI because of very low activity of ASB, excessive excretion of dermatan sulfate in the urine, and storage of GAGs in all organs/tissues. In addition, genetic analysis demonstrated an autosomal single recessive transmission of the defect. We propose to name the line that produces the mutant as MPR indicating mucopolysaccharidosis rat, and the autosomal recessive single gene as *abd* representing ASB deficiency.

Because no abnormalities were detected in the nervous system of this mutant, there might be a possibility that this mutant rat maintains normal or near normal intelligence, as reported in man and cats (1–4, 8). However, further studies such as ultrastructural examination should be necessary to investigate nervous system in detail, since mentation in rodents is difficult to evaluate.

There have been few effective therapies for the patients with lysosomal storage diseases including MPS. Animal models of MPS were already reported in canine and feline MPS I (14, 26–28), feline MPS VI (7–9, 22–24), and canine and mouse MPS VII (18, 29–31), and some experimental attempts for the therapy have been accomplished using the feline models of MPS I and MPS VI (32, 33). However, no successful reports have been achieved. Recently, gene therapy has been attracted attention as a useful therapy of genetic diseases. Schuchman and colleagues (5) reported that the availability of a full-length

cDNA encoding human ASB permitted studies of this gene's structure, organization, and expression, and Jin and colleagues (6) described that the identification of the first molecular lesions in the ASB gene that caused MPS VI facilitated more accurate carrier testing and provided the basis for genotype/phenotype correlations for this disease (5, 6). This murine model is genetically well defined and homogeneous and provides an adequate number of animals to allow experiments. In addition, because of its small size, this mutant rat seems to be good for breeding, with such features as ease of animal care and low cost. Therefore, this mutant rat would be a very useful model to analyze the pathophysiology of MPS and also to investigate experimental therapies.

Acknowledgments

We thank Dr. A. Maekawa, and Dr. Y. Shirasu, for their helpful comments in this manuscript and Mrs. Oyake, Miss A. Suzuki, and Miss K. Fujii for their excellent technical assistance.

References

1. Neufeld, E. F., and J. H. Muenzer. 1989. The mucopolysaccharidosis. In *Metabolic Basis of Inherited Disease*. C. R. Scriver, A. L. Beaudet, W. S. Sly, and D. Valle, editors. McGraw-Hill, Inc., New York. 1565–1587.
2. Glew, R. H., A. Basu, E. M. Prenc, and A. T. Remaley. 1985. Biology of disease: lysosomal storage diseases. *Lab. Invest.* 53:250–269.
3. Takeuchi, J. 1984. Mucopolysaccharidosis. In *Current Encyclopedia of Pathology* 3. S. Iijima, H. Ishikawa, K. Kageyama, and T. Shimamine, editors. Nakayama-shoten, Tokyo. 215–226.
4. Yamamura, Y. 1982. *Metabolism and Disease*, Volume 19, Nakayama-shoten, Tokyo. 883 pp.
5. Schuchman, E. H., C. E. Jackson, and R. J. Desnick. 1990. Human arylsul-

- fatase B:mopac cloning, nucleotide sequence of a full-length cDNA, and regions of amino acid identity with arylsulfatases A and C. *Genomics*. 6:149-158.
6. Jin, W., C. E. Jackson, R. J. Desnick, and E. H. Schuchman. 1992. Mucopolysaccharidosis type VI: identification of three mutations in the arylsulfatase B gene of patients with the severe and mild phenotypes provides molecular evidence for genetic heterogeneity. *Am. J. Hum. Genet.* 50:795-800.
 7. Jezyk, T. F., M. E. Haskins, and D. F. Patterson. 1977. Mucopolysaccharidosis in a cat with arylsulfatase B deficiency: a model of Maroteaux-Lamy syndrome. *Science (Wash. DC)*. 198:834-836.
 8. Haskins, M. E., R. F. Jezyk, and D. F. Patterson. 1979. Mucopolysaccharide storage disease in three families of cats with arylsulfatase B deficiency: leukocyte studies and carrier identification. *Pediatr. Res.* 13:1203-1210.
 9. Haskins, M. E., G. D. Aguirre, P. F. Jezyk, and D. F. Patterson. 1980. The pathology of the feline model of mucopolysaccharidosis VI. *Am. J. Pathol.* 101:657-674.
 10. Takahashi, M., S. Nagase, and M. Ishibashi. 1981. Clinico-biochemical study on Ishibashi rats. *Exp. Anim.* 30:457-463.
 11. Bitter, T. and H. M. Muir. 1962. A modified uronic acid carbazole reaction. *Anal. Biochem.* 4:330-334.
 12. Khym, J. X., and D. G. Doherty. 1952. The analysis and separation of glycuronic and galacturonic acids by ion exchange. *J. Am. Chem. Soc.* 74:3199-3200.
 13. Seno, N., K. Anno, K. Kondo, S. Nagase, and S. Saito. 1970. Improved method for electrophoretic separation and rapid quantitation of isomeric chondroitin sulfates on cellulose acetate strips. *Anal. Biochem.* 37:197-202.
 14. Haskins, M. E., P. F. Jezyk, R. J. Desnick, S. K. McDonough, and D. F. Patterson. 1979. Alpha-L-idurinidase deficiency in a cat: a model of mucopolysaccharidosis I. *Pediatr. Res.* 13:1294-1297.
 15. Desnick, R. J., K. Y. Allen, R. J. Desnick, M. K. Paman, R. W. Bernlohr, and W. Krivit. 1973. Fabry's disease: enzymatic diagnosis of hemizygotes and heterozygotes. α -Galactosidase activities in plasma, serum, urine, and leukocytes. *J. Lab. Clin. Med.* 81:157-171.
 16. Desnick, R. J., H. L. Sharp, G. A. Grabowski, R. J. Brunning, J. H. Sung, P. G. Quie, and J. U. Ikonne. 1976. Mannosidosis; clinical, ultrastructural, immunologic and biochemical studies. *Pediatr. Res.* 10:985-996.
 17. Ikonne, J. U., M. C. Pattazzi, and R. J. Desnick. 1975. Characterization of Hex S: the major residual β -hexosaminidase activity in Sandhoff disease. *Am. J. Hum. Genet.* 27:639-650.
 18. Bikenmeier, E. H., M. T. Davison, W. G. Beamer, R. E. Ganschow, C. A. Vogler, B. Gwynn, K. A. Lyford, L. M. Maltais, and C. J. Wawrzyniak. 1989. Murine mucopolysaccharidosis type VII. *J. Clin. Invest.* 83:1258-1266.
 19. Osanai, T., M. Iwamori, Y. Nagai, and S. Nagase. 1977. Selective measurement for arylsulfatase A and B. *Seikaq.* 49:782.
 20. Maroteaux, P., and M. Lamy. 1963. La maladie de Morquio: Étude clinique, radiologique et biologique. *Press Med.* 71:2091-2094.
 21. Maroteaux, P., and M. Lamy. 1965. Herler's disease, Morquio's disease, and related mucopolysaccharidosis. *J. Pediatr.* 67:312-323.
 22. Haskins, M. E., P. F. Jezyk, R. J. Desnick, and D. F. Patterson. 1981. Animal model of human disease: mucopolysaccharidosis VI Maroteaux-Lamy syndrome. *Am. J. Pathol.* 105:191-193.
 23. Aguirre, G., L. Stramm, and M. Haskins. 1983. Feline mucopolysaccharidosis VI: general ocular and pigment epithelial pathology. *Invest. Ophthalmol. Vis. Sci.* 24:991-1007.
 24. Haskins, M. E., E. J. Otis, J. E. Hayden, P. F. Jezyk, and L. Stramm. 1992. Hepatic storage of glucosaminoglycans in feline and canine models of mucopolysaccharidosis I, VI, and VII. *Vet. Pathol.* 29:112-119.
 25. Luna, L. G. 1968. Methods of digestion with hyaluronidase. In *Manual of Histologic Staining of the Armed Forces Institute of Pathology*. Seishi Shoin Ltd., Tokyo. 213-214.
 26. Cowell, K. R., P. F. Jezyk, M. E. Haskins, and D. F. Patterson. 1976. Mucopolysaccharidosis in a cat. *J. Am. Vet. Med. Assoc.* 169:334-339.
 27. Haskins, M. E., P. F. Jezyk, R. J. Desnick, S. K. McDonough, and D. F. Patterson. 1981. Mucopolysaccharidosis in a domestic short-haired cat—a disease distinct from that seen in the Siamese cat. *J. Am. Vet. Med. Assoc.* 175:384-387.
 28. Shull, R. M., R. J. Munger, E. Spellacy, C. W. Hall, G. Constantopoulos, and E. F. Neufeld. 1982. Animal model of human disease: canine α -L-iduronidase deficiency. *Am. J. Pathol.* 109:244-248.
 29. Haskins, M. E., R. J. Desnick, N. Diferrante, P. F. Jezyk, and D. F. Patterson. 1984. β -Glucuronidase deficiency in a dog: a model of human mucopolysaccharidosis VII. *Pediatr. Res.* 18:980-984.
 30. Vogler, C., E. H. Birkenmeier, W. S. Sly, B. Levy, C. Pegors, J. W. Kyle, and W. G. Beamer. 1990. A murine model of mucopolysaccharidosis VII. Gross and microscopic findings in beta-glucuronidase deficient mice. *Am. J. Pathol.* 136:207-217.
 31. Haskins, M. E., G. D. Aguirre, P. F. Jezyk, E. G. Schuchman, R. J. Desnick, and D. F. Patterson. 1991. Animal model of human disease: mucopolysaccharidosis type VII (Sly syndrome). Beta-glucuronidase-deficient mucopolysaccharidosis in the dog. *Am. J. Pathol.* 138:1553-1555.
 32. Hasper, P. W., M. A. Thrall, D. A. Wenger, D. W. Macy, L. Ham, R. E. Dornsife, K. McBiles, S. L. Quackenbush, M. L. Kesel, E. L. Gillette, et al. 1984. Correction of feline arylsulphatase B deficiency (mucopolysaccharidosis VI) by bone marrow transplantation. *Nature (Lond.)*. 312:467-469.
 33. Shull, R. M., N. E. Hastings, R. R. Selcer, J. B. Jones, J. R. Smith, W. C. Cullen, and G. Constantopoulos. 1987. Bone marrow transplantation in canine mucopolysaccharidosis I. *J. Clin. Invest.* 79:435-443.