

CASE REPORT

# A Patient with Delayed Contact Dermatitis to Coral and She Displayed Superficial Granuloma

Hyo Sang Ahn, M.D., Sun Young Yoon, M.D., Hyun Jeong Park, M.D., Jun Young Lee, M.D., Baik Kee Cho, M.D.

Department of Dermatology, St. Mary's Hospital, College of Medicine, The Catholic University of Korea, Seoul, Korea

Contact with coral may cause a rare type of contact dermatitis, and the resulting skin reaction can be divided into different reactions: the acute, delayed and chronic types of coelenterate dermatitis. Granulomas of delayed skin reactions have rarely been reported. Herein, we report on a rare case of a delayed reaction of the skin to coral injury, and the patient displayed superficial granulomas and atypical CD30+ lymphocytes. (*Ann Dermatol (Seoul)* 21(1) 95~97, 2009)

**-Keywords-**

Contact dermatitis, Coral, Granuloma

## INTRODUCTION

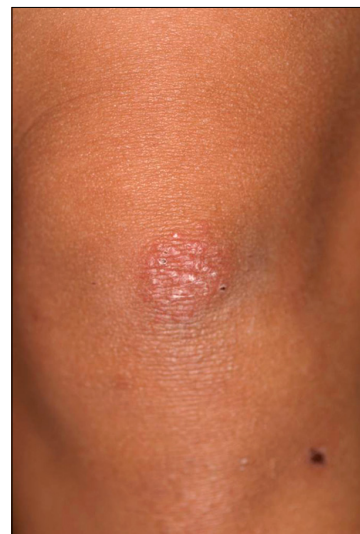Corals are coelenterates of the Anthozoa class<sup>1</sup>. They may cause injury either because of their nematocytes or due to their sharp-edged calcareous outer skeletons. Stings from their nematocytes may cause a rare type of contact dermatitis that can be divided into different reactions: acute, delayed and chronic coelenterate dermatitis. Acute reactions, such as acute urticaria and vesiculobullous lesions, can be due to the immediate effect of toxic substances contained in nematocytes, including quaternary ammonium compounds, proteins, 5-hydroxytryptamine, catecholamines, histamine and histamine liberators. Delayed reactions are less well known, but they are thought to be induced through both immediate and de-

layed hypersensitivity mechanisms. Chronic, persistent reactions are assumed to be a form of allergic contact dermatitis<sup>2</sup>.

We report here on a rare case of a delayed reaction of the skin to coral injury, and the patient displayed superficial granulomas. Among the different delayed reactions, granulomas have rarely been reported<sup>3</sup>. With the atypical CD30+ lymphocytes seen in this case, the delayed granulomatous reaction in our patient was considered to be an allergic foreign-body granuloma due to a hypersensitivity reaction and persistent antigen stimulation.

## CASE REPORT

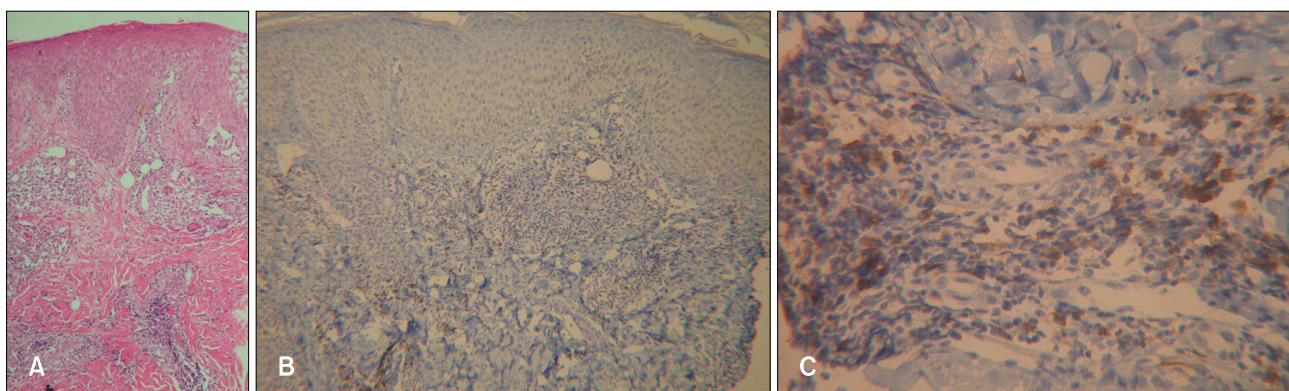
Several minutes after coming in contact with hard coral in the Gulf of Thailand, South China Sea, a 28-year-old



**Fig. 1.** An erythematous patch, 2.5 cm in diameter, was composed of multiple flat papules on the left knee.

Received June 30, 2008, Accepted for publication September 12, 2008

**Reprint request to:** Hyun Jeong Park, M.D., Department of Dermatology, St. Mary's Hospital, College of Medicine, The Catholic University of Korea, 62, Yeouido-dong, Yeongdeungpo-gu, Seoul 150-713, Korea. Tel: 82-2-3779-1230, Fax: 82-2-783-7604, E-mail: hjpark@catholic.ac.kr



**Fig. 2.** (A) Dense, superficial perivascular and periadnexal infiltrates of lymphocytes and eosinophils in the dermis and focal, superficial, small epithelioid granulomas with multinucleated giant cells (H&E,  $\times 100$ ). (B, C) Superficial patchy CD30+ nucleolated lymphocytes in the inflammatory infiltrates and the magnified view (alkaline phosphatase-antialkaline phosphatase,  $\times 100$ ,  $\times 400$ ).

female had a stinging, burning sensation on the resulting scratch wound on her left knee. Five days later, a pruritic erythematous patch composed of multiple flat papules developed at the site of the previous scratch (Fig. 1). No systemic symptoms were observed. The patient had no specific history of allergy. A biopsy was taken from the lesional skin. The epidermis showed acanthosis, spongiosis and focal lymphocyte exocytosis. A dense, superficial perivascular and periadnexal infiltrate of lymphocytes and eosinophils was present in the dermis. Focal superficial small epithelioid granuloma with multinucleated giant cells and focal collagen degeneration was also present (Fig. 2A). Observation under polarized light failed to demonstrate any foreign material inside the granulomas. On the immunohistochemistry, CD3+ and CD4+ T-helper (Th) cells, S-100+ dendritic cells and CD30+ nucleolated atypical lymphocytes were revealed in the inflammatory infiltrates (Fig. 2B, C). After one month of topical corticosteroid application, the skin lesions cleared completely with leaving some residual hypopigmentation.

## DISCUSSION

Coral dermatitis can be divided into three or four stages. Miracco et al<sup>2</sup> divided it into the acute, delayed and chronic stages and Addy<sup>4</sup> classified it as acute urticaria, acute vesicubullous dermatitis, subacute fleshy granulomatous dermatitis and chronic lichenoid dermatitis. These stages does not have strict definitions, but the clinically acute stage usually develops immediately or within several hours after contact with coral and it resolves within several hours or days. The delayed stage can develop several days or weeks after this. The chronic stages can be recurrent or the lichenoid dermatitis can persist. The histology of the acute stages show spongiosis

with microvesicles, intracellular edema of the epidermis and edema of the papillary dermis. The features of the delayed stages are similar to those of pityriasis lichenoides and persistent insect-bite reaction, showing wedge shaped, subepidermal and perivascular mononuclear cell infiltrates and extravasated erythrocytes. The chronic stages show acanthosis, parakeratosis and an increased granular layer, in addition to a diffuse dense mononuclear cell infiltration in the upper dermis<sup>2,4</sup>.

The skin lesions in the current case are clinically and pathologically similar to those described in the cases of delayed skin reaction to coelenterates, except this case also showed superficial granulomas. Miracco et al<sup>2</sup> reported a case that displayed a delayed skin reaction to coral injury with superficial granulomas and atypical CD30+ lymphocytes. The same results were obtained on immunohistochemical staining. We observed a predominance of Langerhans cells and Th lymphocytes in the inflammatory infiltrates, as well as focal epithelioid granulomas and numerous large CD30+ nucleolated lymphocytes.

It has generally been assumed that most coelenterate envenomation reactions are toxic rather than allergic, but there have been several reports of delayed, recurrent, persistent skin reactions that have been attributed to allergies. In addition to type I hypersensitivity, type IV allergy is considered to be involved in some such eruptions<sup>5</sup>. Addy et al<sup>4</sup> showed coral dermatitis to be an allergic contact dermatitis because not all people who have contact with coral actually develop the dermatitis. That study suggested some of the risk factors for coral dermatitis are seafood allergy and atopic dermatitis.

The granuloma of coral dermatitis is considered to be a foreign-body reaction. Generally, the foreign-body granulomas can be divided into two groups: nonallergic and

allergic. Nonallergic foreign-body reaction typically shows a granulomatous response that's marked by histiocytes and giant cells surrounding the foreign material. Often, some of the giant cells are of the foreign-body type. Polariscopy is helpful for identification of foreign materials. Allergic foreign-body granuloma shows a sarcoidal or tuberculoid pattern that consists of epithelioid cells with or without giant cells. Phagocytosis of the foreign substance is very slight or absent. Some substances that first act as foreign material may later on act as allergens after sensitization has occurred, as in the case of sea-urchin spines and silica<sup>6</sup>. In this case, the superficial granuloma was considered to be caused by allergic reaction. The clinically delayed onset of the skin lesions, the pathologically epithelioid cell infiltrations with Langerhans giant cells and no foreign material found by polariscopy suggest allergic reaction was responsible for the patient's condition.

The CD30 (Ki-1) antigen expression on T cells has been proposed to be a marker for a subset of memory T cells with potent B cell helper activity<sup>7</sup>. Atypical CD30+ T cells are frequently observed in lymphoproliferative disorders and acute atopic dermatitis, scabies and EBV, HIV, HTLV and hepatitis B&C virus infection. The presence of atypical CD30+ lymphocytes can be considered to be due to hypersensitivity reaction and persistent antigen stimulation. The described case is the second case report showing superficial granuloma formation with CD30+ T cells in a patient with delayed coral dermatitis. The case of Miracco et al<sup>2</sup> is quite similar to our case, except their patient suffered from atopic dermatitis. Because CD30+ lymphocytes are frequently found in atopic patients<sup>8</sup>, they may not be associated with delayed

coral dermatitis. However, because our case did not have a history of atopic dermatitis, we can suggest there was a more reliable association between CD30+ lymphocytes and the delayed granulomatous coral dermatitis. Further studies are needed to determine the function of the CD30+ lymphocytes in delayed coral dermatitis, and especially in the resulting granuloma.

## REFERENCES

---

1. Tong D. Coral dermatitis in the aquarium industry. *Contact Dermatitis* 1995;33:207-208.
2. Miracco C, Lalinga AV, Sbrano P, Rubegni P, Romano C. Delayed skin reaction to Red Sea coral injury showing superficial granulomas and atypical CD30+ lymphocytes: report of a case. *Br J Dermatol* 2001;145:849-851.
3. Weedon D, Strutton G. Marine injuries. In: Weedon D, Strutton G, editors. *Skin pathology*. 1st ed. Edinburgh: Churchill Livingstone, 1997:611-619.
4. Addy JH. Red sea coral contact dermatitis. *Int J Dermatol* 1991;30:271-273.
5. Camarasa JG, Nogues Antich E, Serra-Baldrich E. Red Sea coral contact dermatitis. *Contact Dermatitis* 1993;29:285-286.
6. David EE, Rosalie E, Bernett LJ Jr, Gerorge FM. *Lever's histopathology of the skin*. 9th ed. Philadelphia: Lippincott Williams & Wilkins, 2005:384-386.
7. Lucey DR, Clerici M, Shearer GM. Type 1 and type 2 cytokine dysregulation in human infectious, neoplastic, and inflammatory diseases. *Clin Microbiol Rev* 1996;9:532-562.
8. Dummer W, Rose C, Brocker EB. Expression of CD30 on T helper cells in the inflammatory infiltrate of acute atopic dermatitis but not of allergic contact dermatitis. *Arch Dermatol Res* 1998;290:598-602.