

# Brain volumes in psychotic youth with schizophrenia and mood disorders

Mohamed El-Sayed, MD, MSC, PhD; R. Grant Steen, PhD; Michele D. Poe, PhD;  
T. Carter Bethea, MD; Guido Gerig, PhD; Jeffrey Lieberman, MD; Linmarie Sikich, MD

El-Sayed, Steen, Bethea, Gerig, Sikich — Department of Psychiatry; Poe — Frank Porter Graham Child Development Center, University of North Carolina at Chapel Hill, NC; El-Sayed — Department of Psychiatry, Mansoura University, Mansoura, Egypt; Gerig — Departments of Psychiatry, Computer Science and Bioengineering, University of Utah, Salt Lake City, Utah; Lieberman — Department of Psychiatry, Columbia University, New York, NY

**Background:** We sought to test the hypothesis that deficits in grey matter volume are characteristic of psychotic youth with early-onset schizophrenia-spectrum disorders (EOSS) but not of psychotic youth with early-onset mood disorders (EOMD). **Methods:** We used magnetic resonance imaging to examine brain volume in 24 psychotic youth (13 male, 11 female) with EOSS ( $n = 12$ ) or EOMD ( $n = 12$ ) and 17 healthy controls (10 male, 7 female). We measured the volume of grey and white matter using an automated segmentation program. **Results:** After adjustment for age and intracranial volume, whole brain volume was lower in the EOSS patients than in the healthy controls ( $p = 0.001$ ) and EOMD patients ( $p = 0.002$ ). The EOSS patients had a deficit in grey matter volume ( $p = 0.005$ ), especially in the frontal ( $p = 0.003$ ) and parietal ( $p = 0.006$ ) lobes, with no significant differences in white matter volume. **Limitations:** The main limitations of our study were its small sample size and the inclusion of patients with depression and mania in the affective group. **Conclusion:** Adolescents with EOSS have grey matter deficits compared with healthy controls and psychotic adolescents with EOMD. Our results suggest that grey matter deficits are not generally associated with psychosis but may be specifically associated with schizophrenia. Larger studies with consistent methods are needed to reconcile the contradictory findings among imaging studies involving psychotic youth.

## Introduction

Structural brain changes, particularly reductions in grey matter volume, are well established in schizophrenia. A meta-analysis of adults with first-episode schizophrenia found robust changes in total brain volume and cerebrospinal fluid (CSF) with more limited data indicating volumetric deficits in total cortical grey matter and temporal grey matter.<sup>1</sup> Recent studies have consistently found grey matter deficits in patients with first-episode schizophrenia<sup>2</sup> and chronic schizophrenia.<sup>3</sup> Youth with treatment-resistant childhood-onset schizophrenia have marked reductions in cortical grey matter, which are initially present medially and posteriorly.<sup>4</sup> Longitudinal volumetric studies involving patients with childhood-onset schizophrenia have shown progressive cortical changes that involve the entire cortex within 5 years and then gradually become limited to the

frontal and temporal regions in early adulthood.<sup>5-10</sup> It remains unclear whether the structural changes observed in childhood-onset, compared with adult-onset, schizophrenia are associated with disruption of a neurodevelopmental process, as has been suggested by some genetic studies.<sup>11-13</sup> Alternatively, structural changes could be associated with chronic illness, positive psychotic symptoms, treatment resistance or a combination of these factors. It is also unclear whether youth with more typical adolescent-onset schizophrenia have grey matter changes of the same magnitude and spatial extent as youth with childhood-onset schizophrenia.

A review of longitudinal brain changes in childhood-onset schizophrenia and adolescent-onset psychosis reported evidence of increased CSF and reduced grey matter at diagnosis in both disease states, but there is a lack of consensus about progressive changes thereafter.<sup>5</sup> Studies involving adolescents

**Correspondence to:** Dr. L. Sikich, Department of Psychiatry, University of North Carolina, Chapel Hill NC 27599-7160; fax 919 966-9646; lsikich@med.unc.edu

*J Psychiatry Neurosci* 2010;35(4):229-36.

Submitted Apr. 20, 2009; Revised Nov. 5, 2009, Feb. 5, 2010; Accepted Feb. 9, 2010.

DOI: 10.1503/jpn.090051

with schizophrenia have found increased fourth ventricle CSF and reduced prefrontal cortex total, grey and white matter volume, but not reduced total brain volume at diagnosis.<sup>14,15</sup> Among adolescents with undifferentiated psychosis, increases in intracranial CSF and reductions in frontal grey matter have been reported; these changes appear to be less severe than in patients with childhood-onset schizophrenia.<sup>16</sup>

We asked whether the brain volume differences between patients and controls are because of disease-specific neurodevelopmental factors or chronic psychotic symptoms. One approach to answer this question is to compare structural brain changes between adolescents with early-onset schizophrenia-spectrum disorders (EOSS) and adolescents experiencing positive psychotic symptoms as part of affective illness. Youth with early-onset affective illness more often experience psychotic symptoms than do individuals with adult-onset affective illness. Furthermore, the course of illness is often more severe and long term in youth with mood disorders than in patients with adult-onset mood disorders.

We sought to determine whether the brain changes observed in youth experiencing psychotic symptoms in the context of EOSS and early-onset mood disorders (EOMD) are similar. Similarities would suggest that the greater brain changes reported in patients with childhood-onset schizophrenia relative to adult-onset schizophrenia are related to an earlier onset of the psychotic process. Differences would suggest that the brain changes in EOSS are unique to the pathophysiology of schizophrenia, rather than being related to psychosis or severe psychiatric illness.<sup>17</sup>

Few studies have directly compared cortical volume in adults with schizophrenia to that in adults with other active psychosis.<sup>18-25</sup> These studies have not yielded consistent results, although differences in the brain regions studied and in the specific diagnostic subtypes of the psychotic (nonschizophrenic) groups may have contributed to disparate findings.

To assess the potential role of disrupted neurodevelopmental processes in the development of psychosis, it is important to extend the studies comparing affective and schizophrenic psychoses to adolescence, a time when psychotic symptoms frequently begin and when normal neurodevelopmental processes are highly active. We hypothesized that adolescents with schizophrenia would have more pronounced grey matter deficits than those with affective psychoses or normal controls. In this study, we tested the hypothesis that differences in brain volume are associated specifically with schizophrenia, rather than with psychosis in general.

## Methods

### *Participants*

We included adolescents with psychosis who were experiencing at least 1 positive psychotic symptom of moderate or greater severity on the Brief Psychiatric Rating Scale for Children,<sup>26</sup> this symptom had to have been present for at least 2 weeks. These criteria allowed for the inclusion of those with a possible diagnoses of schizophrenia, schizoaffective disorder, major depression with psychotic features and bipolar af-

fective disorder with psychotic features. All diagnoses were made on the basis of a medical record review, detailed clinical examination by an adolescent psychiatrist (L.S.) and a structured diagnostic interview administered by a social worker or psychiatric nurse immediately after the youth enrolled in the study. All clinicians achieved 0.85 interrater reliability on the New York University form of the Schedule for Affective Disorders and Schizophrenia for School-Age Children Present and Lifetime Version (K-SADS-PL)<sup>27</sup> and on the Structured Clinical Interview for DSM-IV (SCID).<sup>28</sup> The K-SADS-PL and the psychotic disorders section of the SCID were used for most participants, whereas the SCID alone was used for participants older than 18 years ( $n = 3$ ).

We excluded patients with psychotic symptoms that were secondary to substance intoxication or withdrawal, those with a full scale intelligence quotient less than 70, those with a concurrent diagnosis of pervasive developmental disorder, those with any neurologic disorder, and those who were pregnant or who posed imminent risk of harm to themselves or others.

The psychotic adolescents were recruited on the basis of participation in an ongoing antipsychotic treatment study involving 50 youth with active psychosis. We recruited control participants from the community through advertisement and by word of mouth. Controls had no psychiatric disorder or neurologic disease, as determined by K-SADS-PL and focused neurologic examination. Controls and their guardians self-reported that they had no first-degree relatives with a major psychiatric disorder. Psychotic patients and controls were recruited over a 3.5-year period. There was no change in the scanner protocol during this period.

The protocol was approved by the Institutional Review Board of the University of North Carolina. Each adolescent gave written assent and each participant 18 years or older gave written informed consent, as did all patient guardians.

### *Magnetic resonance imaging*

All magnetic resonance imaging (MRI) examinations were performed on a 1.5-T Signa scanner (GE Medical Systems) using a standard head coil. Routine, weekly quality-assurance monitoring was done for field homogeneity, eddy current compensation and image quality, and there were procedures in place for daily signal-to-noise measurement in the head coil using a standard phantom. A scout sequence was run for each participant to achieve similar slice positioning, and  $T_1$ - and  $T_2$ -weighted image sets were acquired in the axial plane. The  $T_1$ -weighted sequence was a 3-dimensional inversion recovery-prepped axial spoiled gradient-recalled acquisition in steady state sequence (repetition time [TR] 12.3 ms, echo time [TE] 5.4 ms, flip angle 20°, slice thickness 1.5 mm, field of view 24 cm, matrix 256 × 256, 124 slices, acquisition time 9:47 min). The  $T_2$ -weighted sequence was an axial double-echo fast spin echo (FSE) multiplanar sequence with flow compensation (TR 3000 ms, flip angle 90°, slice thickness 3.0 mm, field of view 24 cm, matrix 256 × 160, 60 slices, acquisition time 10:35 min) to provide both  $T_2$ -weighted (TE 70 ms) and proton density-weighted (TE 28 ms) images. The FSE was zero-padded in the phase-encoding direction from 160 to 256. Coregistered sets

of  $T_1$  and dual-echo FSE were used to perform a multivariate classification of 3 contrast channels. Parameters were optimized to show grey and white matter with good contrast and to yield reproducible segmentation with an automated program. The entire exam was typically completed in 20 minutes.

### Analysis of brain volume by MRI

Brain volumetric assessments were made using a suite of programs developed at the University of North Carolina ([www.cs.unc.edu/~gerig/soft.html](http://www.cs.unc.edu/~gerig/soft.html)). The MRI data were analyzed in a multistep process that was designed to facilitate volumetric analysis. After skull-stripping and correction for magnetic resonance bias inhomogeneity were performed individually for each channel, we interpolated the baseline  $T_1$ -weighted data to an isotropic  $1 \times 1 \times 1 \text{ mm}^3$  grid and registered the data to the International Consortium for Brain Mapping probabilistic brain atlas, so that all brains were analyzed and displayed in a standard coordinate system. The dual-echo  $T_2$ -weighted data were registered to the  $T_1$ -weighted data, and all images were analyzed with a 3-channel segmentation, which used an automatic, atlas-based brain tissue segmentation program (Expectation Maximization Segmentation) to separate brain tissue into grey matter, white matter and CSF.<sup>29</sup> The probabilistic brain atlas driving the tissue segmentation utilizes Talairach-based box parcellation that divides left from right hemispheres and coarsely represents the frontal, temporal, occipital and parietal lobes.<sup>30</sup> Atlas registration overlays these boxes onto each scan, thereby creating a fully automatic brain parcellation for each data set. We measured ventricular volume by use of an automated level-set evolution method. All measurements were performed without knowledge of the participant's diagnosis.

Most of the tools used were fully automatic (atlas registration and intermodality registration, brain tissue segmentation, parcellation) or automated with minimal user interaction (initialization of ventricle segmentation), which makes the procedures robust against rater drift. We calculated the intraclass correlation coefficient for the only manual process using a sample set of 5 data sets replicated 3 times, which resulted in 15 image data sets. The trained expert user (M.E.S.), who performed all measurements in this study, applied the ventricular volume tool to this set of 15 images. The intraclass correlation coefficient for the ventricular volume measurement process was 0.999, demonstrating excellent intrarater reliability. Our analysis was limited to the relatively large structures that can be measured with a high degree of measurement precision (Fig. 1).

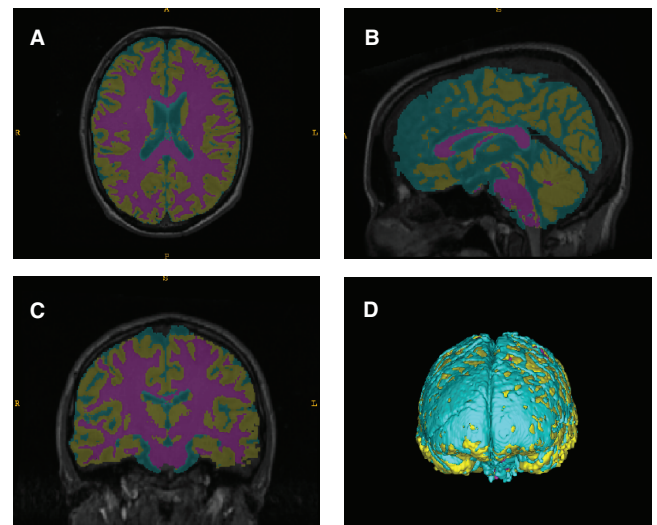
### Statistical analyses

We performed all statistical analyses using SAS 9.1. We used descriptive statistics and data plots to look for outliers and group differences in baseline characteristics. We examined the intracranial volume, CSF and lateral ventricle volumes using a general linear model that was adjusted for age and sex. The dependent variable was volume, and the independent variables were diagnostic group, age and sex. We controlled for

age because it is a strong predictor of brain volume in children.<sup>31</sup> To control the rate of type I errors, we required that the test of diagnosis group (2 degrees of freedom) be significant at the  $\alpha = 0.05$  level before the 2-way contrasts between groups were interpreted.

We performed tests concerning lobe and tissue volume by standard mixed-models analyses with repeated-measures over a spatial domain (regional brain volumes). Each participant had 16 repeated measures, which were designated by a combination of 3 independent variables: lobe (frontal, temporal, parietal, occipital), tissue type (grey or white) and hemisphere (left or right). The dependent variable was regional volume, whereas the independent variables included lobe, tissue, hemisphere and diagnosis group; we included all 2-, 3- and 4-way interactions between these 4 variables. In addition, we included age and intracranial volume as control variables in the regression analyses, along with the interactions between each of these variables and region and tissue. We also included intelligence quotient and sex as covariates in the model; these variables did not contribute significantly or change the results, so they were not included in the final analyses.

We performed initial comparisons of total brain, grey and white matter volumes between the 2 diagnostic groups and between each of the diagnostic groups and the healthy control group. Because we found no difference in the volumes of the brain structures between the EOMD and control group, we combined these groups. The subsequent analyses of regional volumes compared the EOSS group with the combined EOMD and control group. This increased the sample size of participants included as controls, yet it is consistent with our initial hypothesis that only patients in the EOSS group would show volume changes.



**Fig. 1:** False colour of grey and white matter segmentation. Representative participant magnetic resonance imaging data following image registration and segmentation showing the axial (A), sagittal (B) and coronal (C) views, with 3-dimensional surface rendering (D). An atlas-based 3-channel tissue segmentation program (Expectation Maximization Segmentation) was used to segregate white matter (puce), grey matter (gold) and cerebrospinal fluid (blue).

To adjust for heteroscedasticity within the regions of interest, we computed empirical estimates using the empirical option of SAS Proc Mixed<sup>32</sup> because lobes and other small structures can have different means and variances. To adjust for systematic variances in the regional brain volumes, we computed empirical estimates of the standard errors with a correction factor for small samples using SAS Proc Mixed.<sup>32,33</sup>

## Results

### Participants

In total, we included 15 patients with schizophrenia spectrum disorder (schizophrenia or schizoaffective disorder, hereafter referred to as schizophrenia), 14 patients with affective psychoses and 17 healthy controls. Twenty-nine of the 50 participants in the psychosis-treatment study (58%) completed imaging. Reasons for not completing the imaging included metal in their body or braces ( $n = 5$ ), too psychotic to tolerate the MRI procedure ( $n = 4$ ), aged less than 12 years ( $n = 4$ ) and declined to participate ( $n = 8$ ). In addition, the images of 5 patients (3 with EOSS and 2 with EOMD) were excluded because of inadequate image quality for segmentation owing to motion artifacts during the scan procedure.

The final analyzed sample included 12 patients with schizophrenia (6 with schizoaffective disorder), 12 patients with affective psychosis (7 with psychotic depression, 5 with

bipolar disorder) and 17 controls (Table 1). Age did not significantly differ between the groups. There were fewer male participants in the EOMD group than in either the EOSS or control groups (Table 1).

### Brain volumes

There was no significant difference in intracranial volume across the 3 groups after adjustment for age and sex ( $F_{2,35} = 1.78$ ,  $p = 0.18$ ). The distribution of grey matter, white matter and CSF volumes proportional to total intracranial volume in each group is shown in Figure 2. Total, grey matter and white matter volumes adjusted for age and intracranial volume are provided in Table 2. After adjustment for age and intracranial volume, the EOSS group had reduced total brain volume compared with the healthy control group ( $-2.2\%$ ,  $t_{36} = -3.88$ ,  $p = 0.001$ ) and the EOMD group ( $-2.0\%$ ,  $t_{36} = -3.88$ ,  $p = 0.002$ ). After adjustment, the EOSS group had reduced grey matter compared with the healthy control group ( $-4.0\%$ ,  $t_{36} = -3.13$ ,  $p = 0.001$ ) and EOMD group ( $-4.5\%$ ,  $t_{36} = -3.29$ ,  $p = 0.019$ ), but there was no differences in white matter volume (data not shown). In contrast, there were no differences in adjusted total brain volume, grey matter or white matter between the EOMD group and the healthy control group ( $p = 0.40$  to  $0.48$ ).

All subsequent comparisons involved the EOSS group and the combined control group (EOMD plus healthy controls; Table 2). The EOSS group had significantly reduced adjusted

**Table 1: Demographic and clinical characteristics of participants**

| Characteristic  | Group; mean (SD)*         |                           |                           |
|---|---------------------------|---------------------------|---------------------------|
|   | Schizophrenia, $n = 12$   | Mood disorder, $n = 12$   | Healthy control, $n = 17$ |
| Age, yr, mean (SD) [range]                            | 16.2 (2.5)<br>[12.1–19.7] | 14.9 (1.9)<br>[12.9–17.9] | 15.9 (2.1)<br>[12.1–19.1] |
| Head circumference, mm                                | 561.0 (14.8)              | 531.5 (15.6)              | 555.5 (27.2)              |
| Intracranial volume, mm <sup>3</sup>                  | 1341.8 (108.6)            | 1235.7 (142.1)            | 1365.7 (167.4)            |
| Male, no. (%) of participants                         | 9 (75)                    | 4 (33)                    | 10 (59)                   |
| Nonwhite, no. (%) of participants                     | 6 (50)                    | 3 (25)                    | 8 (47)                    |
| Age at onset, yr                                      | 13.55 (4.27)              | 12.83 (2.79)              | —                         |
| Duration of illness, yr                               | 2.60 (2.67)               | 2.03 (1.81)               | —                         |
| Previous hospitalizations, no.                        | 1.09 (1.58)               | 0.50 (0.67)               | —                         |
| Medication history, no. (%) of participants           |                           |                           | —                         |
| Previous typical antipsychotic                        | 7 (58)                    | 0                         |                           |
| Previous risperidone                                  | 8 (67)                    | 4 (33)                    |                           |
| Previous olanzapine                                   | 6 (50)                    | 3 (25)                    |                           |
| Previous other atypical antipsychotic                 | 0                         | 1 (8)                     |                           |
| Previous antidepressant medications                   | 6 (50)                    | 6 (50)                    |                           |
| Previous mood stabilizer                              | 2 (17)                    | 1 (8)                     |                           |
| Symptom severity                                      |                           |                           | —                         |
| Childhood psychiatric rating scale, positive symptoms | 29.45 (1.37)              | 31.42 (6.44)              |                           |
| Childhood psychiatric rating scale, negative symptoms | 24.18 (14.53)             | 19.08 (12.72)             |                           |
| Brief psychiatric rating for children, total score    | 73.2 (14.7)               | 74.7 (11.6)               |                           |
| Depression items                                      | 9.3 (4.9)                 | 12.7 (4.4)                |                           |
| Mania items   | 12.1 (4.3)                | 14.0 (4.0)                |                           |
| Baseline intelligence quotient                        | 79.1 (14.9)               | 98.2 (12.8)               |                           |

SD = standard deviation.

\*Unless otherwise indicated.

total brain volume ( $-2.1\%$ ,  $t_{36} = -3.70$ ,  $p < 0.001$ ) and total grey matter ( $-4.2\%$ ,  $t_{36} = -3.42$ ,  $p = 0.002$ ) compared with the combined control group. There were no significant differences between groups for white matter volume ( $t_{36} = 1.13$ ,  $p = 0.27$ ).

We observed similar relations for adjusted total and grey matter volumes in the frontal and parietal lobes, with the EOSS group having significantly smaller volumes than the combined control group (Fig. 3). There was no differences between the EOSS group and the combined control group for adjusted volume in the temporal and occipital lobes or for

adjusted white matter volume in any lobe. The EOSS group had significantly greater adjusted CSF volume than the combined control group ( $12.6\%$ ,  $t_{36} = 4.32$ ,  $p < 0.001$ ). However, the adjusted lateral ventricle volume was not different between the EOSS group and the combined control group ( $t_{36} = 0.74$ ,  $p = 0.46$ ).

### Discussion

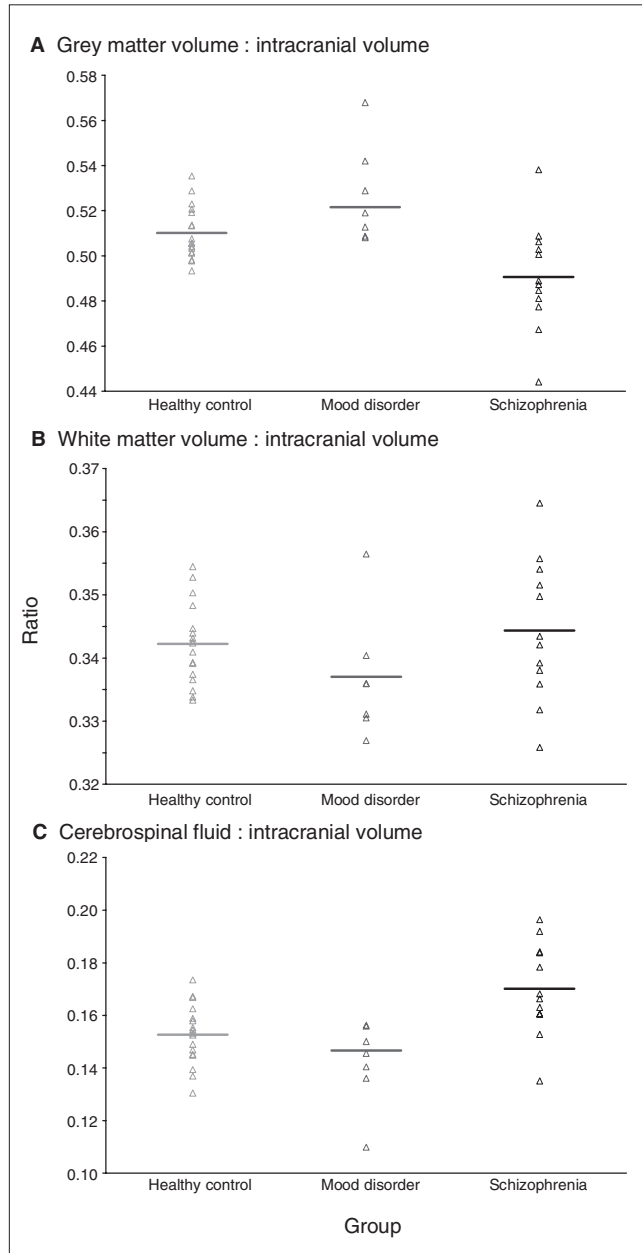
In this study, we report total and regional deficits of grey matter volume in psychotic adolescents with schizophrenia but not in psychotic adolescents with mood disorder. The deficits in grey matter volume were significant in the frontal and parietal lobes. Our results suggest that structural brain changes may be specifically associated with schizophrenia but not generally associated with psychotic symptoms.

Our results in the EOSS group are largely consistent with earlier results from childhood-onset schizophrenia and first-episode schizophrenia studies which reported that grey matter deficits are most prominent in parietal cortices.<sup>4,8,9</sup> In contrast to longitudinal studies in childhood-onset and adult-onset schizophrenia, we did not observe significant grey matter deficits in the temporal lobe.<sup>8,9</sup> The discrepancy in the temporal lobe could also reflect imaging earlier in the disease process or relatively small differences that are only apparent in large samples. Alternatively, divergent results may reflect differences in imaging methods or phenotypic variability in schizophrenia.

Our findings in the schizophrenia group are consistent with those of Nakamura and colleagues,<sup>23</sup> with caveats. We did not detect any differences in grey matter volume in patients with affective psychoses, which contradicts the findings of the baseline scan in their sample. However, our findings are consistent with their 18-month follow-up data, which suggests that the duration of illness may be critical in determining brain volumetric deficits. The mean duration of illness in our sample was 24 months. Our results are also consistent with other comparative studies of first-episode schizophrenia and first-episode affective psychosis.<sup>18,20-22,24</sup> Although a recent study found several grey matter deficits that appeared to be unique to EOSS, it also suggested that left medial frontal grey matter deficits may be common to both adolescents with EOSS and first-episode bipolar psychosis.<sup>34</sup>

### Limitations

The greatest limitation of our study is the small sample size, which limits our ability to detect small differences in volume. We also lacked the power to rigorously test the correlations between cortical volume and clinical and symptomatic characteristics. These results do not preclude the existence of smaller or more focal differences between either psychotic group and healthy controls that might be revealed with other methods or a larger sample size. A strength of our study is that we focused on youth with adolescent-onset schizophrenia rather than on the more rare childhood-onset disorder. Furthermore, most of the participants were not resistant to treatment and had relatively limited exposure to psychotropic drugs.

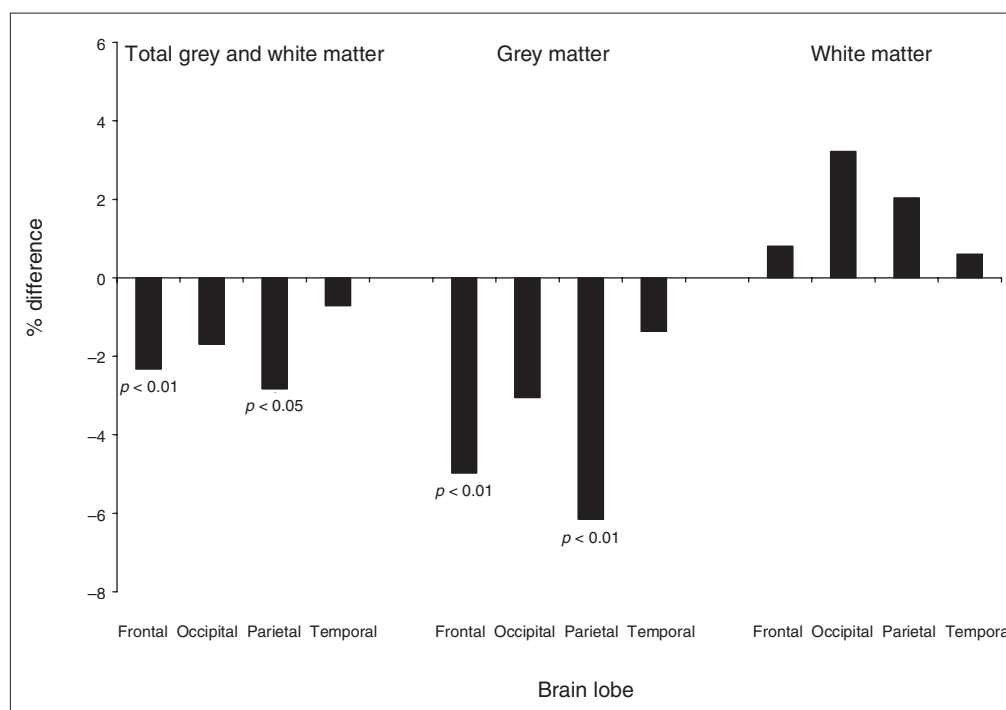


**Fig. 2:** Distribution of brain volume ratios by group with no correction for age. (A) Ratio of grey matter to intracranial volume, (B) ratio of white matter to intracranial volume and (C) ratio of cerebrospinal fluid to intracranial volume.

**Table 2: Group means and differences between schizophrenia patients and combined controls (mood disorder and healthy controls) for grey and white matter volumes**

| Brain region                | Group; brain volume, mm <sup>3</sup> , mean* (SE) |                       |                         |                        | Schizophrenia v. mood disorder and healthy control participants |      |      |         |
|-----------------------------|---|-----------------------|-------------------------|------------------------|---|------|------|---------|
|                             | Schizophrenia, n = 12                             | Mood disorder, n = 12 | Healthy control, n = 17 | Mood + control, n = 29 | Difference  | SE   | %    | p value |
| Intracranial                | 1303.0 (37.0)                                     | 1273.7 (37.9)         | 1360.9 (30.3)           | 1317.3 (23.9)          | -14.4   | 25.4 | -1.1 | 0.75    |
| Cerebrospinal fluid         | 223.5 (4.5)                                       | 197.9 (4.8)           | 199.0 (3.8)             | 198.7 (3.1)            | 25.0  | 5.4  | 12.6 | < 0.001 |
| Lateral ventricle           | 13.3 (1.1)  | 13.4 (1.2)            | 11.2 (1.0)              | 12.3 (0.7)             | 1.0   | 1.4  | 8.1  | 0.46    |
| Total grey and white matter | 1094.5 (5.6)                                      | 1116.4 (4.4)          | 1118.6 (2.6)            | 1116.4 (2.5)           | -23.0   | 6.2  | -2.1 | < 0.001 |
| Frontal lobe                | 554.5 (4.0)                                       | 564.4 (3.1)           | 571.0 (3.1)             | 567.1 (2.2)            | -13.2   | 4.7  | -2.3 | 0.008   |
| Occipital lobe              | 146.9 (2.6)                                       | 150.3 (2.2)           | 148.6 (2.5)             | 149.3 (1.7)            | -2.5  | 3.2  | -1.7 | 0.44    |
| Parietal lobe               | 204.4 (1.9)                                       | 212.1 (2.4)           | 208.6 (1.9)             | 210.1 (1.5)            | -5.9  | 2.5  | -2.8 | 0.024   |
| Temporal lobe               | 188.6 (3.4)                                       | 189.5 (2.3)           | 190.5 (2.1)             | 189.8 (1.5)            | -1.3  | 4.0  | -0.7 | 0.74    |
| Grey matter                 | 647.4 (7.6)                                       | 676.6 (5.3)           | 674.7 (2.9)             | 675.0 (2.8)            | -28.3   | 8.3  | -4.2 | 0.002   |
| Frontal lobe                | 292.1 (4.2)                                       | 306.6 (3.1)           | 308.2 (1.9)             | 307.1 (1.7)            | -15.3   | 4.7  | -5.0 | 0.002   |
| Occipital lobe              | 113.3 (2.2)                                       | 117.2 (1.7)           | 116.5 (1.9)             | 116.7 (1.3)            | -3.6  | 2.6  | -3.1 | 0.18    |
| Parietal lobe               | 117.4 (2.1)                                       | 126.7 (1.5)           | 123.4 (1.4)             | 124.9 (1.0)            | -7.7  | 2.4  | -6.2 | 0.003   |
| Temporal lobe               | 124.6 (2.4)                                       | 126.1 (1.9)           | 126.6 (1.5)             | 126.2 (1.1)            | -1.7  | 2.8  | -1.4 | 0.55    |
| White matter                | 447.1 (4.1)                                       | 439.8 (3.9)           | 444.0 (2.1)             | 441.4 (2.1)            | 5.3   | 4.7  | 1.2  | 0.27    |
| Frontal lobe                | 262.4 (3.3)                                       | 257.7 (2.6)           | 262.9 (2.1)             | 260.0 (1.6)            | 2.1   | 3.7  | 0.8  | 0.58    |
| Occipital lobe              | 33.7 (0.9)  | 33.2 (0.9)            | 32.1 (1.0)              | 32.6 (0.7)             | 1.0   | 1.2  | 3.2  | 0.37    |
| Parietal lobe               | 87.0 (1.2)  | 85.4 (1.3)            | 85.1 (0.8)              | 85.2 (0.7)             | 1.7   | 1.4  | 2.0  | 0.24    |
| Temporal lobe               | 64.1 (1.3)  | 63.4 (1.4)            | 63.9 (0.9)              | 63.6 (0.8)             | 0.4   | 1.6  | 0.6  | 0.82    |

SE = standard error of the mean.  
\*Adjusted for age and intracranial volume.



**Fig. 3:** Differences between patients with schizophrenia and other participants (healthy controls and patients with mood disorder). Percentages have been adjusted by age and intracranial volume. The p values are for the comparisons between the adjusted lobar volumes in the early-onset schizophrenia-spectrum disorders group and in the combined control group (early-onset mood disorder group plus healthy controls) for the specific lobes.

## Conclusion

The finding of grey matter reduction in patients with schizophrenia but not in those with mood disorder suggests that grey matter deficits may be a specific feature of schizophrenia rather than a general feature of psychosis. This may mean that volumetric deficits are related more to negative and cognitive symptoms rather than to positive symptoms. A better understanding of the underlying pathophysiology of schizophrenia and optimized design of next-generation treatment will require larger samples from multisite consortiums and more uniform analysis procedures.

**Acknowledgements:** This study was supported by a National Institute of Mental Health grant (MH53551), University of North Carolina Mental Health and Neuroscience Clinical Research Center (MH MH33127), National Institutes of Health grant (RR00046) from the General Clinical Research Centers program, and National Alliance for Research on Schizophrenia and Affective Disorders. Dr. El-Sayed was supported by a training scholarship from the Egyptian Government. Data from this study were presented at the 2004 American Academy of Child and Adolescent Psychiatry Meeting, Washington, D.C., at the 2004 Society of Biological Psychiatry Convention, New York, NY, and at the 2004 American Psychiatric Association Annual Meeting, New York, NY.

**Competing interests:** Janssen Pharmaceutical and Eli Lilly donated drugs to the initial treatment study from which participants for the present study were recruited. Dr. Sikich received consultancy fees from Sanofi Aventis; honoraria from the American Academy of Child and Adolescent Psychiatry, Medscape, Physicians Postgraduate Press, the Society for Adolescent Medicine, the North Carolina Psychiatric Association, the North Carolina School Community Health Association, Autism Speaks and IMEDEX for teaching, preparing continuing medical education material or conducting informational talks; payment for manuscript preparation from Physicians Postgraduate Press; and royalties from Lippincott Williams & Wilkins. She is also part of an expert panel at Abt Associates and is under contract with Neuropharm, Curemark, Seaside, Otsuka Research, Bristol Myers Squibb and GlaxoSmithKline as a site investigator for industry-sponsored trials in autism, Fragile X and schizophrenia. Dr. Lieberman has received grant or research funding from Allon, Forest Labs, Merck, Pfizer, AstraZeneca, Bristol-Myers Squibb, GlaxoSmithKline, Janssen and Wyeth. He has served as a consultant for Cephalon, Eli Lilly and Pfizer and as an advisor for Bioline, GlaxoSmithKline, Intracellular Therapies, Eli Lilly, Pierre Fabre, PsychogGenics, Wyeth, Astra Zeneca, Forest Labs, Janssen, Otsuka, and Pfizer. He has been a member of the data safety monitoring board for Solvay. He has not received financial compensation or salary support for his participation in research, consulting or advisory board or data safety monitoring board activities. He holds a patent for the use of secretin in the treatment of autism. None declared for Drs. El-Sayed, Steen, Pie, Bethea and Gerig.

**Contributors:** Drs. El-Sayed, Poe, Sikich and Lieberman designed the study. Drs. El-Sayed, Sikich and Lieberman acquired and analyzed the data, which Drs. Steen, Poe, Bethea and Gerig also analyzed. Drs. El-Sayed, Steen, Poe, Bethea and Sikich wrote the article, which Drs. Steen, Poe, Bethea, Gerig and Lieberman reviewed. All authors approved the final version submitted for publication.

## References

1. Steen RG, Mull C, McClure R, et al. Brain volume in first-episode schizophrenia: systematic review and meta-analysis of magnetic resonance imaging studies. *Br J Psychiatry* 2006;188:510-8.

2. Zipparo L, Whitford TJ, Redoblado Hodge MA, et al. Investigating the neuropsychological and neuroanatomical changes that occur over the first 2–3 years of illness in patients with first-episode schizophrenia. *Prog Neuropsychopharmacol Biol Psychiatry* 2008;32:531-8.
3. Honea RA, Meyer-Lindenberg A, Hobbs KB, et al. Is gray matter volume an intermediate phenotype for schizophrenia? A voxel-based morphometry study of patients with schizophrenia and their healthy siblings. *Biol Psychiatry* 2008;63:465-74.
4. Rapoport JL, Giedd JN, Blumenthal J, et al. Progressive cortical change during adolescence in childhood-onset schizophrenia: a longitudinal magnetic resonance imaging study. *Arch Gen Psychiatry* 1999;56:649-54.
5. Arango C, Moreno C, Martinez S, et al. Longitudinal brain changes in early-onset psychosis. *Schizophr Bull* 2008;34:341-53.
6. Gogtay N. Cortical brain development in schizophrenia: insights from neuroimaging studies in childhood-onset schizophrenia. *Schizophr Bull* 2008;34:30-6.
7. Greenstein D, Lerch J, Shaw P, et al. Childhood onset schizophrenia: cortical brain abnormalities as young adults. *J Child Psychol Psychiatry* 2006;47:1003-12.
8. Sporn AL, Greenstein DK, Gogtay N, et al. Progressive brain volume loss during adolescence in childhood-onset schizophrenia. *Am J Psychiatry* 2003;160:2181-9.
9. Thompson PM, Vidal C, Giedd JN, et al. Mapping adolescent brain change reveals dynamic wave of accelerated gray matter loss in very early-onset schizophrenia. *Proc Natl Acad Sci U S A* 2001;98:11650-5.
10. Vidal CN, Rapoport JL, Hayashi KM, et al. Dynamically spreading frontal and cingulate deficits mapped in adolescents with schizophrenia. *Arch Gen Psychiatry* 2006;63:25-34.
11. Kyriakopoulos M, Frangou S. Pathophysiology of early onset schizophrenia. *Int Rev Psychiatry* 2007;19:315-24.
12. Rapoport JL, Addington AM, Frangou S, et al. The neurodevelopmental model of schizophrenia: update 2005. *Mol Psychiatry* 2005;10:434-49.
13. Walsh T, McClellan J, McCarthy S, et al. Rare structural variants disrupt multiple genes in neurodevelopmental pathways in schizophrenia. *Science* 2008;320:539-43.
14. James AC, James S, Smith DM, et al. Cerebellar, prefrontal cortex, and thalamic volumes over two time points in adolescent-onset schizophrenia. *Am J Psychiatry* 2004;161:1023-9.
15. James ACD, Javaloyes A, James S, et al. Evidence for non-progressive changes in adolescent-onset schizophrenia: follow-up magnetic resonance imaging study. *Br J Psychiatry* 2002;180:339-44.
16. Moreno D, Burdalo M, Reig S, et al. Structural neuroimaging in adolescents with a first psychotic episode. *J Am Acad Child Adolesc Psychiatry* 2005;44:1151-7.
17. Kasai K, Shenton ME, Salisbury DF, et al. Differences and similarities in insular and temporal pole MRI gray matter volume abnormalities in first-episode schizophrenia and affective psychosis. *Arch Gen Psychiatry* 2003;60:1069-77.
18. Koo M-S, Levitt JJ, Salisbury DF, et al. A cross-sectional and longitudinal magnetic resonance imaging study of cingulate gyrus gray matter volume abnormalities in first-episode schizophrenia and first-episode affective psychosis. *Arch Gen Psychiatry* 2008;65:746-60.
19. Coryell W, Nopoulos P, Drevets W, et al. Subgenual prefrontal cortex volumes in major depressive disorder and schizophrenia:

- diagnostic specificity and prognostic implications. *Am J Psychiatry* 2005;162:1706-12.
20. Kasai K, Shenton ME, Salisbury DF, et al. Progressive decrease of left superior temporal gyrus gray matter volume in patients with first-episode schizophrenia. *Am J Psychiatry* 2003;160:156-64.
  21. Kasai K, Shenton ME, Salisbury DF, et al. Progressive decrease of left Heschl gyrus and planum temporale gray matter volume in first-episode schizophrenia: a longitudinal magnetic resonance imaging study. *Arch Gen Psychiatry* 2003;60:766-75.
  22. McDonald C, Bullmore E, Sham P, et al. Regional volume deviations of brain structure in schizophrenia and psychotic bipolar disorder: computational morphometry study. *Br J Psychiatry* 2005;186:369-77.
  23. Nakamura M, Salisbury D, Hirayasu Y, et al. Neocortical gray matter volume in first-episode schizophrenia and first-episode affective psychosis: a cross-sectional and longitudinal MRI study. *Biol Psychiatry* 2007;62:773-83.
  24. Salokangas RK, Cannon T, Van Erp T, et al. Structural magnetic resonance imaging in patients with first-episode schizophrenia, psychotic and severe non-psychotic depression and healthy controls. Results of the schizophrenia and affective psychoses (SAP) project. *Br J Psychiatry Suppl* 2002;43:s58-65.
  25. Zipursky RB, Seeman MV, Bury A, et al. Deficits in gray matter volume are present in schizophrenia but not bipolar disorder. *Schizophr Res* 1997;26:85-92.
  26. Overall JE, Pfefferbaum B. The Brief Psychiatric Rating Scale for Children. *Psychopharmacol Bull* 1982;18:10-6.
  27. Chambers WJ, Puig-Antich J, Hirsch M, et al. The assessment of affective disorders in children and adolescents by semistructured interview. Test-retest reliability of the schedule for affective disorders and schizophrenia for school-age children, present episode version. *Arch Gen Psychiatry* 1985;42:696-702.
  28. First M, Gibbon M, Spitzer R, et al. *Structured clinical interview for DSM-IV axis I disorders (SCID-I), clinician version*. Washington (DC): American Psychiatric Press, Inc.; 1997.
  29. Van Leemput K, Maes F, Vandermeulen D, et al. Automated model-based tissue classification of MR images of the brain. *IEEE Trans Med Imaging* 1999;18:897-908.
  30. Lieberman JA, Tollefson GD, Charles C, et al.; HGDH Study Group. Antipsychotic drug effects on brain morphology in first-episode psychosis. *Arch Gen Psychiatry* 2005;62:361-70.
  31. Courchesne E, Chisum HJ, Townsend J, et al. Normal brain development and aging: quantitative analysis at in vivo MR imaging in healthy volunteers. *Radiology* 2000;216:672-82.
  32. Littell RC, Henry PR, Ammerman CB. Statistical analysis of repeated measures data using SAS procedures. *J Anim Sci* 1998;76:1216-31.
  33. Hinkley D. Discussion of paper by H. Li & G.S. Maddala. *J Econom* 1997;80:319-23.
  34. Janssen J, Reig S, Parellada M, et al. Regional gray matter volume deficits in adolescents with first-episode psychosis. *J Am Acad Child Adolesc Psychiatry* 2008;47:1311-20.

PRISTIQ is indicated for the symptomatic relief of major depressive disorder. The short-term efficacy of PRISTIQ (desvenlafaxine succinate extended-release tablets) has been demonstrated in placebo-controlled trials of up to 8 weeks.

The most commonly observed adverse events associated with the use of PRISTIQ (at an incidence  $\geq 5\%$  and at least twice the rate of placebo) were nausea (22%), dizziness (13%), hyperhidrosis (10%), constipation (9%), and decreased appetite (5%).

PRISTIQ is not indicated for use in children under the age of 18. PRISTIQ is contraindicated in patients taking monoamine oxidase inhibitors (MAOIs, including linezolid, an antibiotic) or in patients who have taken MAOIs within the preceding 14 days due to risk of serious, sometimes fatal, drug interactions with selective serotonin reuptake inhibitor (SSRI) or serotonin norepinephrine reuptake inhibitor (SNRI) treatment or with other serotonergic drugs. These interactions have been associated with symptoms that include tremor, myoclonus, diaphoresis, nausea, vomiting, flushing, dizziness, hyperthermia with features resembling neuroleptic malignant syndrome, seizures, rigidity, autonomic instability with possible rapid fluctuations of vital signs, and mental status changes that include extreme agitation progressing to delirium and coma. Based on the half-life of desvenlafaxine succinate, at least 7 days should be allowed after stopping desvenlafaxine succinate and before starting an MAOI.

PRISTIQ is contraindicated in patients demonstrating hypersensitivity to desvenlafaxine succinate extended-release, venlafaxine hydrochloride or to any excipients in the desvenlafaxine formulation. Concomitant use of PRISTIQ with products containing venlafaxine is not recommended.

Recent analyses of placebo-controlled clinical trial safety databases from selective serotonin reuptake inhibitors (SSRIs) and other newer antidepressants suggest that use of these drugs in patients under the age of 18 may be associated with behavioural and emotional changes, including an increased risk of suicide ideation and behaviour over that of placebo.

The small denominators in the clinical trial database, as well as the variability in placebo rates, preclude reliable conclusions on the relative safety profiles among the drugs in the class. There are clinical trial and post-marketing reports with SSRIs and other newer antidepressants, in both pediatric and adults, of severe agitation-type events that include: akathisia, agitation, disinhibition, emotional lability, hostility, aggression and depersonalization. In some cases, the events occurred within several weeks of starting treatment.

Rigorous clinical monitoring for suicide ideation or other indicators of potential for suicide behaviour is advised in patients of all ages, especially when initiating therapy or during any change in dose or dosage regimen. This includes monitoring for agitation-type emotional and behavioural changes.

Patients currently taking PRISTIQ should NOT be discontinued abruptly, due to risk of discontinuation symptoms. At the time that a medical decision is made to discontinue an SSRI or other newer antidepressant drug, a gradual reduction in the dose, rather than an abrupt cessation is recommended.

Reference: 1. Wyeth Canada. PRISTIQ Product Monograph, August 2009. Product Monograph available upon request.



PRISTIQ®  
© Wyeth, owner,  
now a part of Pfizer Inc.

## Wyeth

© 2010 Wyeth Canada  
Montreal, Canada H4R 1J6

Count on

**Pristiq**  
desvenlafaxine succinate

for powerful symptom relief