

# Percutaneous removal of a knotted pulmonary artery catheter using a tracheostomy dilator

Marja Jagers op Akkerhuis, Constantijn G Bauland and Ad J Voets

## Statement of findings

This case report describes removal of a knotted, subclavian, pulmonary artery catheter using a tracheostomy dilator. With this simple method an invasive procedure might be averted.

Address: Department of Intensive Care, Atrium Medisch Centrum, P.O. Box 4446, 6401 CX Heerlen, The Netherlands

Correspondence: Marja Jagers op Akkerhuis, Department of Surgery, Academisch Ziekenhuis Maastricht, P.O. Box 5800, 6202 AZ Maastricht, The Netherlands. Tel: +31 43 3876543, page 4256

**Keywords:** knotting, pulmonary artery catheter, tracheostomy dilator

Received: 24 April 1999

Revisions requested: 13 July 1999

Revisions received: 21 July 1999

Accepted: 28 July 1999

Published: 16 September 1999

*Crit Care* 1999, **3**:(awaiting print pagination)

The original version of this paper is the electronic version which can be seen on the Internet (<http://ccforum.com>). The electronic version may contain additional information to that appearing in the paper version.

© Current Science Ltd

Print ISSN 1364-8535 Online ISSN 1466-609X

## Introduction

Pulmonary artery catheterization is a well established technique in the management of the critically ill. This technique is not entirely without complications, however. Serious complications occur in only 3–4.4% [1,2], and include pneumothorax, haemothorax, pulmonary artery rupture, valve damage, dysrhythmias and rarely knotting of the catheter. In case of a knotted catheter, its subsequent withdrawal may lead to damage of the tricuspid valve, or rupture of the papillary muscle or vessel wall [3]. In the present case, a subclavian Swan Ganz (pulmonary artery) catheter, after formation of a knot, became firmly stuck between the clavicle and the second rib, and its subsequent method of removal is described.

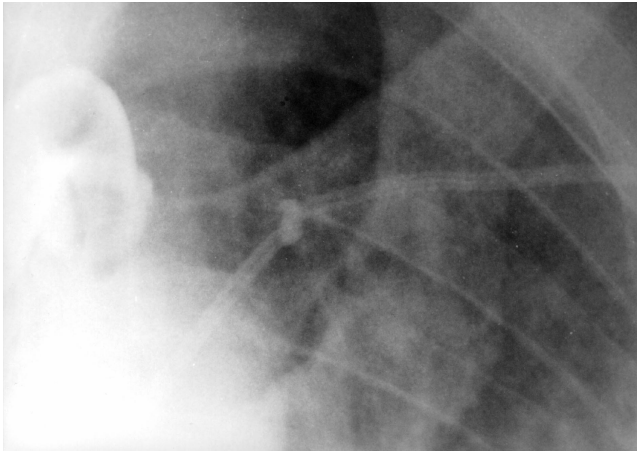
## Case report

A 69-year-old male with a history of silicosis was admitted to our hospital with a splenic abscess, for which computed tomography-guided percutaneous drainage was performed. Subsequently, he developed septic shock and respiratory failure, necessitating mechanical ventilation. A pulmonary artery catheter was uneventfully introduced via the right subclavian vein to manage fluid resuscitation and administration of inotropic agents. Initially, the

patient recovered, and the Swan Ganz catheter was removed after 4 days. The abscess persisted, however, with ensuing haemodynamic instability. A splenectomy was performed, and postoperatively, in yet another uneventful procedure, a new pulmonary artery catheter (Crite Cath Thermodilution, 7F, SP 5107 H) was inserted through the left subclavian vein. Chest radiography showed a knot in the catheter at a distance of 16 cm from the tip, however (Fig 1).

An attempt was made to remove the catheter. On gentle pulling the knot appeared to be firmly stuck between the left clavicle and the second rib, even after careful manipulation of shoulder and arm. Attempts to untie the knot using a guidewire or to tighten the knot using traction at the introducer sheath were unsuccessful. We felt reluctant to pull out the catheter with sheath without reducing the size of the knot, because of the danger of laceration of the subclavian vein. After application of a local anaesthetic and thorough antiseptic treatment of the catheter, the distal end of the catheter was cut off and the flexible introducer sheath was removed. Then a 12F tracheostomy dilator (Cook, Ciaglia percutaneous tracheostomy introducer set, C-PTS-100; William Cook Europe AIS,

**Figure 1**



Chest radiography showing a knot in the pulmonary artery catheter at a position between the clavicle and the second rib.

**Figure 2**



Tracheostomy dilator and pulmonary artery catheter after removal.

Bjaeverskov, Denmark) was inserted over the remaining part of the catheter without encountering any resistance. The catheter was carefully withdrawn until the knot reached the end of the dilator. There the knot was pulled tighter, but could not be retracted into the dilator. The knot had approximately the same circumference as the middle part of the dilator, however, and together they were removed without the occurrence of any further complications (Fig 2).

Haemoglobin levels remained stable, and chest radiography showed no signs of haemothorax. Unfortunately, the patient died 9 days later because of therapy-resistant sepsis.

### Discussion

Knotting of a pulmonary artery catheter is a rare complication, to which several factors may contribute. Dilatation of the right ventricle; the insertion of a pulmonary artery catheter for more than 50 cm without achieving a pulmonary capillary wedge pressure curve; and the introduction of an incompletely inflated balloon all entail a high risk of coiling and subsequent knotting [3,4].

Various different methods for removal of knotted catheters have been reported. One approach is to pull the catheter against the introducer sheath, thereby reducing the size of the knot, followed by removing both catheter and sheath [5]. In catheters inserted via the subclavian route, a potential danger is venous laceration and subsequent haemothorax.

Another method is to attempt to unwire the knot. This may be achieved by inserting a guidewire in the pulmonary

artery catheter itself [6], or through the femoral vein or antecubital vein and manipulate it to untie the knot [7]. Tan *et al* [8] achieved this by introducing a balloon catheter through the femoral vein, pushing it through the knot and inflating it, thereby unwiring it. Alternatively, a Dotter basket can be inserted through the femoral vein to snare the pulmonary artery catheter and remove it in two pieces [9]. Furthermore, surgical removal can be used, either by venous cut down or open surgery (ie thoracotomy).

In the present case attempts to unwire the knot were unsuccessful. Because of the flexibility of the introducer sheath it was not possible to tighten the knot further without the risk of damaging the sheath and thereby inducing venous tearing. We therefore removed the introducer sheath and replaced it with a firm tracheostomy dilator with a diameter close to that of the knot. After that the knot could be tightened further and the catheter effortlessly removed. This procedure is similar to that used by Dach *et al* [10] with a biliary stent catheter. Although there still remains a chance of venous laceration and subsequent haemothorax, we believe this procedure reduces the risk of bleeding of the subclavian vein.

The preferred technique to remove a knotted Swan Ganz catheter is to untie the knot, but in some cases this can not be achieved. In those cases, removal of a tightened knot resting behind an unflexible sheath or tracheostomy dilator with a comparable diameter could be a simple, elegant and noninvasive solution.

## References

1. Colbert S, O'Hanlon DM, Quill DS, Keane P: **Swan Ganz catheter-all in a knot.** *Eur J Anaesthesiology* 1997, **14**:518–520.
2. Boyd KD, Thomas SJ, Gold J, Boyd AD: **A prospective study of complications of pulmonary artery cathetrization in 500 consecutive patients.** *Chest* 1983, **84**:245–249.
3. Kranz A, Mundigler G, Bankier A, *et al*: **Knotting of two central venous catheters: a rare complication of pulmonary artery catheterization.** *Wien Klin Wochenschr* 1996, **18**:404–406.
4. Fibuch EE, Tuohy GF: **Intracardiac knotting of a flow-directed balloon-tipped catheter.** *Anesth Analg* 1980, **59**:217–219.
5. Castellá M, Rimbau V, Palacin J, Font C, Mulet J: **True knot in a Swan Ganz catheter on a central venous catheter: a simple trick for percutaneous removal.** *Intens Care Med* 1996, **22**:830–831.
6. Böttiger BW, Schmidt H, Böhler H, Martin E: **Mistakes and dangers: non-surgical removal of a knotted Swan-Ganz-Catheter [in German].** *Anaesthesist* 1991, **40**:682–686.
7. Agarwal NN, Giesswein P, Leverett L, Gracey J, Hess D: **An unusual case of pulmonary artery catheter knotting during withdrawal.** *Crit Care Med* 1989, **17**:1081–1082.
8. Tan C, Bristow PJ, Segal P, Bell RJ: **A technique to remove knotted pulmonary artery catheters.** *Anaesth Intens Care* 1997, **25**:160–162.
9. Bellamy CM, Ramsdale DR: **Removal of a knotted Swan-Ganz balloon catheter using a Dotter basket.** *Postgrad Med J* 1988, **64**:475–476.
10. Dach JL, Galbut DL, LePage JR: **The knotted Swan-Ganz catheter: new solution to a vexing problem.** *Am J Roentgenol* 1981, **137**:1274–1275.