

Primary research

Balloon laryngoscopy reduces head extension and blade leverage in patients with potential cervical spine injury

Spyros D Mentzelopoulos, Marina V Tsitsika, Marina P Balanika, Maria J Joufi and Evangelia A Karamichali

Evangelismos General Hospital, Athens, Greece

Received: 6 May 1999
Revisions requested: 19 July 1999
Revisions received: 6 October 1999
Accepted: 29 October 1999
Published: 24 January 2000

Crit Care 2000, 4:40–44

© Current Science Ltd

Abstract

Background: Head extension and excessive laryngoscope blade levering motion (LBLM) are undesirable during airway management of trauma patients. We hypothesized that laryngoscopy with a modified blade facilitating glottic exposure by balloon inflation would reduce head extension and LBLM.

Patients and methods: Seventeen elective surgery patients were enrolled. Patients lay supine with their heads flat on a rigid board and had a rigid collar around their necks. Laryngoscopy was performed with the modified blade and a standard curved blade. Head extension and LBLM angles were determined upon maximal glottic exposure and compared using paired *t*-tests. Laryngoscopic view grade and oxygen saturation were also determined.

Results: Balloon laryngoscopy resulted in less head extension and LBLM ($P < 0.001$). Laryngoscopic view was approximately identical with both blades, and oxygen saturation was always above 97%.

Conclusions: Balloon laryngoscopy reduces head extension and LBLM under simulated cervical spine precautions.


Keywords: balloon laryngoscopy, blade, extension, head, leverage, spine

Introduction

Cervical spine stabilization manoeuvres are employed during conventional airway management of trauma patients to avoid secondary neurological deficits [1–5]. A degree of potentially hazardous head extension may still be necessary for laryngeal visualization, however [1]. Head and neck stabilization may prevent the alignment of mouth and glottis [1]. Poor laryngeal visualization is frequently associated with excessive laryngoscope blade levering motion (LBLM) and subsequent risk of upper teeth or gum trauma [6].

In the present study, we performed laryngoscopy with a no. 4 standard and a no. 4 modified curved blade in elective surgery patients under simulated cervical spine precautions. The modified blade carries two no. 10 Foley catheters (Fig. 1) and is a partial development of a new laryngoscope (international patent document no. 98/19589) [7]. The standard balloon laryngoscopy technique includes modified blade tip insertion into the vallecula, right catheter balloon inflation with 2 ml air (Fig. 1) and blade elevation to achieve the best laryngeal view [8]. In patients with anterior larynx, the lifting of the epiglottis is facilitated by establishing

Figure 1



Modified Macintosh Blade with right catheter balloon inflated with 2 ml air and automatic angle finder. MR, angle finder's metallic ruler; VA, angle finder's vertical arm.

adequate contact between the inflated balloon's upper surface and the tongue base and hyoid bone [8].

We hypothesized that balloon laryngoscopy might result in less head extension and LBLM, because balloon inflation and subsequent blade elevation should facilitate laryngeal exposure and reduce the extent of the necessary laryngoscopic manoeuvres.

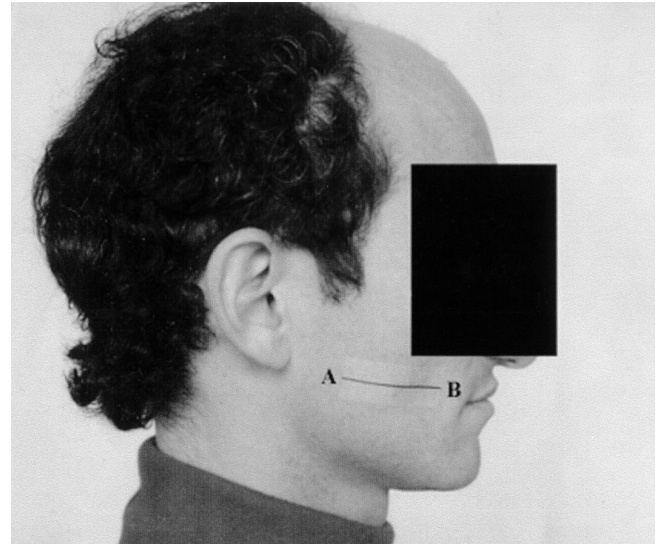We determined the head extension and LBLM needed for maximal glottic exposure with both blades, the laryngoscopic view grade during each laryngoscopy and oxygen saturation. The present results showed significant reduction in the head extension and LBLM angles during balloon laryngoscopy.

Patients and methods

Ethics committee approval and informed, written patient consent were obtained. The enrollees were adult males, classified as American Society of Anesthesiologists physical status I, and were scheduled for elective surgery that required general anaesthesia with endotracheal intubation. Exclusion criteria were a history of cervical spine pathology, any condition predisposing to pulmonary aspiration and previous difficult intubation [4]. All patients had Mallampati class I oropharyngeal views [9], head extension was greater than 35° [10], thyromental distance was greater than 6.5 cm [10], sternomental distance was greater than 13.5 cm [11], maximal incisal opening was greater than 4 cm [12] and body mass index was less than 27.5 kg/m² [13].

The operating table was kept parallel to the operating room floor (defined as horizontal plane) as follows: an automatic angle finder (serial no 295; Fisher Instruments, Kent, UK), detached from its metallic ruler (Fig. 1), was sequentially

Figure 2



An adhesive tape is placed on the right cheek of an assistant. The tape's median longitudinal axis (AB) is parallel to the occlusal surface of the maxillary molars.

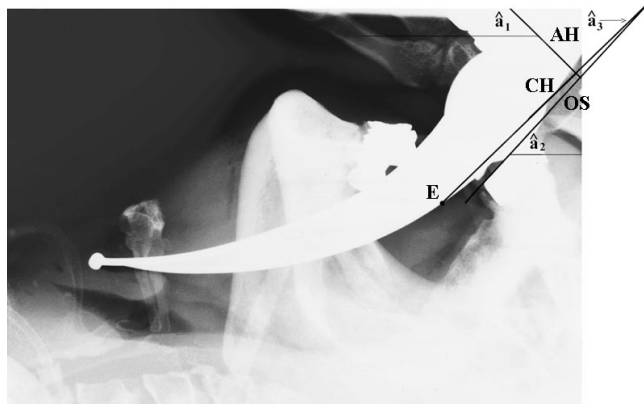
placed on the right-long and cephalad-short sides of the table's metallic frame; and each time the table's inclination was adjusted until the angle finder read 0°.

Patients lay supine with their heads flat on the operating table. Before induction of anaesthesia, a piece of adhesive tape (1.2 × 5 cm) was placed on the right patient cheek with its median longitudinal axis parallel to the occlusal surface of the maxillary molars (or gums; Fig. 2). Standard monitoring (including pulse oximetry) was used.

After 5 min preoxygenation with 100% oxygen, anaesthesia was induced with fentanyl (2 µg/kg) and propofol (2.5 mg/kg). After the disappearance of the eyelid reflex, a rigid board was placed under each patients' shoulders and occiput [5], and a rigid Philadelphia collar was fitted around their necks. Airway instrumentation was facilitated with intravenous succinylcholine (1.5 mg/kg). After the disappearance of the fasciculations in the face, the patient head was placed in the neutral position by aligning the occlusal surface of the maxillary molars' perpendicular to the operating table as follows: the angle finder's 'vertical arm' (Fig. 1) was placed on the longitudinal axis of the adhesive tape (Fig. 2), and the head was manipulated until the angle finder read 0°. Subsequently, laryngoscopy was performed with both standard and modified blades in randomized order. In between laryngoscopies, neutral head position was resumed.

Balloon laryngoscopy technique consisted of modified blade tip insertion into the vallecula, right catheter balloon

Figure 3



Lateral neck radiograph during conventional direct laryngoscopy (informed and written patient consent were obtained). The angle of head extension is defined as $90^\circ - \hat{a}_2$. \hat{a}_1 , angle between AH and horizontal plane; \hat{a}_2 , angle between occlusal surface of maxillary molars and horizontal plane; \hat{a}_3 , angle of laryngoscope blade levering motion; AH, axis of handle; CH, chord corresponding to the radian formed by the proximal third of the laryngoscope blade convex surface; E, distal end point of said radian; OS, axis of occlusal surface of maxillary molars or gums.

inflation with 2ml air, and blade elevation until maximal glottic exposure was achieved. The angles of the laryngoscope handle and the maxillary molars' occlusal surface relative to horizontal (Fig. 3; angles \hat{a}_1 and \hat{a}_2 , respectively) were measured with the angle finder upon maximal glottic exposure with each blade. To measure the angle of the handle relative to horizontal, the angle finder's metallic ruler was placed on the median longitudinal axis of the handle's posterior aspect. All patients were intubated during the second laryngoscopy immediately after measurements were taken.

Airway instrumentation was performed by a senior anesthesiologist (MPB), who had a prior experience of more than 200 balloon laryngoscopies. The measured angles, the best laryngoscopic view during each laryngoscopy and oxygen saturation throughout the study were recorded. The laryngoscopic view was graded with the use of a modified grading scale (Table 1) proposed by SDM and MJJ.

The difference $'90^\circ - \hat{a}_2'$ was defined as head extension angle, and the difference $'\hat{a}_1 - \hat{a}_2'$ was defined as the LBLM angle. The LBLM angle (Fig. 3; angle \hat{a}_3) is formed between the occlusal surface axis of the maxillary molars or gums (Fig. 3; line OS) and a chord (Fig. 3; line CH) that is perpendicular to the axis of the handle (Fig. 3; line AH) and corresponds to the radian formed by the proximal one-third of the convex surface of the blade. This chord passes through the distal end point of the radian (Fig. 3; point E).

Table 1

The modified Cormack–Lehane grading scale used to evaluate the laryngoscopic findings obtained in the present study

Laryngoscopic view	Grade
The anterior commissure of glottis is visible	I
More than 50% of glottis is visible; the anterior commissure of glottis is not visible	II _a
Less than 50% of glottis is visible, including its posterior commissure and the arytenoid cartilages	II _b
Only the arytenoid cartilages and the epiglottis are visible	III _a
Only the epiglottis is visible	III _b
Only the retropharyngeal wall is visible	IV

The maximal acceptable laryngoscopy duration and time between the two laryngoscopies were 30s, and the maximal allowable study procedure duration was 180s. Procedure timing began upon succinylcholine administration.

Data from patients with laryngeal views differing by two or more consecutive grades between the two laryngoscopies (eg grade I and grade II_b) were excluded from the subsequent statistical analysis (see Discussion). The head extension and LBLM angles with each laryngoscope blade were calculated and compared with the paired *t*-test. $P < 0.05$ was considered statistically significant.

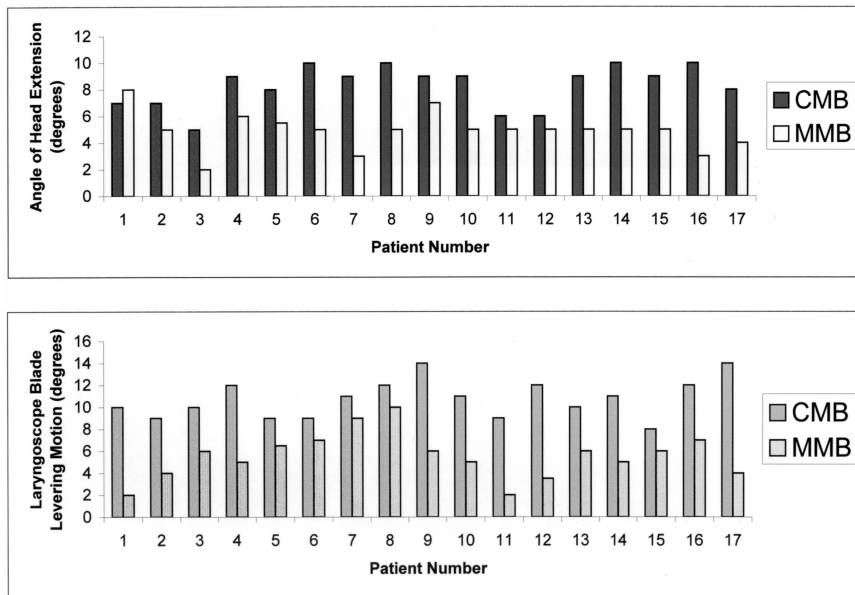
Results

Seventeen adult male patients were studied, and no patients were excluded from the analysis because of differences in the laryngoscopic view grade. Mean patient age and body mass index were 28.1 years (range 22–39 years) and 23.3 kg/m² (range 20.5–26.8 kg/m²), respectively. In all patients, the laryngoscopic view grades were virtually identical and grade II_a or less with both blades, the study procedure lasted less than 120s, and oxygen saturation remained greater than 97%. The values of the head extension and LBLM angles (Fig. 4) were normally distributed. According to the present data (Fig. 4 and Table 2), balloon laryngoscopy resulted in significantly reduced head extension ($P < 0.001$) and LBLM ($P < 0.001$).

Discussion

In the current investigation, we determined the potentially beneficial effects of the use of a curved blade modified to improve laryngeal visualization by balloon inflation on the cervical spine motion and LBLM under simulated cervical spine precautions. The present data showed a 40–50% reduction in the head extension and LBLM angles with balloon laryngoscopy (Table 2). This might be due to reduced need to manoeuvre the modified blade while exposing the glottis.

Figure 4



Patient-by-patient values of the determined head extension and laryngoscope blade levering motion angles. CMB, conventional Macintosh blade; MMB, modified Macintosh blade.

Table 2

Values of the head extension and laryngoscope blade levering motion angles during conventional and balloon laryngoscopy

	Conventional Macintosh blade	Modified Macintosh blade	<i>P</i>
Angle of head extension	8.29 ± 1.57	4.91 ± 1.42	< 0.001
Angle of laryngoscope blade levering motion	10.76 ± 1.75	5.53 ± 2.13	< 0.001

Values are expressed as mean ± standard deviation in degrees. *P* values were obtained by using the paired *t*-test.

The estimated incidence of difficult laryngoscopy [grade III_b or less (Table 1)] in general surgery patients is approximately 1% [14]. The use of neutral head position along with cervical spine stabilization manoeuvres has resulted in an incidence of 4.3–16.6% [2,15]. The 0% incidence in the current study may be due to the combined use of multiple difficult airway predictors during patient selection, and the relatively small patient number (*n*=17). Additionally, the maintenance of oxygen saturation above 97% throughout the study procedure was to be expected, because the safe duration of apnea tolerance in non-obese, American Society of Anesthesiologists physical status I patients exceeds 4 min [16].

It seemed sensible to compare head extension and LBLM angles only if laryngeal exposure was maximal and approximately identical during both laryngoscopies in all patients. Maximal values would then be achieved in both angles. If in some patients the larynx were partly (or not at all) exposed, the head extension would probably be less than if the full view were obtained [2]. Consequently, the head extension angles would be falsely underestimated during

the laryngoscopy with the least glottic exposure [2]. The risk of this bias would increase in patients with predicted difficult laryngoscopy. In such patients, conventional laryngoscopy might result in lesser laryngeal exposure than is achieved with balloon laryngoscopy [8]. Furthermore, the increased difficulty in laryngeal visualization might result in excessive LBLM [6] and subsequent overestimation of the 'conventional' LBLM angles. Thus, we studied patients with 'easy' airways in order to maximize the probability of obtaining satisfactory (grade II_b or greater, Table 1) and similar laryngoscopic views with both blades.

External head extension angles during laryngoscopy with different blades and with or without cervical spine stabilization have been measured in two previous studies [2,3]. In the study by Hastings and Wood [2], the head extension angles for best laryngeal view during conventional laryngoscopy under manual head immobilization (mean ± standard deviation 9 ± 6°) were similar to ours (Table 2). The smaller coefficient of variation (defined as standard deviation/mean value) of the present results (0.19 versus 0.67 [2]) may be due to the following: all laryngoscopies

were performed by one experienced operator, whereas in the previous study [2] 62 laryngoscopies were performed by 16 operators; and the use of a hard collar for cervical spine stabilization, which has eliminated the potential variability in angle measurements caused by differences in the force applied by different assistants performing head immobilization [2].

Head extension is the major external movement that occurs during airway management [2]. Also, the externally measured head extension angle during laryngoscopy has been correlated with the angle formed between the occiput and the fourth cervical vertebra ($r^2=0.7$) [3]. The maximum allowable head extension during airway management of trauma victims and the actual risk of neurological deterioration associated with conventional airway management techniques applied in cervical spine-injured patients still remain to be determined, however.

In the current study, we also determined the LBLM, which has not been previously determined under simulated cervical spine precautions. LBLM was defined by SDM and MJJ as the backward motion of the blade's convex surface toward the maxilla. Its range was estimated by measuring the angle between the occlusal surface axis of the maxillary molars and the chord of the radian formed by the proximal one-third of the blade (Fig. 3). This chord is the best straight-line approximation to the geometrical shape of the proximal one-third of the blade's convex surface. This portion of the no. 4 blade is most frequently in close proximity with the upper teeth of adult males during laryngoscopy, and may traumatize them if excessive LBLM is employed. Upper incisor trauma and/or dislodgment may then result in aspiration of tooth fragments into the trachea.

In our opinion, the potential risks of spinal cord injury and of maxillary teeth dislodgement during laryngoscopy performed in trauma patients under cervical spine precautions should not be underestimated (especially in the presence of unstable cervical spine injuries and/or maxillary trauma), despite the fact that they have not yet been accurately determined.

In summary, we demonstrated that the head extension and LBLM angles are significantly reduced when balloon laryngoscopy is performed under simulated cervical spine precautions in carefully preselected and adequately anaesthetized and paralyzed elective surgery patients. Such 'ideal' conditions may not be achievable in the emergency setting, however. Thus, further investigation is required to prove the usefulness of balloon laryngoscopy in the emergency airway management of cervical spine-injured patients.

References

- Hastings RH, Marks JD: **Airway management for trauma patients with potential cervical spine injuries.** *Anesth Analg* 1991, **73**: 471-482.
- Hastings RH, Wood PR: **Head extension and laryngeal view during laryngoscopy with cervical spine stabilization maneuvers.** *Anesthesiology* 1994, **80**:825-831.
- Hastings RH, Vigil CA, Hanna R, Yang BY, Sartoris DJ: **Cervical spine movement during laryngoscopy with the Bullard, Macintosh, and Miller laryngoscopes.** *Anesthesiology* 1995, **82**:859-869.
- Watts ADJ, Gelb AW, Bach DB, Pelz DM: **Comparison of the Bullard and Macintosh laryngoscopes for endotracheal intubation of patients with a potential cervical spine injury.** *Anesthesiology* 1997, **87**:1335-1342.
- Majernick T, Bieniek R, Houston J, Hughes H: **Cervical spine movement during orotracheal intubation.** *Ann Emerg Med* 1986, **15**: 417-420.
- McCoy EP, Mirachur RK: **The levering laryngoscope.** *Anaesthesia* 1993, **48**:516-519.
- Mentzelopoulos SD, Ballas CJ: **Laryngoscope with a flexible blade, inflatable balloons, two thin double lumen tubes, and one thin single lumen tube.** International patent document No. 98/19589; International Application No. PCT/GR97/00038 published under the Patent Cooperation Treaty.
- Mentzelopoulos SD, Tsitsika MV, Karamichali EA: **Difficult airway management with balloon inflation.** *Anesth Analg* 1999, **88**:1425-1426.
- Mallampati SR, Gatt SP, Gugino LD, *et al*: **A clinical sign to predict difficult tracheal intubation: a prospective study.** *Can J Anaesth* 1985, **32**:429-434.
- Benumof JL: **Management of the difficult adult airway: with special emphasis on awake tracheal intubation.** *Anesthesiology* 1991, **75**: 1087-1110.
- Ramadhani SAL, Mohamed LA, Rocke DA, Gows E: **Sternomental distance as the sole predictor of difficult laryngoscopy in obstetric anaesthesia.** *Br J Anaesth* 1996, **77**:312-316.
- Sheppard IM, Sheppard FM: **Maximal incisal opening: a diagnostic index.** *J Dent Med* 1965, **20**:13-15.
- Morgan GE, Mikhail MS: **Anesthesia for patients with endocrine disease.** In: *Clinical Anesthesiology*, 2nd ed. Edited by Reinhardt S, Langan C. New Jersey: Appleton and Lange, 1996:645-646.
- El-Ganzouri RA, McCarthy JR, Tuman JK, Tanck NE, Ivankovich DA: **Preoperative airway assessment: predictive value of a multivariate risk index.** *Anesth Analg* 1996, **82**:1197-1204.
- Suderman VS, Crosby ET, Lui A: **Elective oral tracheal intubation in cervical spine-injured adults.** *Can J Anaesth* 1991, **38**:785-789.
- Jense HG, Dubin SA, Silverstein PI: **Effect of obesity on safe duration of apnea in anesthetized humans.** *Anesth Analg* 1991, **72**: 89-93.

Authors' affiliation: Department of Anesthesiology, Evangelismos General Hospital, Athens, Greece

Correspondence: Spyros D Mentzelopoulos, MD, 2A Kypseli Str, GR-11362, Athens, Greece. Tel: +30 1 8213641; fax: +30 1 3218493