

CaJEM PEARLS

This is our first installment of a series intended to provide clinical tips for the ED practitioner. We welcome your submissions for this series via email: rrodriguez@hghed.com

Combining the Modified Allen's Test and Pulse Oximetry for Evaluating Ulnar Collateral Circulation to the Hand for Radial Artery Catheterization of the ED Patient

Benjamin Z.S. Paul, MD, PhD*
Colin M. Feeney, MD, FACP#

*Department of Anesthesia, University of California, San Francisco

San Francisco, CA

#Department of Medicine, Alameda County Medical Center

Oakland, CA

Correspondence:

Colin M. Feeney, MD, FACP
Department of Medicine
Highland General Hospital
Alameda County Medical Center
1411 E. 31st St.
Oakland, CA 94602

There was no financial support or any financial interest of any of the authors in the subject matter or materials discussed in this article.

Radial artery catheterization for the purpose of continuous blood pressure monitoring and frequent blood gas sampling is regularly performed in the emergency department (ED) and in the intensive care unit (ICU). In the operating room, anesthesiologists generally have the benefit of a conscious and cooperative patient, and the modified Allen's test can be performed before catheterization of the radial artery to assure adequate collateral circulation. In contrast, patients in the ED and ICU are frequently unable to follow com-

mands due to sedation or to a significantly altered level of consciousness. Under such circumstances the modified Allen's test cannot be accurately performed and the radial artery is often catheterized without assessing the collateral circulation of the hand. ED and ICU patients are frequently hypotensive and are often being treated with vasoconstricting medication. Furthermore, many of these patients have peripheral vascular disease. Under these circumstances cannulation of the radial artery may carry a greater risk for causing limb ischemia. We discuss how pulse oximetry may be used to perform the modified Allen's test in these patients to evaluate collateral circulation and potentially reduce the risk of iatrogenic hand injury.

The Allen's test was first described in 1929 to evaluate the arterial blood supply of the hand in patients with thromboangiitis obliterans.^{1,2} In this test, complete arterial occlusion was accomplished by compressing the radial arteries of both hands simultaneously, while the patient clenched both fists tightly for one minute. Wright modified this test in 1952 to examine the adequacy of the collateral blood supply through the ulnar artery before cannulation of the radial artery.³ In this modified test, the clinician compresses both the ulnar and radial arteries of the hand, while the patient repeatedly clenches the hand into a fist, causing the hand to blanch. The test is considered normal if the palm reddens less than ten seconds after release of pressure over the ulnar artery.

To use pulse oximetry in evaluation of hand collateral circulation, begin by placing the pulse oximetry probe on the patient's index finger. Next, the ulnar and radial arteries are compressed. The loss of the pulse oximeter waveform and oxygen saturation reading indicates that compression is adequate. Subsequent return of a pulse and oxygen saturation reading following the release of the ulnar artery indicates a positive test, i.e., adequate ulnar collateral circulation (see Figure 1). Our experience has shown that this combination of pulse oximetry and the modified Allen's test produces a reliable and an unambiguous result. Usually, however, the pulse oximetry waveform resulting from release of the ulnar artery has a smaller amplitude than that of the initial pulse oximetry wave-

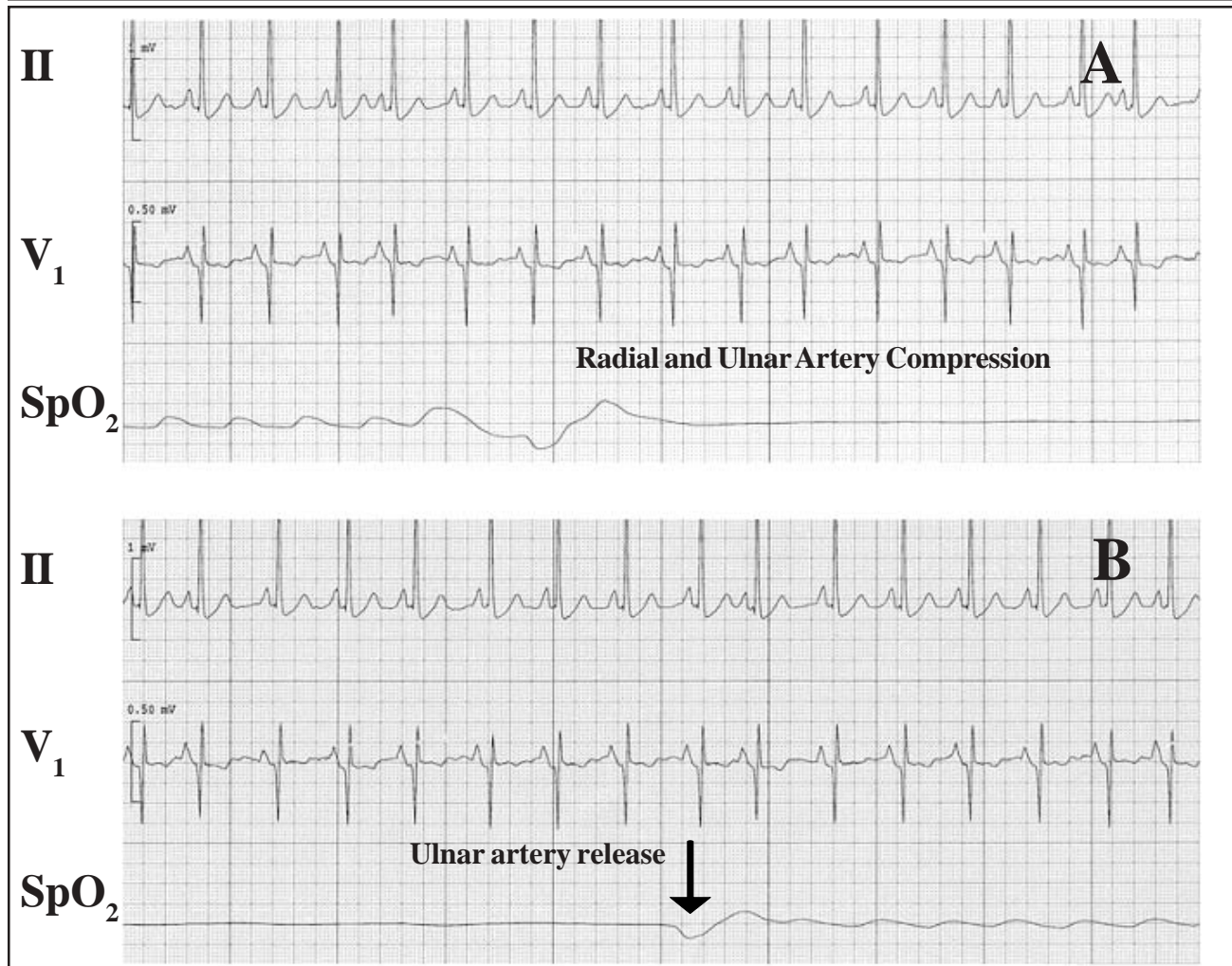


Figure 1: Plethysmographic tracings from pulse oximeter during modified Allen's test. (A) Disappearance of the plethysmographic tracing (labeled SpO₂) from the pulse oximeter with compression of both the radial and ulnar arteries. The labeled arrow indicates initiation of compression. Electrocardiograph tracing from leads II and V1 are shown as indicated. (B) Release of the radial artery is indicated by the labeled arrow. The return of the plethysmographic tracing indicates adequate ulnar collateral circulation.

form. We have noted that the oximetry wave amplitude varies according to choice of finger placement of the pulse oximeter probe—the amplitude is greater the closer the probe is placed to the patent arterial source.

The modified Allen's test, Doppler ultrasound, pulse oximetry, and digit blood pressure have all been used to assess the adequacy of collateral hand circulation.⁴⁻⁸ Although only the laser Doppler provides a quantitative measurement of blood flow, all of these methods provide some information about collateral circulation. In a study of 1000 healthy patients without peripheral vascular disease assessed using the modified Allen's test, 49% were clearly normal (< 5 sec),

24% were intermediately normal (5-9 sec), and 27% were abnormal (≥ 10 sec); these results imply that it would be safer to cannulate another artery besides the tested radial artery in over a quarter of healthy patients.⁹ However, the clinical significance of an abnormal modified Allen's test is unclear. It has been reported that vascular insufficiency caused by radial artery catheterization is a very rare occurrence.¹⁰ A recent angiographic study of ICU patients with indwelling radial artery catheters for more than four days revealed that over half of the patients had either a partial thrombosis (57%) or a complete thrombosis of the radial artery (19%), but all of the thromboses were clinically asymptomatic with no signs of ischemia.¹⁰

While some studies have also shown that catheterization of radial arteries in patients with an abnormal modified Allen's test (> 15 sec) did not lead to limb ischemia or produce any negative consequences, the applicability of these results to ED and ICU populations is questionable.¹¹⁻¹³ Most of the aforementioned investigations were performed in healthy individuals undergoing surgical procedures.¹¹⁻¹³ The study populations excluded patients with diabetes, peripheral vascular disease, or severe cardiopulmonary compromise, in contrast to typical ED and ICU populations. A study of 4932 ICU patients found the most common complication of arterial catheterization to be vascular insufficiency, occurring in 3.4% of medical ICU patients, and 4.6% of surgical ICU patients.¹³ Many patients in the ED and ICU are at risk for complications secondary to hypoperfusion. Although no ED or ICU studies have been performed proving the utility of the combined pulse oximetry modified Allen's test, we believe that a normal test adds helpful information regarding the adequacy of collateral hand circulation. This test should be considered in unconscious or uncooperative ED and ICU patients requiring radial artery catheterization.

of hand circulation before radial artery harvest for coronary artery bypass grafting. *J Thorac Cardiovasc Surg* 1999;117:261.

8. Fuhrman TM, McSweeney E. Noninvasive evaluation of the collateral circulation to the hand. *Acad Emerg Med* 1995;2:195.

9. Benit E, Vranckx P, Jaspers L, Jackmaert R, Poelmans C, Coninx R. Frequency of a positive modified Allen's test in 1,000 consecutive patients undergoing cardiac catheterization. *Cathet Cardiovasc Diagn* 1996;38:352.

10. Martin C, Saux P, Papazian L, Gouin F. Long-term arterial cannulation in ICU patients using the radial artery or dorsalis pedis artery. *Chest* 2001;119:901.

11. Slogoff S, Keats AS, Arlund C. On the safety of radial artery cannulation. *Anesthesiology* 1983;59:42.

12. Sellden H, Nilsson K, Larsson LE, Ekstrom-Jodal B. Radial arterial catheters in children and neonates: a prospective study. *Crit Care Med* 1987;15:1106.

13. Frezza EE, Mezghebe H. Indications and complications of arterial catheter use in surgical or medical ICUs: analysis of 4932 patients. *Am Surg* 1998;64:127.

REFERENCES

1. Cable DG, Mullany CJ, Schaff HV. The Allen test. *Ann Thorac Surg* 1999;67:876.
2. Allen EV. Thromboangiitis obliterans: methods of diagnosis of chronic occlusive arterial lesions distal to the wrist with illustrative cases. *Am J Med Sci* 1929;2:1.
3. Fuhrman TM, Pippin WD, Talmage LA, Reilley TE. Evaluation of collateral circulation of the hand. *J Clin Monit* 1992;8:28.
4. Jarvis MA, Jarvis CL, Jones PR, Spyt TJ. Reliability of Allen's test in selection of patients for radial artery harvest. *Ann Thorac Surg* 2000;70:1362.
5. Pola P, Serricchio M, Flore R, Manasse E, Favuzzi A, Possati GF. Safe removal of the radial artery for myocardial revascularization: a Doppler study to prevent ischemic complications to the hand. *J Thorac Cardiovasc Surg* 1996;112:737.
6. Ruengsakulrach P, Brooks M, Hare DL, Gordon I, Buxton BF. Preoperative assessment of hand circulation by means of Doppler ultrasonography and the modified Allen test. *J Thorac Cardiovasc Surg* 2001;121:526.
7. Starnes SL, Wolk SW, Lampman RM, Shanley CJ, Prager RL, Kong BK, Fowler JJ, Page JM, Babcock SL, Lange LA, Erlandson EE, Whitehouse WM Jr. Noninvasive evaluation