

EXPERIMENTAL THROMBO-ATHEROSCLEROSIS *

By MEYER FRIEDMAN AND SANFORD O. BYERS

(From The Harold Brunn Institute, Mount Zion Hospital and Medical Center,
San Francisco, Calif.)

(Submitted for publication December 27, 1960; accepted March 3, 1961)

Thrombosis long has been known as an often occurring sequent of coronary atherosclerosis, but until quite recently, very few investigators seriously considered that thrombosis of itself incited atherosclerosis. This possibility, initially proposed by von Rokitansky (1), was apparently refuted by Virchow (2) and this seeming refutation, together with the discovery by Anitschkow (3) of the atheroma-inducing propensities of a diet rich in cholesterol, discouraged further consideration of atherosclerosis as of thrombogenic origin.

However, Duguid (4-6) has revived the thrombogenic etiology of atherosclerosis. He stressed the detection of fibrin in typical coronary and aortic atherosclerotic plaques as a probable sequent of an earlier thrombosis. He called attention to the presence of fibrous-lined lamellae in plaques, which suggested to him that the pathogenetic process might be intermittent rather than chronically progressive. He believed that he could observe evolutionary stages in the transformation and organization of mural thrombi into lipid-rich atherosclerotic plaques. Finally he emphasized, as other pathologists also have done (2, 7-10), that the lipid deposit in the human atherosclerotic plaque (see Figure 1, A) is usually deeply situated, whereas it is superficially accumulated in the atherosclerotic plaque observed in the rabbit continuously fed cholesterol. It is important to point out, however, that if the hypercholesterolemic-atherosclerotic rabbit is allowed to return to its usual normocholesterolemic level, eventually the lipid in its plaque also may become deeply embedded (11).

The observations of Duguid have been confirmed by some pathologists (12-15) but his conclusions have not been accepted either by all

* Aided by grants from the National Institutes of Health, the Life Insurance Medical Research Fund, the American Heart Association, the San Francisco Heart Association, the Sacramento Heart Association and the Contra Costa County Heart Association.

pathologists (7, 9) or by the majority of those investigators who have oriented their thoughts and actions to disturbances in lipid dynamics (either within the arterial wall or in the blood stream). These latter particularly have continued to be profoundly influenced by the ease with which experimentally induced hypercholesterolemia leads to atherosclerosis and have generally discounted the fact that the site of deposition of lipid in the atherosclerotic animal continuously receiving cholesterol is quite different from that usually observed in human coronary atherosclerosis (compare A and H in Figure 1).

Obviously, as McLetchie (9) observed, there is need to evaluate Duguid's contention by experimental means. In short, beginning with a thrombus arising *in situ*, can the morphological facsimile of human coronary atherosclerosis be reproduced?

Recently we have been able to induce thrombus formation in the arterial system by either the introduction of a specially treated magnesium alloy coil (16) or polyethylene tubing (17). It therefore appeared important to us to study the evolution of such thrombi in both normocholesterolemic and hypercholesterolemic rabbits. The results obtained indicated that the production of a thrombus invariably led to the formation of a cellular plaque. In the presence of hypercholesterolemic plasma this experimental plaque accumulated lipid in sites which simulated exactly the distribution of lipid observed in the human atherosclerotic plaque.

METHODS

Both acute and chronic experiments were done. In the acute experimental study, 10 hypercholesterolemic rabbits that had been given a Wayne rabbit chow diet with added cholesterol (2 per cent) and cottonseed oil (2 per cent) for 3 months had a 1.5 cm long magnesium alloy coil inserted into the abdominal aorta below the site of exit of the renal arteries; 8 similar rabbits received a 0.5 inch hemicylindrical segment cut from polyethylene tubing (ID 0.045, OD 0.062 inch) in the same portion

of their aortas. The method of preparation and insertion of both the coil (16) and polyethylene segment (17) have been described previously. For control purposes, 8 normocholesterolemic rabbits received the coil and 8, the tubing; 72 hours later, after blood serum samples were obtained, the animals were sacrificed and the thrombi removed. The serum samples and the total thrombi, or plaques, were analyzed for cholesterol by appropriate methods (18). Previous to analysis, the polyethylene was removed from its associated thrombus, or plaque. The wire could not be similarly removed since

there remained only a residuum of fragmented metallic salts. The thrombi produced by the coil method also were analyzed for triglyceride content (19). In addition, sections of each thrombus were stained with Mallory's phosphotungstic acid hematoxylin stain (PTAH) and Sudan IV.

Several types of chronic studies were done. The first study used 68 rabbits in whose aorta a magnesium alloy coil was inserted; 32 of these rabbits also were placed on a cholesterol (2 per cent) cottonseed oil (2 per cent) enriched diet, and the remaining 36 animals (serv-

FIG. 1

A. LOW-POWER VIEW OF A SECTION OF ANTERIOR DESCENDING BRANCH OF THE LEFT CORONARY ARTERY OF A 57 YEAR OLD MAN WHO HAD DIED OF AN ACUTE CORONARY THROMBOSIS OF THE CIRCUMFLEX BRANCH OF THE SAME ARTERY (SUDAN IV STAIN IN ALL COLOR SLIDES). This is the typical histological picture of a moderately diseased coronary artery and is presented for purposes of comparison with the succeeding slides. Note the eccentric position of the plaque, the deeply situated lipid separated by fibrous-like tissue free of stainable lipid, both from the lumen and from the partially thinned and fragmented media. The essential dissimilarity of this histological structure with that found in the spontaneously developing atherosclerosis of the cholesterol-oil fed rabbit can be seen by comparing this illustration with H.

B. RABBIT MW-4: LOW-POWER VIEW OF THE THROMBOTIC PROCESS IN A CHOLESTEROL-OIL FED RABBIT 21 DAYS AFTER INTRA-AORTIC COIL INSERTION. The cellular envelopment and penetration of the original thrombus and the fragmentation of the subjacent media are clearly visible. Sudanophilia of the basal lateral areas and the subjacent medial remnants also is depicted. Note the absence of sudanophilia in the more peripheral portions of the enveloping and penetrating newly formed tissue. Fragments of metallic salts also are shown.

C. RABBIT MG 22-3: ANOTHER LOW-POWER VIEW OF THE THROMBOTIC PROCESS IN A CHOLESTEROL-OIL FED RABBIT 21 DAYS AFTER INTRA-AORTIC COIL INSERTION. Here the sudanophilia in the basal central area of the newly developing tissue just adjacent to the media is clearly shown. Note the partial disorganization and sudanophilia of the media underlying the thrombotic process and their absence in those portions of the media not in juxtaposition with the process. In this section large masses of metallic salts persist despite penetration of hyperplastic intimal tissue which also contains some extracellular pools of lipid.

D. RABBIT RR-25: LOW-POWER VIEW OF PLAQUE, 84 DAYS AFTER INSERTION OF COIL IN A CHOLESTEROL-OIL FED RABBIT. The sudanophilia deeply situated in the basal and lateral areas of the plaque is clearly shown. Fragmentation and sudanophilic infiltration of the media subjacent to the plaque also can be seen. Some metallic salts still remain in the plaque. The freedom from atherosclerotic involvement of the more distant portions of the aorta was a usual finding. The essential similar-

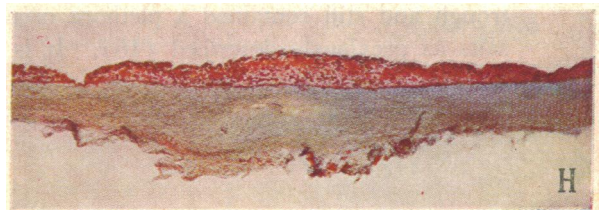
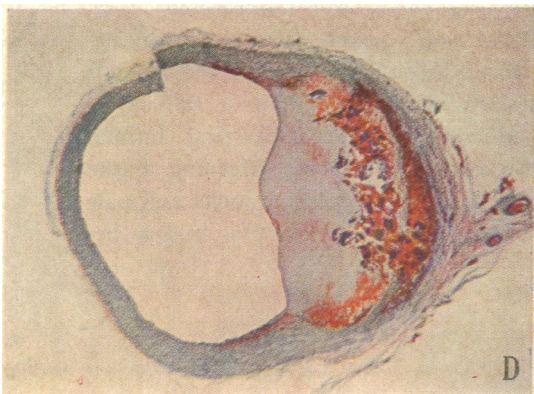
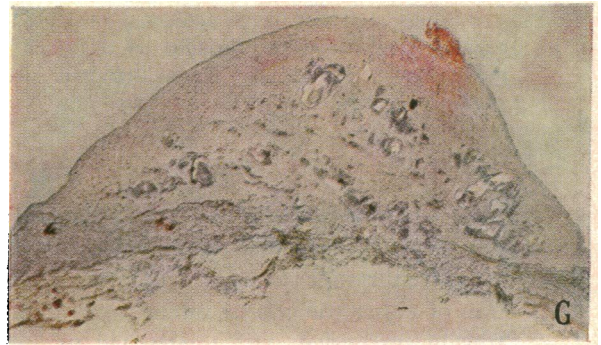
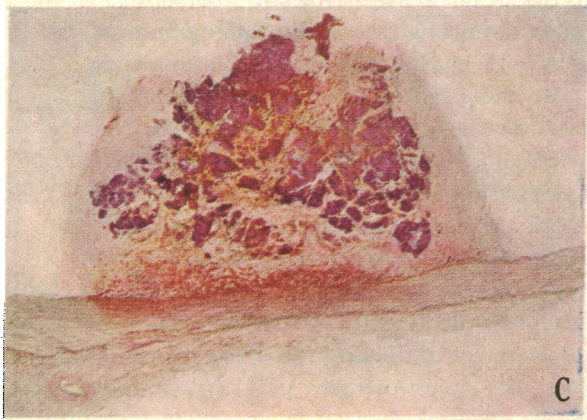
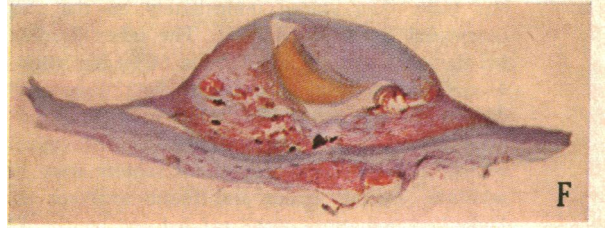
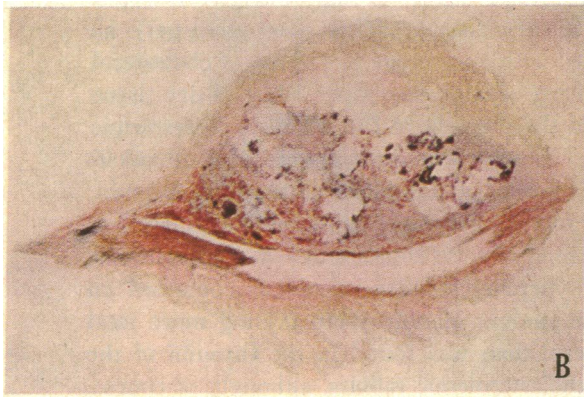
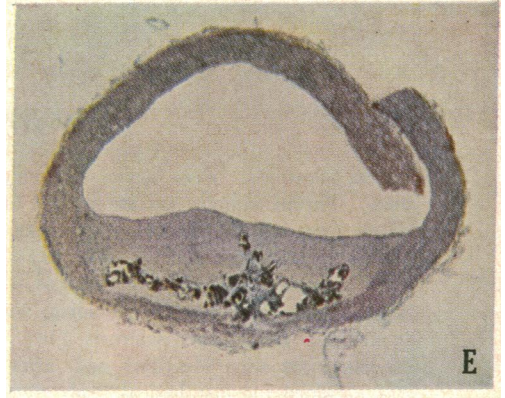
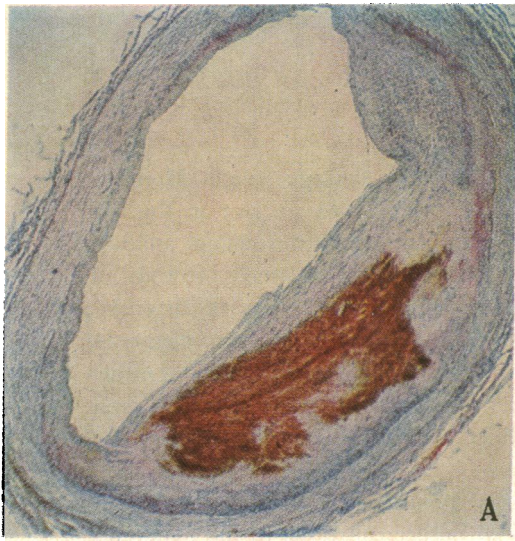
ity of this plaque to that found in the human coronary artery and its dissimilarity to the atherosclerotic process developing spontaneously in the cholesterol-oil fed rabbit can be seen by comparing the above photograph with A and H, respectively.

E. RABBIT RR-32: LOW-POWER VIEW OF PLAQUE, 84 DAYS AFTER INSERTION OF COIL IN A CONTROL RABBIT FED THE STOCK DIET. Here dense fibrous tissue containing residual metallic salts at its base has completely replaced the original thrombus. Note the complete absence of sudanophilia. In other respects, however, its structural characteristics are similar to those of plaque shown in D.

F. RABBIT R3-12: LOW-POWER VIEW OF PLAQUE, 84 DAYS AFTER INSERTION OF HEMICYLINDRICAL SEGMENT OF POLYETHYLENE TUBING IN A CHOLESTEROL-OIL FED RABBIT. The cleft in the center of the plaque was the area occupied by the tubing whose trough and its contained thrombus had faced the lumen. A portion of this thrombus, staining a brownish color and encircled by a thin rim of new intimal tissue, can still be seen in the cleft area. Note the absence of sudanophilia in this thrombus remnant and its dense accumulation in the basal central and lateral areas of the hyperplastic intima. Actually, the wall of the tubing itself elicited the total intimal reaction, since it had isolated the thrombus in its trough from the intimal surface of the aorta. Nevertheless, this plaque, and also that shown in D, bears a strong likeness in its essential structural details to the human plaque depicted in A.

G. RABBIT Z-3 NO. 10: LOW-POWER VIEW OF PLAQUE, 168 DAYS AFTER INSERTION OF COIL IN A RABBIT FED CHOLESTEROL-OIL DIET DURING THE LAST HALF OF THE PERIOD. This dense, relatively acellular plaque with only the slightest peripheral tint of sudanophilia resembles the 84-day old plaque of the stock-fed rabbit shown in E despite the cholesterol and oil feeding. The fragmentation of the media is well shown.

H. RABBIT Z-3 NO. 10: LOW-POWER VIEW OF THE SPONTANEOUSLY DEVELOPED ATHEROSCLEROSIS IN THE ARCH OF THE AORTA OF THE SAME RABBIT WHOSE THROMBUS-INDUCED PLAQUE IS ILLUSTRATED IN G. The superficial site of lipid deposition in the hyperplastic intima contrasts strongly with the sites of lipid accumulation shown in the human plaque A and in the thrombus-induced plaque of the rabbit fed cholesterol-oil concomitantly with intra-aortic coil or tubing insertion (D and F).



ing as controls) were given ordinary Purina rabbit chow. Serum samples for cholesterol analyses were obtained from all rabbits every 3 weeks, excepting those rabbits sacrificed at 7, 14 and 21 days; from these animals a single terminal serum sample was obtained. At time of sacrifice, the entire aorta was inspected and graded for gross atherosclerosis (18). The thrombotic remnant was then identified and, after a small section was obtained for histological study, the total process including the new intimal overgrowth (when this had occurred) was removed and analyzed for its cholesterol content. In addition, for control purposes a 5 cm section of abdominal aorta directly cephalad to the thrombotic process was removed and also analyzed for its cholesterol content. This chronic study continued for 84 days.

The second study used 20 rabbits. Polyethylene tubing was inserted into each abdominal aorta; 11 of the rabbits were then placed immediately on the cholesterol-cottonseed oil enriched diet. The other 9 rabbits were fed the stock diet. Eight rabbits (4 on the stock diet and 4 on the cholesterol-oil enriched diet) were sacrificed 21 days, and the remaining 12 rabbits were sacrificed 84 days, after insertion of tubing. Gross and histological studies of the thrombotic process of all rabbits were done. In addition, similar serum and tissue analyses and histological examinations were carried out on the 12 rabbits allowed to live for 84 days after the insertion of tubing.

The third study used 26 rabbits; all of these also received the magnesium alloy coil, but they were at first given the stock diet. Twenty-one days after the coil had been inserted, 8 of these rabbits were placed on the cholesterol-cottonseed oil enriched diet and continued thereon for an additional 84 days; another 14 were at first given the stock diet for 84 days after the coil had been inserted and then placed on the cholesterol-cottonseed oil enriched diet for an additional 84 days. The remaining 4 rabbits were continued on the stock diet for the entire 168 day period. The analytic and histological studies were also done on these rabbits.

RESULTS

A. Characteristics of the newly formed thrombus in the normal and hypercholesterolemic rabbit. The thrombi removed 3 days after the insertion of either the coil or tubing were found to be freshly suspended—still unattached to the intima of the aorta (16) in both the normo- and hypercholesterolemic rabbits. It was thus obvious that material arising from the blood stream itself was under study.

Both types of induced thrombi appeared pinkish white. Those produced by the coil were considerably larger than those formed in the tubing trough and still contained a plethora of metallic salts as previously described (16). It is of in-

terest, however, that the average weight of either type of thrombus was not any greater in the hyper- than in the normocholesterolemic animals (Table I). Upon histological study, strands of fibrin were observed in both types of thrombi; both were relatively devoid of cellular elements, but rich in platelets. None of the thrombi of either type in either the normo- or hypercholesterolemic animals exhibited a positive staining reaction for lipid.

The analytical results were of considerable interest. The coil-induced thrombi in the hypercholesterolemic rabbits contained an average of 840 mg of cholesterol and 657 mg of triglyceride per 100 g of dry tissue (dried over silica-gel) as compared with an average of 418 mg of cholesterol and 464 mg of triglyceride per 100 g of dry tissue found in the thrombi of the normocholesterolemic rabbits. When these figures were used to calculate the amount of cholesterol in the total thrombi, it was found that these thrombi contained less than 0.2 mg of total cholesterol. Moreover, those in the hypercholesterolemic animals contained an absolute amount of only about 0.1 mg more total cholesterol than was found in the thrombi of the normocholesterolemic rabbits, although, of course, the *percentage* of cholesterol was greater in thrombi from hypercholesterolemic rabbits.

The cholesterol analyses of the tubing-induced thrombi in both normo- and hypercholesterolemic rabbits also indicated that a minimal amount of cholesterol was deposited in the early thrombus. Thus (Table I), although the average cholesterol content of the thrombi in the hypercholesterolemic rabbits was greater than that in the normocholesterolemic rabbits, neither type of rabbit had thrombi that contained more than 0.04 mg of total cholesterol, and the average difference in the total cholesterol content of the thrombi of the two series of rabbits was approximately 0.01 mg—a most insignificant quantity.

B. The chronic changes occurring in thrombi in rabbits fed excess cholesterol immediately after insertion of the coil. Seven days after coil insertion, the aortic thrombus was observed in both the hypercholesterolemic and control rabbits to be lightly adherent to the underlying intima. Upon histological study, newly invading tissue composed of cells containing large nuclei and pale cytoplasm coming directly from the intima be-

TABLE I

The effect of immediate cholesterol-oil feeding upon cholesterol content of coil- and tubing-induced thrombi and plaques

Rabbits	Av. wt	Coil or tubing inserted	Av. serum cholesterol	Aorta air-dried cholesterol	Thrombotic process		Av. ratio TP/A cholesterol*	
					Av. wt (dry)	Cholesterol		
no.	g	no. days	mg %	mg/100 g	mg	mg/100 g		
I. Rabbits fed cholesterol-oil diet immediately after insertion of coil								
Series†	10	2,930	3	644† (208-1,383) ±101.0	1,095 (820-1,400) ±42.0	25 (17-33) ±3.2	840 (575-1,148) ±48	0.77
Range: SE of mean								
Series A	3	3,020	7	115‡ (41-226)	735 (578-844)	35 (29-40)	939 (850-988)	1.28
B	3	2,960	14	221‡ (86-313)	871 (804-962)	25 (20-33)	1,432 (1,170-1,680)	1.65
C	4	3,032	21	348‡ (178-612)	1,206 (748-1,660)	16 (12-20)	2,774 (1,690-3,820)	2.30
D	8	3,104	42	311§ (118-804) ±69.0	832 (613-1,030) ±49.0	17 (11-22) ±1.4	4,359 (1,965-8,230) ±740	5.25
E	14	3,438	84	724§ (630-948) ±66.0	1,063 (730-1,480) ±87.0	13 (9-24) ±1.3	6,240 (2,520-12,560) ±890.0	5.85
II. Rabbits fed stock diet after insertion of coil								
Series O	8	2,398	3	54 (42-78) ±2.4	508 (501-604) ±35.0	29 (15-40) ±3.1	418 (329-500) ±180	0.83
Series A	3	3,125	7	33‡ (27-36)	631 (518-768)	25 (14-33)	693 (629-757)	1.10
B	3	2,860	14	25‡ (15-36)	654 (565-707)	24 (19-28)	960 (854-1,100)	1.47
C	6	2,980	21	39‡ (22-42) ±3.1	730 (520-710) ±62.0	14 (8-24) ±3.3	1,274 (468-1,810) ±188.0	1.74
D	24	3,438	84	51§ (30-71) ±1.4	532 (294-973) ±116.0	8 (8-9) ±0.3	1,016 (459-2,095) ±83.0	1.90
III. Rabbits fed cholesterol-oil diet immediately after insertion of tubing								
Series O †	8	2,978	3	320† (108-435) ±40.0	1,090 (788-1,262) ±195.0	1.9 (0.8-6.5) ±0.9	1,898 (562-2,790) ±294.0	1.73
Series A	7	3,482	84	1,506§ (1,091-2,180) ±62.0	1,974 (778-5,550) ±89.0	5.1 (1.4-7.7) ±0.8	17,189 (4,250-29,100) ±3,700.0	8.77
IV. Rabbits fed stock diet after insertion of tubing								
Series O	8	2,864	3	70 (37-102) ±4.8	770 (619-892) ±49.0	1.5 (0.4-4.0) ±0.35	1,508 (620-2,750) ±208	1.96
Series A	5	3,346	84	35§ (27-45) ±2.6	437 (418-474) ±32	1.8 (0.8-3.0) ±0.37	1,991 (1,305-2,980) ±212	4.55

* TP/A cholesterol ratio equals $\frac{\text{cholesterol concentration of thrombotic process}}{\text{cholesterol concentration of adjacent aortic segment}}$

† These rabbits were hypercholesterolemic at time of coil or tubing insertion, having been fed the cholesterol-oil enriched diet for the preceding 3 months. The cholesterol values given represent average of 3 monthly values.

‡ Represents serum cholesterol value on day of sacrifice.

§ Represents average of all serum cholesterol values obtained every 3 weeks.

neath the central basal portion of the thrombus was observed in the three normocholesterolemic and the three already slightly hypercholesterolemic animals. A few capillaries could be detected accompanying these cells. The media beneath this area of hyperplasia appeared somewhat altered in that the elastic lamellae were distorted and frequently fragmented. No evidence of acute inflammation was observed. Finally, despite the moderate elevation of the serum cholesterol in the three rabbits ingesting the cholesterol-oil enriched diet, (Table I) no evidence of sudanophilia was observed in any of the specimens.

Cholesterol analyses of the aortic segment and the thrombotic process (Table I) suggested that a greater amount of cholesterol was present in the thrombotic masses of the hypercholesterolemic rabbits, but the ratio of the cholesterol content of the thrombotic process to that of the adjacent aorta (TP/A cholesterol ratio) was approximately the same (Table I) in both groups of animals.

Thrombi observed 14 days after their insertion into three normocholesterolemic and three hypercholesterolemic rabbits exhibited a more tenacious adherence to the vessel wall. Extension of the hyperplastic intimal tissue up along the sides of the thrombi could be detected grossly.

Upon histological study it could be seen that the intimal new growth had invaded the central basal area of the thrombus even farther and had ascended along its sides. At this time, very small amounts of lipid were first observed but only in the specimens obtained from the three rabbits fed the cholesterol-oil enriched diet; moreover, this lipid was confined chiefly to the *basal areas* of the newly formed tissue either beneath the thrombus or ascending the latter's sides. This lipid was apparently both intra- and extracellular, but no true foam cells were seen. The media lying beneath the thrombus showed even more disorganization.

The average cholesterol content of the three thrombotic processes was considerably greater in the hyper- than in the normocholesterolemic rabbits (Table I). The TP/A cholesterol ratio in both groups of rabbits also had increased.

All of the aortic thrombi of the 10 rabbits sacrificed 21 days after insertion of the coil now were covered by newly formed intimal tissue (Figure

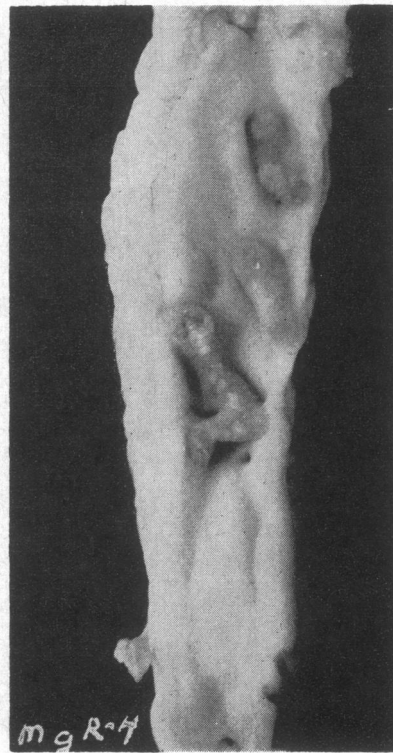


FIG. 2. RABBIT Mg R-4: TYPICAL APPEARANCE OF THE THROMBOTIC PROCESS 21 DAYS AFTER INSERTION OF COIL INTO THE AORTA. Although three segments are seen, they actually formed a continuous spiral mass prior to incision of the aorta. At this time the original thrombus is entirely covered by newly formed intimal tissue. The white spots observed in the lowest mass are residual remnants of metallic salts lying just beneath the newly formed tissue envelope.

2). Such thrombi both in the normal and hypercholesterolemic rabbits were still grayish-white in color, but they could be stripped from the aorta only with difficulty. At this time, the average weight of the thrombotic process was approximately the same in the two groups of rabbits. Spontaneous atherosclerosis involving any area of the aorta was not observed grossly in the hypercholesterolemic rabbits.

There was a very marked difference in the histological appearance of the thrombotic processes of the two groups of rabbits. Although all thrombi (still containing large amounts of metallic salts) now were covered completely as well as invaded by newly formed intimal cells, only the thrombotic processes of the hypercholesterolemic rabbits showed well marked deposits of lipid. This lipid, chiefly *extracellular*, was still found in those por-

tions of newly formed intimal tissue at the base and along the lower sides of the original thrombus and also in the inner third of the now completely disorganized media immediately subjacent to the original thrombus (Figure 1, B and C). It was thus apparent that the major portion of the excess lipid seen either arose *in situ* or came from an intramural rather than a transintimal source. It was of interest too that no lipid was ever observed at this time in the aortic intima not occupied by the thrombotic area (Figure 1, C).

The average cholesterol content of the total thrombotic process (including of course the basal and lateral intimal hyperplastic tissue) in the hypercholesterolemic rabbits was over twice that found in the same process in the normal rabbits (Table I). Also the TP/A cholesterol ratio had increased to 2.30. The average cholesterol concentration of the thrombotic processes of the normal rabbits had increased also but to a lesser extent (Table I).

Eight cholesterol-oil fed rabbits were sacrificed 42 days after coil insertion. No significant spontaneous atherosclerosis was observed in any portion of the aorta of these eight rabbits. At this time, however, the original site of coil insertion was marked by a serpiginous, pinkish plaque, well covered with intimal tissue, approximately 1.5 cm long (i.e., the same length as the coil that had been inserted) and 3 to 5 mm wide. Along the lateral base of this plaque newly formed blood vessels were quite prominent. Five of these eight plaques when incised showed a central core of yellowish, semiliquified waxy material.

Upon histological examination, the initial thrombus appeared to be almost completely replaced by the intimal tissue that had grown in from the base and along the sides. Already the most peripheral portions of intimal tissue forming the plaque had begun to resemble dense fibrous tissue containing scattered elastic fibers. Only some residual metallic salts remained to indicate that the plaque had been induced by a thrombus. The central core of the plaque, however, in most instances exhibited necrosis. The lipid deposit, which had increased greatly, was almost totally extracellular and accumulated in lake-like masses at the basal areas of the plaque. The more peripheral areas of most plaques appeared relatively free of lipid.

The average cholesterol content of these eight

plaques was 4,359 mg per 100 g of dry tissue. At this time there remained no doubt that the process was accumulating cholesterol far more avidly than was the adjacent aortic segment that had been analyzed (TP/A cholesterol ratio: 5.25).

Fourteen hypercholesterolemic and 24 normal rabbits were sacrificed 84 days after insertion of the coil. Twelve of the 14 hypercholesterolemic rabbits exhibited slight to moderate spontaneous atherosclerosis (grade 1-3) in the arch and thoracic portions of the aorta. Only 4 of these 14 rabbits, however, exhibited any gross spontaneous atherosclerosis in that portion of the abdominal aorta immediately above or below the plaque.

The gross appearance of the plaques in the two groups of animals differed markedly (Figure 3); whereas in the normal rabbits the plaques usually had shrunk to a dense, hard, rather flat, whitish-gray plaque, those of the 14 hypercholesterolemic animals appeared larger, frequently exhibiting a waxy yellowish color. In general too, the aorta adjacent to these latter plaques appeared more distorted. Eight of the 14 plaques in the hypercholesterolemic rabbits exhibited a necrotic core from which yellow, waxy, thick fluid could be expressed. Similar central necrosis of the plaques in the normal rabbits was never observed.

At histological examination, the plaque of the hypercholesterolemic rabbits exhibited a structure that resembled rather markedly that seen in the diseased human coronary artery (Figure 1, D; compare with A). Thus the eccentric position of the thrombo-atherosclerotic plaque, the dense lipid deposit situated quite deep in the plaque, the fibrous cap, and the relative immunity of the aortic intima not subjacent to the process are well illustrated. In two of the plaques small areas of calcification also were observed. These fibrous plaques with deeply accumulated lipid at the base of the plaque and in the subjacent portion of the media were never seen in the spontaneous atherosclerosis occurring in the rabbit during the first few months of cholesterol feeding (see H, Figure 1).

The plaque occurring in the normal rabbits 84 days after coil insertion was composed (see E, Figure 1) almost entirely of dense, fibrous-like tissue interspersed with occasional elastic fibers and containing some residual metallic salts at the base of the plaque. Thinning and distortion of

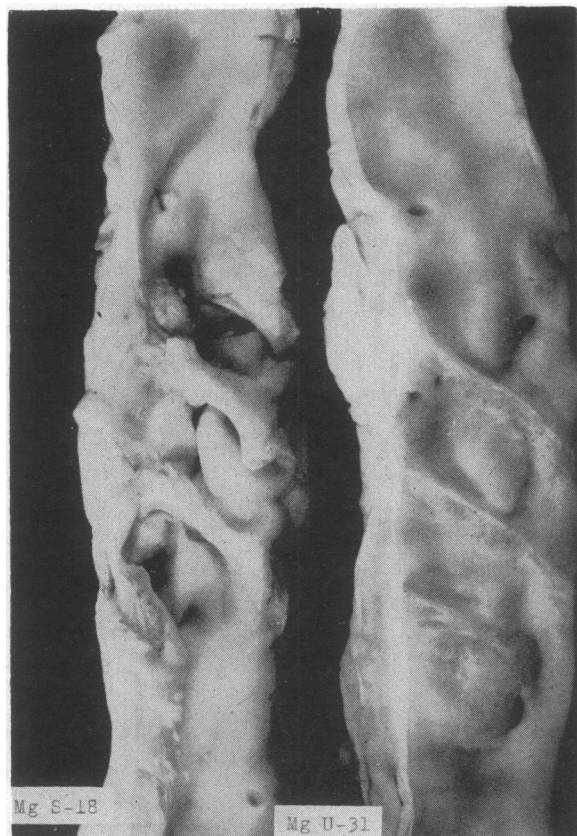


FIG. 3. RABBITS Mg S-18 AND Mg U-31: THE PLAQUES FORMING 84 DAYS AFTER INTRA-AORTIC COIL INSERTION INTO THE CHOLESTEROL-OIL FED RABBIT (Mg S-18) AND INTO THE CONTROL RABBIT FED THE STOCK DIET (Mg U-31). Fully developed plaques have now replaced the initial thrombus mass. The plaque in each animal was actually a spiral continuous process but was cut into three sections on incision of the aorta. Note the greater thickness and the lipid infiltration of the plaque segments of the rabbit fed the cholesterol-oil enriched diet (Mg S-18). Also note the distortion of the aorta adjacent to the plaque. The plaque segments of the control rabbit (Mg U-31) are flatter, thinner and translucent and exhibit pinpoint areas composed of small blood vessels.

the media subjacent to the process almost always was observed.

C. The chronic changes occurring in thrombi in rabbits fed excess cholesterol immediately after insertion of tubing. As previously described (17), the trough of the polyethylene tubing was occupied by a relatively cell-free, fibrin- and platelet-rich thrombus within 72 hours after its insertion. When the aorta of the eight rabbits sacrificed 21 days after introduction of the tubing was opened, no spontaneous atherosclerosis was ob-

served in either the cholesterol-fed or the normal rabbits. The polyethylene tubing in every case enclosed a greyish-white mass which adhered to the intima of the aorta (Figure 4). Close inspection revealed that this mass was covered with intimal tissue growing over it and separating it from the tubing wall. In addition to this, the outer wall of the tubing itself also was partially covered by a bilateral extension of living intimal tissue.

Histological examination of these plaques revealed that, in most of them, the original relatively acellular thrombus was almost completely replaced by intimal tissue invading and encircling the original thrombus in much the same fashion as that observed in the coil-induced thrombi. Again, as in the coil-induced process after 21 days,

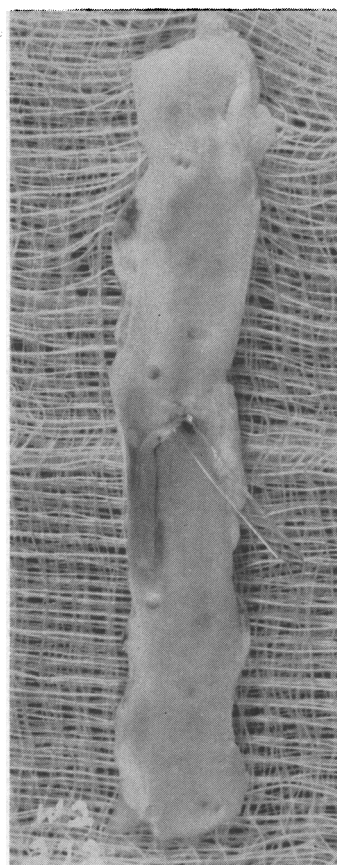


FIG. 4. RABBIT W2-272: THE THROMBOTIC PROCESS 21 DAYS AFTER INSERTION OF A SEGMENT OF POLYETHYLENE TUBING INTO THE AORTA. The polyethylene has been lifted and pulled to the side. The whitish-grey thrombus is attached to the intima from which newly formed tissue has arisen to begin to cover the thrombus and also the outer wall of the tubing.

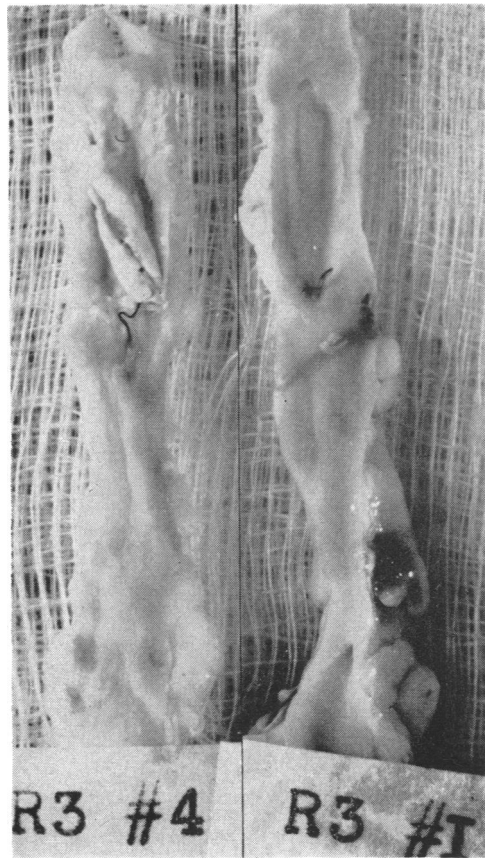


FIG. 5. RABBITS R3-4 AND R3-1: THE PLAQUES FORMING 84 DAYS AFTER INTRA-AORTIC POLYETHYLENE TUBING SEGMENT INSERTION INTO THE CHOLESTEROL-OIL FED RABBIT (R3-4) AND INTO THE CONTROL RABBIT (R3-1) FED THE STOCK DIET. Fully developed plaques covering the tubing (removed prior to photography) and its contained thrombus have now developed. The thick, lipid-infiltrated walls of this plaque in the cholesterol-oil fed rabbit (R3-4) contrast strongly with the poorly visualized, flat, translucent plaque of the control animal (R3-1). The two lateral dark lines running lengthwise represent the space occupied by the walls of the tubing. The new intimal growth had grown within the trough of the tubing and also had ascended the latter's outer walls. The silk stay sutures can still be seen.

the basal portions of the intimal tissue invading and encircling the thrombotic remnants in the cholesterol-fed rabbits exhibited lipid chiefly in extracellular aggregations. Thus, except for the absence of metallic salt fragments, the histological appearance of the plaques arising after tubing insertion was essentially similar to that of the coil-induced plaques.

All of the seven cholesterol-fed rabbits sacrificed

84 days after insertion of the tubing showed extensive confluent atherosclerosis in the arch and thoracic portions of the aorta (grade 3-4), but the abdominal aorta of four of them was free of visible atherosclerosis, and in the remaining three there were only scattered small plaques. In each of these seven rabbits the polyethylene tubing in the aorta was totally covered by a thick, obviously lipid-containing tissue (Figure 5). The trough of two of the tubings was found to face the lumen rather than the wall of the aorta. In strong contrast, the plaques present in the aorta of the control normocholesterolemic rabbits were smaller, flatter, more translucent, and devoid of grossly detectable lipid. The plaques in both groups of rabbits were relatively tough and one had the impression of cutting through scar tissue when transverse incisions were made in either type of plaque. The interior of the plaque in six hypercholesterolemic animals was occupied by the same type of yellowish, waxy, thick fluid observed in some of the coil-induced plaques.

Similar to the histological structure observed in the coil-induced plaques, the tubing-induced plaque in the cholesterol-fed rabbit showed in every case dense, extracellular accumulation of lipid in the basal central and lateral areas (Figure 1, F). Usually the media immediately beneath the plaque was thinned, slightly disorganized, and occasionally infiltrated with lipid situated both intra- and extracellularly. In the aorta of the two animals whose tubing trough had faced the lumen of the aorta, the original clot therein had been invaded by new intimal tissue which, ascending the lateral walls of the tubing, then had dipped into the trough to begin to replace the initial thrombus. This is shown in Figure 1, F, which illustrates several very interesting points. The section shows quite well that the lipid deposition is in the basal intimal tissue that was separated right from the beginning from any contact with the thrombus by the impermeable walls of the polyethylene tubing. This, of course, cogently suggests that the intimal lipid could not have been derived from the original thrombus. Confirming this probability, the residual portion of the thrombus itself showed no lipid. The section also indicates that the hyperplastic intimal tissue reaction, with its rich deposition of chiefly extracellular lipid, has been a response not to the thrombus but

to the wall of the tubing itself. Finally, the section bears a much closer resemblance to the type of atherosclerosis observed in the human coronary artery than does that observed in our rabbit fed excess cholesterol (Figure 1, compare F with A and H).

The plaques of the five control rabbits in general showed the same type of cellular structure observed in the plaques of the cholesterol-oil fed rabbits; however, the total plaque was considerably smaller and completely devoid of sudanophilic material except for one, in which a few sudanophilic droplets were seen in the basal central area. As observed in the experimental animals, the plaques of these control rabbits exhibited what we considered to be fibrous transformation of the initial intimal extension.

The plaques of both the experimental and control rabbits contained far more cholesterol than did the immediately adjacent aorta. Thus (Table I), the average cholesterol content of the control plaques was more than four times that found in their aortas. Even more striking was the finding that the average cholesterol concentration of the plaques of the cholesterol-oil fed rabbits was more than eight times that found in either their own aortas or in the plaques of the control rabbits. This greater concentration of cholesterol in the tubing-induced plaques, as compared with that found in the coil-induced plaques, was probably due not only to the greater degree of hypercholesterolemia achieved in the rabbits bearing the

tubing but also to the absence of metallic fragments.

D. The chronic changes occurring in thrombi of rabbits not fed cholesterol immediately after insertion of the coil. The plaques of the eight rabbits fed the cholesterol-oil diet for 84 days, beginning 21 days after coil insertion, were examined both histologically and chemically. They appeared to present essentially the same cellular structure and about the same amount of sudanophilia both in the basal central and basal lateral portions of the plaque as did plaques from rabbits fed cholesterol-oil immediately. Moreover, their average cholesterol content was as great (Table II) as that found in the 84-day old plaques of the rabbits fed the cholesterol-oil diet immediately after coil insertion.

On the other hand, when the 14 rabbits, fed the cholesterol-oil enriched diet for 84 days beginning 84 days after coil insertion, were sacrificed, a most interesting phenomenon was observed. Twelve of these 14 rabbits exhibited moderate atherosclerosis of the ascending portion of their aortas (grade 1-3) but all of their coil-induced plaques appeared shrunken and grossly devoid of fat deposition and markedly resembled the type of plaque observed in the four control rabbits fed the stock diet over the same period (Figure 6).

Histologically too, only 1 of the 14 hypercholesterolemic rabbits had a coil-induced plaque that contained sudanophilic material. Even in this

TABLE II
The effect of delayed cholesterol-oil feeding upon coil-induced plaques

Rabbits	Av. wt	Coil inserted	Av. serum cholesterol*	Aorta cholesterol	Thrombotic process		Av. ratio TP/A cholesterol
					Av. wt (dry)	Cholesterol	
no.	g	no. days	mg %	mg/100 g	mg	mg/100 g	
I. Rabbits fed cholesterol-oil diet 21 days after coil inserted							
8	2,998	105	876	1,242	14	8,083	6.50
Range			(720-1,035)	(730-1,830)	(8-24)	(3,130-11,700)	
SE of mean			±42.0	±156.0	±1.6	±950.0	
II. Rabbits fed cholesterol-oil diet 84 days after coil inserted							
14	3,553	168	741	1,419	8	2,097	1.47
			(309-1,101)	(510-4,290)	(5-12)	(880-4,020)	
			±62.0	±405.0	±0.65	±260.0	
III. Control rabbits fed stock diet							
4	3,284	168	57	583	8	560	0.96
			(38-64)	(391-937)	(8-9)	(488-600)	

* Average of all serum cholesterol determinations obtained every 3 weeks.

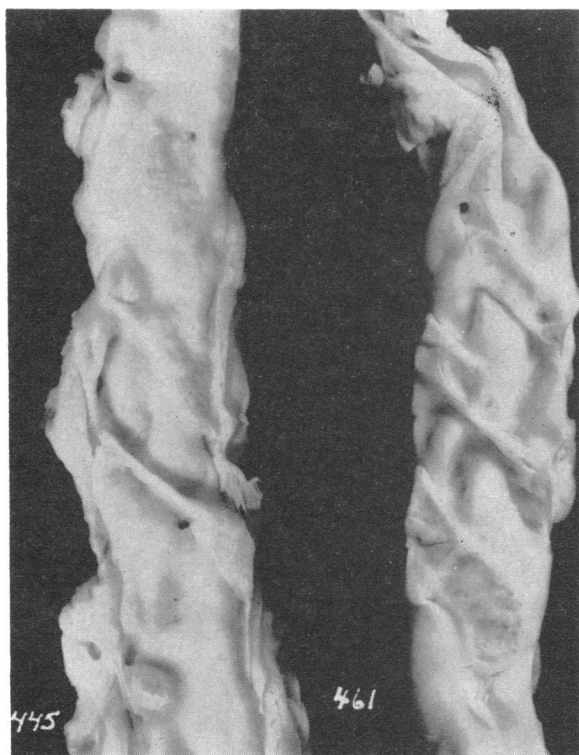


FIG. 6. RABBITS 445 AND 461: THE PLAQUES FORMING 168 DAYS AFTER INTRA-AORTIC COIL INSERTION. Although Rabbit 445 had been fed the cholesterol-oil enriched diet for the last half of the total period, its plaque segments in general resemble those of the control rabbit 461 fed the stock diet. Compare these plaque segments of Rabbit 445 with those of Rabbit Mg S-18 of Figure 3.

one plaque (Figure 1, G), the degree of sudanophilia was insignificant compared with that found in the same rabbit's ascending aorta (Figure 1, H). In short, a firm, relatively acellular, fibrous plaque, essentially similar to that found in the stock-fed rabbits (compare E and G in Figure 1), was observed in these rabbits despite their prolonged cholesterol-oil feeding and accompanying hypercholesterolemia.

The chemical analyses also indicated that a plaque already 84 days old possessed a relative immunity to experimentally induced dietary hypercholesterolemia not shared by the plaque only 21 days old or less. Thus (Table II), the average cholesterol of these plaques was 2,097 mg per 100 ml, a value only 1.47 times that of the adjacent abdominal aorta. It should be noted, however, that the average cholesterol content of the plaques of the four control rabbits allowed to survive for a

similar period of 168 days was considerably less than that of the plaques of other rabbits fed the stock diet and allowed to survive for only 84 days after coil insertion.

DISCUSSION

We are well aware of the probability that some of the results of this present study will be considered by some investigators as important principally because they furnish direct experimental proof of the ability of a thrombus to elicit the formation of a plaque bearing a striking chemical as well as architectural resemblance to the plaque found in the human artery. Certainly it cannot be denied that starting with a thrombus, we invariably induced a plaque. Nor can it be denied that if the cholesterol concentration of the rabbit's blood was elevated to that of man or higher, lipid and cholesterol accumulation quickly ensued in these plaques and that they, similar to human plaques, frequently exhibited internal degeneration, necrosis and liquefaction.

But these same experiments also appeared to us to demonstrate that the formation of a plaque need not rely solely upon a thrombus for its initiation, growth or maturation. Certainly in our own experiments with hypercholesterolemic rabbits, an atherosclerotic plaque resulted whether the initial injury or stimulus to the vessel wall was caused by the fulminant sort of thrombus induced by metal coil, by the bland type resulting from introduction of the polyethylene tubing, or even by mere contact with the tubing itself. Moreover, the type of plaque and its evolution induced by our thrombi was essentially similar to that induced by needle scraping of the aortic intima (10, 20), by cauterization of the adventitia (21), by explantation of the carotid arteries (22), and by freezing of the aorta (8, 23). Indeed, it is probable that the fragmentation of the internal elastic membrane observed in the arteries of infants (24), and the intramural hemorrhage so often observed in the arteries of adults (25) conceivably could induce the same type of atherosclerotic plaque that has been produced experimentally.

Despite the variety and multiplicity of the above agents and events capable of injuring or altering the arterial wall and hence inducing

atherosclerotic reactions, all of them are followed, as is well known, by intimal proliferation or hyperplasia. We consider it quite probable that the essential sameness of all human atherosclerotic plaques may be due, not to the sameness of initiating agent, but to the sameness of intimal hyperplasia and its peculiar properties which these various agents elicit.

It is of course possible that the initial tissue injury itself, by giving rise to a state of inflammation, as Boyd (26), Winternitz, Thomas and LeCompte (27) and Waters (28-31) believe, invariably elicits the intimal hyperplasia and perhaps the lipid and cholesterol accumulation occurring therein. It is difficult to refute this possibility if only because all of the above agents seemingly induce tissue injury or change, and the latter might be expected to elicit, if not all, at least several of the classic phenomena associated with inflammatory processes. In our own experiments however we, as did Taylor, Balwin and Hass (23), failed to observe the presence of a significant number of inflammatory cells in our lesions at any stage. Moreover, the lipid and cholesterol accumulation observed in the plaques of rabbits that were not made hypercholesterolemic until 21 days after clot induction was no less than that observed in the plaques of rabbits made hypercholesterolemic immediately after thrombus formation. Whereas these facts make us reasonably certain that *acute* inflammation could not be responsible for the lipid and cholesterol accumulation, they do not rule out the possible operation of a chronic inflammatory process. Indeed, the mere presence of a rapidly growing tissue in a high pressure system such as is present in the arterial lumen might lead to a new series of injuries or inflammatory reactions, or both.

The present studies indicated quite clearly, we believe, that in the early stages of intimal hyperplasia, stainable lipid was first deposited chiefly in the basal and lateral areas of the forming plaque. Whether such lipid represented an increased synthesis *in situ* or an exudate (31) is a question that remains to be answered. Certainly it was clearly shown that it could not have been derived from any lipid initially present in the thrombus as Curran, Thomas and O'Neal (32) believed. It was of great interest to us, too, to observe that, although the newly developing

plaque exhibited tremendous proneness to lipid and cholesterol accumulation, the mature plaque, as Ssolowjew (21, 22) also observed in his experiments, exhibited a striking immunity to such accumulation. The basal deposition of lipid in the induced plaque of hypercholesterolemic rabbits contrasted strikingly with the superficial subendothelial lipid accumulation occurring in the spontaneous atherosclerosis developing in the aortic arch of these animals. In view of the similarity of the human plaque to the induced one and its well known dissimilarity to the spontaneous atherosclerotic area developing in the rabbit maintained *continuously* hypercholesterolemic (2, 7), it seems possible that the human atherosclerotic plaque may also quite often be the sequent of a *discontinuous* insult rather than of a continuous transintimal penetration of lipid and cholesterol. Such an insult could be a thrombotic one, but it could just as well be hemorrhagic, physical or chemical.

Central necrosis with occasional ulcer formation is frequently observed in the human arterial plaque. Its cause has not been determined, although it has been postulated (2, 12, 33) that it occurs as a result of central ischemia. This, however, does not appear to be the responsible agent because, in our experiments, none of the plaques of the normocholesterolemic animals ever exhibited central disintegration or necrosis. On the other hand, it was found in almost all of the lipid-laden plaques of the hypercholesterolemic animals. Thus, it is our belief that it is the huge depots of lipid and cholesterol themselves that effected the necrosis we observed so often. These may also be associated with the pathogenesis of the central necrosis occurring in human arterial plaques.

It was rather disconcerting to observe that the plaques induced in the control normocholesterolemic rabbits, while considerably smaller than those found in the hypercholesterolemic rabbits, were not insignificant in size, despite their absence of stainable lipid and relatively low cholesterol content. Similar relatively lipid-free plaques are also found in human arteries (2, 12, 34, 35). Indeed, from the studies of Moon (24) and Enos, Beyer and Holmes (33) it seems extremely doubtful that such plaques could have been caused by an initial deposit of lipid or cholesterol. Rather,

it would appear that the plaque served as a site for later accumulation of these substances. In our studies, in which the total process could be observed at all stages, there could be no doubt that a plaque's origin did not depend exclusively upon a prior deposit of lipid or cholesterol; to the contrary, it invariably depended upon a preceding intimal hyperplasia. This latter phenomenon in turn did not at all stem *always* from an initial infiltration or accumulation of lipid or cholesterol. However, the later accumulation of such substances almost always intensified, hence aggrandized, the intimal overgrowth.

SUMMARY

The experimental induction of intra-arterial thrombi by two different techniques led, in the hypercholesterolemic rabbit, to a plaque exhibiting a striking gross and histological resemblance to that observed in human atherosclerosis. These induced thrombo-atherosclerotic plaques consisted of dense, relatively acellular fibrous tissue having deeply embedded lipid and were frequently subject to central fatty degeneration and liquefaction.

The propensity of these plaques to accumulate the excessive amounts of lipid and cholesterol actually observed was found to be due to the intimal hyperplastic tissue that the thrombi evoked. The avidity of this living intimal tissue for these substances, however, was confined to the early stages of the tissue's growth. After final fibrous transformation of such tissue, actual protection against the accumulation of lipid and cholesterol was observed.

The possible relevance of these experimental studies to the general pathogenesis of atherosclerosis was discussed.

ACKNOWLEDGMENT

The authors wish to express their deep thanks to C. Omoto, W. Hayashi and Elizabeth Wang for their technical assistance. The costs of publishing the color plate in this article were defrayed by a contribution from the Wm. S. Merrell Company. Their assistance is gratefully acknowledged.

REFERENCES

1. von Rokitsansky, C. A Manual of Pathological Anatomy. London, Sydenham Soc., 1852, vol. 3, p. 261.
2. Virchow, R. Gesammelte Abhandlungen zur wissenschaftlichen Medicin. Frankfurt a. M., Meidinger, 1856, p. 499.
3. Anitschkow, N. Über die Atherosklerose der Aorta beim Kaninchen und über deren Entstehungsbedingungen. Beitr. path. Anat. 1914, 59, 306.
4. Duguid, J. B. Thrombosis as a factor in the pathogenesis of coronary atherosclerosis. J. Path. Bact. 1946, 58, 207.
5. *Ibid.*, 1948, 60, 57.
6. Duguid, J. B. Pathogenesis of Atherosclerosis. Lancet 1949, 2, 925.
7. Moon, H. D., and Rinehart, J. F. Histogenesis of coronary arteriosclerosis. Circulation 1952, 6, 481.
8. Kelly, F. B., Jr., Taylor, C. B., and Hass, G. M. Experimental atheroarteriosclerosis; localization of lipids in experimental arterial lesions of rabbits with hypercholesteremia. Arch. Path. (Chicago) 1952, 54, 419.
9. McLetchie, N. G. B. The pathogenesis of atheroma. Amer. J. Path. 1952, 28, 413.
10. Prior, J. T., and Hartmann, W. H. The effect of hypercholesterolemia upon intimal repair of the aorta of the rabbit following experimental trauma. Amer. J. Path. 1956, 32, 417.
11. Constantinides, P., Booth, J., and Carlson, G. Production of advanced cholesterol atherosclerosis in the rabbit. Arch. Path. (Chicago) 1960, 70, 712.
12. Geiringer, E. Intimal vascularisation and atherosclerosis. J. Path. Bact. 1951, 63, 201.
13. Crawford, T., and Levene, C. I. The incorporation of fibrin in the aortic intima. J. Path. Bact. 1952, 64, 523.
14. Morgan, A. D. The Pathogenesis of Coronary Occlusion. Oxford, Blackwell, 1956.
15. Haust, M. D., More, R. H., and Movat, H. Z. The mechanism of fibrosis in arteriosclerosis. Amer. J. Path. 1959, 35, 265.
16. Friedman, M., Byers, S. O., and Pearl, F. Experimental production of intra-arterial and intravenous thrombi in the rabbit and rat. Amer. J. Physiol. 1960, 199, 770.
17. Friedman, M., and Byers, S. O. Employment of polyethylene tubing for production of intra-arterial thrombi in rabbits and rats. Proc. Soc. exp. Biol. (N. Y.). In press.
18. Friedman, M., Homer, R., and Byers, S. O. An evaluation of potassium iodide as a therapeutic agent in the treatment of experimental hypercholesteremia and atherosclerosis. J. clin. Invest. 1956, 35, 1015.
19. Van Handel, E., and Zilversmit, D. B. Micromethod for the direct determination of serum triglycerides. J. Lab. clin. Med. 1957, 50, 152.
20. Prior, J. T., and Hutter, R. V. P. Intimal repair of the aorta of the rabbit following experimental trauma. Amer. J. Path. 1955, 31, 107.

21. Ssolowjew, A. Experimentelle Untersuchungen über die Bedeutung von lokaler Schädigung für die Lipoidablagerung in der Arterienwand. *Z. ges. exp. Med.* 1930, **69**, 94.
22. Ssolowjew, A. Über experimentell hervorgerufene Elasticarisse der Arterien und deren Bedeutung für die Lipoidablagerung. *Virchows Arch. path. Anat.* 1932, **283**, 213.
23. Taylor, C. B., Baldwin, D., and Hass, G. M. Localized arteriosclerotic lesions induced in the aorta of the juvenile rabbit by freezing. *Arch. Path. (Chicago)* 1950, **49**, 623.
24. Moon, H. D. Coronary arteries in fetuses, infants, and juveniles. *Circulation* 1957, **16**, 263.
25. Paterson, J. C., and Moffatt, T. The demonstration of iron in early atherosclerotic plaques (abstract). *Circulation* 1954, **10**, 609.
26. Boyd, A. N. An inflammatory basis for coronary thrombosis. *Amer. J. Path.* 1928, **4**, 159.
27. Winternitz, M. C., Thomas, R. M., and Le Compte, P. M. *The Biology of Arteriosclerosis*. Springfield, Ill., C. C. Thomas, 1938.
28. Waters, L. L. Studies on the pathogenesis of vascular disease. The effect of intravenous egg-yolk emulsions on inflammatory lesions of the aorta and coronary arteries of dogs. *Yale J. Biol. Med.* 1956, **29**, 9.
29. Waters, L. L. Studies on the pathogenesis of vascular disease: The effect of intravenously injected human plasma and of lipid-rich human plasma globulins on inflammatory lesions of the coronary arteries of dogs. *Yale J. Biol. Med.* 1957, **30**, 57.
30. Waters, L. L. Studies on the pathogenesis of vascular disease: The effect of a fatty meal on the course of acute inflammatory lesions of the coronary arteries and aorta of dogs. *Yale J. Biol. Med.* 1957, **30**, p. 101.
31. Waters, L. L. The reaction of the artery wall to injury by chemical or infection *in* Symposium on Atherosclerosis. *Proc. nat. Acad. Sci. (Wash.)* 1954, publ. 338, p. 91.
32. Curran, J., Thomas, W. A., and O'Neal, R. M. The introduction of fat into thrombi. An experimental study. *Arch. Path. (Chicago)* 1960, **69**, 270.
33. Enos, W. F., Jr., Beyer, J. C., and Holmes, R. H. Pathogenesis of coronary disease in American soldiers killed in Korea. *J. Amer. med. Ass.* 1955, **158**, 912.
34. Wilens, S. L. The nature of diffuse intimal thickening of arteries. *Amer. J. Path.* 1951, **27**, 825.
35. Holman, R. L., McGill, H. C., Jr., Strong, J. P., and Geer, J. C. Natural history of atherosclerosis: Early aortic lesions as seen in New Orleans in the middle of the 20th century. *Amer. J. Path.* 1958, **34**, 209.