

Functional Profile of Tissue-infiltrating and Circulating CD68⁺ Cells in Giant Cell Arteritis

Evidence for Two Components of the Disease

Annette D. Wagner, Jörg J. Goronzy, and Cornelia M. Weyand

Department of Medicine, Division of Rheumatology, Mayo Clinic and Foundation, Rochester, Minnesota 55905

Abstract

Macrophages represent a critical component in the inflammatory lesions of giant cell arteritis. By combining immunohistochemistry and in situ hybridization, we have analyzed the functional heterogeneity of tissue-infiltrating macrophages in patients with untreated vasculitis. 20% of macrophages in temporal artery tissue synthesized IL-6-specific mRNA and produced IL-6 and IL-1 β proteins. IL-6 and IL-1 β production was not limited to CD68⁺ cells in the lymphoid aggregates but was a feature of CD68⁺ cells dispersed throughout the tissue. 50% of tissue-infiltrating CD68⁺ cells synthesized 72-kD type IV collagenase. Only a small subset of CD68⁺ cells produced cytokines as well as collagenase, indicating functional specialization or distinct differentiation stages of CD68⁺ cells in the inflamed tissue. Activation of CD68⁺ cells was not restricted to tissue-infiltrating cells. Expression of IL-6 and IL-1 β was found in 60–80% of circulating monocytes of patients with untreated giant cell arteritis, whereas collagenase production was restricted to tissue macrophages. IL-6 and IL-1 β production by the majority of circulating monocytes was a shared feature of patients with giant cell arteritis and polymyalgia rheumatica but was not found in rheumatoid arthritis. These data suggest that giant cell arteritis has two components of disease, an inflammatory reaction in vessel walls and a systemic activation of monocytes. Systemic monocyte activation can manifest independently without vasculitis as exemplified in patients with polymyalgia rheumatica. (*J. Clin. Invest.* 1994. 94:1134–1140.) Key words: polymyalgia rheumatica • vasculitis • monocyte activation • macrophage activation • chronic inflammation

Introduction

Giant cell arteritis (GCA)¹ is a vasculitic entity which characteristically affects the extracranial branches of the aorta (1). The diagnosis of GCA is established by demonstrating a panarteritic

infiltrate in the temporal artery (2). The etiology and pathogenesis of the disease is not understood completely (3). Several unique features of GCA patients might provide clues toward creating a pathogenic model for the disease. The dominant manifestations of the vasculitis are signs of a systemic disease with intense production of acute phase reactants. Affected individuals are consistently older than 50 yr of age, and the disease exhibits a unique tissue tropism by affecting the upper extremity branches of the thoracic aorta, but sparing the intracranial arteries (1, 4).

We have provided evidence recently for clonal expansion of CD4⁺ T cells in the vascular lesions (5). A minority of tissue-infiltrating T cells were present in multiple copies, and CD4⁺ T cells with identical T cell receptor β chains were isolated from distinct vasculitic foci. GCA has also been demonstrated to be an HLA-linked disease and a potentially disease-relevant genetic element has been mapped to the second hypervariable region of the HLA-DR β chain (6–9). Clonal expansion of CD4⁺ T cells and restriction in the polymorphism of antigen-presenting HLA-DR molecules support the model that GCA is an antigen-driven disease resulting from recognition of a disease-inducing antigen in the wall of medium-sized arteries.

Besides T lymphocytes, macrophages are the second component of the vascular lesions. Their role in the inflammatory events in the arterial wall is unclear. Several functions of macrophages could be of significance in initiating and maintaining the tissue infiltrate in GCA. Macrophages are phagocytic and internalize microorganisms and cellular debris. They process and present antigen to T cells (10). They release a spectrum of cytokines, inflammatory mediators, and tissue-damaging enzymes, and form oxygen radicals (11). The secretory potential of macrophages probably contributes to their involvement in cytotoxic responses, their regulatory role of immune responses and inflammation, and their participation in hemo- and lymphopoiesis. The analysis of tissue-infiltrating macrophages and circulating monocytes in GCA presented here demonstrates that they play a role in two aspects of the disease. Macrophages in the inflammatory infiltrate are heterogeneous and include a subset secreting proinflammatory cytokines. Circulating monocytes are highly activated and probably are recruited into the tissue. The presence of activated circulating monocytes in patients with polymyalgia rheumatica (PMR), a related condition without vasculitis, suggests that activation of monocytes is neither sufficient to induce vasculitis nor the result of it. We hypothesize that GCA has two components of disease, a systemic component and an in situ component, which might be independently regulated.

Methods

Patient population. PBMC were obtained from 12 patients with biopsy-proven GCA, 7 patients with PMR, 9 patients with seropositive RA,

Address correspondence to Cornelia M. Weyand, M.D., Ph.D., Mayo Clinic, 401 Guggenheim Building, 200 First Street, SW, Rochester, MN 55905.

Received for publication 28 January 1994 and in revised form 28 April 1994.

1. Abbreviations used in this paper: GCA, giant cell arteritis; PMR, polymyalgia rheumatica; RT-PCR, reverse transcriptase–polymerase chain reaction.

and 14 control individuals. Temporal artery specimens were obtained from 10 patients with GCA. Criteria used for the diagnosis of PMR were as follows: at least a 4-wk history of aching and stiffness involving two out of three areas (shoulders and proximal arms, hips and proximal thighs, and neck and torso) and an erythrocyte sedimentation rate of > 40 mm/1 h in the absence of any other underlying disease (12). Patients with RA fulfilled the American College of Rheumatology criteria for seropositive erosive disease and had active joint disease (13). None of the patients received corticosteroid treatment at the time of the study. The control individuals had no history of an inflammatory disease.

Antibodies. The following antibody reagents were used: anti-CD14 (anti-Leu M3; Becton Dickinson Immunocytometry Systems, Mountain View, CA), murine anti-CD68 mAb (KPI; Dako Corp., Carpinteria, CA), goat anti-human IL-1 β and anti-human IL-6 antibodies (R&D Systems, Inc., Minneapolis, MN), murine anti-human IL-6 mAb (Dr. J. VanDamme, Leuven, Belgium), polyclonal rabbit anti-72-kD type IV collagenase antibody (Dr. W. G. Steler-Stevenson, National Institutes of Health, Bethesda, MD), biotinylated rabbit anti-mouse Ig (Dako Corp.), rhodamine isothiocyanate-conjugated AffiniPure donkey anti-mouse Ig, FITC-conjugated AffiniPure donkey anti-goat IgG, and FITC-conjugated anti-rabbit Ig (all from Jackson ImmunoResearch Laboratories, Inc., West Grove, PA).

Semiquantification of IL-6- and IL-1 β -specific mRNA by reverse transcriptase-polymerase chain reaction (RT-PCR). PBMC were purified from heparinized venous blood of untreated patients and normal controls by Ficoll gradient centrifugation. The percentage of CD14 $^{+}$ cells was determined by FACS $^{\circ}$ analysis. Total RNA was extracted by phenol guanidinium thiocyanate phenol chloroform extraction (RNAzol; Tel Text, Inc., Friendswood, TX). cDNA equivalent to 1×10^4 CD14 $^{+}$ cells was serially diluted and amplified by PCR with primer sets specific for IL-6 (GATGTAGCCGCCACACAGACAG and CCTCAAACCTCAAAGACCAGTGATG) and IL-1 β (GACACATGGGATAACGAGGC and ACGCAGGACAGGTACAGATT). The maximal dilution of cDNA giving an amplified product which could be detected by agarose electrophoresis and ethidium bromide staining was compared in untreated patients and normals to semiquantify cytokine production as described recently (14). Amplification with β -actin-specific primers (ATCATGTTTGGACCTTCAACACC and CATGGTGGTGCCGCCAGACAG) was used as an internal control.

Immunohistochemistry. Tissue samples (4- μ m serial sections) were fixed with cold 4% paraformaldehyde/PBS, pH 7.4, washed two times in diethylpyrocarbonate/PBS, and dehydrated through graded ethanol (30, 50, 75, 95, and 100%). Slides were dried at room temperature for 30 min and stored at -70°C .

Frozen slides were rehydrated, and every tenth section was stained with an anti-CD68 antibody to demonstrate inflammatory infiltrates. Slides were developed by subsequent incubations with biotinylated rabbit anti-mouse IgG, peroxidase-labeled streptavidin, and diaminobenzidine substrate solution. Specimens adjacent to sections with an inflammatory infiltrate were stained with combinations of the following antibodies: anti-IL-6 and anti-CD68, anti-IL-1 β and anti-CD68, anti-IL-6 and anti-IL-1 β , anti-CD68 and anti-72-kD type IV collagenase, and anti-IL-6 and anti-72-kD type IV collagenase antibodies for 1 h at room temperature. After washing, slides were subsequently incubated with the appropriate developing antibodies for 45 min at 37°C . Slides were analyzed by using an upright Axiphot fluorescence photomicroscope (Carl Zeiss, Inc., Oberkochen, Germany). The images were captured with an SIT camera (Hamamatsu, Hamamatsu City, Japan) and digitized to 256 gray values with an IBAS image analysis system (Kontron Elektronik, Munich, Germany). Data were analyzed for the number of single- and double-positive cells after accounting for background fluorescence and objects showing autofluorescence.

7.5×10^4 PBMC were fixed in chamber slides with cold 4% paraformaldehyde/PBS, pH 7.4, for 50 min at room temperature. After fixation, cells were incubated with 0.1 Triton X-100/PBS buffer for 10 min at room temperature, washed twice in PBS, and preincubated with 10% FCS/PBS for 30 min. Fixed PBMC were analyzed by immunohistochemistry as outlined above for tissue sections.

In situ hybridization. Sense and antisense riboprobes were synthesized by amplifying cDNA from LPS-activated PBMC with IL-6-specific primers. A T7 promoter sequence was attached to either oligonucleotide. The amplified template was transcribed using T7 RNA polymerase and a commercially available kit (Promega Corp., Madison, WI) in the presence of S35 UTP.

Temporal artery tissue sections and PBMC, respectively, were stained with the anti-CD68 mAb, incubated with 0.1% Triton X-100/PBS buffer for 10 min at room temperature, and acetylated in 0.1 M triethanolamine, pH 8.0, and 0.25% acetic anhydride for 10 min at room temperature. Slides were washed twice in $0.2 \times$ SSC for 10 min each at room temperature and prehybridized for 3 h in 50% formamide, $2.5 \times$ Denhardt's solution, 0.15 mg/ml salmon sperm DNA, 0.6 M NaCl, 10 mM Tris/HCl, pH 7.5, 1 mM EDTA, 0.1% SDS, and 0.05 mg/ml wheat germ RNA. Riboprobes (1.25×10^5 cpm) were added to 50 μ l hybridization solution containing prehybridization buffer plus 10% dextran sulphate and 10 mM DTT. After 12 h at 45°C , the slides were sequentially washed in 50% formamide, $1 \times$ SSC, and 10 mM EDTA, followed by $0.5 \times$ SSC, and then $0.2 \times$ SSC. The slides were treated with RNase, dehydrated, coated with Kodak NTB2 autoradiography emulsion (Eastman Kodak Co., Rochester, NY), exposed for 2 wk, and counterstained with Schmitt's hematoxylin (EM Science, Gibbstown, NJ). An in situ hybridization signal was considered positive when a cell contained 15 or more silver grains.

Results

Functional analysis of tissue-infiltrating CD68 $^{+}$ cells in GCA. Macrophages infiltrating the wall of the temporal artery could contribute to the inflammatory process through their secretory, phagocytic, and immunoregulatory functions. To assess whether inflammatory macrophages produce cytokines such as IL-6 and IL-1 β , we used immunohistochemistry combined with in situ hybridization. Temporal artery specimens of 10 patients with unequivocal GCA were analyzed. Staining with anti-CD68 mAb showed that 15–20% of all nucleated cells expressed this marker. CD68 is an intracellular glycoprotein with a molecular mass of 110 kD, probably associated with lysosomal granules and expressed in tissue macrophages and in monocytes, granulocytes, and myeloid precursor cells (15). In the absence of tissue-infiltrating granulocytes in GCA, the CD68 $^{+}$ cells should predominantly represent macrophages or infiltrating monocytes. Although CD68 $^{+}$ cells were clustered in the inflammatory granuloma typically arranged around the elastic lamina, CD68 $^{+}$ cells were also abundantly present outside of the infiltrate and were encountered in the intima as well as the adventitia.

Immunohistochemistry demonstrated the presence of IL-6 protein in the tissue (Fig. 1, a and b). To semiquantify the frequency of CD68 $^{+}$ cells producing IL-6 protein, double immunofluorescence with anti-CD68 and anti-IL-6 antibodies was applied. Anti-IL-1 β antibodies in combination with anti-CD68 antibodies were used to examine the production of a second proinflammatory cytokine. Results from these experiments are summarized in Table I. All patients analyzed had IL-6-secreting CD68 $^{+}$ cells, the frequency ranged from 12 to 25% of CD68 $^{+}$ cells. About 20% of CD68 $^{+}$ tissue-infiltrating cells produced IL-1 β . More than 90% of CD68 $^{+}$ cells producing IL-6 coproduced IL-1 β as demonstrated by double immunofluorescence (Fig. 1, c and d). A small number of CD68 $^{+}$ macrophages produced either IL-6 or IL-1 β . These experiments also revealed that $> 90\%$ of IL-1 β - or IL-6-producing cells expressed the CD68 phenotype. The small number of CD68 $^{-}$ cytokine-producing cells were dispersed throughout the tissue,

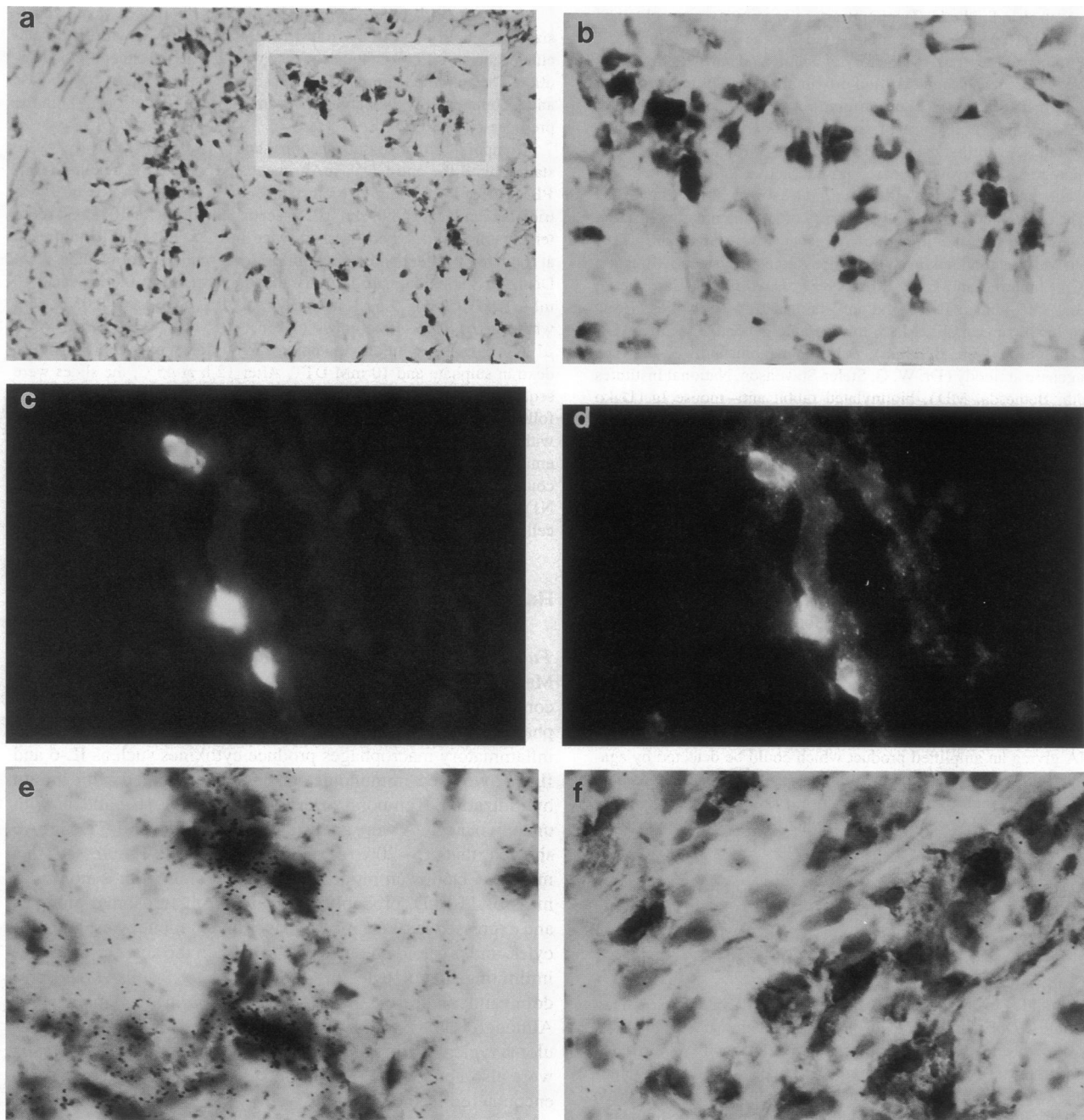


Figure 1. Expression of IL-6 protein and IL-6 mRNA in the vascular lesions of patients with GCA. Cryosections of temporal artery specimens were analyzed by immunohistochemistry (*a* and *b*), double immunofluorescence (*c* and *d*), and in situ hybridization with an IL-6 mRNA-specific oligonucleotide probe (*e* and *f*). *a* shows representative experiments using anti-IL-6 antibody for immunohistochemical studies. The highlighted area in *a* is given as a high power view in *b* (at a magnification of 1,000). Staining with antibodies specific for IL-6 (red fluorescence) is shown in *c*. These cells coexpressed IL-1 β protein as demonstrated in *d* (green fluorescence). Control slides stained without the primary cytokine-specific antibodies did not show any cytoplasmic staining (data not shown). In situ hybridization with IL-6 antisense riboprobes combined with immunohistochemistry with an anti-CD68 antibody (*e*) revealed that IL-6-specific transcripts were synthesized by CD68⁺ cells. The control experiment with an IL-6 mRNA-specific sense probe is shown in *f*.

were CD4⁻, and did not locate with endothelial cells (data not shown).

Staining for IL-1 β and IL-6 was more pronounced in CD68⁺ cells but was also found extracellularly. To address the question whether CD68⁺ cells were indeed the cellular source of IL-6, in situ hybridization was combined with immunohistochemistry.

Hybridization with IL-6-specific probes showed that IL-6 mRNA was abundantly present in vascular lesions. IL-6 mRNA-expressing cells predominantly stained as CD68⁺. About 20% of CD68⁺ cells gave a positive hybridization signal for IL-6-specific transcripts (Table I and Fig. 1, *e* and *f*). Again, CD68⁺ IL-6 mRNA-positive cells were encountered both inside and

Table I. Expression of Proinflammatory Cytokines in Temporal Artery Specimens of Patients with GCA

	Number of patients	Percentage of CD68 ⁺ tissue-infiltrating cells (mean±SD)
IL-6 mRNA	7	18.3±3.2
IL-6 protein	10	19.6±5.7
IL-1 β protein	8	20.1±5.5

outside of the densely packed lymphoid aggregates. To examine whether CD68⁺ cells within the cellular aggregates were enriched for cytokine-secreting cells, the frequencies of CD68⁺ IL-6⁺ cells inside and outside of the granulomatous infiltrate were compared. The fraction of IL-6-secreting cells among the CD68⁺ cell population was one out of five cells, both inside and outside of the granuloma. In tissue samples where giant cells were identified, IL-6 or IL-1 production could not be assigned to these cells (data not shown).

GCA is characterized by destruction of the arterial wall. In particular, fragmentation of the elastic lamina is considered a hallmark of the disease. Macrophages secreting metalloproteinases might have critical function in degradation of matrix macromolecules. To investigate whether tissue-infiltrating CD68⁺ cells have the potential for tissue destruction, tissue samples were analyzed for the expression of the 72-kD type IV collagenase. Immunohistochemistry with 72-kD type IV collagenase-specific antibodies demonstrated that the vast majority of collagenase-secreting cells were of the CD68⁺ phenotype (data not shown). Extracellular staining was not seen. About 50% of all CD68⁺ cells in the tissue had the capability of producing the metalloproteinase. In previous reports, the potential to secrete metalloenzymes has been correlated with the state of differentiation of macrophages (16). To examine whether the capacity to degrade extracellular matrix via secreted metalloproteinases and the ability to produce proinflammatory cytokines were linked, or could be attributed to different subsets of CD68⁺ cells, double immunofluorescence was used. The data are given in Fig. 2 and show that cytokine production and collagenase secretion were functions of different cell populations. Only a small proportion of CD68⁺ cells stained positive for IL-6 protein and collagenase, indicating that these cells had both functional capabilities.

The analysis of CD68⁺ cells in the arteritic lesions revealed that at least four phenotypically distinct macrophage subsets exist; about half of all CD68⁺ cells are a source of the tissue-degrading metalloproteinase 72-kD type IV collagenase. 20% of the CD68⁺ macrophages produce the proinflammatory cytokines IL-1 β and IL-6, and about one-third of the cells neither secrete collagenase nor cytokines. A small fraction of CD68⁺ cells has the potential to function as cytokine-producing and collagenase-producing cells.

Functional analysis of circulating CD68⁺ cells in GCA. Analysis of tissue-infiltrating CD68⁺ cells demonstrated functional heterogeneity with only a subset of cells producing IL-6 and IL-1 β protein. Cytokine production was not restricted to macrophages within the inflammatory aggregates, raising the question of where these cells acquire their state of activation. Phenotypical and functional studies were therefore extended to include circulating monocytes. Staining with anti-72-kD type

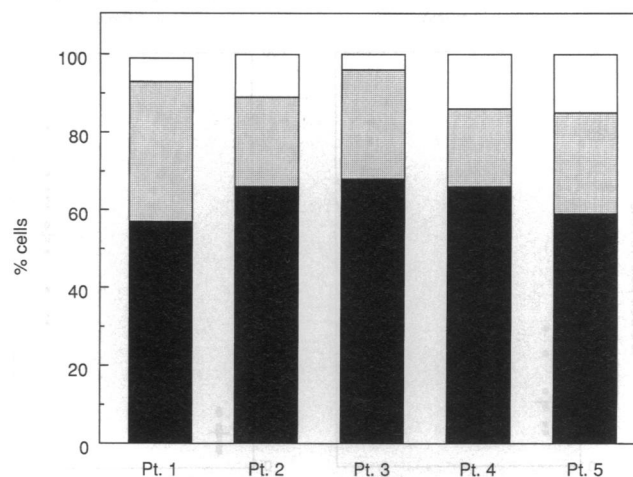


Figure 2. Expression of 72-kD type IV collagenase and IL-6 protein in vascular lesions of GCA. Temporal artery sections of five patients with GCA were stained with a polyclonal rabbit anti-72-kD type IV collagenase antibody and a murine anti-human IL-6 mAb. Slides were developed with an FITC-conjugated anti-rabbit Ig and a rhodamine isothiocyanate-conjugated anti-mouse Ig antibody. Cells with double and single immunofluorescence were counted and expressed as the percentage of the total of fluorescing cells. Of all cells, 60–70% expressed collagenase only (solid bars), 19–36% expressed IL-6 (stippled bars), and only a minority of cells coexpressed IL-6 and collagenase (open bars). Double fluorescence with an anti-CD68 antibody and the anti-IL-6 or anticollagenase antibody showed that ~50% of CD68⁺ cells express collagenase (data not shown) and ~20% express IL-6 (Table I). These data demonstrate that IL-6- and collagenase-producing cells are distinct subsets of CD68⁺ cells with a small overlap of cells coproducing the enzyme and the cytokine.

IV collagenase antibodies was essentially negative on PBMC of GCA patients and normal controls (data not shown). Immunohistochemical studies with antibodies specific for IL-6 and IL-1 β proteins showed that a high frequency of PBMC from GCA patients produced these cytokines (Fig. 3). In PBMC from 12 patients with untreated GCA, 56% of CD68⁺ cells gave a positive signal for IL-6 protein. A mean of 9% of CD68⁺ cells in 14 healthy normal donors produced IL-6 protein. To exclude that the cytokine expression was induced by the adherence step before immunohistochemistry, saponin-treated and formaldehyde-fixed PBMC were directly stained with anti-IL-6 antibody and analyzed by FACS[®]. These experiments confirmed that the majority of circulating monocytes of GCA patients expressed IL-6 (data not shown). To identify the cellular source of IL-6, in situ hybridization was combined with immunohistochemistry. CD68⁺ cells were the exclusive cell type in PBMC producing IL-6 mRNA. 72% of all CD68⁺ cells from untreated GCA patients compared with 17% of CD68⁺ PBMC from control individuals hybridized with the IL-6 probe (Fig. 3). This approach demonstrated that circulating monocytes in GCA patients were activated and released the proinflammatory cytokine IL-6. While the tissue-infiltrating CD68⁺ cells were heterogeneous, circulating monocytes were predominantly composed of a population phenotypically similar to ~20% of the tissue macrophages.

Functional analysis of circulating CD68⁺ cells in PMR. Comparison of circulating and tissue-infiltrating CD68⁺ cells in GCA patients revealed two interesting findings. Circulating

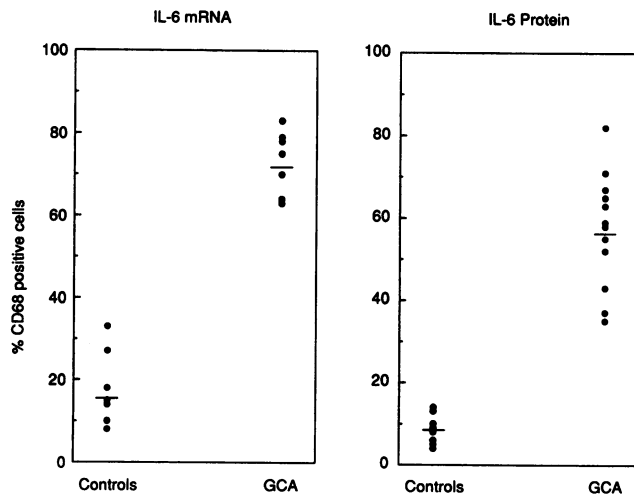


Figure 3. Expression of IL-6 mRNA and production of IL-6 protein in PBMC of GCA patients. PBMC of patients with GCA and normal individuals were analyzed for the expression of IL-6 mRNA by in situ hybridization and for the production of IL-6 protein by immunofluorescence. CD68⁺ cells were identified by immunohistochemistry. In situ hybridization results are shown for 7 control individuals and 7 GCA patients (*left*), the expression of IL-6 protein was analyzed for 14 control and 12 GCA patients (*right*). GCA patients had significantly higher numbers of CD68⁺ cells producing IL-6 mRNA ($P < 0.0001$) and IL-6 protein ($P < 0.0001$).

CD68⁺ cells were activated in a high frequency, and the composition of the peripheral and tissue compartments was clearly distinct, raising the possibility of selective recruitment into the vascular lesions. To investigate the relationship between circulating and tissue-infiltrating CD68⁺ cells, we made use of the fact that a clinically incomplete form of GCA exists. PMR shares with GCA the acute phase response, the constitutional symptoms, and the prompt response to corticosteroids. PMR lacks the vasculitic infiltrate and thus resembles a forme fruste of GCA.

To analyze the production of proinflammatory cytokines in PMR patients, we collected PBMC from untreated patients and semiquantified IL-1 β - and IL-6-specific transcripts by RT-PCR. The number of CD14⁺ cells was higher in patients with GCA and PMR than in normal controls (data not shown). Cell numbers were therefore adjusted for the frequency of CD14⁺ cells. By subsequent cytokine-specific RT-PCR, we determined the minimal cDNA dilution providing a specific signal. Data are summarized in Table II. In samples from normal controls, no signal for IL-6 was detected in a total of 1×10^4 CD14⁺

Table II. Semiquantification of IL-1 β and IL-6 Transcripts in PBMC by RT-PCR

	Minimal cDNA dilution providing specific signal	
	IL-1 β	IL-6
Healthy controls ($n = 9$)	1:2–1:4	n.d.*
GCA patients ($n = 5$)	1:128	1:8–1:16
PMR patients ($n = 6$)	1:64–1:128	1:8–1:16

*Not detectable.

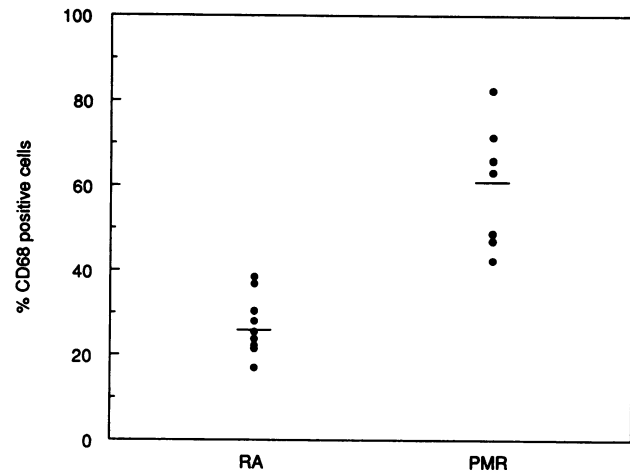


Figure 4. Production of IL-6 protein in PBMC of patients with PMR and RA. PBMC from nine patients with RA and seven patients with PMR were stained with anti-IL-6 and anti-CD68 antibodies. The percentage of IL-6-producing CD68⁺ cells in RA was only slightly higher than in normal controls (Fig. 3), but was significantly higher in patients with PMR than in RA patients ($P = 0.0003$).

cells. 8–16-fold dilutions of cDNA provided a specific band for IL-6 in PBMC from GCA patients, confirming the finding that monocytes were activated to produce IL-6. Very similar titers were found in PBMC of PMR patients. Similarly, both patient cohorts shared a substantial increase in the amount of IL-1 β -specific transcripts. While IL-1 β -specific signals were lost after one to two dilutions in cDNA from normals, cDNA from PMR and GCA patients could be diluted 1:64 to 1:128 and still contained detectable IL-1 β -specific sequences. These data indicated that PMR and GCA patients share the increase in IL-1 β and IL-6 mRNA synthesis in circulating cells.

PMR and GCA are both inflammatory diseases which are distinguished by the presence of a tissue-degrading infiltrate of T cells and macrophages in GCA. Activation of CD68⁺ circulating cells in both syndromes raises the question whether induction of IL-6 and IL-1 β mRNA is an epiphenomenon of inflammation. To address that question, we collected PBMC from patients with active RA who did not receive corticosteroids at the time of blood collection. Double immunofluorescence was applied to estimate the frequency of IL-6-producing CD68⁺ cells in nine RA patients and seven PMR patients. Data are shown in Fig. 4. Compared with normal healthy control individuals (Fig. 3), the frequency of IL-6⁺ CD68⁺ cells was slightly elevated in RA patients (mean $27 \pm 10\%$). A significant elevation of CD68⁺ IL-6⁺ cells was found in PMR patients. The mean frequency of 59% of CD68⁺ IL-6⁺ cells was indistinguishable from the frequency described in GCA patients (56%, Fig. 3). These experiments demonstrated that PMR and GCA have in common highly elevated numbers of cytokine-producing CD68⁺ cells in the periphery. PMR and GCA patients can be distinguished from RA patients in whom the frequencies of CD68⁺ IL-6⁺ cells are increased only slightly. These studies showed that induction of IL-6 and IL-1 β in circulating monocytes is not simply a consequence of tissue inflammation.

Discussion

Granulomatous inflammation is understood as a reaction aimed at isolating a harmful agent. Granuloma formation has been

associated with certain stimuli such as inert material or pathogenic microbes including bacteria, fungi, and parasites (17). Assembly of granulomas in the wall of medium-sized arteries is the histopathological hallmark of GCA, and it has been assumed that patients with GCA suffer from the sequelae of an unsuccessful attempt to eliminate a locally residing antigen. Studies presented here, designed to analyze the function of macrophages recruited to the site of inflammation, indicate that GCA has two components of disease, a local component and a systemic component which can be clearly dissected and which might have distinct pathomechanisms.

CD68⁺ macrophages constitute a major subset of the inflammatory cells forming the granuloma. Our phenotypical and functional studies indicate that they are rather heterogeneous. Only a small subset has the ability to secrete proinflammatory cytokines such as IL-1 β and IL-6 (Table I). Production of potentially tissue-degrading metalloproteinases could be assigned to a different subset of CD68⁺ cells (Fig. 2). This finding is in line with a previous report that cytokine secretion and other functions of phagocytotic cells are not necessarily linked (18). The *in situ* expression of 72-kD type IV collagenase, which cleaves basement membrane collagen and several denatured collagen types or gelatins, provides evidence that macrophages may be involved in tissue destruction (16, 19).

Whether macrophages expressing 72-kD type IV collagenase are derived from resident macrophages or from exudate macrophages remains unclear. The finding that > 50% of CD68⁺ cells in the infiltrate has acquired the capability for enzyme production makes it unlikely that all of them derived from locally proliferating macrophages. Indeed, we did find a small population of CD68⁺ cells which exhibited both functions, cytokine production and enzyme production. Whether the heterogeneity in the macrophage population results from differences in the functional state or the developmental state requires further investigation. The heterogeneity of tissue-infiltrating CD68⁺ cells supports the notion that these cells are involved in different aspects of the disease process such as tissue damage, amplification of cell recruitment, stimulation of T cells, and antigen presentation. IL-6, IL-1 β , and 72-kD type IV collagenase are not constitutively expressed in monocytes, but the induction of their genes requires activation. The dispersed distribution of cytokine- and enzyme-expressing cells in the inflammatory infiltrate makes cell-to-cell activation unlikely, but could be explained by a soluble mediator such as IFN- γ stimulating monokine and metalloproteinase gene expression.

While studies on the composition of tissue-infiltrating CD68⁺ cells demonstrating the recruitment of a functionally and phenotypically heterogeneous population of macrophages yielded an expected result, the finding of high frequencies of IL-6- and IL-1 β -producing CD68⁺ cells was surprising. Activation of circulating monocytes was shared by patients with GCA and PMR and thus cannot be considered the consequence of the vasculitic inflammation. Indeed, the degree of cytokine induction was similar in both syndromes without evidence for a more pronounced response in GCA. These findings are in line with our previous report that serum levels of IL-6 are highly elevated in patients with untreated GCA and PMR (20). Serum concentrations of IL-6 were equally elevated in both disease entities as well. It could be argued that induction of IL-6 mRNA, IL-1 β mRNA, and production of IL-6 and IL-1 β protein are an epiphenomenon of an inflammatory disease. Indeed, crossregu-

lation of cytokines appears to be the rule rather than the exception (21, 22). To address that question, we examined patients with a distinct inflammatory disease, RA, which is also characterized by local activation of macrophages and local IL-6 production (23–25). RA patients had slightly elevated frequencies of CD68⁺ IL-6⁺ cells when compared with normals. IL-6 positivity in the majority of circulating CD68⁺ cells, however, was a unique finding for GCA and PMR patients (Figs. 3 and 4). These data indicate that induction of proinflammatory cytokines in blood monocytes is not necessarily the result of a chronic inflammatory disease localized in the tissue.

The presence of similar frequencies of CD68⁺ IL-6⁺ cells in PMR and GCA patients demonstrates that activation of peripheral monocytes does not require the vasculitic part of the disease. Whether the availability of IL-6- and IL-1 β -producing monocytes in the blood is a prerequisite preceding the formation of the vasculitic lesions is possible but unanswered. That model would predict that an additional disease mechanism exists in GCA patients which causes the progression of the disease from PMR to GCA.

Understanding the relationship of PMR to GCA might represent an approach to elucidate the pathomechanisms in these diseases. We have recently addressed the question whether the progression to vasculitis is an HLA-linked phenomenon. However, immunogenetic studies have shown that distributions of HLA-DRB1 alleles in GCA and PMR are not distinct, suggesting that the pathomechanisms leading to the vasculitic complications are not controlled by a particular HLA-DR polymorphism (26, 27).

We have proposed that the vascular lesions in GCA resemble an antigen-driven response. This conclusion is based on the presence of identical and clonally expanded T cell specificities in different vasculitic foci of the same patient (5). A minority of CD4⁺ T cells in the vasculitic infiltrates has undergone proliferation, indicating that they have recently recognized antigen. Clonally expanded T cells were not detected in the peripheral blood, indicating that there is accumulation of such T cells in the tissue. These results predict that some T cells encounter antigen locally residing in the tissue, inducing the vasculitic manifestations. The data presented here support the view that an additional component of systemic monocyte activation exists. It is possible that the activation of circulating monocytes results from an immune response to the same antigen in other tissues than the temporal artery, e.g., lymph nodes and bone marrow. This model would raise the question whether PMR patients lack a mechanism necessary for antigen recognition in the arterial wall. Selected T cell specificities necessary for the development of vasculitis might not be represented in the repertoire of every individual, and their availability might define an additional risk factor in the development of GCA. Alternatively, separate activation mechanisms are involved in inducing IL-6 and IL-1 β in the majority of blood monocytes and the recruitment of inflammatory cells to the temporal artery.

The composition of tissue-infiltrating macrophages in the inflammatory response of GCA patients appears not to be unique but quite similar to those in virus-infected tissues (28). This raises the question of whether pathways leading to macrophage activation and recruitment are rather nonspecific. However, specificity may be introduced through the antigen and the antigen-specific T cells. The availability of selected T cell specificities might be the limiting factor in granuloma assembly in the temporal artery. Comparison of GCA and PMR patients would

be a unique approach to this question. Based on the data presented here, we propose that GCA has two components of disease, one of which is unique and is critical in granuloma formation, whereas the second one is shared with PMR and is involved in inducing cytokine gene expression in circulating monocytes.

Acknowledgments

The authors thank Toni L. Buss for secretarial assistance and Mr. M. Schreiber of the Section of Visual Information for assistance.

This work was supported in part by the Mayo Foundation and by a grant-in-aid from the American Heart Association. C. M. Weyand is the recipient of an Arthritis Investigator Award. A. D. Wagner is funded through the Deutsche Forschungsgemeinschaft.

References

1. Huston, K., G. Hunder, J. Lie, R. Kennedy, and L. Elveback. 1978. Temporal arteritis: a 25-year epidemiologic, clinical, and pathologic study. *Ann. Intern. Med.* 88:162-167.
2. Lie, J., and Members and Consultants of the American College of Rheumatology Subcommittee on Classification of Vasculitis. 1990. Illustrated histopathologic classification criteria for selected vasculitis syndromes. *Arthritis Rheum.* 33:1074-1087.
3. Hunder, G. G., J. T. Lie, J. J. Goronzy, and C. M. Weyand. 1993. Pathogenesis of giant cell arteritis. *Arthritis Rheum.* 36:757-761.
4. Hunder, G. G., D. A. Bloch, B. A. Michel, M. B. Stevens, W. P. Arend, L. H. Calabrese, S. M. Edworthy, A. S. Fauci, R. Y. Leavitt, J. T. Lie, et al. 1990. The American College of Rheumatology 1990 criteria for the classification of giant cell arteritis. *Arthritis Rheum.* 33:1122-1128.
5. Weyand, C. M., J. Schönberger, U. Oppitz, N. N. H. Hunder, K. C. Hicok, and J. J. Goronzy. 1994. Distinct vascular lesions in giant cell arteritis share identical T cell clonotypes. *J. Exp. Med.* 179:951-960.
6. Calamia, K. T., S. B. Moore, L. R. Elveback, and G. G. Hunder. 1981. HLA-DR locus antigens in polymyalgia rheumatica and giant cell arteritis. *J. Rheumatol.* 8:993-996.
7. Bignon, J. D., C. Ferec, J. Barrier, Y. Pennec, C. Verlingue, M. L. Cheneau, V. Lucas, J. Y. Muller, and J. P. Saleun. 1988. HLA class II genes polymorphism in DR4 giant cell arteritis patients. *Tissue Antigens.* 32:254-258.
8. Lowenstein, M. B., P. H. Bridgeford, F. B. Vasey, B. F. Germain, and L. R. Espinoza. 1983. Increased frequency of HLA-DR3 and DR4 in polymyalgia rheumatica-giant cell arteritis. *Arthritis Rheum.* 26:925-927.
9. Weyand, C. M., K. C. Hicok, G. G. Hunder, and J. J. Goronzy. 1992. The HLA-DRB1 locus as a genetic component in giant cell arteritis. Mapping of a disease-linked sequence motif to the antigen binding site of the HLA-DR molecule. *J. Clin. Invest.* 90:2355-2361.
10. Unanue, E. R. 1984. Antigen-presenting function of the macrophage. *Annu. Rev. Immunol.* 2:395-428.
11. Nathan, C. F. 1987. Secretory products of macrophages. *J. Clin. Invest.* 79:319-326.
12. Chuang, T.-Y., and G. G. Hunder. 1982. Polymyalgia rheumatica: a 10-year epidemiologic and clinical study. *Ann. Intern. Med.* 97:672-680.
13. Arnett, F. C., S. M. Edworthy, D. A. Bloch, D. J. McShane, J. F. Fries, N. S. Cooper, L. A. Healey, S. R. Kaplan, M. H. Liang, H. S. Luthra, et al. 1988. The American Rheumatism Association 1987 revised criteria for the classification of rheumatoid arthritis. *Arthritis Rheum.* 31:315-324.
14. Gold, K. N., C. M. Weyand, and J. J. Goronzy. 1994. Modulation of helper T cell function by prostaglandins. *Arthritis Rheum.* 37:925-933.
15. Pulford, K. A. F., E. M. Rigney, K. J. Mickletham, M. Jones, W. P. Stross, K. C. Gatter, and D. Y. Mason. 1989. KP1: a new monoclonal antibody that detects a monocyte/macrophage associated antigen in routinely processed tissue sections. *J. Clin. Pathol.* 42:414-421.
16. Welgus, H. G., E. J. Campbell, J. D. Cury, A. Z. Eisen, R. M. Senior, S. M. Wilhelm, and G. I. Goldberg. 1990. Neutral metalloproteinases produced by human mononuclear phagocytes. Enzyme profile, regulation, and expression during cellular development. *J. Clin. Invest.* 86:1496-1502.
17. Boros, D. L. The granulomatous inflammatory response: an overview. 1980. *In Basic and Clinical Aspects of Granulomatous Diseases.* D. L. Boros and T. Yoshida, editors. Elsevier/North Holland, New York. 1-14.
18. Bernaudin, J.-F., K. Yamauchi, M. D. Wewers, M. J. Tocci, V. J. Ferrans, and R. G. Crystal. 1988. Demonstration by *in situ* hybridization of dissimilar IL-1 β gene expression in human alveolar macrophages and blood macrophages in response to lipopolysaccharide. *J. Immunol.* 140:3822-3829.
19. Collier, I. E., S. M. Wilhelm, A. Z. Eisen, B. L. Marmor, G. A. Grant, J. L. Seltzer, A. M. Kronberger, C. He, E. A. Bauer, and G. I. Goldberg. 1988. Human bronchial epithelial cells respond to transformation with H-ras oncogene by secretion of a single metalloprotease capable of degrading basement membrane collagen. *J. Biol. Chem.* 263:6579-6587.
20. Roche, N. E., J. W. Fulbright, A. D. Wagner, G. G. Hunder, J. J. Goronzy, and C. M. Weyand. 1993. Correlation of interleukin-6 production and disease activity in polymyalgia rheumatica and giant cell arteritis. *Arthritis Rheum.* 36:1286-1294.
21. Dinarello, C. A. 1992. Interleukin-1 and tumor necrosis factor: effector cytokines in autoimmune diseases. *Semin. Immunol.* 4:133-145.
22. Dinarello, C. A. 1993. The role of IL-1 in disease. *N. Engl. J. Med.* 328:106-113.
23. Firestein, G. S., W.-D. Xu, K. Townsend, D. Broide, J. Alvaro-Gracia, A. Glasebrook, and N. J. Zvaifler. 1988. Cytokines in chronic inflammatory arthritis. I. Failure to detect T cell lymphokines (interleukin 2 and interleukin 3) and presence of macrophage colony-stimulating factor (CSF-1) and a novel mast cell growth factor in rheumatoid synovitis. *J. Exp. Med.* 168:1573-1586.
24. Xu, W. D., G. S. Firestein, R. Taetle, K. Kaushansky, and N. J. Zvaifler. 1989. Cytokines in chronic inflammatory arthritis. II. Granulocyte-macrophage colony-stimulating factor in rheumatoid synovial effusions. *J. Clin. Invest.* 83:876-882.
25. Guerne, P.-A., B. L. Zuraw, J. H. Vaughan, D. A. Carson, and M. Lotz. 1989. Synovium as a source of interleukin 6 *in vitro*. Contribution to local and systemic manifestations of arthritis. *J. Clin. Invest.* 83:585-592.
26. Weyand, C. M., N. N. H. Hunder, K. C. Hicok, G. G. Hunder, and J. J. Goronzy. 1994. HLA-DRB1 alleles in polymyalgia rheumatica, giant cell arteritis, and rheumatoid arthritis. *Arthritis Rheum.* 37:514-520.
27. Weyand, C. M., and J. J. Goronzy. 1994. Functional domains on HLA-DR molecules. Implications for the linkage of HLA-DR genes to different autoimmune diseases. *Clin. Immunol. Immunopathol.* 70:91-98.
28. Devergne, O., M. Peuchmaur, M. Humbert, E. Navratil, M. B. Leger-Ravet, M. C. Crevon, M. A. Petit, P. Galanaud, and D. Emilie. 1991. *In vivo* expression of IL-1 β and IL-6 genes during viral infections in human. *European Cytokine Network.* 2:183-194.