

## Spontaneous Hepatic Copper Accumulation in Long-Evans Cinnamon Rats with Hereditary Hepatitis

### A Model of Wilson's Disease

Yu Li,<sup>\*,†</sup> Yuji Togashi,<sup>\*</sup> Shin Sato,<sup>§</sup> Tadasu Emoto,<sup>§</sup> Jong-Hon Kang,<sup>\*</sup> Noritoshi Takeichi,<sup>\*</sup> Hiroshi Kobayashi,<sup>\*</sup> Yutaka Kojima,<sup>§</sup> Yoshie Une,<sup>‡</sup> and Junichi Uchino<sup>‡</sup>

<sup>\*</sup>Laboratory of Pathology, Cancer Institute, Hokkaido University School of Medicine; <sup>§</sup>Department of Environmental Medicine, Graduate School of Environmental Science, Hokkaido University; and <sup>‡</sup>First Department of Surgery, Hokkaido University School of Medicine, Sapporo 060, Japan

### Abstract

Long-Evans Cinnamon (LEC) rats, an inbred strain of a mutant rat isolated from Long-Evans rats, develop hereditary hepatitis. To elucidate the role of copper metabolism in the development of the hepatitis in LEC rats, we examined the copper concentration in the tissues and serum levels of copper and ceruloplasmin. Copper concentration in the liver of LEC rats was over 40 times that of normal Long-Evans Agouti (LEA) rats, while the serum ceruloplasmin and copper concentrations in LEC rats decreased significantly. The hepatocytes of LEC rats show steatosis in cytoplasm and pleomorphism of mitochondria, resembling the histologic features of the liver in Wilson's disease. These findings suggest that the hereditary hepatitis in LEC rats is closely associated with copper toxicity, and may be dealing with a rat form of Wilson's disease. Thus the LEC rats will provide a unique and useful animal model for clarifying the mechanism and for developing treatment strategies for Wilson's disease and other abnormal copper metabolism in humans. (*J. Clin. Invest.* 1991. 87:1858-1861.) **Key words:** fulminant hepatic failure • trace metal • copper toxicity • metabolism • genetic disorder

### Introduction

Long-Evans Cinnamon (LEC)<sup>1</sup> rats, an inbred strain of a mutant rat that was originally isolated from a closed colony of Long-Evans rats, develop acute hepatitis ~ 4 mo after birth (1, 2). Those rats that survive acute hepatitis suffer from chronic hepatitis, and develop hepatocellular carcinoma from 1 yr after birth. The acute hepatitis resembles human fulminant hepatic failure both clinically and histopathologically. Although genetic analyses have revealed that the hepatitis is inherited by

autosomal recessive manner, the pathogenesis of hepatic disorders in LEC rats has not yet been clarified (1-3).

Wilson's disease, one of the hereditary hepatic diseases in human (4), is also known to be caused by an autosomal recessive disorder (5). The most characteristic feature of Wilson's disease is the accumulation of copper in tissues, particularly those of the liver and brain (6); in some patients the disease takes a clinical course which can hardly be distinguished from fulminant hepatic failure (7-9). Noting the similarity in the inheriting manners as well as the clinical features of LEC rat hepatitis and human Wilson's disease, we examined the copper concentration in LEC rat tissues and serum, as well as the serum level of ceruloplasmin and the histological and clinical changes related to copper toxicity.

### Methods

The LEC rats were maintained under normal conditions at the Center for Experimental Plants and Animals of Hokkaido University, Sapporo, Japan. The details of the origin, maintenance, and breeding history of the LEC rats have been previously described (1, 2). Long-Evans Agouti (LEA) rats, which are a sibling line of LEC rats and do not develop hepatitis and hepatocellular carcinoma, were used as a control. The LEC and LEA rats used in this study were at 50th and 49th generation of brother-sister mating, respectively. The LEC rats will be available on a commercial basis from Charles River Japan, Inc., Kanagawa, as of spring, 1991.

We used male and female LEC rats aged 2 d and 3 mo that had not yet developed acute hepatitis, and those aged 8 mo with chronic hepatitis. The animals were killed under ether anesthesia and blood was taken from the inferior vena cava. The liver, kidney, and brain were quickly removed, weighed, and frozen-stored at -80°C. Sera were separated and frozen-stored at -20°C. The tissues were wet ashed with nitric, perchloric, and sulfuric acid, and copper concentrations were determined with an atomic absorption spectrophotometer (Model 180-30; Hitachi Ltd., Tokyo, Japan). The sera were diluted with 0.1% Triton X-100 (Wako, Osaka, Japan), and the copper concentrations were determined with a polarized Zeeman atomic absorption spectrophotometer (Model Z-8100; Hitachi). The serum ceruloplasmin concentration was measured as a serum oxidase activity by the method of Schosinsky et al. (10): samples were mixed with the optimal concentration of *o*-dianisidine dihydrochloride (7.88 mM) in 0.1 M acetate buffer (pH 5.0), and the absorption at 540 nm was measured. The oxidase activity was calculated as follows: activity (U/liter) = (absorption at 15 min - absorption at 5 min) × 625. For histochemical examinations, the paraffin sections were made from the livers and stained with rhodanine and orcein. The sections of freshly frozen liver tissue were stained with Sudan III. For electron microscopy, the Epok-812 embedded sections

Address correspondence to Dr. Yu Li, Laboratory of Pathology, Cancer Institute, Hokkaido University School of Medicine, Sapporo 060, Japan.

Received for publication 29 October 1990 and in revised form 18 December 1990.

1. Abbreviations used in this paper: LEA, Long-Evans Agouti; LEC, Long-Evans Cinnamon.

*J. Clin. Invest.*

© The American Society for Clinical Investigation, Inc.

0021-9738/91/05/1858/04 \$2.00

Volume 87, May 1991, 1858-1861

were made from the livers and stained with uranyl acetate and lead citrate, and observed by Hitachi H-800 microscope.

The statistical significance was evaluated by Student's *t* test. The experiments were approved by the Animal Care and Use Committee of our institution.

## Results

Table I shows that copper had accumulated more densely in the liver of all the LEC rats than in the liver of age- and sex-matched LEA rats; the respective concentration values of 3- and 8-mo old LEC rats were over 50 and 40 times higher than those of age- and sex-matched LEA rats. Copper concentration in the brain was significantly low in 3-mo old LEC rats, both male and female, but high in 8-mo old male LEC rats compared with those in age- and sex-matched LEA rats. Although copper concentration in the kidney was higher in 8-mo old LEC rats than in LEA rats, there was no statistically significant difference between the two strains (Table II).

Ceruloplasmin is a glycoprotein containing 90–95% of the copper in the serum. In both 3- and 8-mo old LEC rats, the serum levels of ceruloplasmin and copper decreased significantly (Table III).

The hepatocytes in all specimens of LEC rat liver were stained by neither rhodanine nor orcein, but rhodanine and orcein positive granules were found infrequently in the Kupffer cells of LEC rats with chronic hepatitis. Sudan III staining revealed steatosis in the hepatocytes of LEC rats (Fig. 1), while ultrastructural examination revealed lipid droplets in cytoplasm and a striking pleomorphism of mitochondria in the hepatocytes (Fig. 2).

Neurological symptoms often appear in untreated patients with Wilson's disease (8, 9). Some LEC rats aged between 8 and 12 mo occasionally went into convulsion whereas no LEA rats showed this symptom. The Kayser-Fleischer ring in the cornea was not detected macroscopically in LEC rats until 8 mo after birth.

## Discussion

Shortly before the onset of hepatitis, the copper concentration in the liver of 3-mo old LEC rats reached a toxic level. Recently, Togashi et al. found that an oral administration of D-penicillamine, a chelating agent that is widely used in the treat-

Table II. Copper Concentration in the Kidney and Brain of LEC and LEA Rats

Sex	Age	Copper concentration in kidney		Copper concentration in brain	
		LEC	LEA	LEC	LEA
		μg/g wet wt		μg/g wet wt	
Male	3 mo	5.13±0.24	7.08±1.51	1.37±0.07*	1.91±0.03
	8 mo	14.53±3.27	5.37±0.82	2.70±0.04*	1.99±0.09
Female	3 mo	8.95±3.13	6.35±0.31	1.51±0.07*	2.16±0.04
	8 mo	13.04±4.02	6.96±1.08	3.58±0.96	2.30±0.24

Copper concentration was determined by atomic absorption spectrophotometry. Data are means±SE with three rats. \* *P* < 0.005 vs. age- and sex-matched LEA rats.

ment of Wilson's disease, has completely inhibited the development of the hepatitis and that it reduced hepatic copper level in LEC rats (unpublished observation). These findings suggest that the development of hepatitis in LEC rats is closely related to the copper toxicity.

The copper profile in LEC rats, including copper accumulation in the liver and the reduction of serum level of ceruloplasmin, closely resembles that in human Wilson's disease. The lipid deposition and mitochondria changes in hepatocytes of LEC rats are similar to the characteristic histologic features of the liver in Wilson's disease (8, 9). Neither histochemical rhodanine staining for copper nor orcein staining for copper-associated protein was positive for hepatocytes in LEC rats. These stainings are also negative for hepatocytes in the majority of cases of Wilson's disease (8, 9); this phenomenon is possibly due to a diffusely distributed copper in the cytosol of hepatocytes (11). Both the hepatitis in LEC rats and Wilson's disease are inherited by autosomal recessive manner, and the clinical feature in LEC rats resembles that of hepatic crisis in Wilson's disease. These important similarities between the hepatitis in LEC rats and Wilson's disease suggest that the hepatitis in LEC rats may be dealing with a rat form of Wilson's disease.

It has been reported that there is a close linkage between

Table I. Copper Concentration in the Liver of LEC and LEA Rats

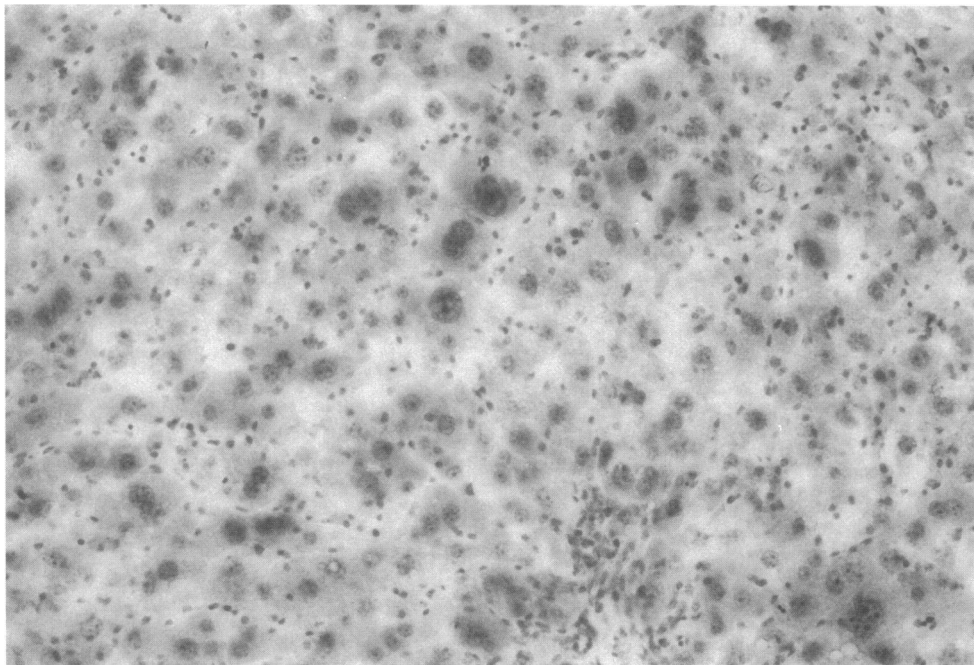
Sex	Age	Copper concentration	
		LEC	LEA
		μg/g wet wt	
Male	2 d	148.0±6.8*	49.51±0.97
	3 mo	183.8±24.9†	3.46±0.13
	8 mo	213.4±3.3*	3.37±0.04
Female	2 d	151.1±10.4*	48.06±2.28
	3 mo	282.9±51.7†	2.90±0.10
	8 mo	152.7±27.4†	3.25±0.15

Copper concentration was determined by atomic absorption spectrophotometry. Data are means±SE with three rats. \* *P* < 0.001; † *P* < 0.05 vs. age- and sex-matched LEA rats.

Table III. Ceruloplasmin and Copper Concentrations in the Serum of LEC and LEA Rats

Sex	Age	Ceruloplasmin concentration		Copper concentration	
		LEC	LEA	LEC	LEA
		U/liter		μg/dl	
Male	2 d	ND	ND	52.3±11.0	57.0±1.5
	3 mo	0.9±0.5*	162.2±7.2	38.0±11.0†	135.7±2.3
	8 mo	15.0±9.5*	175.0±4.1	52.7±2.4†	137.3±7.2
Female	2 d	ND	ND	50.0±12.0	68.7±8.1
	3 mo	3.1±0.8*	195.8±7.5	31.3±2.1†	158.0±2.7
	8 mo	7.1±0.2*	214.3±19.9	47.3±3.8†	161.3±9.7

Ceruloplasmin concentration was determined as a serum oxidase activity. Copper concentration was determined by atomic absorption spectrophotometry. Data are means±SE with three rats. † *P* < 0.001; \* *P* < 0.005 vs. age- and sex-matched LEA rats.

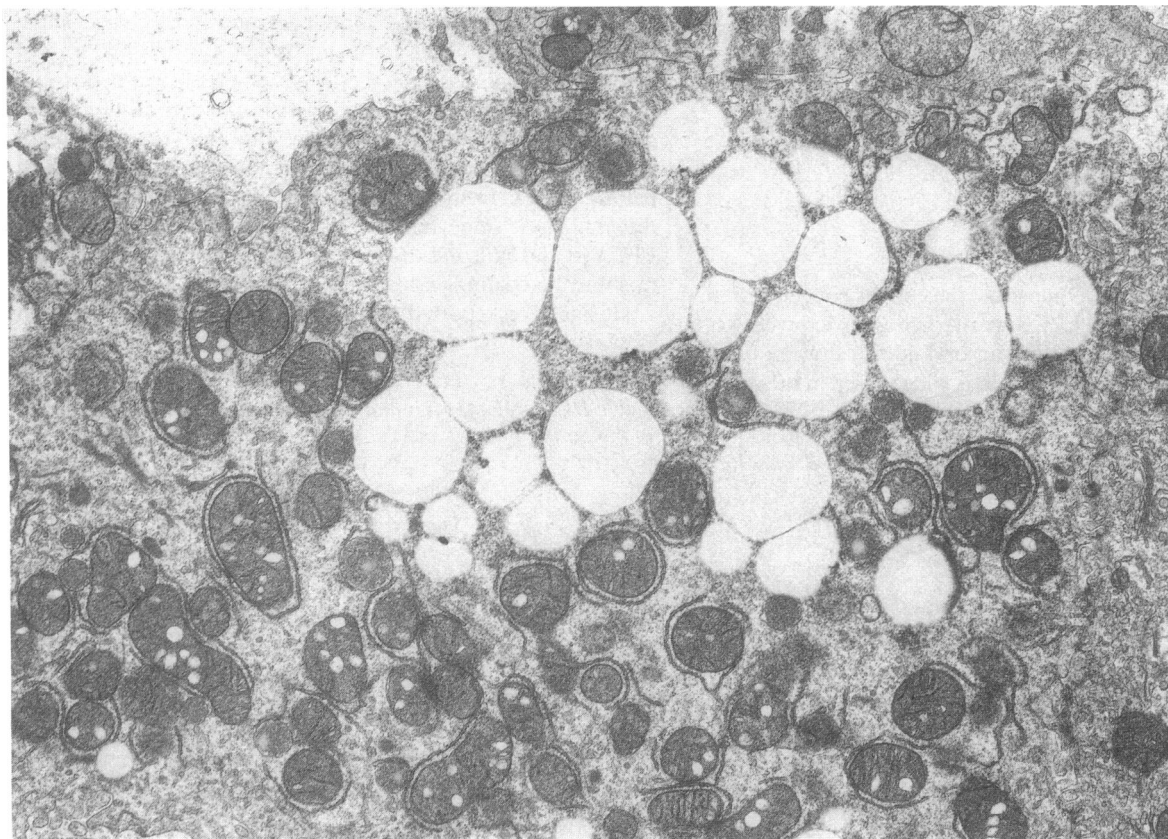


*Figure 1.* Histochemical stain of liver from 5-mo old female LEC rats. Hepatocytes stain intensely with Sudan III indicating an abundance of lipid droplets. Sudan III,  $\times 200$ .

esterase D gene locus and the gene that causes Wilson's disease on chromosome 13 (12). Matsumoto et al. have recently found in LEC rats new esterases that are associated with the development of hepatitis (13). Their finding may support our observa-

tion, although further investigation of genetic linkage will be needed.

On the other hand, there are some differences between the disorders in LEC rats and Wilson's disease: the huge and "bi-



*Figure 2.* Electron micrograph of liver from 7-mo old female LEC rats. Hepatocyte contains numerous lipid droplets in cytoplasm. Mitochondria show striking pleomorphism with electron-lucent vacuoles ( $\times 3,000$ ).

zarre" nuclei of hepatocytes in LEC rats (2, 3) differ from the ballooned glycogen nuclei of hepatocytes in Wilson's disease. The liver disorder in the rats with chronic hepatitis results in cholangiofibrosis (2), which is not the same as liver cirrhosis found in Wilson's disease. These differences may be due to different tissue repairing responses to copper toxicity in rats and men. LEC rats which have survived for more than one year have a high incidence of hepatocellular carcinoma (14). Although only a few cases of hepatocellular carcinoma have been reported in patients with Wilson's disease (8, 9, 15), our results suggest that the abnormal copper metabolism in LEC rats may be involved in hepatic carcinogenesis. The mechanism of hepatic copper accumulation in LEC rats remains unclear; we need to investigate the absorption of copper from gut, its excretion into bile and its binding proteins.

Although reports have indicated that, in Wilson's disease, both biliary excretion of copper and its incorporation into ceruloplasmin are impaired (16, 17), the primary defect is unknown (8, 9, 18). Although treatment with chelating agents (19, 20) is very effective in the early stage, the disease is drug-resistant and has a poor prognosis both when acute hepatic crisis occurs and when it is in the advanced stage (8, 9). Animals have rarely been known to develop hereditary hepatic disorders with copper accumulation (21, 22). In toxic milk mice, the pups fed with their mother's milk show a reduced hepatic copper level and copper deficiency symptoms, but those fed with the milk of a normal female accumulate copper in the liver (23, 24). Although many Bedlington terriers show a congenital gross copper accumulation in the liver, they show normal or elevated plasma ceruloplasmin levels and do not develop characteristic neurological disturbance (25, 26). The LEC rats therefore will offer a unique and useful animal model for studies of Wilson's disease and other abnormal copper metabolism, including the clarification of the pathogenesis and development of treatment strategies.

## Acknowledgments

We thank Dr. Y. Fujioka and Dr. K. Nagashima for helpful discussions, and Ms. M. Yanome for preparation of the manuscript.

## References

1. Sasaki, M., M. C. Yoshida, K. Kagami, N. Takeichi, H. Kobayashi, K. Dempo, and M. Mori. 1985. Spontaneous hepatitis in an inbred strain of Long-Evans rats. *Rat News Letter*. 14:4-6.
2. Yoshida, M. C., R. Masuda, M. Sasaki, N. Takeichi, H. Kobayashi, K. Dempo, and M. Mori. 1987. New mutation causing hereditary hepatitis in the laboratory rat. *J. Hered.* 78:361-365.
3. Takeichi, N., H. Kobayashi, M. C. Yoshida, M. Sasaki, K. Dempo, and M. Mori. 1988. Spontaneous hepatitis in Long-Evans rats: a potential animal model for fulminant hepatitis in man. *Acta Pathol. Jpn.* 38:1369-1375.
4. Wilson, S. A. K. 1912. Progressive lentacular degeneration: a familiar nervous disease associated with cirrhosis of the liver. *Brain*. 34:295-509.
5. Bearn, A. G. 1953. Genetic and biochemical aspects of Wilson's disease. *Am. J. Med.* 15:442-449.
6. Cumings, J. N. 1948. The copper and iron content of brain and liver in the normal and in hepatolenticular degeneration. *Brain*. 71:410-415.
7. Roche-Sicot, J., and J-P. Benhamou. 1977. Acute intravascular hemolysis and acute liver failure associated as a first manifestation of Wilson's disease. *Ann. Intern. Med.* 86:301-303.
8. Walshe, J. M. 1987. The liver in Wilson's disease (hepatolenticular degeneration). In *Diseases of the Liver*. L. Schiff and E. R. Schiff, editors. J. B. Lippincott Co., Philadelphia. 1037-1050.
9. Gollan, J. L. 1989. Copper metabolism, Wilson's disease, and hepatic copper toxicosis. In *Hepatology*. D. Zakim and T. D. Boyer, editors. W. B. Saunders Co., Philadelphia. 1249-1272.
10. Schosinsky, K. H., H. P. Lehmann, and M. F. Beeler. 1974. Measurement of ceruloplasmin from its oxidase activity in serum by use of *o*-dianisidine dihydrochloride. *Clin. Chem.* 20:1556-1563.
11. Nartey, N. O., J. V. Frei, and M. G. Cherian. 1987. Hepatic copper and metallothionein distribution in Wilson's disease (hepatolenticular degeneration). *Lab. Invest.* 57:397-401.
12. Frydman, M., B. Bonn -Tamir, L. A. Farrer, P. M. Conneally, A. Magazanik, S. Ashbel, and Z. Goldwicht. 1985. Assignment of the gene for Wilson disease to chromosome 13: linkage to the esterase D locus. *Proc. Natl. Acad. Sci. USA*. 82:1819-1821.
13. Matsumoto, K., E. Ono, K. Izumi, H. Otsuka, M. C. Yoshida, M. Sasaki, N. Takeichi, and H. Kobayashi. 1987. Expression of new esterases and pathologic profiles in LEC rats with spontaneous fulminant hepatitis. *Transplant Proc.* 19:3207-3211.
14. Masuda, R., M. C. Yoshida, M. Sasaki, K. Dempo, and M. Mori. 1988. High susceptibility to hepatocellular carcinoma development in LEC rats with hereditary hepatitis. *Jpn. J. Cancer Res.* 79:828-835.
15. Polio, J., R. E. Enriquez, A. Chow, W. M. Wood, and C. E. Atterbury. 1989. Hepatocellular carcinoma in Wilson's disease. *J. Clin. Gastroenterol.* 11:220-224.
16. Frommer, D. J. 1974. Defective biliary excretion of copper in Wilson's disease. *Gut*. 15:125-129.
17. Sternlieb, I., and I. H. Scheinberg. 1979. The role of the radio copper in the diagnosis of Wilson's disease. *Gastroenterology*. 77:138-142.
18. Editorial. 1989. Homing in on Wilson's disease. *Lancet*. i:822-823.
19. Walshe, J. M. 1956. Penicillamine, a new oral therapy for Wilson's disease. *Am. J. Med.* 21:487-495.
20. Walshe, J. M. 1982. Treatment of Wilson's disease with trientine (triethylene tetramine) dihydrochloride. *Lancet*. i:643-647.
21. Danks, D. M. Of mice and men, metals and mutations. *J. Med. Genet.* 23:99-106.
22. Schilsky, M. L., R. R. Blank, M. J. Czaja, M. A. Zern, I. H. Scheinberg, R. J. Stockert, and I. Sternlieb. 1989. Hepatocellular copper toxicity and its attenuation by zinc. *J. Clin. Invest.* 84:1562-1568.
23. Rauch, H. 1983. Toxic milk, a new mutation affecting copper metabolism in the mouse. *J. Hered.* 74:141-144.
24. Biempica, L., H. Rauch, N. Quintana, and I. Sternlieb. 1988. Morphologic and chemical studies on a murine mutation (toxic milk mice) resulting in hepatic copper toxicosis. *Lab. Invest.* 59:500-508.
25. Hardy, R. M., J. B. Stevens, and C. M. Stowe. 1975. Chronic progressive hepatitis in Bedlington terriers associated with elevated liver copper concentrations. *Minn. Vet.* 15:13-24.
26. Su, L.-C., S. Ravanshad, C. A. Owen, Jr., J. T. McCall, P. E. Zollman, and R. M. Hardy. 1982. A comparison of copper-loading disease in Bedlington terriers and Wilson's disease in humans. *Am. J. Physiol.* 243:G226-230.