

Published in final edited form as:

*Hirosaki Igaku*. 2010 July 8; 61(Suppl): S111–S124.

## CEREBRAL AMYLOID ANGIOPATHY AND ALZHEIMER'S DISEASE

Jorge Ghiso<sup>1),2)</sup>, Yasushi Tomidokoro<sup>3)</sup>, Tamas Revesz<sup>4)</sup>, Blas Frangione<sup>1),2)</sup>, and Agueda Rostagno<sup>1)</sup>

<sup>1)</sup> Department of Pathology, New York University School of Medicine, New York, U.S.A

<sup>2)</sup> Department of Psychiatry, New York University School of Medicine, New York, U.S.A

<sup>3)</sup> Department of Clinical Sciences, Tsukuba University, Tsukuba, Japan

<sup>4)</sup> Queen Square Brain Bank for Neurological Disorders, Department of Molecular Neuroscience, UCL Institute of Neurology, University College London, London, United Kingdom

### Abstract

Cerebral amyloid angiopathy (CAA) is increasingly recognized as a major contributor of Alzheimer's disease (AD) pathogenesis. To date, vascular deposits and not parenchymal plaques appear more sensitive predictors of dementia. Amyloid deposition in and around cerebral blood vessels plays a central role in a series of response mechanisms that lead to changes in the integrity of the blood-brain barrier, extravasations of plasma proteins, edema formation, release of inflammatory mediators and matrix metalloproteases which, in turn, produce partial degradation of the basal lamina with the potential to develop hemorrhagic complications. The progressive buildup of amyloid deposits in and around blood vessels chronically limits blood supply and causes focal deprivation of oxygen, triggering a secondary cascade of metabolic events several of which involve the generation of nitrogen and oxygen free radicals with consequent oxidative stress and cell toxicity. Many aspects of CAA in early- and late-onset AD –the special preference of A $\beta$ 40 to deposit in the vessel walls, the favored vascular compromise associated with many A $\beta$  genetic variants, the puzzling observation that some of these vasculotropic variants solely manifest with recurrent hemorrhagic episodes while others are mainly associated with dementia– await clarification. Non-A $\beta$  cerebral amyloidoses reinforce the viewpoint that plaque burden is not indicative of dementia while highlighting the relevance of nonfibrillar lesions and vascular involvement in the disease pathogenesis. The lessons learned from the comparative study of A $\beta$  and non-A $\beta$  cerebral amyloidosis provide new avenues and alternative models to study the role of amyloid in the molecular basis of neurodegeneration.

---

Alzheimer's disease (AD) is the most common form of dementia in humans over the age of 65, affecting more than 50% of individuals 85 or older. It is a debilitating neurodegenerative disorder that affects millions of people constituting one of the major Public Health concerns in all developed countries. Neuropathological hallmarks of AD are the presence of intraneuronal neurofibrillary tangles (NFT)-deposits of hyperphosphorylated protein tau in the form of paired helical filaments-together with the existence of parenchymal extracellular deposits composed of both diffuse pre-amyloid lesions and mature amyloid plaques. Although its significance was ignored for decades, together with these lesions, fibrillar amyloid deposition is also commonly observed in medium-sized and small cerebral vessels,

a feature known as Cerebral Amyloid Angiopathy (CAA). Cerebrovascular and parenchymal lesions are composed of self-aggregates of A $\beta$  protein generated by proteolytic cleavage of a larger precursor APP by the so-called  $\beta$  and  $\gamma$  secretases<sup>1-3</sup>. In difference to  $\beta$ -secretase, the multiprotein  $\gamma$  secretase complex has broader specificity and is able to cleave APP at multiple sites within its transmembrane domain generating A $\beta$  peptides ranging in length from 38 to 42 residues<sup>4</sup>. Nearly 90% of secreted A $\beta$  ends at residue 40, whereas A $\beta$ 42 accounts for only <10%, and peptides ending at residues 38 are minor components<sup>5</sup>. Notably, the pattern and distribution of these species varies among the different topographical lesions. Parenchymal deposits consist of A $\beta$ 42 as the major component, whereas vascular A $\beta$ -particularly in the large leptomeningeal vessels - is primarily composed of A $\beta$ 40 species organized in large concentric sheets and replacing the smooth muscle cell layer<sup>6</sup>. Amyloid associated with arterioles and small cortical arteries contains a mixture of A $\beta$ 40 and A $\beta$ 42, while deposits affecting the capillary network are mainly composed of A $\beta$ 42<sup>7</sup>. The reasons for this selectivity as well as its importance for the pathogenesis of the disease remain unclear.

### A $\beta$ and non-A $\beta$ CAA genetic variants

Although the most common protein associated with amyloid deposition in the vasculature is by far A $\beta$  present in sporadic late-onset AD as well as in normal aging, numerous hereditary conditions are known today which primarily associate with CAA. These familial diseases are characterized by the presence of genetic variants of both A $\beta$  and non-A $\beta$  proteins as the main components of the CAA deposits. Among the many A $\beta$  variants described today, those located in the hot spot comprised between positions 21-23 typically show strong vascular compromise and primarily associate with CAA, hemorrhagic strokes and dementia. The first described and likely the most studied of these variants is A $\beta$ E22Q, found in a condition known as hereditary cerebral hemorrhage with amyloidosis, Dutch type (HCHWA-Dutch)<sup>8,9</sup>. Carriers of the mutation develop recurrent episodes of cerebral hemorrhages correlating with massive amyloid deposition in the walls of leptomeningeal and cortical arteries and arterioles as well as in vessels in the brainstem and cerebellum<sup>10</sup>, a phenotype recapitulated, albeit at old age, in transgenic mice carrying the mutation<sup>11</sup>. In addition to the vascular involvement, parenchymal amyloid deposits resembling the diffuse preamyloid lesions seen in AD are also observed in Dutch familial cases, while dense-core plaques and neurofibrillary tangles are rare or even completely absent<sup>8</sup>.

To the moment, of the dozen of A $\beta$  genetic variants reported half of them are located within the 21-23 amino acid cluster. Interestingly, only one of the intra-A $\beta$  variants located outside this region of the molecule -the L34V Piedmont mutant- associates with cerebral hemorrhage and exhibits a comparable, albeit less aggressive, clinical phenotype to A $\beta$ E22Q. The clinical features of the disease include recurrent hemorrhagic strokes, weakness and paresthesias together with confusional states. Cognitive impairment is infrequent as a presenting symptom but is observed after various episodes of intracerebral hemorrhages. Neuropathological examination of the few available cases showed severe CAA with compromise of small and medium-size arteries as well as capillaries in all lobes of the brain, particularly the occipital and cerebellar regions. The vascular involvement includes vessel-within-the-vessel configurations, microhemorrhages, microaneurisms, microthrombi, and lymphocytic infiltration of the vessel walls. Diffuse and dense-cored plaques as well as neurofibrillary pathology were notably absent<sup>12</sup>.

A number of familial forms of CAA are caused by deposition of non-A $\beta$  amyloid proteins. The deposited molecules comprise an array of different molecules including cystatin C, gelsolin, transthyretin, prion, and BRI-2 related proteins. For space constraints we will limit our review to two of these categories which exemplify the striking diverse clinical

phenotypes associated with CAA. In one extreme cystatin C-CAA, which correlates with massive cerebral hemorrhages in the other end, BRI2-related dementias, which in spite of the severe vascular involvement, correlates only with cognitive impairment in total absence of hemorrhagic episodes.

### Cystatin C-related cerebral amyloidosis

Hereditary cerebral hemorrhage with amyloidosis, Icelandic type (HCHWA-Icelandic), is a disorder described in individuals from small rural communities of Iceland<sup>13</sup>. The disease is associated with a point mutation that translates into a Leu for Gln change at position 68 of cystatin C<sup>14</sup>, a ubiquitously expressed inhibitor of cysteine proteases. The 110-residue-long amyloid subunit constituting the amyloid deposits not only bears the mutated amino acid residue but it is also degraded at the N terminus, starting at position 11 of the normal cystatin C<sup>15,16</sup>. The main clinical hallmark of the disease is cerebral hemorrhage with fatal outcome in the third to fourth decade of life in approximately 50% of the cases. Cognitive decline followed by dementia may occur in those cases that survive the hemorrhagic episodes. Neuropathologically, the mutation is associated with massive amyloid deposition within small arteries and arterioles of leptomeninges, cerebral cortex, basal ganglia, brainstem, and cerebellum. Although brain involvement is the main clinicopathological feature, silent amyloid deposits have also been described in peripheral tissues, such as skin, lymph nodes, spleen, salivary glands, and seminal vesicles.

The biochemical and structural properties of the variant form of cystatin C have been extensively studied. The mutated residue is located within the hydrophobic core of the protein and the amino acid substitution affects the stability of the molecule destabilizing alpha-helical structures and yielding a more unfolded molecule with higher tendency to form dimeric assemblies compared with the wild type counterpart<sup>17</sup>. The crystal structure of the molecule revealed that dimerization occurs through 3-dimensional domain swapping<sup>18</sup> and, in turn, through dimer association, results in the formation of larger amyloid-like structures with involvement of intermolecular  $\beta$ -sheet interactions<sup>19</sup>. The N-terminal truncation of the molecule found *in vivo* in the amyloid deposits of the Icelandic patients seems not to be crucial for the overall domain-swapped dimer formation; however the absence of the N-terminal decapeptide appears to facilitate the subsequent association of the protein via  $\beta$ -sheet interactions through intermolecular contacts<sup>20</sup>.

### BRI2 gene-related dementias

This novel group of hereditary disorders, also known as chromosome 13 dementias, and composed of familial British and Danish dementias (FBD and FDD, respectively), presents with cognitive impairment as one of the main defining clinical phenotypes<sup>21,22</sup>. Both diseases, share many features with AD including the presence of neurofibrillary tangles, parenchymal preamyloid and amyloid deposits, extensive cerebral amyloid angiopathy and a variety of co-localized amyloid-associated proteins and inflammatory components. These early-onset conditions, as described below, are linked to specific mutations at or near the stop codon of the *BRI2* gene that cause generation of longer-than-normal protein products.

Interesting new findings have demonstrated a cross-talk between BRI2 and APP that could bring new lights into the molecular mechanisms underlying neurodegeneration. Although BRI2 has still an unknown function, it was recently shown to specifically interact with APP. As a result of this binding interaction BRI2 masks the cleavage sites of  $\beta$ - and  $\alpha$ -secretase on APP and the  $\gamma$ -secretase docking site on the APP C-terminal fragment C99. As a consequence, BRI2 modulates APP processing inhibiting A $\beta$  formation and deposition properties, a feature observed in both cell culture and mouse models of AD<sup>23–26</sup>.

**Familial British dementia**—This hereditary disorder is the first described cerebral amyloidosis in the Western world<sup>27</sup> and affects an extensive pedigree of British origin which spans over nine generations<sup>21</sup>. The disease presents typically around the fifth decade of life, being its earliest manifestations personality changes followed by cerebellar ataxia and spastic paralysis. In the end, all patients progress to a chronic vegetative state becoming mute, unresponsive, quadriplegic, and incontinent. Neuropathologically, FBD cases exhibit severe and widespread amyloid angiopathy of the brain and spinal cord and characteristic perivascular changes including abundant vessel-associated-amyloid plaques. Notably, despite the extensive amyloid deposition in the vasculature, large intracerebral hemorrhage is a rare feature. Neuritic and non-neuritic amyloid plaques affect cerebellum, hippocampus, amygdala, and occasionally, cerebral cortex. Neurofibrillary degeneration is indistinguishable from that observed in AD cases. As it occurs in other forms of non-A $\beta$  cerebral amyloidosis, FBD presents systemic thioflavin-S-positive deposits in many organs<sup>28</sup>; however, this systemic deposition appears to be asymptomatic since clinical phenotypes of all described cases are only related to the cerebral compromise.

The disease is associated with a T to A substitution at codon 267 of *BR12* which results in the presence of an Arg residue in place of the stop codon normally occurring in the wild-type precursor molecule and a longer open-reading frame of 277 amino acids instead of 266<sup>29</sup>. Furin-like processing of this longer precursor releases a 34 amino acids-long C-terminal fragment, named ABri, which is found constituting the characteristic cerebral and systemic deposits in FBD<sup>28,29</sup>.

**Familial Danish dementia**—Familial Danish dementia (FDD) is an early onset disorder originating in the Djursland peninsula in Denmark and also associated with a genetic mutation in the *BR12* gene<sup>30</sup>. A 10-nucleotide duplication insertion mutation between codons 265 and 266 abolishes the normal stop codon and results, as in the case of FBD, in an extended precursor protein composed of 277 amino acids instead of the normal 266<sup>30,31</sup>. The 34-amino-acid-long C-terminal peptide ADan, as the ABri counterpart, is cleaved from the mutated precursor protein by a furin-like process, and readily forms the deposited amyloid fibrils. The disease, identified in a single family and spanning three generations, is clinically characterized by the development of cataracts, hearing loss and progressive cerebellar ataxia before the age of 40 with subsequent paranoid psychosis and dementia. Death occurs in most patients during their fifth or sixth decade. Neuropathological characteristics, similarly to those seen in FBD, include widespread amyloid angiopathy and severe neurofibrillary compromise which is more pronounced than that seen in FBD. Abnormal neurites, as seen in some other forms of CAA, mainly cluster around the vascular deposits and are absent around nonfibrillar diffuse parenchymal lesions<sup>32</sup>.

An interesting feature observed in FDD cases is the deposition of variable amounts of A $\beta$  in blood vessels and, to a lesser extent, in brain parenchyma in the form of pre-amyloid deposits, either in combination with ADan or in isolated lesions<sup>33</sup>. Biochemical analysis of brain extracted amyloid revealed that CAA deposited A $\beta$  is an N-terminal truncated form of A $\beta$ 42, a surprising finding in view of the prevalence of A $\beta$  ending at position 40 in vascular deposits observed in sporadic and familial AD, Down syndrome, and normal aging<sup>34</sup>. Detailed mass spectrometry analysis of extracted brain amyloid revealed that the deposited ADan species, similarly to the ABri counterparts, are post-translationally modified at the N-terminus<sup>28,34</sup>, as described in detail below.

## Biochemical features of CAA deposits

The biochemical composition of the amyloid lesions has been assessed at the molecular level in only a few instances, being the A $\beta$ -Dutch deposits perhaps the most thoroughly

studied<sup>35, 36</sup>. The currently available data indicate that all CAA deposits share a number of biochemical similarities irrespective of the nature of the primary component of the deposits being the high heterogeneity one of the most striking characteristics.

### Co-deposition of mutated and wild type subunits

Familial cases associated with specific mutations exhibit a remarkable co-deposition of mutated and non-mutated species, a feature observed in A $\beta$  hereditary forms<sup>36</sup> and prion diseases<sup>37</sup>, as well as in systemic forms of amyloidosis<sup>38–42</sup>. It is likely that the deposition of the respective mutated species exerts a seeding effect –or a conformational mimicry– enhancing the fibrillization and subsequent co-deposition of the wild type counterparts, as previously proposed<sup>34,43,44</sup>. Other common finding among the different familial CAA forms is the presence of numerous post-translational modifications, and an abundance of associated components, known as amyloid associated proteins.

### Post-translational modifications

Among the many post translational modifications identified in cerebral amyloidoses, phosphorylation, isomerization, racemization, oxidation and cyclation occurring in conjunction with proteolytic fragmentation are the most relevant<sup>6,28,34,45–48</sup>. Hyperphosphorylation is the most common post-translational modification of intracellular tau composing the paired helical filaments accumulating as NFTs in several neurodegenerative disorders<sup>49</sup>. Heavy isomerization and racemization of the aspartyl residues at positions 1 and 7 have been reported for A $\beta$  with more than half of the residues being composed of L-isoAsp in some AD cases<sup>45</sup>. A similar modification of Asp residues was found in the Iowa FAD variant cases<sup>50</sup>. Additional isomerization at Asp 23 was reported not only in sporadic AD<sup>51</sup> but also in Iowa patients<sup>52</sup>, although at a seemingly lower ratio than in the other positions. Our own biochemical studies showed that overall ~10 to 30% of the total deposited molecules in Iowa-brain tissues contain isoAsp23. In general terms, Asn deamidation with the consequent generation of isoAsp is associated with conformational changes and aging<sup>53,54</sup>. In this sense, not only do A $\beta$  molecules bearing isoAsp23 show enhanced *in vitro* fibrillization kinetics compared to wt molecules<sup>51</sup>, but the presence of isoAsp typically translates into a decreased sensitivity for proteolytic degradation<sup>55</sup>, features that may well contribute to disease pathogenesis.

Perhaps one of the most frequent post-translational modifications is the formation of N-terminal pyroglutamate which is also believed to confer resistance against N-terminal peptidases delaying and/or preventing their removal from the lesions. Interestingly, the formation of pyroglutamate seems to take place via two different molecular mechanisms according to the N-terminal amino acid involved. If the amino acid is glutamine, as observed with many immunoglobulin molecules, pyroglutamate arise through a process of deamination; however, if the N-terminus is aspartic acid, as seen in A $\beta$  species truncated at position 3 and 11 as well as in the ABri and ADan molecules, pyroglutamate formation occurs through a process of dehydration<sup>28,34</sup>. According to some reports, pyroglutamate-containing peptides account for more than 50% of the truncated A $\beta$  species accumulated in plaques, being particularly enriched with A $\beta$ 3(pE)40/42<sup>46,56</sup>, a component not only present in senile plaques but also in pre-amyloid lesions<sup>57</sup>. A $\beta$ 3(pE) appears more resistant than full-length peptides to proteolytic cleavage *in vitro*, confers enhanced tendency to oligomerization<sup>58</sup>, and exerts higher toxicity for both neuronal and glial cell cultures<sup>59</sup>. Pyroglutamate derivatives of A $\beta$  are not major species in plasma or CSF, suggesting that their formation takes place at the site of deposition. In cases of familial British and Danish dementias, circulating ABri and ADan peptides feature only glutamate at their N-terminus whereas their pyroglutamate counterparts are the heavily dominant species in the amyloid deposits. Since the conversion to pyroglutamate is chemically stable and poorly reversible,

the presence of glutamate-only species in plasma is a clear indication that the circulating material does not represent a clearance mechanism for the cerebral deposits, but rather their immediate precursors<sup>21</sup>. Another post-translational modification, the oxidation of methionine (in the form of methionine sulfoxide) at position 35 of the A $\beta$  peptide has been widely documented in AD<sup>60–63</sup>. Interestingly, A $\beta$  peptides containing Met35 sulfoxide are able to induce oxidative stress and are more cytotoxic<sup>64</sup>.

### Amyloid associated proteins

Complex mixtures of unrelated molecules, collectively known as amyloid associated proteins, colocalize with all amyloid deposits (including those of A $\beta$ ) not being a structural part of the final fibril [reviewed in ref<sup>2</sup>]. Serum amyloid P component (SAP),  $\alpha$ 1-antichymotrypsin (ACT), apoE, apoJ, complement components, vitronectin, glycosaminoglycans, interleukins and extracellular matrix proteins are among the many amyloid associated proteins so far described in all forms of cerebral and systemic amyloidosis<sup>21,65–73</sup>. To the moment, it is still unclear whether these molecules are innocent bystanders or whether their presence is related to the mechanism of amyloidogenesis. Several lines of investigation favor the latter notion, at least for some of them. For example, apoE and SAP have been found in all immunoglobulin-light-chain fibrillar deposits whereas their presence cannot be demonstrated in the nonfibrillar, Congo red negative, immunoglobulin deposits in cases of Light Chain Deposition Disease<sup>74,75</sup>. Similar findings have been reported in A $\beta$  and non-A $\beta$  cerebral amyloidosis in which SAP and activation-derived products of the complement system are present in amyloid deposits but consistently absent in nonfibrillar pre-amyloid lesions<sup>74,76</sup>. Mice knockout for either SAP or apoE exhibit fewer amyloid lesions and delay in their onset although neither SAP nor apoE gene ablation prevents the formation of amyloid deposits<sup>77,78</sup>. Studies mostly limited to A $\beta$  indicate that many amyloid associated proteins have also the ability to modulate the formation of amyloid fibrils *in vitro*. Some of them (e.g. C1q, apoE4, SAP, ACT) enhance A $\beta$  fibril formation<sup>79–83</sup> while others (e.g. apoJ) contribute to the peptide solubility precluding fibrillogenesis *in vitro*<sup>68,84</sup>. In the latter, this protecting effect has been proposed to contribute to the enhanced production of slowly sedimenting A $\beta$ -derived diffusible ligands (ADDLs) highly toxic to neurons in culture at nanomolar concentrations<sup>85</sup>.

### CAA contribution to disease pathogenesis

It is clear that more than a single factor is associated with the pathogenic mechanisms resulting from cerebral amyloid deposition. Mounting evidence indicates that, in addition to a direct effect on cell viability related to the formation of oligomers/protofibrils and their ability to assemble into functional ion channel-like structures in lipidic environments, amyloids are also able to induce apoptosis/necrosis, to trigger oxidative stress, to generate an inflammatory response and/or to activate the complement cascade. In turn, these pathways, separately or synergistically, are capable to produce different levels of cell damage and modulate cytotoxicity.

### Focal ischemia, oxidative stress, inflammation, and hemorrhagic complications

The vascular dysfunction resulting from amyloid deposition at the cerebral vessel walls is considered today an active player in the mechanism of neurodegeneration and a major contributor to the disease pathogenesis<sup>86–90</sup>. CAA can actively contribute to cognitive decline as a result of the deposit-related cerebral ischemia and microhaemorrhagic complications<sup>91–97</sup>. As illustrated in Figure 1, amyloid deposition in the cerebral vessel wall limits blood supply causing a focal deprivation of oxygen. The resulting focal ischemia, in turn, elicits the release of free radicals inducing oxidative stress mechanisms and leading to enhanced cellular toxicity. Degenerative changes secondary to amyloid deposition also

predispose blood vessels to rupture, which is a major cause of spontaneous, frequently recurrent, lobar cerebral haemorrhages in the elderly<sup>98</sup>. The alteration in blood brain barrier permeability caused by the deposits is aggravated by the induction of inflammatory mechanisms and release of proteases, in particular matrix metalloproteases, which contribute to the partial degradation of the basal lamina and subsequent hemorrhagic complications.

### CAA and apoptotic bio-signaling

Recent studies have also brought light into the intricate molecular mechanisms elicited by specific CAA proteins on cells of the cerebral vessel wall. Figure 2 illustrates the two main pathways -extrinsic and intrinsic- leading to apoptosis in mammalian cells. The latter, modulated by the Bcl-2 family of proteins and typically initiated by oxidative stress and calcium dysregulation, involves mitochondrial outer membrane permeabilization allowing the release of proteins, including cytochrome c, to the cytoplasm. These events, in turn, facilitate downstream cell death cascades leading to sequential activation of caspase-9 followed by the effector caspase-3, DNA fragmentation and formation of apoptotic bodies. The extrinsic path, normally activated through specific cell receptors, involves multiple partners and complex mechanisms and is typically centered in the initiator caspase-8 before the downstream activation of effector caspases common to both intrinsic and extrinsic pathways<sup>99</sup>. Both mechanisms are not completely independent and, once activated, caspase-8 can also result in involvement of the mitochondrial path through its proteolytic effect on Bid leading to Bax translocation, oligomerization and insertion onto the mitochondria with subsequent leakage of cytochrome c. The PI3K pathway and its downstream effector Akt play a primordial role in EC homeostasis constituting active participants in the cross-talk between the cell survival and apoptotic mechanisms. Phosphorylated Akt allows Bad phosphorylation which, in turn, inhibits the activation of Bcl-2 and Bcl-xL, precluding the translocation of Bid, Bax and Bak to the mitochondria and, therefore, preventing the activation of the intrinsic apoptotic pathway. Under physiologic conditions cell homeostasis is tightly maintained through a rigorous control of the balance regulating survival and apoptotic signaling.

Recent data demonstrate that A $\beta$  vasculotropic variants are strong inducers of the apoptotic mitochondrial pathway in cells composing the vessel wall, and highlight their role in various downstream cascades including Bax translocation and cytochrome c release to the cytosol. These events subsequently trigger caspase-9 activation, followed by activation of caspase-3, and downstream DNA fragmentation<sup>100–102</sup>. Contributing to the induction of apoptosis our studies also indicate that A $\beta$  peptides exert an additional powerful effect on Akt phosphorylation downregulating in this way cell survival signaling with the concomitant decrease in EC angiogenesis, and enhancement of apoptosis induction<sup>101</sup>.

### Lessons from A $\beta$ and non-A $\beta$ cerebral amyloidoses

The mechanisms regulating cerebral amyloidosis in general and CAA in particular, are undoubtedly very complex and likely interlink a diversity of mechanistic pathways. Although AD is by far the most common and best studied form of amyloid-related disorders in humans, recent findings on the molecular mechanisms of brain degeneration have demonstrated common features among this heterogeneous group of disorders. Histopathologic, genetic, biochemical, and physicochemical studies, together with the generation of transgenic animal models, strongly support the notion that this diverse group of pathological entities are caused by the abnormal folding, aggregation/fibrilization and subsequent tissue accumulation of particular proteins, specific for each disorder. Shared features among the different CAA-associated disorders bridge together this wide range of pathological entities and suggest unifying mechanisms of disease pathogenesis. The analysis of these common elements, detailed above, highlight a number of features: i) Amyloid

peptides are of primary importance in the process of neurodegeneration, ii) The process is not restricted to A $\beta$ ; other amyloid subunits are associated with similar –if not identical– neuropathological changes leading to the same scenario: neuronal loss and dementia, iii) NFTs and amyloid/pre-amyloid deposits not always co-exist and/or co-localize, pointing to a differential vulnerability for the various neuronal populations, iv) These striking neuropathological similarities in spite of differences in the amyloid subunits, are suggestive of common pathogenic pathways, v) The mechanism of neurodegeneration is complex and likely involves additional unknown factors or interrelationships among different cellular pathways. Overall, it can be envisioned that the lessons learned from the study of non-A $\beta$  cerebral amyloid disorders may bring light to the field of neurodegeneration by providing alternative models to study the molecular basis of neuronal cell death, cerebral hemorrhage, and neurodegeneration.

## Acknowledgments

This work was partially funded by NIH grants NS051715 and AG030539, the Alzheimer's Association, and the American Heart Association

## References

1. Masters CL, Simms G, Weinman NA, et al. Amyloid plaque core protein in Alzheimer disease and Down syndrome. *Proc Natl Acad Sci USA* 1985;82:4245–9. [PubMed: 3159021]
2. Ghiso J, Frangione B. Amyloidosis and Alzheimer's disease. *Adv Drug Delivery Rev* 2002;54:1539–51.
3. Kang I, Lemaire HG, Unterbeck A, et al. The precursor of Alzheimer's disease amyloid A4 protein resembles a cell-surface receptor. *Nature* 1987;325:733–6. [PubMed: 2881207]
4. Selkoe DJ, Wolfe MS. Presenilin: running with scissors in the membrane. *Cell* 2007;131:215–21. [PubMed: 17956719]
5. Thinakaran G, EHK. Amyloid precursor protein trafficking, processing, and function. *J Biol Chem* 2008;283:29615–9. [PubMed: 18650430]
6. Roher AE, Lowenson JD, Clarke S, et al. Beta-Amyloid-(1–42) is a major component of cerebrovascular amyloid deposits: implications for the pathology of Alzheimer disease. *Proc Natl Acad Sci USA* 1993;90:10836–40. [PubMed: 8248178]
7. Kokjohn TA, Roher A. Amyloid precursor protein transgenic mouse models and Alzheimer's disease: understanding the paradigms, limitations, and contributions. *Alzheimers & Dementia* 2009;5:340–7.
8. Levy E, Carman MD, Fernandez Madrid IJ, et al. Mutation of the Alzheimer's disease amyloid gene in hereditary cerebral hemorrhage, Dutch type. *Science* 1990;248:1124–6. [PubMed: 2111584]
9. Maat-Schieman M, Roos R, van Duinen S. Hereditary cerebral hemorrhage with amyloidosis-Dutch type. *Neuropathology* 2005;25:288–97. [PubMed: 16382777]
10. Bornebroek M, Haan J, Roos N. Hereditary cerebral hemorrhage with amyloidosis-Dutch type (HCHWA-D): a review of the variety in phenotypic expression. *Amyloid* 1999;6:215–24. [PubMed: 10524288]
11. Herzig MC, Winkler DT, Burgermeister P, et al. A $\beta$  is targeted to the vasculature in a mouse model of hereditary cerebral hemorrhage with amyloidosis. *Nature Neurosci* 2004;7:954–60.
12. Zhang-Nunes SX, Maat-Schieman M, van Duinen S, et al. The cerebral  $\beta$ -amyloid angiopathies: Hereditary and sporadic. *Brain Pathol* 2006;16:30–9. [PubMed: 16612980]
13. Gudmundsson G, Hallgrimsson J, Jonasson T, Bjarnason O. Hereditary cerebral hemorrhage with amyloidosis. *Brain* 1972;95:387–404. [PubMed: 4655034]
14. Levy E, Lopez-Otin C, Ghiso J, Geltner D, Frangione B. Stroke in Icelandic patients with hereditary amyloid angiopathy is related to a mutation in the cystatin C gene, an inhibitor of cysteine proteases. *J Exp Med* 1989;169:1771–8. [PubMed: 2541223]



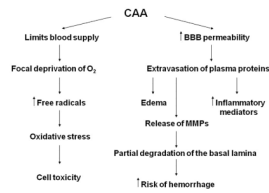
15. Ghiso J, Jenson O, Frangione B. Amyloid fibrils in hereditary cerebral hemorrhage with amyloidosis of Icelandic type is a variant of gamma-trace basic protein (cystatin C). *Proc Natl Acad Sci USA* 1986;83:2974–8. [PubMed: 3517880]
16. Ghiso J, Pons-Estel B, Frangione B. Hereditary cerebral amyloid angiopathy: the amyloid contain a protein which is a variant of cystatin C, an inhibitor of lysosomal cysteine proteases. *Biochem Biophys Res Comm* 1986;136:548–54. [PubMed: 3707586]
17. Levy E, Jaskolski M, Grubb A. The role of cystatin C in cerebral amyloid angiopathy and stroke: Cell biology and animal models. *Brain Pathol* 2006;16:60–70. [PubMed: 16612983]
18. Janowski R, Kozak M, Jankowska E, et al. Human cystatin C, an amyloidogenic protein, dimerizes through three-dimensional domain swapping. *Nat Struct Biol* 2001;8:316–20. [PubMed: 11276250]
19. Janowski R, Kozak M, Abrahamson M, Grubb A, Jaskolski M. 3D Domain-swapped human cystatin C with amyloid like intermolecular  $\beta$ -sheets. *Structure Function, and Bioinformatics* 2005;61:570–8.
20. Janowski R, Abrahamson M, Grubb A, Jaskolski M. Domain swapping in N-truncated cystatin C. *J Mol Biol* 2004;341:151–60. [PubMed: 15312769]
21. Rostagno A, Tomidokoro Y, Lashley T, et al. Chromosome 13 dementias. *Cell Mol Life Sci* 2005;62:1814–25. [PubMed: 15968464]
22. Ghiso, J.; Vidal, R.; Rostagno, A., et al. Amyloidogenesis in Familial British Dementia is associated with a genetic defect on chromosome 13. In: Growdon, J.; Wurtman, R.; Corkin, S.; Nitsch, R., editors. *Molecular basis of dementia*. New York: New York Academy of Sciences; 2000. p. 84-92.
23. Matsuda S, Giliberto L, Matsuda Y, et al. The familial dementia BRI2 gene binds the Alzheimer's gene amyloid-beta precursor protein and inhibits amyloid-beta production. *J Biol Chem* 2005;280:28912–6. [PubMed: 15983050]
24. Matsuda S, Giliberto L, Matsuda T, Mc-Gowan E, D'Adamio L. BRI2 inhibits amyloid beta peptide precursor protein processing by interfering with the docking of secretases to the substrate. *J Neurosci* 2008;28:8668–76. [PubMed: 18753367]
25. Fotinopoulou A, Tsachaki M, Vlavaki M, et al. BRI2 interacts with amyloid precursor protein (APP) and regulates amyloid beta(A $\beta$ ) production. *J Biol Chem* 2005;280:30768–72. [PubMed: 16027166]
26. Kim J, Miller VM, Levites Y, et al. BRI2(Itm2b) inhibits A $\beta$  deposition *in vivo*. *J Neurosci* 2008;28:6030–6. [PubMed: 18524908]
27. Worster-Drought C, Hill T, McMenemey W. Familial presenile dementia with spastic paralysis. *J Neurol Psychopathol* 1933;14:27–34.
28. Ghiso J, Holton J, Miravalle L, et al. Systemic amyloid deposits in Familial British Dementia. *J Biol Chem* 2001;276:43909–14. [PubMed: 11557758]
29. Vidal R, Frangione B, Rostagno A, et al. A stop-codon mutation in the *BRI* gene associated with familial British dementia. *Nature* 1999;399:776–81. [PubMed: 10391242]
30. Vidal R, Ghiso J, Revesz T, et al. A decamer duplication in the 3' region of the *BRI* gene originates a new amyloid peptide that is associated with dementia in a Danish kindred. *Proc Natl Acad Sci USA* 2000;97:4920–5. [PubMed: 10781099]
31. Ghiso J, Rostagno A, Tomidokoro Y, et al. Genetic alterations of the BRI2 gene: familial British and Danish dementias. *Brain Pathol* 2006;16:71–9. [PubMed: 16612984]
32. Holton J, Ghiso J, Lashley T, et al. Regional distribution of fibrillar and nonfibrillar ABri deposition and its association with neurofibrillary degeneration in Familial British Dementia. *Am J Pathology* 2001;158:515–26.
33. Holton J, Lashley T, Ghiso J, et al. Familial Danish Dementia: a novel form of cerebral amyloidosis associated with deposition of both amyloid-Dan and amyloid-beta. *J Neuropathol Exp Neurol* 2002;61:254–67. [PubMed: 11895040]
34. Tomidokoro Y, Lashley T, Rostagno A, et al. Familial Danish dementia: Co-existence of ADan and A $\beta$  amyloid subunits in the absence of compact plaques. *J Biol Chem* 2005;280:36883–94. [PubMed: 16091362]

35. Castano EM, Prelli F, Soto C, et al. The length of amyloid-beta in hereditary cerebral hemorrhage with amyloidosis, Dutch type. Implications for the role of amyloid-beta 1-42 in Alzheimer's disease. *J Biol Chem* 1996;271:32185-91. [PubMed: 8943274]
36. Prelli F, Levy E, van Duinen SG, et al. Expression of a normal and variant Alzheimer's  $\beta$ -protein gene in amyloid of hereditary cerebral hemorrhage, Dutch type: DNA and protein diagnostic assays. *Biochem Biophys Res Comm* 1990;170:301-7. [PubMed: 2196878]
37. Gabizon R, Telling G, Meiner Z, Halimi M, Kahana I, Prusiner SB. Insoluble wild-type and protease-resistant mutant prion protein in brains of patients with inherited prion disease. *Nat Med* 1996;2:59-64. [PubMed: 8564843]
38. Ando Y, Ando E, Ohlsson P-I, Olofsson A, Sandgren O, Suhr O, Terazaki H, Obayashi K, Lundgren E, Ando M, Negi A. Analysis of transthyretin amyloid fibrils from vitreous samples in familial amyloidotic polyneuropathy (Val30Met). *Amyloid* 1999;6:119-23. [PubMed: 10439118]
39. Thylén C, Wahlqvist J, Haettner E, Sandgren O, Holmgren G, Lundgren E. Modification of transthyretin in amyloid fibrils: analysis of amyloid from homozygous and heterozygous individuals with the Met30 mutation. *EMBO J* 1993;12:743-8. [PubMed: 8095018]
40. Dwulet FE, Benson MD. Characterization of a transthyretin (prealbumin) variant associated with familial amyloidotic polyneuropathy type II (Indiana/Swiss). *J Clin Invest* 1986;78:880-6. [PubMed: 3760189]
41. Yazaki M, Tokuda T, Nakamura A, Higashikata T, Koyama J, Higuchi K, Harihara Y, Baba S, Kametani F, Ikeda S-I. Cardiac amyloid in patients with familial amyloid polyneuropathy consists of abundant wild-type transthyretin. *Biochem Biophys Res Commun* 2000;274:702-6. [PubMed: 10924339]
42. Yazaki M, Liepnieks JJ, Kincaid JC, Benson MD. Contribution of wild-type transthyretin to hereditary peripheral nerve amyloid. *Muscle Nerve* 2003;28:438-42. [PubMed: 14506715]
43. Frangione B.; Wisniewski, T.; Tagliavini, F.; Bugiani, O.; Ghiso, J. Alzheimer's disease and Dutch variant: Opposing faces of a single coin. In: Corain, B.; Iqbal, K.; Nicolini, B., et al., editors. *Alzheimer's disease: Advances in clinical and basic research*. Chichester, England: John Wiley and Sons; 1993. p. 387-96.
44. Wisniewski T, Golabek AA, Kida E, Wisniewski KE, Frangione B. Conformational mimicry in Alzheimer's disease. Role of apolipoproteins in amyloidogenesis. *Am J Pathol* 1995;147:238-44. [PubMed: 7639323]
45. Roher AE, Lowenson JD, Clarke S, et al. Structural alterations in the peptide backbone of beta-amyloid core protein may account for its deposition and stability in Alzheimer's disease. *J Biol Chem* 1993;268:3072-83. [PubMed: 8428986]
46. Saido T, Iwatsubo T, Mann DM, et al. Dominant and differential deposition of distinct  $\beta$ -amyloid peptide species,  $A\beta_{N3(pE)}$ , in senile plaques. *Neuron* 1995;14:457-66. [PubMed: 7857653]
47. Shimizu T, Fukuda H, Murayama S, Izumiyama N, Shirasawa T. Isoaspartate formation at position 23 of amyloid beta peptide enhanced fibril formation and deposited onto senile plaques and vascular amyloids in Alzheimer's disease. *J Neurosci Res* 2002;70:451-61. [PubMed: 12391606]
48. Bellotti V, Mangione P, Merlini G. Review: immunoglobulin light chain amyloidosis--the archetype of structural and pathogenic variability. *J Struct Biol* 2000;130:280-9. [PubMed: 10940232]
49. Watanabe A, Takio K, Ihara Y. Deamidation and isoaspartate formation in smeared tau in paired helical filaments. Unusual properties of the microtubule-binding domain of tau. *J Biol Chem* 1999;274:7368-78. [PubMed: 10066801]
50. Shin Y, Cho HS, Fukumoto H, et al. Abeta species, including IsoAsp23 Abeta, in Iowa-type familial cerebral amyloid angiopathy. *Acta neuropathol* 2003;105:252-8. [PubMed: 12557012]
51. Shimizu T, Fukuda H, Murayama S, Izumiyama N, Shirasawa T. Isoaspartate formation at position 23 of amyloid beta peptide enhanced fibril formation and deposited onto senile plaques and vascular amyloids in Alzheimer's disease. *J Neurosci Res* 2002;70:451-61. [PubMed: 12391606]
52. Shin Y, Cho HS, Fukumoto H, Shimizu T, Shirasawa T, Greenberg SM, Rebeck GW. Abeta species, including IsoAsp23 Abeta, in Iowa-type familial cerebral amyloid angiopathy. *Acta Neuropathol (Berl)* 2003;105:252-8. [PubMed: 12557012]

53. Robinson NE, Robinson AB. Deamination of human proteins. *Proc Natl Acad Sci U S A* 2001;98:12409–13. [PubMed: 11606750]
54. Lindner H, Helliger W. Age-dependent deamidation of asparagine residues in proteins. *Exp Gerontol* 2001;36:1551–63. [PubMed: 11525877]
55. Kuo YM, Webster S, Emmerling MR, De Lima N, Roher AE. Irreversible dimerization/tetramerization and post-translational modifications inhibit proteolytic degradation of A beta peptides of Alzheimer's disease. *Biochim Biophys Acta* 1998;1406:291–8. [PubMed: 9630681]
56. Mori H, Takio K, Ogawara M, Selkoe D. Mass spectrometry of purified amyloid beta protein in Alzheimer's disease. *J Biol Chem* 1992;267:17082–6. [PubMed: 1512246]
57. Lalowski M, Golabek A, Lemere CA, et al. The "nonamyloidogenic" p3 fragment (amyloid beta17-42) is a major constituent of Down's syndrome cerebellar preamyloid. *J Biol Chem* 1996;271:33623–31. [PubMed: 8969231]
58. Harigaya Y, Saido TC, Eckman CB, et al. Amyloid  $\beta$  protein starting pyroglutamate at position 3 is a major component of the amyloid deposits in the Alzheimer's disease brain. *Biochem Biophys Res Comm* 2000;24:422–7. [PubMed: 11027491]
59. Russo C, Violani E, Salis S, et al. Pyroglutamate-modified amyloid  $\beta$ -peptides- A $\beta$ N3(pE)-strongly affect cultured neuron and astrocyte survival. *J Neurochem* 2002;82:1480–9. [PubMed: 12354296]
60. Naslund J, Schierhorn A, Hellman U, et al. Relative abundance of Alzheimer A $\beta$  amyloid peptide variants in Alzheimer disease and normal aging. *Proc Natl Acad Sci USA* 1994;91:8378–82. [PubMed: 8078890]
61. Dong J, Atwood CS, Anderson VE, et al. Metal binding and oxidation of amyloid-beta within isolated senile plaque cores: raman microscopic evidence. *Biochemistry* 2003;42:2768–73. [PubMed: 12627941]
62. Kuo Y-M, Kokjohn TA, Beach T, et al. Comparative analysis of amyloid- $\beta$  chemical structure and amyloid plaque morphology of transgenic mouse and Alzheimer's disease brains. *J Biol Chem* 2001;276:12991–8. [PubMed: 11152675]
63. Barnham KJ, Ciccotosto GD, Tickler AK, et al. Neurotoxic, redox-competent Alzheimer's  $\beta$ -amyloid is released from lipid membrane by methionine oxidation. *J Biol Chem* 2003;278:42959–65. [PubMed: 12925530]
64. Varadarajan S, Kanski J, Aksenova M, Lauderback C, Butterfield DA. Different mechanisms of oxidative stress and neurotoxicity for Alzheimer's A $\beta$ (1-42) and A $\beta$ (25-35). *J Am Chem Soc* 2001;123:5625–31. [PubMed: 11403592]
65. Coria F, Castaño EM, Prelli F, et al. Isolation and characterization of amyloid P component from Alzheimer's disease and other types of cerebral amyloidosis. *Lab Invest* 1988;58:454–7. [PubMed: 2965774]
66. Wisniewski T, Frangione B. Apolipoprotein E: a pathological chaperone protein in patients with cerebral and systemic amyloid. *Neurosci Lett* 1992;135:235–8. [PubMed: 1625800]
67. Kalaria RN, Galloway PG, Perry G. Widespread serum amyloid P immunoreactivity in cortical amyloid deposits and the neurofibrillary pathology of Alzheimer's disease and other degenerative disorders. *Neuropathol Appl Neurobiol* 1991;17:189–201. [PubMed: 1891063]
68. Veerhuis R, Boshuizen RS, Familian A. Amyloid associated proteins in Alzheimer's and prion disease. *Curr Drug Targets CNS & Neurological Dis* 2005;4:235–48.
69. Rostagno, A.; Ghiso, J. Amyloidosis. In: Aminoff, M.; Daroff, R., editors. *Encyclopedia of neurological sciences*. San Diego: Academic Press; 2003. p. 129-35.
70. Ghiso, J.; Rostagno, A.; Tomidokoro, Y., et al. Familial British and Danish dementias. Amyloid proteins. In: Sipe, JD., editor. *The beta sheet conformation and disease*. Weinheim, Germany: Wiley-VCH Verlag GmbH & Co. KGaA; 2005. p. 515-26.
71. Namba Y, Tomonaga M, Kawasaki H, Otomo E, Ikeda K. Apolipoprotein E immunoreactivity in cerebral amyloid deposits and neurofibrillary tangles in Alzheimer's disease and kuru plaque amyloid in Creutzfeldt-Jakob disease. *Brain Res* 1991;541:163–6. [PubMed: 2029618]
72. Yamada T, Kakiyama T, Gejyo F, Okada M. A monoclonal antibody recognizing apolipoprotein E peptides in systemic amyloid deposits. *Ann Clin Lab Sci* 1994;24:243–9. [PubMed: 8048796]
73. Kindy MS, King AR, Perry G, de Beer MC, de Beer FC. Association of apolipoprotein E with murine amyloid A protein amyloid. *Lab Invest* 1995;73:469–75. [PubMed: 7474917]

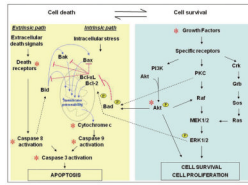
74. Gallo G, Picken M, Frangione B, Buxbaum JN. Nonamyloidotic monoclonal immunoglobulin deposits lack amyloid P component. *Mod Pathol* 1988;1:453–6. [PubMed: 3146753]
75. Gallo G, Wisniewski T, Choi-Miura NH, Ghiso J, Frangione B. Potential role of apolipoprotein-E in fibrillogenesis. *Am J Pathology* 1994;145:526–30.
76. Rostagno A, Revesz T, Lashley T, et al. Complement activation in Chromosome 13 dementias: Similarities with Alzheimer's Disease. *J Biol Chem* 2003;277:49782–90. [PubMed: 12388551]
77. Botto M, Hawkins PN, Bickerstaff MCM, et al. Amyloid deposition is delayed in mice with targeted deletion of serum amyloid P component. *Nature Med* 1997;3:855–9. [PubMed: 9256275]
78. Holtzman DM, Bales KR, Wu S, et al. Expression of human apolipoprotein E reduces amyloid-beta deposition in a mouse model of Alzheimer's disease. *J Clin Invest* 1999;103:R15–R21. [PubMed: 10079115]
79. Tennent GA, Lovat LB, Pepys MB. Serum amyloid P component prevents proteolysis of the amyloid fibrils of Alzheimer's disease and systemic amyloidosis. *Proc Natl Acad Sci USA* 1995;92:4299–303. [PubMed: 7753801]
80. Wisniewski T, Castaño EM, Golabek AA, Vogel T, Frangione B. Acceleration of Alzheimer's fibril formation by apolipoprotein E in vitro. *Am J Pathology* 1993;145:1030–5.
81. LaDu MJ, Falduto MT, Manelli AM, et al. Isoform-specific binding of apolipoprotein E to beta-amyloid. *J Biol Chem* 1994;269:23403–6. [PubMed: 8089103]
82. Ma J, Yee A, Brewer HB Jr, Das S, Potter H. Amyloid-associated proteins alpha 1-antichymotrypsin and apolipoprotein E promote assembly of Alzheimer beta-protein into filaments. *Nature* 1994;392:92–4. [PubMed: 7969426]
83. Webster S, O'Barr S, Rogers J. Enhanced aggregation and  $\beta$  structure of amyloid  $\beta$  peptide after coincubation with C1q. *J Neurosci Res* 1994;39:448–56. [PubMed: 7884823]
84. Matsubara E, Soto C, Governale S, Frangione B, Ghiso J. Apolipoprotein J and Alzheimer's amyloid beta solubility. *Biochem J* 1996;316:671–9. [PubMed: 8687416]
85. Lambert MP, Barlow AK, Chromy BA, et al. Diffusible, nonfibrillar ligands derived from A $\beta$ 1-42 are potent central nervous system neurotoxins. *Proc Natl Acad Sci USA* 1998;95:6448–53. [PubMed: 9600986]
86. Farkas E, Luiten PGM. Cerebral microvascular pathology in aging and Alzheimer's disease. *Progress Neurobiol* 2001;64:575–611.
87. Bailey TL, Rivara CB, Rocher AB, Hof PR. The nature and effects of cortical microvascular pathology in aging and Alzheimer's disease. *Neurol Res* 2004;26:573–8. [PubMed: 15265277]
88. de la Torre JC. Alzheimer's disease is a vasocognopathy: a new term to describe its nature. *Neurol Res* 2004;26:517–24. [PubMed: 15265269]
89. Gorelick PB. Risk factors for vascular dementia and Alzheimer's disease. *Stroke* 2004;35:2620–7. [PubMed: 15375299]
90. Petty MA, Wettstein JG. Elements of cerebral microvascular ischaemia. *Brain Res Rev* 2001;36:23–34. [PubMed: 11516770]
91. Cadavid D, Mena H, Koeller K, Frommelt RA. Cerebral beta amyloid angiopathy is a risk factor for cerebral ischemic infarction. A case control study in human brain biopsies. *J Neuropathol Exp Neurol* 2000;59:768–73. [PubMed: 11005257]
92. Greenberg SM. Cerebral amyloid angiopathy and dementia: two amyloids are worse than one. *Neurology* 2002;58:1587–8. [PubMed: 12058082]
93. Natta R, Maat-Schieman M, Haan J, et al. Dementia in hereditary cerebral hemorrhage with amyloidosis-Dutch type is associated with cerebral amyloid angiopathy but is independent of plaques and neurofibrillary tangles. *Ann Neurol* 2001;50:765–72. [PubMed: 11761474]
94. Olichney JM, Hansen LA, Hofstetter CR, et al. Cerebral infarction in Alzheimer's disease is associated with severe amyloid angiopathy and hypertension. *Arch Neurol* 1995;52:702–8. [PubMed: 7619027]
95. Pfeifer LA, White LR, Ross GW, Petrovitch H, Launer LJ. Cerebral amyloid angiopathy and cognitive function: the HAAS autopsy study. *Neurology* 2002;58:1629–34. [PubMed: 12058090]
96. Snowdon DA, Greiner LH, Mortimer JA, et al. Brain infarction and the clinical expression of Alzheimer's disease. The Nun Study. *JAMA* 1997;277:813–7. [PubMed: 9052711]

97. Winkler DT, Bondol WL, Herzig MC, et al. Spontaneous hemorrhagic stroke in a mouse model of cerebral amyloid angiopathy. *J Neurosci* 2001;21:1619–27. [PubMed: 11222652]
98. O'Donnell HC, Rosand J, Knudsen KA, et al. Apolipoprotein E genotype and the risk of recurrent lobar intracerebral hemorrhage. *N Engl J Med* 2000;342:240–5. [PubMed: 10648765]
99. Mattson MP. Apoptosis in neurodegenerative disorders. *Nat Rev Molec Cell Biol* 2000;1:120–9. [PubMed: 11253364]
100. Fossati S, Cam J, Meyerson J, et al. Differential activation of mitochondrial apoptotic pathways by vasculotropic amyloid- $\beta$  variants in cells composing the cerebral vessel walls. *Faseb J* 2010;24:229–41. [PubMed: 19770225]
101. Solito R, Corti F, Fossati S, et al. Dutch and Arctic mutant peptides of beta amyloid (1-40) differentially affect the FGF-2 pathway in brain endothelium. *Exp Cell Res* 2009;315:385–95. [PubMed: 19061884]
102. Viana RJ, Nunes AF, Castro RE, et al. Tauroursodeoxycholic acid prevents E22Q Alzheimer's A $\beta$  toxicity in human cerebral endothelial cells. *Cell Mol Life Sci* 2009;66:1094–104. [PubMed: 19189048]



**Figure 1. Molecular mechanisms associated with amyloid deposition in the cerebrovascular vessels**

Schematic representation of the diverse molecular pathways affected by CAA, leading to stroke, ischemia, and the development of hemorrhagic complications.



**Figure 2. Cellular apoptotic pathways**

*Left panel:* diagram of the molecular events triggered by the induction of intrinsic and extrinsic apoptotic pathways. *Right panel:* schematic representation of the main cell survival and proliferation mechanisms. \* indicates the molecular events affected by CAA-amyloid in cerebral vessel wall cells.