

## Clinical Article

# Analysis of Complications Following Decompressive Craniectomy for Traumatic Brain Injury

Seung Pil Ban, M.D., Young-Je Son, M.D., Hee-Jin Yang, M.D., Yeong Seob Chung, M.D., Sang Hyung Lee, M.D., Dae Hee Han, M.D.

Department of Neurosurgery, Seoul National University Boramae Medical Center, Seoul, Korea

**Objective :** Adequate management of increased intracranial pressure (ICP) is critical in patients with traumatic brain injury (TBI), and decompressive craniectomy is widely used to treat refractory increased ICP. The authors reviewed and analyzed complications following decompressive craniectomy for the management of TBI.

**Methods :** A total of 89 consecutive patients who underwent decompressive craniectomy for TBI between February 2004 and February 2009 were reviewed retrospectively. Incidence rates of complications secondary to decompressive craniectomy were determined, and analyses were performed to identify clinical factors associated with the development of complications and the poor outcome.

**Results :** Complications secondary to decompressive craniectomy occurred in 48 of the 89 (53.9%) patients. Furthermore, these complications occurred in a sequential fashion at specific times after surgical intervention; cerebral contusion expansion ( $2.2 \pm 1.2$  days), newly appearing subdural or epidural hematoma contralateral to the craniectomy defect ( $1.5 \pm 0.9$  days), epilepsy ( $2.7 \pm 1.5$  days), cerebrospinal fluid leakage through the scalp incision ( $7.0 \pm 4.2$  days), and external cerebral herniation ( $5.5 \pm 3.3$  days). Subdural effusion ( $10.8 \pm 5.2$  days) and postoperative infection ( $9.8 \pm 3.1$  days) developed between one and four weeks postoperatively. Trenching and post-traumatic hydrocephalus syndromes developed after one month postoperatively (at  $79.5 \pm 23.6$  and  $49.2 \pm 14.1$  days, respectively).

**Conclusion :** A poor GCS score ( $\leq 8$ ) and an age of  $\geq 65$  were found to be related to the occurrence of one of the above-mentioned complications. These results should help neurosurgeons anticipate these complications, to adopt management strategies that reduce the risks of complications, and to improve clinical outcomes.

**KEY WORDS :** Decompressive craniectomy · Traumatic brain injury · Complication

## INTRODUCTION

Traumatic head injury is an important cause of intracranial hypertension<sup>1)</sup>. The aims of the management of traumatic intracranial hypertension are the control of intracranial pressure (ICP), and the maintenance of cerebral perfusion pressure (CPP) and cerebral blood flow (CBF) to prevent cerebral ischemia. Severe intracranial hypertension does not respond to medical management in 10 to 15% of head injured patients<sup>1,16,23)</sup> and decompressive craniectomy appears to be a reasonable alternative treatment in these patients, but the long-term functional outcomes of this method when used to treat an elevated ICP (ICP > 20 mmHg) remain unknown. Never-

theless, several authors have reported a gradual decrease in mortality and an increase in the proportion of patients that achieve a good outcome after decompressive craniectomy<sup>1)</sup> and others have concluded that surgical decompression may improve oxygen delivery to brain tissue, cerebral compliance, CPP, and CBF, and reduce swelling, and thus, improve clinical outcomes<sup>3,8,19,26,28)</sup>. The surgical method is relatively straightforward, but postoperative complications can severely affect clinical outcome. Here, we retrospectively analyzed complications following decompressive craniectomy in patients with traumatic brain injury (TBI) and sought to identify the clinical risk factors related to poor outcome.

## MATERIALS AND METHODS

### Study characteristics

We retrospectively investigated the medical records on patients with TBI who underwent decompressive craniectomy between February 2004 and February 2009.

• Received : May 4, 2010 • Revised : August 4, 2010

• Accepted : September 17, 2010

• Address for reprints : Young-Je Son, M.D.

Department of Neurosurgery, Seoul National University Boramae Medical Center, 39 Boramae-gil, Dongjak-gu, Seoul 156-707, Korea

Tel : +82-2-870-2304, Fax : +82-2-870-3863

E-mail : petitprince1024@hanmail.net

## Surgical indications and procedure

Surgical indications for decompressive craniectomy were included : 1) the appearance of unilateral or bilateral brain swelling and a midline shift of at least 5 mm on CT scans with a poor initial GCS score ( $\leq 8$ ); 2) neurological worsening (a decrease of GCS score of  $\geq 2$  points) and aggravation of pupillary response to light during initial medical therapy; 3) bilateral fixed pupils with an intact brain stem reflex; 4) therapy-resistant increases in ICP to  $> 25$  mmHg in patients undergoing ICP monitoring; 5) a swollen brain despite hematoma evacuation. Surgical decompression was not performed in any patient without brain stem reflex.

Patients received decompressive craniectomy, hematoma removal, augmentative duraplasty, and decompressive lobectomy if necessary. Decompressive craniectomy was performed by removing a large portion of the frontotemporoparietal cranium ( $> 12$  cm) for lesions confined to one cerebral hemisphere. Patients with bifrontal or anterior cranial fossa lesions underwent bilateral frontal craniectomy from the anterior cranial fossa to the coronal suture. After craniectomy, epidural hematoma (EDH) and subdural hematoma (SDH) were evacuated when present. Brain parenchymal hemorrhagic contusion was removed in cases with persistent and significant brain swelling after craniectomy and hematoma evacuation.

## Diagnosis of complications

Several complications occurred after decompressive craniectomy, such as, contusion expansion, postoperative epilepsy, external cerebral herniation, intracranial hematoma contralateral to the craniectomy defect, subdural effusion, CSF leakage through the skin incision, postoperative infection, post-traumatic hydrocephalus, and syndrome of the trephined.

The following criteria were used to diagnose these complications following decompressive craniectomy. Contusion expansion was defined as an enlarged non-hemorrhagic or hemorrhagic contusion ipsilateral or contralateral to the decompressed hemisphere on serial cranial CT scans. Subdural effusion was defined as a newly appearing subdural fluid collection on serial cranial CT scans. External cerebral herniation was defined as more than 1.5 cm of herniated brain tissue through the craniectomy in the center of the skull defect, as previously described by Yang et al.<sup>26</sup>. Post-operative epilepsy was defined as one or more postoperative epilepsy attack. Post-traumatic hydrocephalus was defined as; 1) ventricular dilation not due to brain atrophy; 2) onset within 6 months after surgery; and 3) neurological deterioration. Syndrome of the trephined was defined as the following profile; 1) newly appearing symptoms including headache, irritability, memory problems, mood disturbances, or neurological deficits follow-

ing decompressive craniectomy; with 2) a sunken parenchymal contour on the skull defect side by brain CT.

## Assessment of neurological outcomes

Neurological outcomes were evaluated using the Glasgow outcome scale (GOS) as follows : 1) death; 2) vegetative state; 3) severe disability; 4) moderate disability; and 5) good recovery. Clinical outcomes were analyzed with respect to initial GCS score, age, pupillary response to light, and the midline shift by cranial CT scan at admission. In addition, we compared the incidences of complications among different patient subgroups to identify risk factors affecting complications.

## Statistical analysis

Data were analyzed using SPSS 14.0 for Windows (SPSS, Inc., Chicago, IL, USA). Pearson's chi-square test, Fisher's exact test and logistic regression analysis were used to calculate the significances of differences. Statistical significance was accepted for *p* values of  $< 0.05$ .

## RESULTS

Eighty-nine patients (79 men and 10 women), mean age of 51.4 years old (range, 4-82 years old), underwent decompressive craniectomy. The most common cause of head injury was fall ( $n = 53$ , 59.5%), and other causes were motor-vehicle accidents ( $n = 28$ , 31.5%) and violence ( $n = 8$ , 9%). The mean preoperative GCS score was 7/15 (range, 3-14). Bilaterally dilated unreactive pupils were seen in 39 patients (43.8%), a dilated unreactive pupil was seen in 19 patients (21.3%), and bilaterally reactive pupils were seen in 31 patients (34.8%). The midline shift of  $\leq 10$  mm on initial cranial CT scans was seen in 24 patients (27.0%) (Table 1).

Complications associated with decompressive craniectomy occurred in 48 of the 89 patients (53.9%), and 21 (23.6%) patients developed more than one complication. Each complication following decompressive craniectomy showed a tendency to occur within a specific time window after surgery (Table 1). We divided complications into three subgroups according to onset time after surgery; early (within 1 week), late (from day 8 to 30) and delayed ( $> 1$  month).

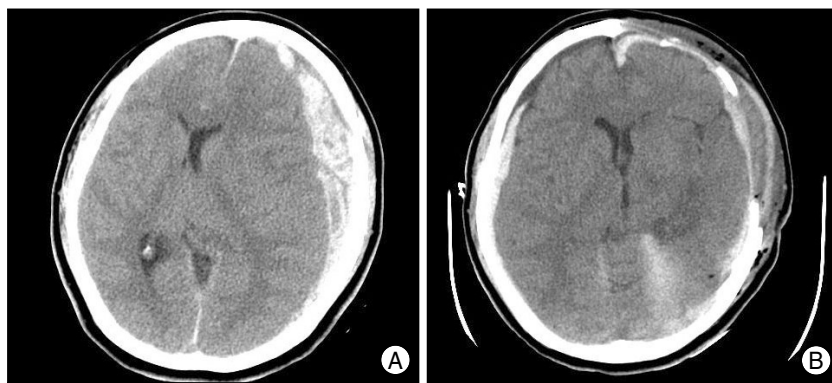
## Early complications

Hematoma contralateral to the decompressive craniectomy defect occurred in 5 patients and was the earliest complication to develop ( $1.5 \pm 0.9$  days) (Fig. 1). Reoperation was performed in 2 patients due to significant mass effect and neurological deterioration.

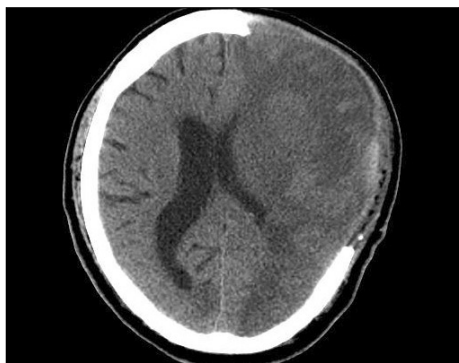
Contusion expansion occurred in 11 of 48 patients ( $2.2 \pm 1.2$  days) and 4 of these underwent hematoma evacuation to

**Table 1.** Complications associated with decompressive craniectomy for TBI

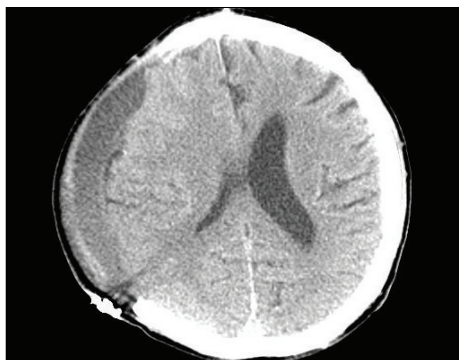
	No.	Incidence rate (%)	Time of onset (days, mean ± standard deviation)
Hematoma contralateral to the craniectomy defect	5	5.6	1.5 ± 0.9
Contusion expansion	11	12.4	2.2 ± 1.2
Postoperative epilepsy	3	3.4	2.7 ± 1.5
External cerebral herniation	13	14.6	5.5 ± 3.3
CSF leakage through skin incision	2	2.2	7.0 ± 4.2
Postoperative infection	4	4.5	9.8 ± 3.1
Subdural effusion	29	32.6	10.8 ± 5.2
Post-traumatic hydrocephalus	10	11.2	49.2 ± 14.1
Syndrome of the trephined	8	9.0	79.5 ± 23.6



**Fig. 1.** A : Initial brain CT image showing left traumatic subdural hematoma. B : Brain CT after decompressive craniectomy showing a new hematoma contralateral to the craniectomy defect.



**Fig. 2.** Brain CT image demonstrating external cerebral herniation.



**Fig. 3.** Brain CT image of postoperative subdural effusion.

reduce ICP. Furthermore, despite preventive antiepileptic medication, post-traumatic epilepsy occurred in 3 patients (2.7 ± 1.5 days).

External cerebral herniation occurred in 13 patients (5.5 ± 3.3 days) and CSF leakage in 2 patients (7.0 ± 4.2 days). These complications resolved spontaneously (Fig. 2).

**Late complications (from postoperative 8 to 30 days)**

Postoperative infection occurred in 4 patients (9.8 ± 3.1 days) and was treated by antibiotics. Subdural effusion occurred in 29 patients within 15 days (10.8 ± 5.2 days) (Fig. 3) and was the most common complication encountered. Most of these lesions resolved spontaneously. However, surgery was necessary on one case because of the neurological deficit.

**Delayed complications**

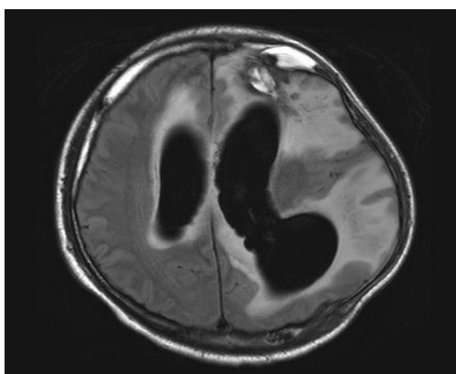
Post-traumatic hydrocephalus occurred in 10 patients (49.2 ± 14.1 days) (Fig. 4) and a ventriculoperitoneal (VP) shunt was placed in all. Syndrome of the trephined occurred in 8 patients (79.5 ± 23.6 days) (Fig. 5), and these patients improved after cranioplasty.

**Relations between complications and clinical factors**

Patients were divided into three groups according to initial GCS score; group 1 (GCS 3-8), group 2 (9-12) and group 3 (≥ 13). Group 1 contained 57 (64.0%) patients, group 2 contained 22 (28.1%) and group 3 contained 7 (7.9%). We also divided patients into three groups by age; group I (< 40 years old) contained 57 (64.0%), group II (40-64 years old) 25 (28.1%) and group III (≥ 65 years old) 7 (8.9%) patients (Table 2). It was found that patients with lower GCS score at admission (*p* = 0.048) and older patients (≥ 65; *p* = 0.042) had significantly higher complication incidence rates. Furthermore, 41 patients without complications achieved functional recovery (GOS 4-5) after surgery (*p* = 0.048).

**Clinical outcomes**

The clinical outcomes were determined using GOS score. Final outcomes were evaluated at postoperative 6 months or at death. Twenty-one of 89 patients who underwent decom-



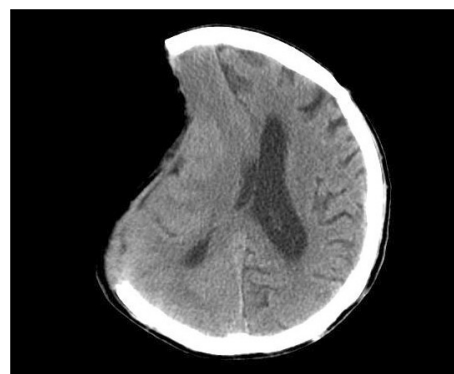
**Fig. 4.** Brain MR image showing post-traumatic hydrocephalus.

pressive craniectomy died within 1 month of surgery (GOS 1). Of these, 15 patients died of intractable intracranial hypertension and six patients succumbed to other medical problems. Of the 68 survivors after decompressive craniectomy, 42 patients achieved functional recovery (GOS 4 & 5) and 26 non-functional recovery (GOS 2 & 3) (Table 3). Our analysis showed that patients with the poor GCS score ( $\geq 8$ ) at admission ( $p < 0.001$ ), older patients ( $\geq 65$ ,  $p = 0.010$ ), patients with the midline shift exceeding 10 mm ( $p < 0.05$ ) and patients with bilaterally unreactive pupils ( $p < 0.005$ ) showed worse clinical outcome rates.

We performed univariate and multivariate analysis to examine relations between postoperative outcomes and postoperative complications. Complications with a  $p$  value of  $< 0.1$  by univariate analysis were subjected to multivariate analysis. Contusion expansion ( $p = 0.010$ ) and age ( $p = 0.016$ ) were found to be significantly predictive of postoperative death, and subdural effusion ( $p = 0.012$ ) was found to be significantly associated with low risk of postoperative death. However, multivariate analysis revealed that only contusion expansion and subdural effusion were significantly associated with clinical outcome (Table 4).

## DISCUSSION

Traumatic brain injury is one of the most common causes of death among young people in the industrialized countries<sup>6,24</sup>. Marked ICP elevation, which causes cerebral ischemia and secondary brain damage, is difficult to treat by medical management alone<sup>6,9,20,21</sup> and thus, in these cases, neurosurgeons generally perform decompressive craniectomy to reduce ICP and prevent additional brain damage. Furthermore, many studies on decompressive craniectomy have shown that it improves clinical outcomes<sup>1,2,7,11,13,14,17,18,25</sup>. Nevertheless, there is no prospective controlled randomized trial to establish that decompressive craniectomy for TBI actually improve quality of life<sup>29</sup>) and long-term functional outcomes following this procedure for intractable intracranial hyper-



**Fig. 5.** Brain CT image showing a sinking scalp flap.

**Table 2.** Clinical characteristics of patients with TBI

Characteristics	
Total	89
Gender	
Male	79 (88.8%)
Female	10 (11.2%)
Age	
Average (years)	51.5 ± 15.8
< 40	57 (64.0%)
40-64	25 (28.1%)
≥ 65	7 (8.9%)
Cause of TBI	
Falling	53 (59.5%)
Motor-vehicle accidents	28 (31.5%)
Violence	8 (9.0%)
Initial GCS score	
Average	7.2 ± 3.1
3-8	57 (64.0%)
9-12	25 (28.1%)
≥ 13	7 (7.9%)
Pupillary response	
Bilaterally unreactive	39 (43.8%)
Unilaterally unreactive	19 (21.3%)
Bilaterally reactive	31 (34.8%)
Midline shift on initial carnial CT scan	
≤ 10 mm	24 (27.0%)
> 10 mm	65 (73.0%)

**Table 3.** Clinical outcome at postoperative 6 months

	No. of patients (%)
Good recovery (GOS 5)	21 (23.6)
Moderate disability (GOS 4)	21 (23.6)
Severe disability (GOS 3)	20 (22.5)
Vegetative state (GOS 2)	6 (6.7)
Mortality (GOS 1)	21 (23.6)
Total	89 (100)

tension have not been proved.

The purpose of treating traumatic brain injury is to prevent secondary injury and the establishment of a vicious cycle. However, decompressive craniectomy can be accompanied

**Table 4.** The relation between postoperative outcome and postoperative complications (univariate & multivariate analysis)

Complications	Univariate		Multivariate	
	Odd ratio (95% CI)	p value	Odd ratio (95% CI)	p value
Age	3.66 (1.36-9.87)	0.010	2.10 (0.65-6.71)	0.213
Sex	3.05 (0.36-25.60)	0.304	Not assessed	Not assessed
Hematoma contralateral to the craniectomy defect	2.28 (0.36-14.66)	0.385	Not assessed	Not assessed
Expansion of contusion	5.04 (1.36-18.75)	0.016	11.3 (1.11-115.25)	0.041
Postoperative epilepsy	1.65 (0.14-19.16)	0.689	Not assessed	Not assessed
External cerebral herniation	0.97 (0.24-3.90)	0.962	Not assessed	Not assessed
CSF leakage through skin incision	Not statistical	Not statistical	Not assessed	Not assessed
Postoperative infection	Not statistical	Not statistical	Not assessed	Not assessed
Subdural effusion	0.071 (0.01-0.56)	0.012	0.032 (0.00-0.43)	0.010
Post-traumatic hydrocephalus	Not statistical	Not statistical	Not assessed	Not assessed
Syndrome of the trephined	Not statistical	Not statistical	Not assessed	Not assessed

Complications with a *p* value of < 0.1 by univariate analysis were subjected to multivariate analysis

by several complications, which can adversely affect clinical outcome. The majority of these complications develop from normal pathophysiologic changes in ICP, CSF circulation and CBF following the removal of a large portion of skull. Several surgical complications were examined in the present study, whereas the majority of previous studies have concentrated on the management of increased ICP and clinical outcome, and relatively few have detailed the complications of decompressive craniectomy<sup>1,15,27,29,30</sup>. In previous studies, the most common complication of decompressive craniectomy for TBI was subdural hygroma, and the majority of patients affected resolved spontaneously<sup>1,15,27,29,30</sup> which concurs with our findings.

### Early complications

Contusion expansion or a new intracranial hematoma could develop after decompressive craniectomy contralateral or remote to the decompressed hemisphere. This complication may occur because of a reduction or loss of the tamponade effect<sup>10,22,27</sup> and may develop early after decompression<sup>27,29</sup>. Appropriate management based on close monitoring and early detection is the key to proper management.

The mechanism of postoperative epilepsy is still not fully understood, but graded increases in hyperexcitability and a reduced epileptogenic threshold have been suggested to be potential causes of seizure<sup>5</sup>. Prophylactic antiepileptics may prevent postoperative epilepsy, and we adopted this management strategy. As has been reported previously<sup>29</sup>, 3 of our patients (3.4%) developed postoperative epilepsy. However, this complication disappeared in all after increasing the dosage and/or adding other antiepileptics.

The mechanism of external cerebral herniation has been attributed to brain edema<sup>27</sup>. External cerebral herniation may cause cortical vein compression and cause cortical laceration resulting in venous infarction of herniated brain tissue<sup>27,29</sup> and cortical damage. Large craniectomies with augmentative

duraplasty allow the brain to expand outward without constriction, and thus, minimize the risk of venous infarction<sup>27,29</sup>. In the present study, this complication occurred in 13 patients (14.6%) although craniectomy of larger than 12 cm in diameter had been performed. However, surgical intervention, such as, decompressive lobectomy, was not used in any patient because of the lack of postoperative neurological deterioration, medically responsive ICP, and a CPP of larger than 70 mmHg. Furthermore, external cerebral herniation disappeared in all with time without surgical intervention. In addition, our analysis revealed that external cerebral herniation is unlikely to affect postoperative outcome, especially when a large craniectomy is performed.

CSF leakage occurred in 2 patients (2.2%) through small wound dehiscence, but was resolved by simple suture placement.

### Late complications

Subdural effusion is known to be caused by traumatic rupture of the dura-arachnoid interface and a resultant change in the dynamics of the CSF circulation<sup>4,27,29,30</sup>. In a recent report<sup>29</sup>, subdural effusion occurred at  $13.3 \pm 9$  days postoperatively and was the most common complication after decompressive craniectomy, which concurs with our findings. In our series, this complication resolved spontaneously in 28 of the 29 patients affected; the other patient had progressive neurological deterioration but recovered after surgical intervention.

Postoperative CNS infection can increase morbidity and mortality. *S. epidermidis* which is a major inhabitant of the skin has been reported to be the pathogen most commonly associated with postoperative infections and<sup>31</sup>. As previously described, clean skin preparation and prophylactic antibiotics are important for preventing these infections<sup>31</sup>. In the present study, 4 patients developed this complication and all responded to antibiotics.

## Delayed complications

Posttraumatic hydrocephalus develops when CSF flow is perturbed and the CSF circulation fails to normalize<sup>27,29</sup>. In the present study, 10 patients (11.2%) developed this complication and all underwent a VP shunt operation.

The syndrome of the trephined was first described by Grant and Norcross in 1939, who detailed its symptoms of headache, seizures, mood swings and behavioral disturbances<sup>12</sup>. After decompressive craniectomy, the scalp above the bone defect sinks because of a lack of bone support, which transmits atmospheric pressure directly to the brain, reduces the subarachnoid space, and exerts pressure on the underlying cortex, which perturbs CSF circulation and cerebral blood flow. Cranioplasty is beneficial in cases with syndrome of the trephined, and early cranioplasty after decompressive craniectomy has been recommended<sup>27,29,30</sup>. In the present study, 8 patients (9.0%) developed this complication and symptoms in all were much improved after cranioplasty.

In the present study, multivariate analysis showed patients without complications were more likely to achieve functional recovery (GOS 4-5) after surgery, and that the development of contusion expansion significantly indicated worse outcome. Therefore, it is important to prevent these complications and to detect them at the earliest opportunity after decompressive craniectomy.

The retrospective, non-randomized, non-controlled nature of this study, and the small number of patients recruited limit our ability to draw firm conclusions. Nevertheless, this study does show that complications following decompressive craniectomy have specific onset times and that some complications can affect postoperative outcome.

## CONCLUSION

Complications following decompressive craniectomy for TBI were found to occur at specific times, and the poor GCS score ( $\leq 8$ ) and the older age ( $\geq 65$ ) were found to be related to the occurrence of these complications. In addition, the lack of complications was found to be significantly associated with functional recovery (GOS 4-5) after surgery, and contusion expansion was found to affect postoperative outcome significantly. These results should allow neurosurgeons to better anticipate when complications are likely to develop and adopt to appropriate management strategies.

## References

1. Aarabi B, Hesdorffer DC, Ahn ES, Aresco C, Scalea TM, Eisenberg HM : Outcome following decompressive craniectomy for malignant swelling due to severe head injury. *J Neurosurg* 104 : 469-479, 2006
2. Albanese J, Leone M, Alliez JR, Kaya JM, Antonini F, Alliez B, et al. : Decompressive craniectomy for severe traumatic brain injury : Evaluation

tion of the effects at one year. *Crit Care Med* 31 : 2535-2538, 2003

3. Boret H, Fesselet J, Meaudre E, Gaillard PE, Cantais E : Cerebral microdialysis and P(t)O<sub>2</sub> for neuro-monitoring before decompressive craniectomy. *Acta Anaesthesiol Scand* 50 : 252-254, 2006
4. Carvi Y, Nievas MN, Hollerhage HG : Early combined cranioplasty and programmable shunt in patients with skull bone defects and CSF-circulation disorders. *Neurol Res* 28 : 139-144, 2006
5. Chen JW, Ruff RL, Eavery R, Wasterlain CG : Posttraumatic epilepsy and treatment. *J Rehabil Res Dev* 46 : 685-696, 2009
6. Chibbaro S, Tacconi L : Role of decompressive craniectomy in the management of severe head injury with refractory cerebral edema and intractable intracranial pressure. Our experience with 48 cases. *Surg Neurol* 68 : 632-638, 2007
7. Cooper PR, Rovit RL, Ransohoff J : Hemispheric craniectomy in the treatment of acute subdural hematoma : a re-appraisal. *Surg Neurol* 5 : 25-28, 1976
8. Danish SF, Barone D, Lega BC, Stein SC : Quality of life after hemispheric craniectomy for traumatic brain injury in adults. A review of the literature. *Neurosurg Focus* 26 : E2, 2009
9. DeWitt DS, Jenkins LW, Prough DS : Enhanced vulnerability to secondary ischemic insults after experimental traumatic brain injury. *New Horiz* 3 : 376-383, 1995
10. Flint AC, Manley GT, Gean AD, Hemphill JC 3rd, Rosenthal G : Post-operative expansion of hemorrhagic contusions after unilateral decompressive hemispheric craniectomy in severe traumatic brain injury. *J Neurotrauma* 25 : 503-512, 2008
11. Gaab MR, Rittierodt M, Lorenz M, Heissler HE : Traumatic brain swelling and operative decompression : a prospective investigation. *Acta Neurochir Suppl (Wien)* 51 : 326-328, 1990
12. Grant FC, Norcross NC : Repair of cranial defects by cranioplasty. *Ann Surg* 110 : 488-512, 1939
13. Guerra WK, Gaab MR, Dietz H, Mueller JU, Piek J, Fritsch MJ : Surgical decompression for traumatic brain swelling : indications and results. *J Neurosurg* 90 : 187-196, 1999
14. Huang AP, Tu YK, Tsai YH, Chen YS, Hong WC, Yang CC, et al. : Decompressive craniectomy as the primary surgical intervention for hemorrhagic contusion. *J Neurotrauma* 25 : 1347-1354, 2008
15. Jiang JY, Xu W, Li WP, Xu WH, Zhang J, Bao YH, et al. : Efficacy of standard trauma craniectomy for refractory intracranial hypertension with severe traumatic brain injury : a multicenter, prospective, randomized controlled study. *J Neurotrauma* 22 : 623-628, 2005
16. Juul N, Morris GF, Marshall SB, Marshall LF : Intracranial hypertension and cerebral perfusion pressure : influence on neurological deterioration and outcome in severe head injury. The Executive Committee of the International Selfotel Trial. *J Neurosurg* 92 : 1-6, 2000
17. Kim KH : Predictors for functional recovery and mortality of surgically treated traumatic acute subdural hematoma in 256 patients. *J Korean Neurosurg Soc* 45 : 143-150, 2009
18. Kjellberg RN, Prieto A Jr : Bifrontal decompressive craniotomy for massive cerebral edema. *J Neurosurg* 34 : 488-493, 1971
19. Kontopoulos V, Foroglou N, Patsalas J, Magras J, Foroglou G, Yiannakou-Pephtoulidou M, et al. : Decompressive craniectomy for the management of patients with refractory hypertension : should it be reconsidered? *Acta Neurochir (Wien)* 144 : 791-796, 2002
20. Kunze E, Meixensberger J, Janka M, Sorensen N, Roosen K : Decompressive craniectomy in patients with uncontrollable intracranial hypertension. *Acta Neurochir Suppl* 71 : 16-18, 1998
21. Langfitt TW, Tannanbaum HM, Kassell NF : The etiology of acute brain swelling following experimental head injury. *J Neurosurg* 24 : 47-56, 1966
22. Makino H, Yamaura A : Assessment of outcome following large decompressive craniectomy in management of serious cerebral contusion. A review of 207 cases. *Acta Neurochir Suppl (Wien)* 28 : 193-194, 1979
23. Marshall LF, Smith RW, Shapiro HM : The outcome with aggressive

- treatment in severe head injuries. Part I : the significance of intracranial pressure monitoring. *J Neurosurg* 50 : 20-25, 1979
24. Martins ET, Linhares MN, Sousa DS, Schroeder HK, Meinerz J, Rigo L A, et al. : Mortality in severe traumatic brain injury : a multivariated analysis of 748 Brazilian patients from Florianópolis City. *J Trauma* 67 : 85-90, 2009
  25. Polin RS, Shaffrey ME, Bogaev CA, Tisdale N, Germanson T, Bocchicchio B, et al. : Decompressive bifrontal craniectomy in the treatment of severe refractory posttraumatic cerebral edema. *Neurosurgery* 41 : 84-92; discussion 92-94, 1997
  26. Sahuquillo J, Arkan F : Decompressive craniectomy for the treatment of refractory high intracranial pressure in traumatic brain injury. *Cochrane Database Syst Rev* : CD003983, 2006
  27. Stiver SI : Complications of decompressive craniectomy for traumatic brain injury. *Neurosurg Focus* 26 : E7, 2009
  28. Yamakami I, Yamaura A : Effects of decompressive craniectomy on regional cerebral blood flow in severe head trauma patients. *Neurol Med Chir (Tokyo)* 33 : 616-620, 1993
  29. Yang XF, Wen L, Shen F, Li G, Lou R, Liu WG, et al. : Surgical complications secondary to decompressive craniectomy in patients with a head injury : a series of 108 consecutive cases. *Acta Neurochir (Wien)* 150 : 1241-1247; discussion 1248, 2008
  30. Yang XJ, Hong GL, Su SB, Yang SY : Complications induced by decompressive craniectomies after traumatic brain injury. *Chin J Traumatol* 6 : 99-103, 2003
  31. Zunt JR : Infections of the central nervous system in the neurosurgical patient. *Handb Clin Neurol* 96 : 125-141, 2010