

This is an Open Access article licensed under the terms of the Creative Commons Attribution-NonCommercial-NoDerivs 3.0 License ([www.karger.com/OA-license](http://www.karger.com/OA-license)), applicable to the online version of the article only. Distribution for non-commercial purposes only.

# Keratitis after Implantation of Intrastromal Corneal Rings with Spontaneous Extrusion of the Segment

Juan Ibáñez-Alperte Diana Pérez-García José A. Cristóbal  
Antonio J. Mateo Beatriz Jiménez-del Río  
Enrique Mínguez

Department of Ophthalmology, 'Lozano Blesa' University Clinic Hospital,  
Zaragoza, Spain

## Key Words

INTACS® · Intrastromal rings · Keratitis · Segment extrusion

## Abstract

**Purpose:** To report a case of bacterial keratitis in a patient with a history of intrastromal corneal ring segments (INTACS®) implantation to correct keratoconus.

**Methods:** The patient's history, clinical presentation, pathological analysis and therapeutic management were reviewed.

**Results:** A 36-year-old-man was referred to our department due to decreased vision and intense pain in his left eye, 40 days after INTACS® implantation for keratoconus. Slit-lamp examination revealed epithelial defects and stromal infiltrates in the lower channel without evidence of the inferior ring. The anterior chamber also showed a significant fibrin reaction to hypopyon. A low-tension suture was removed at the site of the incision. Microbiological study of the conjunctival swab was positive for *Staphylococcus epidermidis*, but the corneal culture was sterile. The patient was treated with topical fortified and systemic antibiotics. The infection slowly resolved, leaving opacity at the inferior segment site.

**Conclusions:** Infectious keratitis following INTACS implantation is an infrequent complication that can have important consequences without suitable and early therapeutic management.

## Introduction

Intrastromal rings (INTACS®) are semicircular segments of polymethyl methacrylate (PMMA) that are implanted in the corneal periphery medium, either manually through a

radial incision or assisted by IntraLase, a technique that is currently increasing in popularity. These implants, initially designed to correct myopia in normal eyes, are implanted with the aim of achieving modifications to the corneal curvature and refractive adjustments. In 2000, Colin et al. [1] were the first to report the efficacy of these implants in keratoconus eyes. Besides keratoconus, intrastromal corneal ring segments have also been used successfully for the management of pellucid marginal degeneration and post-laser in situ keratomileusis corneal ectasia. This approach provides multiple benefits primarily based on the potential reversibility of the technique and the relative ease of implementation, which allows preservation of the central corneal area. However, like any surgical procedure, the technique is not exempt from complications, such as protrusion, migration or segment extrusion, perforations during surgery and infection after implantation. Although the frequency of these complications is low, their occurrence causes a significant decrease in the visual prognoses of these patients.

We report a clinical case of the development of a keratitis after implantation of INTACS® with spontaneous segment extrusion.

### Materials and Methods

A male patient came to the emergency department of our hospital for severe pain, blepharospasm, photophobia and decreased visual acuity in his left eye for 2 days.

As part of his clinical history, the patient had undergone INTACS® implantation, using the manual technique, 40 days previously without complications in the immediate postoperative period, and he had been monitored regularly. The patient reported no remarkable systemic disease nor was he undergoing any treatment.

The corrected visual acuity was of hand motion for the right eye and 0.5 for the left eye (–5 to 45°). Biomicroscopy revealed the existence of a corneal ulcer in the corneal bed of the lower intrastromal segment observed in the absence of the segment, with an important fibrinoid reaction in the anterior chamber and approximately 1 mm of hypopyon ([fig. 1](#)). A low-tension suture was removed at the site of the incision.

### Results

Upon hospitalisation, we proceeded to perform cell cultures of corneal conjunctival secretions and necrotic corneal material. Empirical treatment was established using vancomycin and ceftazidime eye drops, repeated hourly, and topical mydriatics, in addition to intravenous antibiotics (vancomycin 1 g/12 h, ciprofloxacin 400 mg/12 h).

The cultures were negative, yet clinical improvement was progressive, indicating a response to the administered antibiotics. Therefore, the patient was discharged after a period of 11 days. The corneal appearance after the infectious process revealed paracentral leucoma with a depression of the corneal surface. The visual axis was preserved, allowing a visual acuity of 0.1 ([fig. 2](#)).

### Discussion

The use of INTACS® has been expanding rapidly in the management of keratoconus because of the technique's safety and effectiveness. Infection after implantation is a rare

and severe complication of the procedure, the appearance of which has been documented from 1 week to more than 1 year after surgery [2], hence the importance of prolonged follow-up of these patients.

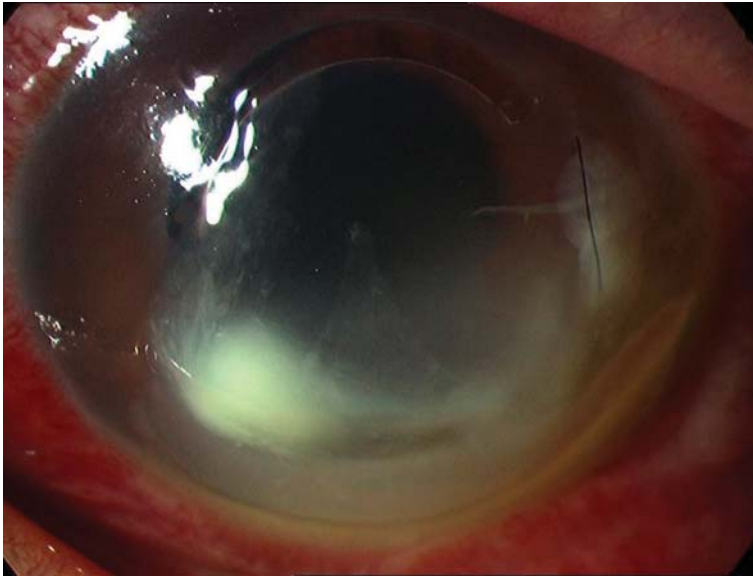
*Staphylococcus aureus* is generally the most frequently isolated pathogen, appearing in up to 25% of cases, followed by *Streptococcus pneumoniae*, *Pseudomonas sp.*, *Nocardia sp.*, *Klebsiella sp.* and *Paecilomices sp.* [3, 4], yet our culture did not yield any of these species. In turn, there have been several factors that have been found to be related to the development of this complication, such as the use of contact lenses, previous trauma or systemic diseases such as diabetes mellitus [3]. In our case, the low tension level of the suture incision in the channel may have led to the entrance of the microorganism responsible for the development of the infection [5].

Other authors also believe that the manual technique used in this study (as compared to the use of IntraLase) may increase the risk of developing these infectious complications [6].

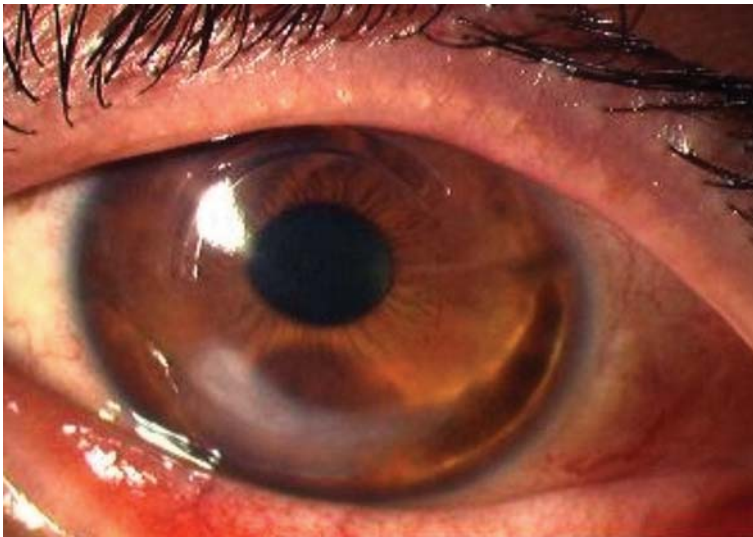
In conclusion, the implantation of intrastromal rings, especially in cases of keratoconus, may be associated with infectious complications, as with other surgical techniques, highlighting the relevance of early recognition of clinical signs as well as the early introduction of appropriate treatment to achieve the appropriate resolution of the condition and better functional results.

#### **Conflict of Interest**

The authors have no proprietary interest. No grants and funds have been received in support of the study. No financial support was received.



**Fig. 1.** Corneal ulcer of the corneal bed of the lower intrastromal segment and significant fibrinoid reaction in the anterior chamber. The existence of a low-tension suture at the point of incision can also be seen.



**Fig. 2.** Final result with an area of paracentral leucoma that does not affect the visual axis.

### References

- 1 Colin J, Cochener B, Savary G, Malet F: Correcting keratoconus with intracorneal rings. *J Cataract Refract Surg* 2000;26:1117–1122.
- 2 Bourcier T, Borderie V, Laroche L: Late bacterial keratitis after implantation of intrastromal corneal ring segments. *J Cataract Refract Surg* 2003;29:407–409.

- 3 Hofling-Lima AL, Branco BC, Romano AC, Campos MQ, Moreira H, Miranda D, Kwitko S, de Freitas D, Casanova FH, Sartori M, Schor P, Souza LB: Corneal infections after implantation of intracorneal ring segments. *Cornea* 2004;23:547–549.
- 4 Shehadeh-Masha'our R, Modi N, Barbara A, Garzozzi HJ: Keratitis after implantation of intrastromal corneal ring segments. *J Cataract Refract Surg* 2004;30:1802–1804.
- 5 Hashemi H, Ghaffari R, Mohammadi M, Moghimi S, Miraftaab M: Microbial keratitis after INTACS implantation with loose suture. *J Refract Surgery* 2008;24:551–552.
- 6 Sánchez F: Use of IntraLase for Ferrara ring and INTACS implantation in keratoconus and LASIK ectasia treatment. Paper presented at the World Cornea Congress Meeting, April 14, 2005, Washington DC.