

# Impaired consciousness in temporal lobe seizures: role of cortical slow activity

Dario J. Englot,<sup>1</sup> Li Yang,<sup>2</sup> Hamada Hamid,<sup>2</sup> Nathan Danielson,<sup>2</sup> Xiaoxiao Bai,<sup>2</sup> Anthony Marfeo,<sup>2</sup> Lissa Yu,<sup>2</sup> Aliza Gordon,<sup>2</sup> Michael J. Purcaro,<sup>2</sup> Joshua E. Motelow,<sup>2</sup> Ravi Agarwal,<sup>2</sup> Damien J. Ellens,<sup>2</sup> Julie D. Golomb,<sup>3</sup> Michel C. F. Shamy,<sup>2</sup> Heping Zhang,<sup>4</sup> Chad Carlson,<sup>5</sup> Werner Doyle,<sup>6</sup> Orrin Devinsky,<sup>5</sup> Kenneth Vives,<sup>7</sup> Dennis D. Spencer,<sup>7</sup> Susan S. Spencer,<sup>2,7</sup> Catherine Schevon,<sup>8</sup> Hitten P. Zaveri<sup>2</sup> and Hal Blumenfeld<sup>2,3,7</sup>

1 Department of Neurosurgery, University of California, San Francisco, CA 94122, USA

2 Department of Neurology, Yale University School of Medicine, New Haven, CT 06520, USA

3 Department of Neurobiology, Yale University School of Medicine, New Haven, CT 06520, USA

4 Yale University School of Public Health, 60 College Street, New Haven, CT 06520, USA

5 Department of Neurology, New York University School of Medicine, New York, NY 10016, USA

6 Department of Neurosurgery, New York University School of Medicine, New York, NY 10016, USA

7 Department of Neurosurgery, Yale University School of Medicine, New Haven, CT 06520, USA

8 Department of Neurology, Columbia University Medical Center, New York, NY 10032, USA

Correspondence to: Prof. Hal Blumenfeld, MD, PhD,  
Department of Neurology,  
Yale University School of Medicine,  
333 Cedar Street,  
New Haven,  
CT 06520-8018, USA  
E-mail: hal.blumenfeld@yale.edu

Impaired consciousness requires altered cortical function. This can occur either directly from disorders that impair widespread bilateral regions of the cortex or indirectly through effects on subcortical arousal systems. It has therefore long been puzzling why focal temporal lobe seizures so often impair consciousness. Early work suggested that altered consciousness may occur with bilateral or dominant temporal lobe seizure involvement. However, other bilateral temporal lobe disorders do not impair consciousness. More recent work supports a 'network inhibition hypothesis' in which temporal lobe seizures disrupt brainstem–diencephalic arousal systems, leading indirectly to depressed cortical function and impaired consciousness. Indeed, prior studies show subcortical involvement in temporal lobe seizures and bilateral frontoparietal slow wave activity on intracranial electroencephalography. However, the relationships between frontoparietal slow waves and impaired consciousness and between cortical slowing and fast seizure activity have not been directly investigated. We analysed intracranial electroencephalography recordings during 63 partial seizures in 26 patients with surgically confirmed mesial temporal lobe epilepsy. Behavioural responsiveness was determined based on blinded review of video during seizures and classified as impaired (complex-partial seizures) or unimpaired (simple-partial seizures). We observed significantly increased delta-range 1–2 Hz slow wave activity in the bilateral frontal and parietal neocortices during complex-partial compared with simple-partial seizures. In addition, we confirmed prior work suggesting that propagation of unilateral mesial temporal fast seizure activity to the bilateral temporal lobes was significantly greater in complex-partial than in simple-partial seizures. Interestingly, we found that the signal power of frontoparietal slow wave activity was significantly correlated with the temporal lobe fast seizure activity in each hemisphere. Finally, we observed that complex-partial seizures were somewhat more common with onset in the language-dominant temporal

lobe. These findings provide direct evidence for cortical dysfunction in the form of bilateral frontoparietal slow waves associated with impaired consciousness in temporal lobe seizures. We hypothesize that bilateral temporal lobe seizures may exert a powerful inhibitory effect on subcortical arousal systems. Further investigations will be needed to fully determine the role of cortical-subcortical networks in ictal neocortical dysfunction and may reveal treatments to prevent this important negative consequence of temporal lobe epilepsy.

**Keywords:** cortex; EEG; seizures; temporal lobe epilepsy; consciousness

## Introduction

Consciousness depends on normal activity in widespread bilateral cortical networks and is modulated by subcortical arousal systems. Disorders of consciousness can be seen with lesions that either disrupt broad regions of the bilateral frontoparietal association cortex or that interfere with arousal mechanisms in the brainstem–diencephalon (Posner *et al.*, 2007; Laureys and Tononi, 2008). In temporal lobe epilepsy, focal temporal lobe seizures produce a unique repertoire of behavioural changes. As expected, epileptic discharges in the mesial temporal lobe evoke typical limbic system-associated symptoms including fear, autonomic changes, a rising epigastric sensation and memory impairment (Engel and Pedley, 2007). However, a more puzzling feature not easily explained by mesial temporal involvement is the common occurrence of behavioural unresponsiveness or impaired consciousness. Why should focal seizure discharges in unilateral or even bilateral mesial temporal structures cause impaired consciousness?

Prior work suggests that effects of temporal lobe seizures on structures beyond the mesial temporal lobe may be important for impaired consciousness. Partial seizures that impair consciousness are traditionally called complex-partial seizures, while consciousness is spared in simple-partial seizures (ILAE, 1981). Patients with temporal lobe epilepsy often experience complex-partial seizures and simple-partial seizures. Early studies proposed that complex-partial seizures occur when seizures propagate from the ipsilateral mesial temporal lobe to involve the bilateral temporal cortex (Gloor *et al.*, 1980; Pedley, 1992; Bancaud *et al.*, 1994). Nevertheless, while bilateral limbic dysfunction can result in amnesia (Milner, 1972), temporal lobe dysfunction alone does not typically cause impaired behavioural responsiveness. One possibility is that rather than directly impairing consciousness, bilateral temporal lobe seizure activity may instead be a marker of downstream disruption of other bilateral networks more crucial for modulation of consciousness. Thus, it has been suggested that temporal lobe seizures could impair consciousness by affecting subcortical arousal systems (Penfield and Jasper, 1954). Indeed, the development of neuroimaging methods including ictal single photon emission computed tomography revealed that temporal lobe seizures exhibit abnormal increased cerebral blood flow in the upper brainstem and medial diencephalon, associated with impaired consciousness (Lee *et al.*, 2002; Blumenfeld *et al.*, 2004b; Tae *et al.*, 2005); confirmed by direct electrical recordings from the thalamus (Guye *et al.*, 2006; Arthuis *et al.*, 2009).

Ultimately however, impaired consciousness must involve dysfunction of the neocortex, since any process that affects

consciousness will alter cortical function either directly or indirectly through effects on subcortical networks. Other states of impaired consciousness such as coma, encephalopathy or deep sleep often exhibit cortical slow wave activity associated with decreased cerebral blood flow and metabolism (Steriade *et al.*, 1993; Cowan and Wilson, 1994; Haider *et al.*, 2006; Laureys and Tononi, 2008). Interestingly, intracranial electroencephalography (EEG) studies have shown that large amplitude 1–2 Hz slow activity can also occur in the frontal and parietal neocortices during (ictal) and immediately following (postictal) temporal lobe seizures (Lieb *et al.*, 1991; Blumenfeld *et al.*, 2004a). This slow wave activity is accompanied by decreased cerebral blood flow in the same frontoparietal neocortical regions (Van Paesschen *et al.*, 2003; Blumenfeld *et al.*, 2004b). Thus, unlike fast seizure activity that exhibits increased cerebral blood flow and metabolism, we have proposed that ictal neocortical slow wave activity represents a depressed cortical state, more closely resembling coma or deep sleep than seizures. We have further hypothesized that this depressed cortical function occurs when temporal lobe seizures propagate to subcortical structures and inhibit their normal arousal mechanisms (Blumenfeld and Taylor, 2003; Englot and Blumenfeld, 2009b). While human imaging studies (Blumenfeld *et al.*, 2004b) and recent investigations of limbic seizures in the rat provide initial support for this ‘network inhibition hypothesis’ (Englot *et al.*, 2008, 2009), direct study of neocortical rhythms during complex-partial seizures versus simple-partial seizures in human patients is crucial.

To date, no quantitative measurements of ictal neocortical slow activity during temporal lobe seizures have been described; a link between cortical slowing and impaired consciousness during seizures has not been established and the relationship between fast activity in the temporal lobes and slow waves in the frontoparietal neocortex in temporal lobe epilepsy remains unknown. Thus, the main goal of our present study was to use human intracranial EEG to investigate changes in cortical electrical activity during complex-partial seizures versus simple-partial seizures and to determine how these changes are related to seizure activity in the temporal lobes. We found that neocortical slow activity is observed in bilateral frontoparietal cortices during complex-partial seizures, associated with impaired responsiveness, but not during simple-partial seizures, during which responsiveness is intact. Interestingly, neocortical slow activity is significantly correlated with bilateral temporal lobe seizure activity, which in turn is also associated with behavioural unresponsiveness ictally. We therefore hypothesize that during complex-partial seizures, seizure spread to bilateral temporal lobes may lead to ictal neocortical slow activity

and loss of consciousness, possibly through the disruption of normal subcortical activating systems.

## Materials and methods

### Patients

All procedures were in accordance with the institutional review boards for human studies at Yale University School of Medicine and New York University School of Medicine, as well as National Institutes of Health guidelines. Informed consent was obtained from all subjects. Inclusion and exclusion criteria were chosen to identify a relatively homogenous group of patients with confirmed mesial temporal lobe epilepsy who had undergone intracranial EEG and video monitoring. Consecutive patients with the following inclusion criteria were used: (i) intracranial EEG monitoring performed between 1995 and 2008 at Yale or 2003 and 2004 at New York University; (ii) surgical pathology demonstrating hippocampal sclerosis; and (iii) successful surgery with no seizures during a minimum follow-up period of 1 year after anteromedial temporal lobe resection. The following seizures were excluded from analysis: secondarily generalized seizures, seizures in which intact or impaired behavioural responsiveness could not be determined (e.g. no one interacted with the patient during the seizure or video not available) and subclinical electrographic seizures (no event button pushed and no other behavioural changes). A total of 63 seizures from 26 patients (18 from Yale and 8 from New York University) were used for the analysis. Twelve patients were male, 14 were female and the mean age was 35 years (range 17–52 years). Twenty-three patients were right-handed and three were left-handed. All patients underwent Wada testing via the intracarotid sodium amobarbital procedure as part of a preoperative neuropsychological testing battery. Based on Wada testing, 21 patients were found to be dominant in the left hemisphere for language production, two patients were right-dominant and three patients showed mixed or bilateral language dominance.

### Anatomic localization of electrode positions

Surgical implants included subdural strip, grid and depth electrode contacts (AdTech Medical Instruments Corp., Racine, WI, USA). Preoperative planning of intracranial electrode locations was decided in each case based on clinical grounds; therefore electrode positions were not standardized. However, electrode coverage in all cases included at least several frontal or parietal neocortical contacts ipsilateral and/or contralateral to the side of seizure onset. Bilateral electrodes were implanted in 20 of the 26 patients. Depth electrodes, together with strip electrodes, were used most commonly to study mesial temporal structures, while grids and strips were typically used to study other regions. Routine high-resolution MRI scans were performed on all patients after intracranial electrode implantation using 3D volume inversion recovery prepopped fast spoiled gradient recalled echo (IR-FSPGR) imaging on a 1.5 T system. Surface reconstructions were then obtained with lateral, medial and inferior views of both hemispheres to determine the positions of all electrode contacts. The brain surface was segmented into the following anatomical regions for both ipsilateral and contralateral hemispheres: mesial temporal, lateral temporal, orbital frontal, lateral frontal, medial frontal, lateral parietal, medial parietal, perirolandic (pre- and post-central gyri) and occipital. Boundaries used for these anatomic regions have been

shown and described in detail previously (Blumenfeld *et al.*, 2004a). Electrode contacts identified on the MRI scans were assigned to these regions for EEG analysis, as previously described (Blumenfeld *et al.*, 2004a). Contacts lying intermediate between two anatomic regions or in the subcortical white matter were excluded from analysis. Medial parietal cortical electrodes were also excluded as data were available for only two seizures for this region. The total numbers of EEG recordings analysed for each anatomical region during seizures are provided in Supplementary Table 1.

### Intracranial electroencephalography recordings

For patients at Yale, intracranial EEG signals were recorded continuously using Telefactor Beehive systems (Grass Telefactor, Astro-Med, Inc., West Warwick, RI, USA) or Bio-Logic Systems 128-channel clinical EEG and video monitoring equipment (Bio-Logic Systems Corp., Mundelein, IL, USA). Amplifier systems were either single-ended with ground and reference tied together, or separate ground and reference, with 128 EEG channels acquired at 12 bit A/D conversion, 200 Hz sampling (256 Hz for Bio-Logic system), 90 dB common-mode rejection ratio, with low-frequency filter setting of 0.1 Hz and high-frequency filter setting of 70 Hz. For patients at New York University, 128 intracranial EEG channels were acquired continuously at 12 bit A/D conversion using the BMSI 5000/6000 EEG system (Nicolet Biomedical, Inc., Madison, WI, USA). Signals were sampled at 400 Hz, amplified (85 dB common-mode rejection ratio) and filtered between a low-frequency setting of 0.5 Hz and high-frequency setting of 65 Hz.

### Electroencephalography analysis

During EEG analysis, times of seizure onset and termination were first identified for each seizure based on the onset and end of fast poly-spike activity on the intracranial EEG. For seizures beginning with periodic spiking followed by low-voltage fast activity, onset was defined as the beginning of low-voltage fast activity. The EEG data were segmented into 1 s segments. Artefacts were delineated in the data records and 1 s segments with artefacts were removed from the analysis. EEG signals from all electrodes were processed by fast Fourier transform analysis for each 1 s segment and signal power was calculated for each electrode corresponding to each of the following frequency bands: delta (0.5 to <4 Hz), theta (4 to <8 Hz), alpha (8–13 Hz), beta (>13 to <25 Hz) and gamma (25–50 Hz) ranges. For each seizure, raw EEG signals were assigned to the anatomical region (see above) of their respective electrode contacts, averaged with signals of other contacts in that location and synchronized to time of temporal lobe seizure onset. Group data for all complex-partial seizures and simple-partial seizures were plotted as mean ( $\pm$ SEM) fractional signal change [(EEG signal power—baseline power)/baseline power] from an uninterrupted 60 s baseline for all data from 60 s before to 300 s after seizure onset in non-overlapping 10 s bins (0 s = seizure onset). Overall fractional signal change during seizure versus baseline was also measured by taking the mean for each seizure, except for seizures lasting longer than 300 s, for which only the first 300 s of seizure data were analysed.

It was noted that temporal lobe seizure activity caused particularly large increases in beta-range activity and frontoparietal neocortical slow waves resulting in dramatically elevated delta activity. Therefore, we generated 3D representations of beta and delta EEG activity changes for one example each of a complex-partial seizure

and simple-partial seizure to more clearly ascertain the anatomical distributions affected by seizure and slow activity. Reconstruction of the pial surface was based on the patient's  $T_1$ -weighted high-resolution MRI using the FreeSurfer image analysis suite (Martinos Centre for Biomedical Imaging at Massachusetts General Hospital, Boston, MA, USA) (Dale *et al.*, 1999; Fischl *et al.*, 1999). The resulting triangular mesh surface model was imported into MATLAB (MathWorks, Natick, MA, USA). Electrodes were manually placed on the pial surface according to a postoperative MRI and fractional change in delta- or beta-range EEG power during the entire seizure (versus uninterrupted 60 s baseline) was assigned to each electrode, representing signal power by colour. A nearest-neighbour approach was used to colour the faces of the triangular mesh with the colour of the closest electrode and a linear fade to zero was then applied over the radius from 1 to 15 mm surrounding each electrode. To produce 3D movies of signal power during these seizures the same procedure was repeated using a moving 10 s window at 1 s increments of fractional signal power changes relative to 60 s baseline.

To statistically analyse group differences in mean temporal beta and neocortical delta activity change during complex-partial seizures versus simple-partial seizures, we used the non-parametric Mann–Whitney U-test, given lack of a normal distribution in complex-partial seizure and simple-partial seizure temporal lobe beta and neocortical delta-range data ( $P < 0.05$ , Shapiro–Wilk test of distribution normality). Occipital and perirolandic regions were not analysed in detail, as they were not typically involved in ictal neocortical slow activity, in agreement with previous work (Blumenfeld *et al.*, 2004a). All statistical tests were performed using SPSS 17 (IBM, Chicago, IL, USA) with significance assessed at  $P \leq 0.05$ .

## Behavioural analysis

Videos of all seizures were viewed and rated by two to four reviewers who were provided with seizure onset and end times based on intracranial EEG, but were otherwise blinded to the EEG data for each respective seizure. The reviewers rated the seizures using a simple two-level classification modified from Lee *et al.* (2002) as described previously (Blumenfeld *et al.*, 2004b). Seizures in which patients had any impaired responsiveness to verbal questions, failed to correctly follow simple commands or exhibited amnesia were classified as complex-partial. Seizures in which patients remained fully alert and appropriately interactive throughout the event were classified as simple-partial. All patients included in the study were presented with questions or commands during seizures by either medical staff or family members. Seizures in which staff or family members did not interact with the patient at any time during the seizure could not be rated and were excluded from analysis, as were seizures with no video. Seizures without unanimous reviewer consensus were also excluded with the exception of seizures rated by three to four experimenters if only one reviewer disagreed. The latter were assigned based on the majority rating. The overall concordance rate between reviewer ratings of analysed seizures was 92%, with a statistically significant inter-rater reliability by Fleiss' generalized kappa measurement ( $\kappa = 0.80$ ,  $P < 0.001$ ).

## Results

We studied intracranial EEG recordings during 38 complex-partial seizures and 25 simple-partial seizures in 26 patients, with behavioural seizure type determined by blinded observer video ratings.

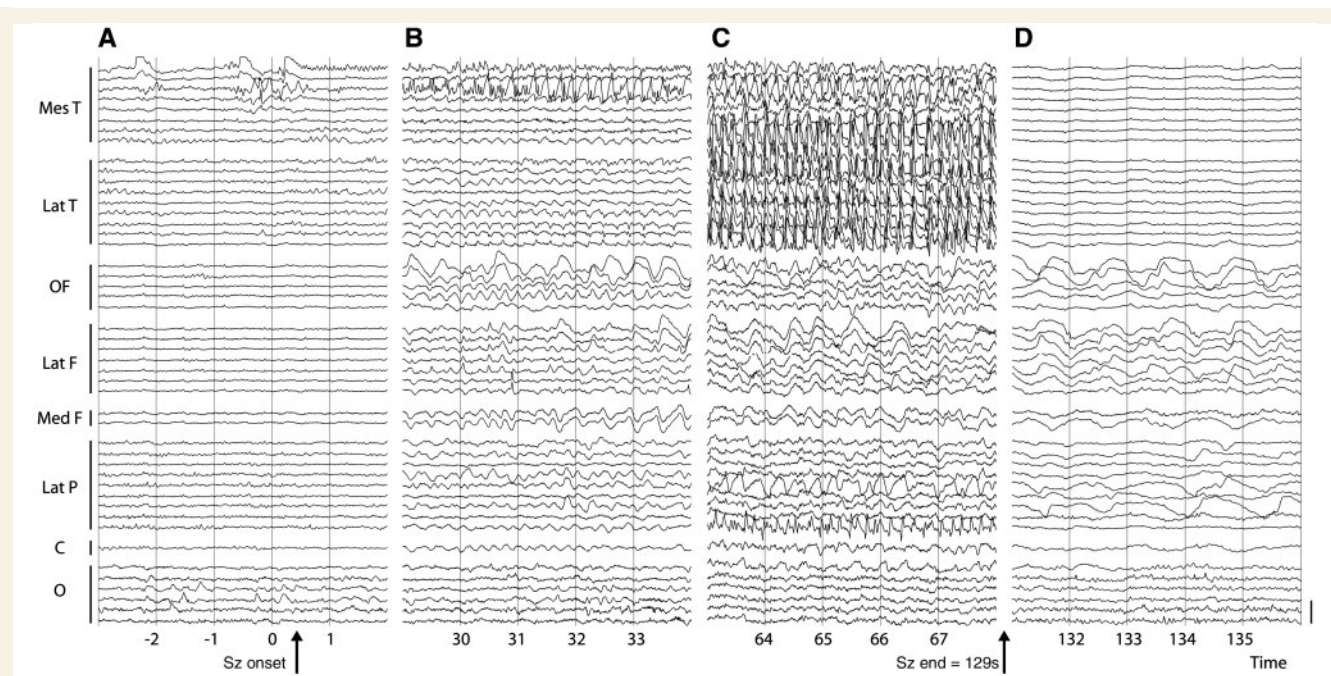
Forty-nine additional seizures were excluded because behavioural responsiveness could not be determined or video was not available. Mean durations of the 63 included seizures were  $168 \pm 21$  s (mean  $\pm$  SEM) for complex-partial seizures and  $201 \pm 39$  s for simple-partial seizures.

## Neocortical slow activity is prominent in complex-partial but not simple-partial seizures

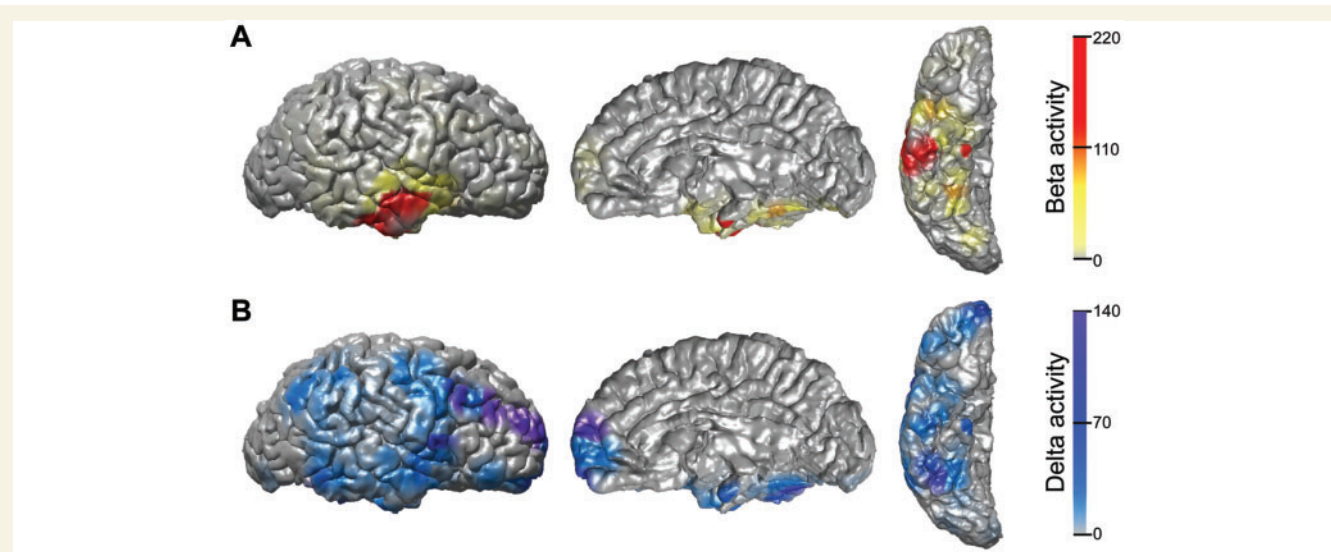
We first examined electrographic changes ipsilateral to the side of seizure onset during complex-partial seizures versus simple-partial seizures. Examples of typical changes observed are shown in Figs 1–4. Figure 1 shows an intracranial EEG recording during a complex-partial seizure with impaired behavioural responsiveness. The seizure begins with low-voltage fast activity in the mesial temporal lobe, most prominent in the beta-frequency range (Fig. 1A). The fast activity later propagates to involve both the mesial and lateral temporal lobe contacts throughout (Fig. 1B and C). Fast seizure spiking does not propagate to the frontoparietal cortex. However, dramatic large-amplitude slow waves, mainly in the 1–2 Hz delta-frequency range, emerge ictally in numerous neocortical regions, particularly the orbital, lateral and medial frontal cortex, as well as the lateral parietal cortex (Fig. 1B and C). After seizure termination, temporal lobe activity is suppressed, although frontoparietal slow activity continues in the postictal period (Fig. 1D).

To more clearly visualize the anatomical distribution of fast seizure activity versus emergent slow rhythms over the surface of the brain during this example complex-partial seizure, we created 3D colour maps of fractional change in beta-range and delta-range EEG activity (Fig. 2). These frequency bands were chosen as they were most greatly affected by seizure and slow activity, respectively and are shown for the entire seizure versus 60 s baseline. Large increases in beta activity are focused in the mesial temporal lobe, the site of seizure origin and in the lateral temporal lobe, representing seizure spread, with few changes in other cortical regions (Fig. 2A). In contrast, dramatic elevations in delta activity are seen in frontal and parietal association cortex, indicating ictal neocortical slow activity, as well as in regions of the mesial and lateral temporal lobe affected by fast seizure activity (Fig. 2B). Perirolandic and occipital regions appear relatively spared (Fig. 2B). Electrode locations used for this 3D EEG analysis are shown in Supplementary Fig. 1A and colour map time course is shown in Supplementary Video 1.

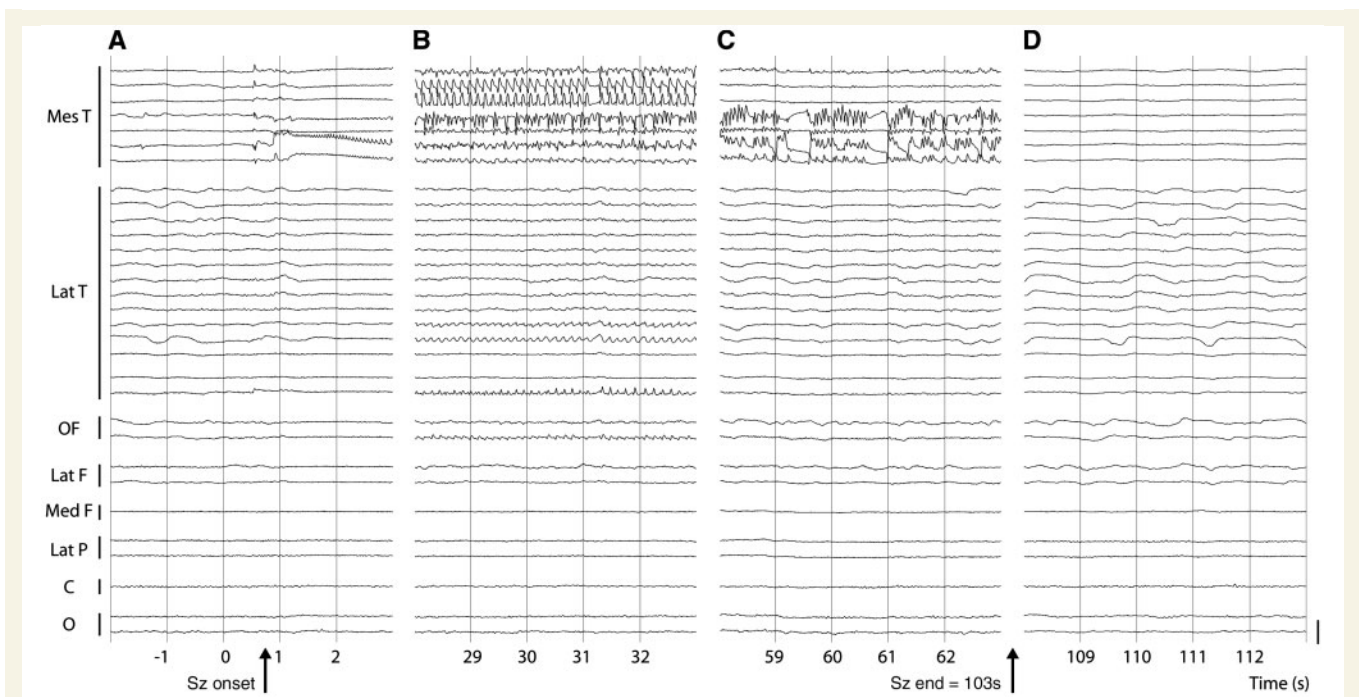
During an example intracranial recording of a simple-partial seizure with preserved behavioural responsiveness, the seizure again begins with low-voltage fast beta activity in the mesial temporal lobe (Fig. 3A). However, during the simple-partial seizure there is little seizure involvement observed in lateral temporal lobe contacts (Fig. 3B and C). Furthermore, no large amplitude delta-frequency slowing is seen in the frontoparietal neocortex during (Fig. 3B and C) or after (Fig. 3D) the event. Examining EEG changes during seizure versus baseline on a 3D colour map, beta activity elevations are observed in the mesial temporal lobe (Fig. 4A), where the seizure originates, but few changes are seen in the lateral temporal lobe. While increased delta activity is seen



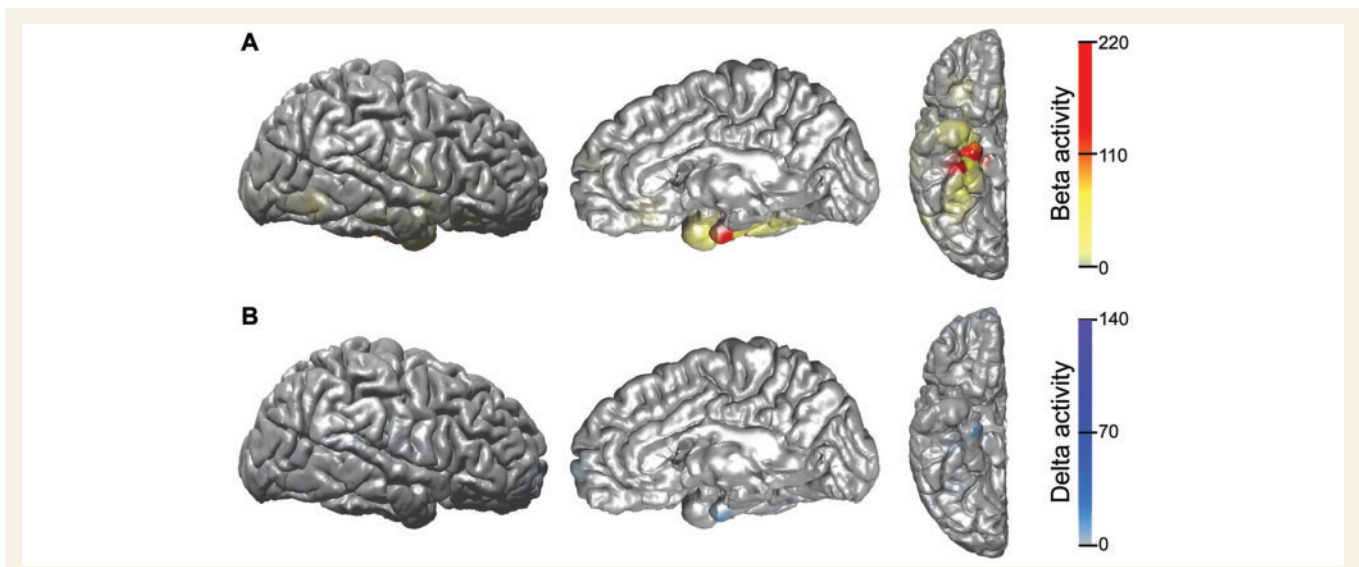
**Figure 1** Example intracranial EEG recording during a temporal lobe complex-partial seizure. (A) Seizure (Sz) onset with low-voltage fast activity emerging from periodic spiking in the mesial temporal contacts. (B) Sample EEG from early seizure. Rhythmic poly-spike and sharp wave activity develops in the mesial temporal lobe, while the frontal and parietal contacts show large-amplitude irregular slow activity. (C) Sample EEG from mid-seizure. Poly-spike and wave activity is present in the mesial and lateral temporal lobe contacts, with ongoing slow waves in the association cortex. Rolandic and occipital contacts are relatively spared. (D) Postictal suppression is seen in temporal lobe contacts, with continued irregular slowing in the frontoparietal neocortex. Only ipsilateral contacts are shown. Bars along left margin indicate electrode contacts from different strips, grids or depth electrodes in the indicated brain regions. A subset of representative electrodes are shown of the 128 studied in this patient. Calibration bar on right is 3 mV. Montage is referential to mastoid. Mes T = mesial temporal; Lat T = lateral temporal; OF = orbital frontal; Lat F = lateral frontal; Med F = medial frontal; Lat P = lateral parietal; C = perirolandic pre- and post-central gyri; O = occipital.



**Figure 2** Three dimensional colour maps of beta and delta activity changes during a complex-partial seizure. (A) Large elevations in fast beta activity are seen in the mesial and lateral temporal lobe during the event, representing regions of seizure onset and propagation, respectively. (B) Increased delta activity is most dramatic in the frontal and parietal association cortices, where there is no fast seizure activity (A), as well as in the mesial and lateral temporal lobe, where fast seizure activity is also present (A). The occipital and perirolandic areas are relatively spared. Data shown are fractional change in beta- (A) or delta- (B) range EEG signal power during the entire seizure versus a 60 s uninterrupted baseline, overlaid on lateral, medial and ventral views of a 3D reconstruction of the patient's pre-implant MRI. Electrode locations are shown in Supplementary Fig. 1A. Only the ipsilateral (right) hemisphere is shown. Raw EEG of the same seizure is shown in Fig. 1 and 3D colour map time course is shown in Supplementary Video 1.



**Figure 3** Example intracranial EEG recording during a temporal lobe simple-partial seizure. (A) Seizure (Sz) onset with low-voltage fast activity emerging from periodic spiking in the mesial temporal contacts. (B) Sample EEG from early seizure. Rhythmic poly-spike and sharp wave activity continues in the mesial temporal lobe. Few changes are observed in lateral temporal and other cortical contacts. (C) Sample EEG from mid-seizure. Poly-spike and wave activity continues in the mesial temporal lobe, while other contacts show activity resembling pre-seizure baseline. No large-amplitude cortical slow activity is seen. (D) Postictal suppression is seen in the mesial temporal lobe. Only ipsilateral contacts are shown. Bars along left margin indicate electrode contacts from different strips, grids or depth electrodes in the indicated brain regions. A subset of representative electrodes are shown of the 128 studied in this patient. Calibration bar on right is 3 mV. Montage is referential to mastoid. Mes T = mesial temporal; Lat T = lateral temporal; OF = orbital frontal; Lat F = lateral frontal; Med F = medial frontal; Lat P = lateral parietal; C = perirolandic pre- and post-central gyri; O = occipital.



**Figure 4** Three dimensional colour maps of beta and delta activity changes during a simple-partial seizure. (A) Elevations in fast beta activity are seen in the mesial temporal lobe, the site of seizure onset, with minimal lateral temporal involvement. (B) Increased delta activity is seen in the mesial temporal lobe, in the same region as the ictal beta activity, but the neocortex is relatively spared. Data shown are fractional change in beta- (A) or delta- (B) range EEG signal power during the entire seizure versus a 60 s uninterrupted baseline, overlaid on lateral, medial and ventral views of a 3D reconstruction of the patient's pre-implant MRI. Electrode locations are shown in Supplementary Fig. 1B. Only the ipsilateral (right) hemisphere is shown. Raw EEG of the same seizure is shown in Fig. 3 and 3D colour map time course is shown in Supplementary Video 2.

at the mesial temporal seizure focus, no frontoparietal delta elevations are visualized in the association cortex (Fig. 4B). Electrode locations used for this 3D EEG analysis are shown in Supplementary Fig. 1B and colour map time course is shown in Supplementary Video 2. A brief summary of cortical regions typically displaying dramatic elevations in fast beta or slow delta activity during both seizure types is provided in Table 1.

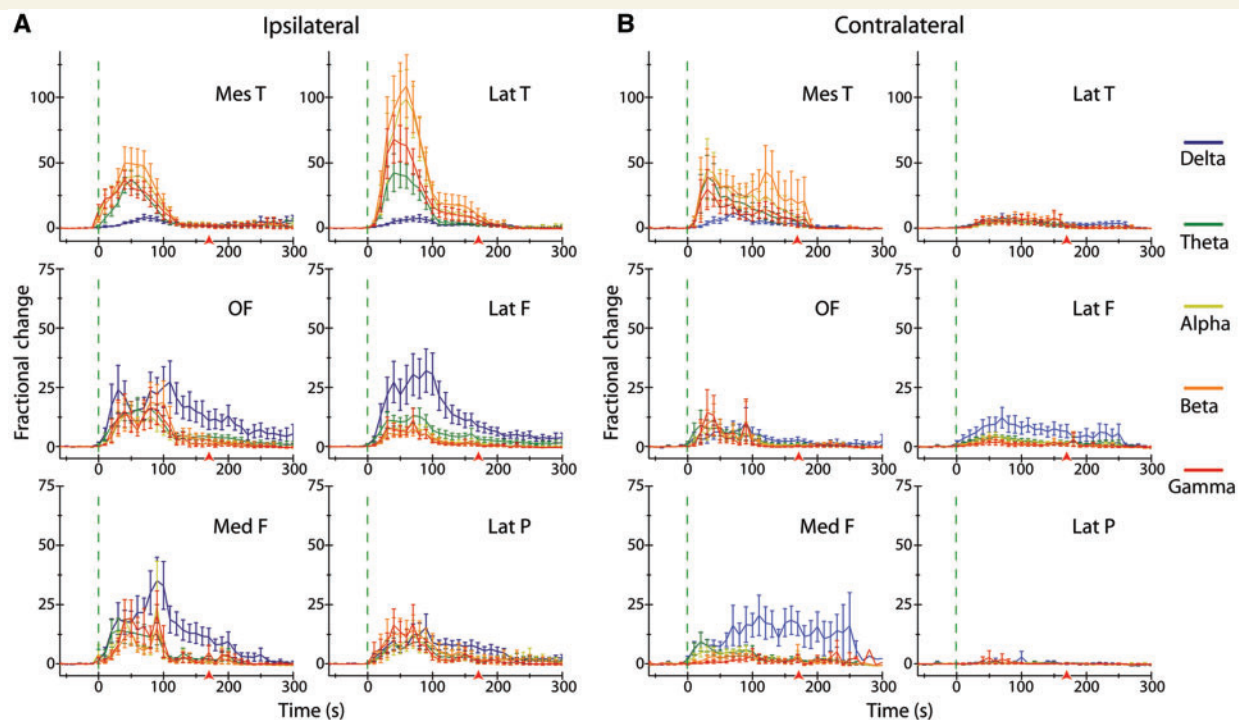
**Table 1 Summary of cortical regions showing dramatic elevations in beta or delta activity during seizures**

|                                 | Seizure type  |                                    |
|---------------------------------|---|------------------------------------|
|                                 | Complex-partial seizures  | Simple-partial seizures            |
| <b>Beta activity increases</b>  | Bilateral mesial temporal cortex<br>Ipsilateral lateral temporal cortex | Ipsilateral mesial temporal cortex |
| <b>Delta activity increases</b> | Bilateral frontal and parietal association cortices                     | –                                  |

## Group data show greater bilateral temporal fast and frontoparietal slow activity in complex-partial versus simple-partial seizures

We next used group data to track electrographic signal changes during both complex-partial seizures and simple-partial seizures, looking at several frequency bands. During complex-partial seizures, fast poly-spike activity on the side of seizure onset produced dramatic elevations in fast (theta, alpha, beta, gamma) EEG activity in the ipsilateral mesial and lateral temporal lobe, particularly within the beta frequency range (Fig. 5A, top). Relatively little change in slow (delta) activity is observed in the temporal lobe (Fig. 5A, top). Similarly, there was increased fast activity, particularly in the beta frequency range (shown in orange), with relatively little change in slow delta activity (shown in blue) in the contralateral mesial temporal lobe and to a lesser extent in the contralateral lateral temporal lobe (Fig. 5B, top).

In contrast to the changes in the temporal lobes, the most dramatic change in the frontal and parietal association cortex during

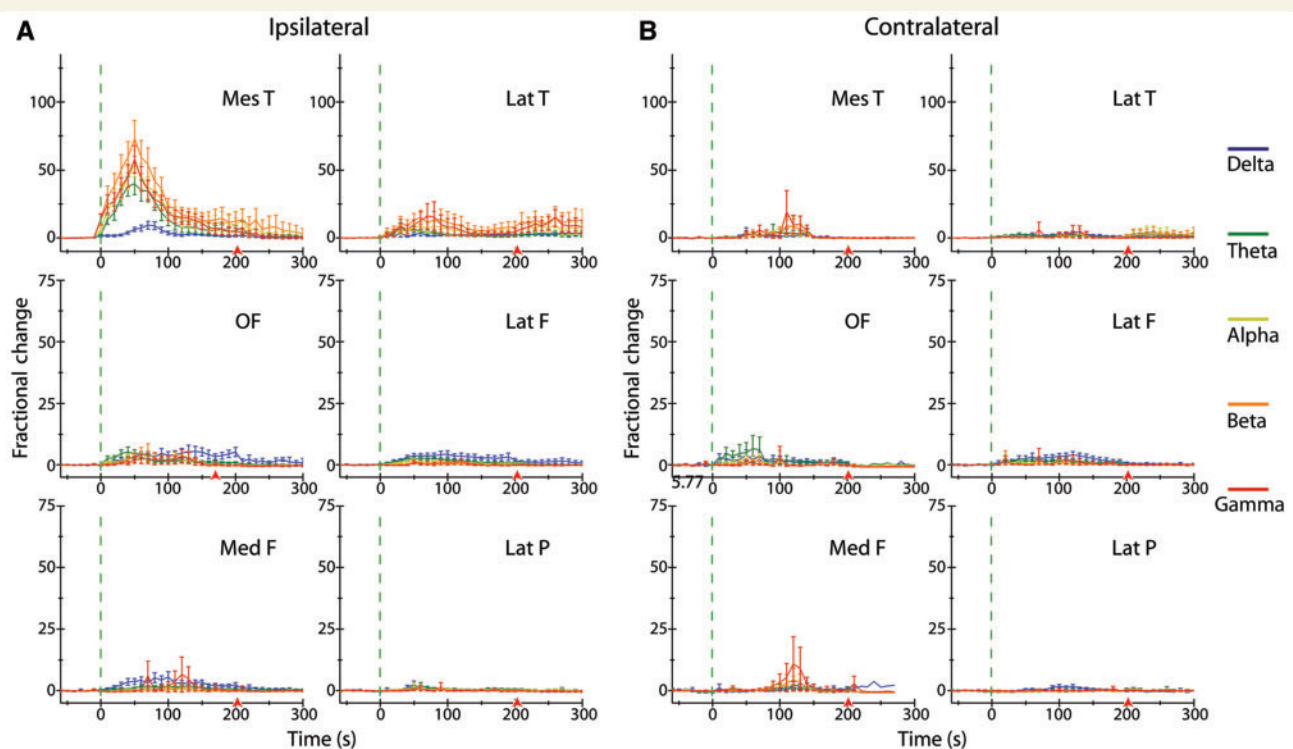


**Figure 5** Time course plots of intracranial EEG changes during complex-partial seizures. (A) Ipsilateral to onset of complex-partial seizures, dramatic increases in fast EEG frequency bands (theta, alpha, beta, gamma) are observed in the mesial and lateral temporal lobe contacts compared with baseline. EEG power in ipsilateral frontoparietal neocortical regions also increases considerably during and following seizures in all frequency bands, with largest increases in slow delta activity in the orbital, lateral and medial frontal cortices. (B) Contralateral to onset of complex-partial seizures, large increases in fast EEG frequency bands (theta, alpha, beta, gamma) are observed in the mesial temporal lobe contacts compared with baseline, with smaller increases in the contralateral lateral temporal lobe. Increases in slow delta EEG activity are recorded in the frontal cortex ictally and postictally. Relatively few changes are observed in the contralateral lateral parietal cortex. Data are mean fractional change ( $\pm$ SEM) in EEG power from 60 s pre-seizure baseline binned every 10 s. Vertical dotted lines indicate seizure onset; arrows indicate mean seizure offset time. Note: different scale between temporal (*top*) and neocortical (*middle and bottom*) data plots. See Supplementary Table 1 (*top*) for total number of seizures (*n*) analysed for each region. Mes T = mesial temporal; Lat T = lateral temporal; OF = orbital frontal; Lat F = lateral frontal; Med F = medial frontal; Lat P = lateral parietal.

complex-partial seizures was increased delta frequency power. Thus, in the ipsilateral frontoparietal cortex during complex-partial seizures, delta signal changes resulting from neocortical slow activity were most prominent (Fig. 5A, middle and bottom rows). The neocortical slow delta activity appears to peak somewhat later in seizures and persisted during the postictal period. Increased delta frequency power during complex-partial seizures persisting into the postictal period was also seen in the contralateral frontal cortices, but not in the contralateral lateral parietal cortex (Fig. 5B, middle and bottom rows).

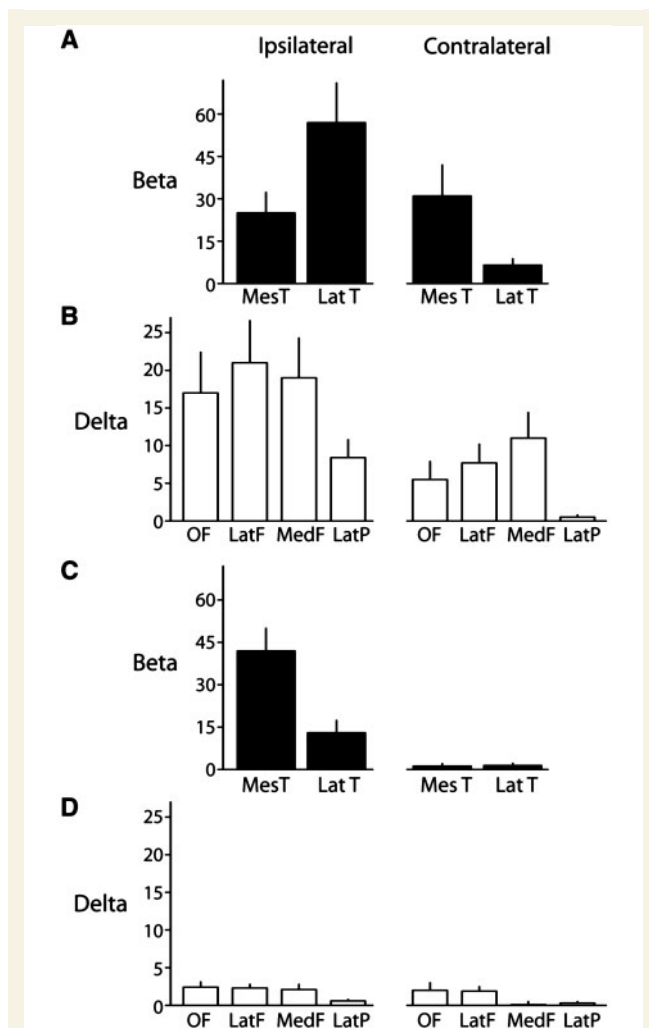
Unlike complex-partial seizures, changes during simple-partial seizures consisted mainly of fast (beta as well as gamma, alpha and theta) activity confined to the temporal lobe on the side of seizure onset (Fig. 6). During simple-partial seizures, elevated fast activity was observed in the ipsilateral mesial temporal lobe, along with smaller increases in fast activity in the ipsilateral lateral, contralateral mesial and lateral temporal lobes (Fig. 6A and B, *top*). Of note, a markedly smaller elevation of delta activity was observed in the ipsilateral and contralateral frontoparietal neocortex during simple-partial seizures (Fig. 6A and B, middle and bottom rows) compared with complex-partial seizures (Fig. 5A and B, middle and bottom rows).

We then analysed the mean amplitude of changes in temporal beta and frontoparietal delta activity, since these frequencies show the most prominent changes in temporal and frontoparietal regions, respectively. To test our central hypothesis, that complex-partial seizures produce more bilateral temporal fast and frontoparietal slow activity than simple-partial seizures, we analysed average beta and delta activity changes during seizure versus 60 s baseline (Fig. 7, Table 2). Fast beta activity in the mesial temporal lobe ipsilateral to seizure onset was not higher during complex-partial seizures and in fact was somewhat higher on average during simple-partial seizures. However, we found that the mean beta power was significantly greater in regions of presumed seizure propagation during complex-partial seizures versus simple-partial seizures, including the lateral region of the ipsilateral temporal lobe and the medial region of the contralateral temporal lobe, with a similar trend also in the contralateral lateral temporal lobe (Fig. 7A and C; Table 2). In addition, mean delta power was significantly greater in the association cortex during complex-partial seizures versus simple-partial seizures. Because we were interested in overall frontoparietal function we analysed these regions together in each hemisphere. Thus, combining the orbital, medial and lateral frontal with the lateral parietal cortex,



**Figure 6** Time course plots of intracranial EEG changes during simple-partial seizures. (A) Ipsilateral to onset of simple-partial seizures, increased fast EEG activity in the mesial temporal lobe resembles changes seen during complex-partial seizures (Fig. 5A), while smaller increases are observed in the lateral temporal lobe. Ictal changes in frontoparietal EEG signals are considerably less dramatic than those recorded during complex-partial seizures (Fig. 5). (B) Contralateral to onset of simple-partial seizures, few changes in EEG power are observed compared with complex-partial seizures (Fig. 5B). Data are mean fractional change ( $\pm$ SEM) in EEG power from 60 s pre-seizure baseline binned every 10 s. Vertical dotted lines indicate seizure onset; arrows indicate mean seizure offset time. Note: different scale between temporal (*top*) and neocortical (*middle and bottom*) data plots. See Supplementary Table 1 (*bottom*) for total number of seizures (*n*) analysed for each region. Mes T = mesial temporal; Lat T = lateral temporal; OF = orbital frontal; Lat F = lateral frontal; Med F = medial frontal; Lat P = lateral parietal.





**Figure 7** Complex-partial seizures are associated with bilateral temporal beta and frontoparietal delta increases, while simple-partial seizures show mainly increases in ipsilateral temporal beta. (A and B) Mean fractional change ( $\pm$ SEM) in temporal beta (A) and neocortical delta (B) EEG power during complex-partial seizures compared with 60 s pre-seizure baseline. (C and D) Mean fractional change ( $\pm$ SEM) in temporal beta (C) and neocortical delta (D) EEG power during simple-partial seizures compared with 60 s pre-seizure baseline. Same data and patients as Figs 5 and 6. See Supplementary Table 1 for total number of seizures ( $n$ ) analysed for each region. Mes T = mesial temporal; Lat T = lateral temporal; OF = orbital frontal; Lat F = lateral frontal; Med F = medial frontal; Lat P = lateral parietal.

there was significantly greater mean delta activity in the ipsilateral frontoparietal cortex as well as in the contralateral frontoparietal cortex during complex-partial seizures compared with simple-partial seizures (Fig. 7B and D; Table 2). Taken together, these findings demonstrate that, compared with simple-partial seizures, complex-partial seizures are associated with significantly more (i) ictal neocortical slow activity bilaterally; (ii) fast seizure activity in the lateral (but not mesial) temporal lobe on the side of seizure onset; and (iii) fast seizure activity in the temporal lobe contralateral to seizure origination.

## Temporal lobe fast activity is directly correlated with frontoparietal slow activity

Our findings thus far suggest that seizure spread out of the ipsilateral mesial temporal lobe into the lateral temporal lobe ipsilaterally, and also into the contralateral temporal lobe, is significantly greater during complex-partial seizures than simple-partial seizures. We therefore hypothesized that propagation of fast seizure activity out of the ipsilateral mesial temporal lobe may lead to altered responsiveness through its association with slow activity in the frontoparietal neocortex. To address this hypothesis, we correlated beta activity in both the mesial and lateral temporal lobes with delta activity in the frontoparietal neocortex in each hemisphere. We found that on the side of seizure onset, fast beta activity in the lateral temporal but not mesial temporal lobe was significantly correlated with slow delta activity in the frontoparietal cortex ( $r=0.42$ ,  $P < 0.001$  for lateral temporal data;  $r=0.06$ ,  $P > 0.200$  for mesial temporal data). In the contralateral hemisphere, beta activity changes in both the mesial and lateral temporal regions were significantly correlated with frontoparietal delta activity ( $r=0.87$ ,  $P < 0.001$  for lateral temporal data;  $r=0.79$ ,  $P < 0.001$  for mesial temporal data). These results indicate a strong relationship between seizure spread outside of its mesial temporal focus and frontoparietal slow rhythms and suggest that long-range network interactions may participate in impaired neocortical function, slow activity and unresponsiveness during bilateral temporal lobe seizures.

## Effects of side of seizure onset

Finally, to address the question of whether the side of seizure onset is related to behavioural unresponsiveness in temporal lobe epilepsy, we examined the laterality of seizure onset in complex-partial seizures versus simple-partial seizures (Table 3). Of the seizures originating in the left temporal lobe, 74% were complex-partial seizures and 26% were simple-partial seizures, while right-sided-onset seizures produced an equal number of each seizure type (Table 3, left). This trend suggests that seizures originating in the left temporal lobe may be more likely to cause impaired responsiveness than right-sided-onset seizures, although the results fall short of statistical significance ( $\chi^2=3.74$ ,  $P=0.053$ ). We also examined effects of seizure onset in the language-dominant versus non-dominant hemisphere, as determined by Wada testing. Only patients with typical (i.e. left-sided) language dominance were included in this analysis (Table 3, right, columns 1 and 2) and those with atypical (i.e. right-sided or bilateral) language location were excluded (Table 3, right, column 3). We observed that 88% of seizures beginning in the dominant (left) hemisphere were complex-partial seizures, while 53% of seizures beginning in the non-dominant (right) hemisphere were complex-partial seizures in left-dominant patients ( $\chi^2=6.18$ ,  $P=0.013$ ). These findings suggest that seizures beginning in the language-dominant hemisphere may be somewhat more likely to impair behavioural responsiveness than those originating on the non-dominant side.

**Table 2 Mean fractional change in temporal beta and neocortical delta electroencephalogram activity during seizures**

|                                     | Ipsilateral               |                           |                | Contralateral             |                           |                |
|-------------------------------------|---------------------------|---------------------------|----------------|---------------------------|---------------------------|----------------|
|                                     | CPS<br>mean $\pm$ SEM (n) | SPS<br>mean $\pm$ SEM (n) | CPS versus SPS | CPS<br>mean $\pm$ SEM (n) | SPS<br>mean $\pm$ SEM (n) | CPS versus SPS |
| beta activity                       |                           |                           |                |                           |                           |                |
| Mesial temporal                     | 25 $\pm$ 7.3 (38)         | 42 $\pm$ 8.0 (25)         | $P=0.029^*$    | 31 $\pm$ 11 (16)          | 1.2 $\pm$ 0.9 (16)        | $P=0.012^*$    |
| Lateral temporal                    | 57 $\pm$ 14 (38)          | 13 $\pm$ 4.4 (25)         | $P=0.003^*$    | 6.5 $\pm$ 2.3 (19)        | 1.4 $\pm$ 0.8 (18)        | $P=0.101$      |
| Delta activity                      |                           |                           |                |                           |                           |                |
| Overall frontoparietal <sup>a</sup> | 15 $\pm$ 3.4 (37)         | 2.4 $\pm$ 0.5 (25)        | $P < 0.001^*$  | 7.4 $\pm$ 1.8 (25)        | 1.9 $\pm$ 0.6 (17)        | $P=0.044^*$    |

Means represent fractional change in EEG activity during the entire seizure versus 60 s of pre-seizure baseline. *n* is the number of seizures in which measurements were performed for each region.  $^*P \leq 0.05$ , Mann–Whitney U-test. CPS = complex-partial seizure; SPS = simple-partial seizure.

<sup>a</sup> Values represent overall mean change across orbital frontal, lateral frontal, medial frontal and lateral parietal regions.

**Table 3 Seizure type versus side of onset**

| Seizure type | Side of onset <sup>a</sup> |       |       | Side of onset <sup>b</sup> |                      |                    | Total |
|--------------|----------------------------|-------|-------|----------------------------|----------------------|--------------------|-------|
|              | Left                       | Right | Total | Dominant (Left)            | Non-dominant (Right) | Other <sup>c</sup> |       |
| CPS          | 20                         | 18    | 38    | 15                         | 18                   | 5                  | 38    |
| SPS          | 7                          | 18    | 25    | 2                          | 16                   | 7                  | 25    |
| Total        | 27                         | 36    | 63    | 17                         | 34                   | 12                 | 63    |

Values represent total number of seizures in each group.

<sup>a</sup> Seizure onset in left versus right hemisphere regardless of language dominance.

<sup>b</sup> Seizure onset classified by language dominance based on Wada testing.

<sup>c</sup> Patients with atypical (right-sided, mixed or bilateral) language function. CPS = complex-partial seizure; SPS = simple-partial seizure.

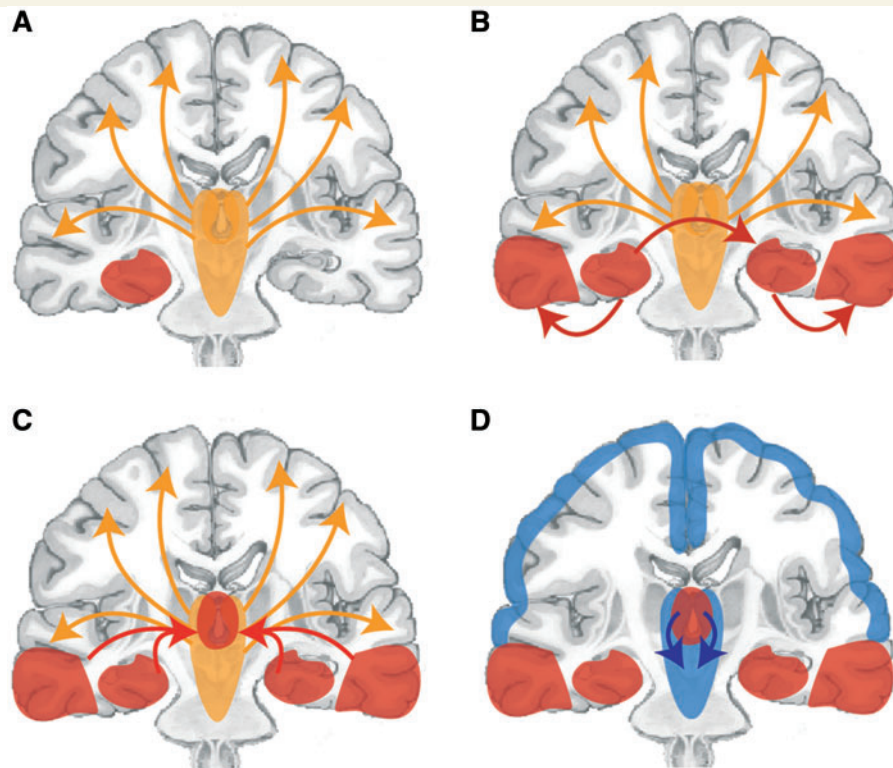
## Discussion

In the present study, we investigated intracranial EEG signals during complex-partial and simple-partial seizures in patients with temporal lobe epilepsy. For the first time we report a direct quantitative relationship between bilateral ictal neocortical slow activity and behavioural unresponsiveness during temporal lobe seizures. Slow (delta) activity elevations were significantly larger in bilateral frontoparietal neocortices during complex-partial seizures than simple-partial seizures. Large-amplitude 1–2 Hz neocortical slow waves observed during complex-partial seizures closely resembled cortical slowing during other states of unconsciousness such as sleep, coma or deep anaesthesia (Steriade *et al.*, 1993; Cowan and Wilson, 1994; Haider *et al.*, 2006) and have previously been associated with frontoparietal decreases in cerebral blood flow during seizures (Blumenfeld *et al.*, 2004b). Thus, we conjecture that in temporal lobe epilepsy, ictal neocortical slow activity leads to impaired consciousness and represents an important pathophysiological difference between complex-partial seizures and simple-partial seizures.

Several other hypotheses have previously been offered to help identify physiological distinctions between complex-partial seizures and simple-partial seizures. One common theory postulates that

consciousness may be most likely to become impaired if temporal lobe involvement in the seizure is bilateral rather than unilateral (Gloor *et al.*, 1980; Pedley, 1992; Bancaud *et al.*, 1994). We did indeed uncover evidence that the spread of fast (beta) seizure activity from its mesial temporal focus to the contralateral mesial temporal lobe—as well as to the lateral temporal lobe on the side of seizure onset—was significantly greater during complex-partial seizures than simple-partial seizures. Thus, involvement of both temporal lobes predicts ictal impairment of consciousness. This relationship may not seem immediately intuitive, as temporal lobe structures are not typically considered vital for consciousness. Therefore, we suspect that increased seizure propagation may lead to unconsciousness not because of temporal lobe pathophysiology, but from association between outward spread of fast temporal lobe discharges and ictal neocortical slow activity. Consistent with this possibility, we found that the propagation of fast seizure activity out of its mesial temporal focus to the contralateral mesial temporal lobe and to bilateral lateral temporal lobes, is significantly correlated with frontoparietal slowing. It is important to note that these associations between bilateral temporal lobe seizure activity and cortical slow rhythms, and also between neocortical slow waves and impaired consciousness, do not necessarily indicate causality or directionality. However, given that mesial temporal seizure activity precedes cortical slow activity (Fig. 1A and B) and that neocortical slow waves but not temporal seizure spikes persist postictally when consciousness often remains impaired (Fig. 1D), it is likely that seizure activity in complex-partial seizures incites significant network disturbances that then lead to frontoparietal slowing and impaired consciousness.

Why might seizure propagation out of its mesial temporal focus into the lateral temporal lobe and contralateral temporal lobe lead to depressed cortical function and impaired consciousness? The mechanisms of seizure propagation are poorly understood, but previous work has suggested that limbic seizures sometimes spread first to the lateral temporal cortex, and in other instances propagate first to the contralateral hippocampus, probably through the hippocampal commissure (Spencer *et al.*, 1987). We propose that as seizure discharges propagate out of their mesial temporal focus, they may become more likely to disrupt function in midline subcortical activating structures. As illustrated in Fig. 8, our group has previously referred to this phenomenon as the ‘network inhibition hypothesis’ (Norden and Blumenfeld, 2002;



**Figure 8** Network inhibition hypotheses for impaired consciousness during complex-partial seizures. (A) Under normal conditions, the upper brainstem–diencephalic activating systems interact with the cerebral cortex to maintain normal consciousness. A focal seizure involving the mesial temporal lobe begins unilaterally. (B) Propagation of seizure activity from the mesial temporal lobe to the ipsilateral lateral temporal lobe and the contralateral temporal lobe. (C) Spread of seizure activity from bilateral temporal lobes to midline subcortical structures. (D) Disruption of the normal activating functions of the midline subcortical structures, together with the resulting depressed activity in bilateral frontoparietal association cortex in complex-partial seizures, leads to loss of consciousness.

Blumenfeld and Taylor, 2003; Blumenfeld *et al.*, 2004a, b; Englot and Blumenfeld, 2009b). Ascending excitatory projections from subcortical structures—such as the thalamus, basal forebrain and brainstem reticular activating systems—play a critical role in normal cortical excitation during the awake, conscious state (Fig. 8A). During a simple-partial seizure, seizure activity in a unilateral mesial temporal focus (Fig. 8A) does not disrupt these arousal systems and therefore has no significant effect on neocortical function and consciousness. In complex-partial seizures, fast ictal discharges propagate into the lateral temporal lobe and the contralateral temporal lobe (Fig. 8B). Then, seizure spread to midline subcortical activating structures (Fig. 8C) leads to inhibition of normal subcortical arousal mechanisms (Fig. 8D). The neocortex enters a depressed state of function and consciousness is lost (Fig. 8D).

Although the model depicts spread of seizures to the bilateral temporal lobes, which in turn cause subcortical inhibition, at least two other possibilities warrant further investigation. It is possible that spread to the contralateral temporal lobe is an epiphenomenon, occurring along with more mechanistically important simultaneous spread to subcortical structures. Evidence against the necessity for bilateral temporal involvement may come from complex-partial seizures arising in other brain areas. Clinical

experience suggests these seizures may impair consciousness without temporal lobe involvement and additional formal investigation is needed of extratemporal complex-partial seizures. Less likely, it is also possible that bilateral temporal seizures lead directly to depressed neocortical function without involving subcortical structures.

Findings from previous studies of human temporal lobe epilepsy, which are consistent with the network inhibition hypothesis, include abnormal increased activity in the bilateral thalamus and upper brainstem (Bertashius, 1991; Blumenfeld *et al.*, 2004b; Tae *et al.*, 2005; Hogan *et al.*, 2006; Rosenberg *et al.*, 2006; Arthuis *et al.*, 2009), which are contrasted with diminished frontoparietal neocortical activity during seizures (Rabinowicz *et al.*, 1997; Menzel *et al.*, 1998; Chang *et al.*, 2002; Van Paesschen *et al.*, 2003; Blumenfeld *et al.*, 2004b). In addition, we found that cerebral blood flow increases in the medial thalamus are directly correlated with cerebral blood flow decreases in the frontoparietal cortex during temporal lobe seizures (Blumenfeld *et al.*, 2004b). Aside from its role in arousal, the thalamus is also well known to play a crucial role in corticothalamic circuits underlying diverse cognitive functions. Therefore, the recent direct demonstration by Bartolomei and colleagues of increased broadband synchrony between cortex and thalamus during temporal lobe seizures

could provide another important mechanism for impaired ictal cognition in temporal lobe epilepsy (Guye *et al.*, 2006; Arthuis *et al.*, 2009).

Recent rat studies have shown that behavioural arrest during partial limbic seizures is associated with frontal cortical slow waves, decreased neuronal firing and hypometabolism (Englot *et al.*, 2008) and that cortical deactivation and behavioural changes depend on seizure spread to subcortical structures (Englot *et al.*, 2009). Our present results, i.e. those that show complex-partial seizures with impaired consciousness are associated with both seizure propagation out of the mesial temporal lobe and increased slow rhythms in the frontoparietal association cortex, are consistent with the network inhibition hypothesis. However, directly addressing the mechanistic underpinnings of ictal unconsciousness in temporal lobe epilepsy would require further measurements of activity in subcortical structures during seizures, simultaneous to temporal and neocortical recordings.

It is interesting to note that the main seizure types causing impaired consciousness share a common anatomical substrate (Blumenfeld and Taylor, 2003; Blumenfeld, 2009). Like temporal lobe complex-partial seizures, both generalized tonic-clonic seizures (Blumenfeld *et al.*, 2009) and absence seizures (Gotman *et al.*, 2005; Labate *et al.*, 2005; Hamandi *et al.*, 2008) affect similar regions of frontoparietal cortex and thalamus when consciousness is impaired (Bai *et al.*, 2010; Berman *et al.*, 2010). Does the side of seizure onset predict ictal unconsciousness in temporal lobe epilepsy? Some have suggested that seizure origin in the left or language-dominant hemisphere may be more likely to cause loss of consciousness than right-sided or non-dominant-sided seizures (Gabr *et al.*, 1989; Inoue and Mihara, 1998; Lux *et al.*, 2002). We did observe an increased probability of behavioural unresponsiveness with seizure onset in the language-dominant hemisphere. However, we also observed impaired responsiveness in seizures with onset in the non-dominant hemisphere. Furthermore, a bias toward impaired consciousness with language-dominant hemisphere onset may have occurred since our measurement of behavioural responsiveness did not differentiate between truly 'unconscious' patients and those who might retain ictal awareness but be unresponsive due to impaired language function. We suspect that seizure origination in the language-dominant hemisphere was not the only variable underlying impaired responsiveness during complex-partial seizures, since we did observe that 18 out of 38 complex-partial seizures originated in the right hemisphere. More detailed correlations between epileptic brain rhythms and alterations in various aspects of consciousness—such as environmental responsiveness, orientation, receptive and expressive language and memory encoding—will be important to consider in forthcoming projects.

In addition to those addressed above, other limitations to this study should be mentioned. For instance, although overall frontoparietal delta activity was found to be significantly greater in both hemispheres during complex-partial seizures compared with simple-partial seizures, fewer recordings were available for some regions (Supplementary Table 1); so further study will be necessary before conclusions about ictal neocortical slow activity in specific subregions can be drawn. Next, a causal relationship between ictal neocortical slow activity and impaired consciousness could not

be inferred in our study, as such a determination would require experimental intervention in network physiology. This limitation highlights the importance of ongoing basic research using animal models of ictal neocortical slow rhythms (Englot *et al.*, 2008, 2009; Englot and Blumenfeld, 2009a) within which invasive recordings and manipulations can be employed to better understand mechanistic roots of the phenomenon.

Although the long-range mechanisms of ictal neocortical slow activity remain incompletely understood, a better understanding of network pathophysiology underlying unconsciousness in temporal lobe epilepsy may have vital clinical implications. Impaired consciousness in temporal lobe epilepsy causes motor vehicle accidents, drownings, poor work and school performance and social stigmatization resulting in a major negative impact on patient quality of life (Sperling, 2004; Jacoby *et al.*, 2005; Draskowski, 2007; Kobau *et al.*, 2008; Yang *et al.*, 2010). Also, previous investigations of patients with temporal lobe epilepsy have found neocortical deficits including grey matter atrophy (Bonilha *et al.*, 2006) and hypometabolism between seizures (Diehl *et al.*, 2003). These abnormalities may be related to neuropsychological sequelae and chronic cognitive impairments frequently suffered by these individuals (Hermann *et al.*, 1997; Helmstaedter and Kockelmann, 2006; Laurent and Arzimanoglou, 2006). A better appreciation of the long-range network effects of temporal lobe seizures could help guide novel therapeutic strategies to prevent neocortical consequences of epilepsy, such as deep brain stimulation of relevant subcortical targets (Lega *et al.*, 2009; Fisher *et al.*, 2010) and is deserving of further attention.

In conclusion, the present study provides the first direct and quantitative evidence that ictal neocortical slow activity is related to impaired consciousness in temporal lobe epilepsy, supporting our hypothesis that impaired neocortical function probably represents an important physiological distinction between complex-partial seizures and simple-partial seizures. Our findings also lend support to the more traditional supposition that bilateral temporal lobe involvement in seizures may help predict ictal unconsciousness. We postulate, however, that it is not aberrant temporal lobe function that directly interferes with consciousness during seizures, but rather the association between bilateral temporal fast spike activity and ictal neocortical slow activity—possibly through the disruption of normal subcortical arousal activity—that underlies this association. Given that cortical dysfunction produced by recurrent limbic seizures adversely affects patients' quality of life, understanding the network contributions to impaired consciousness in temporal lobe epilepsy and devising new targeted interventions to prevent these pathophysiological effects remain vitally important goals.

## Acknowledgements

The authors thank Irina Goncharova for technical help with electrode localization maps and Jennifer Bonito for maintaining the clinical database. We also thank Norma Grill, David Blumenfeld and Adam Sorscher for helpful comments on the article.

## Funding

National Institutes of Health (R01 NS055829 to H.B.); the Donaghue Foundation; Betsy and Jonathan Blattmachr family.

## Supplementary material

Supplementary material is available at *Brain* online.

## References

- Arthuis M, Valton L, Regis J, Chauvel P, Wendling F, Naccache L, et al. Impaired consciousness during temporal lobe seizures is related to increased long-distance cortical-subcortical synchronization. *Brain* 2009; 132: 2091–101.
- Bai X, Vestal M, Berman R, Negishi M, Spann M, Vega C, et al. Dynamic time course of typical childhood absence seizures: EEG, behavior, and functional magnetic resonance imaging. *J Neurosci* 2010; 30: 5884–93.
- Bancaud J, Brunet-Bourgin F, Chauvel P, Halgren E. Anatomical origin of déjà vu and vivid 'memories' in human temporal lobe epilepsy. *Brain* 1994; 117(Pt 1): 71–90.
- Berman R, Negishi M, Vestal M, Spann M, Chung MH, Bai X, et al. Simultaneous EEG, fMRI, and behavior in typical childhood absence seizures. *Epilepsia* 2010. Advance Access published on July 1, 2010, doi:10.1111/j.1528-1167.2010.02652.x.
- Bertashius KM. Propagation of human complex-partial seizures: a correlation analysis. *Electroencephalogr Clin Neurophysiol* 1991; 78: 333–40.
- Blumenfeld H. Epilepsy and consciousness. In: Laureys S, Tononi G, editors. *The Neurology of Consciousness: Cognitive Neuroscience and Neuropathology*. New York: Elsevier; 2009.
- Blumenfeld H, Taylor J. Why do seizures cause loss of consciousness? *The Neuroscientist* 2003; 9: 301–10.
- Blumenfeld H, Rivera M, McNally KA, Davis K, Spencer DD, Spencer SS. Ictal neocortical slowing in temporal lobe epilepsy. *Neurology* 2004a; 63: 1015–21.
- Blumenfeld H, McNally KA, Vanderhill SD, Paige AL, Chung R, Davis K, et al. Positive and negative network correlations in temporal lobe epilepsy. *Cerebral Cortex* 2004b; 14: 892–902.
- Blumenfeld H, Varghese GI, Purcaro MJ, Motelow JE, Enev M, McNally KA, et al. Cortical and subcortical networks in human secondarily generalized tonic-clonic seizures. *Brain* 2009; 132(Pt 4): 999–1012.
- Bonilha L, Rorden C, Appenzeller S, Coan AC, Cendes F, Li LM. Gray matter atrophy associated with duration of temporal lobe epilepsy. *Neuroimage* 2006; 32: 1070–9.
- Chang DJ, Zupal IG, Gottschalk C, Necochea A, Stokking R, Studholme C, et al. Comparison of statistical parametric mapping and SPECT difference imaging in patients with temporal lobe epilepsy. *Epilepsia* 2002; 43: 68–74.
- Cowan RL, Wilson CJ. Spontaneous firing patterns and axonal projections of single corticostriatal neurons in the rat medial agranular cortex. *J Neurophysiol* 1994; 71: 17–32.
- Dale AM, Fischl B, Sereno MI. Cortical surface-based analysis. I. Segmentation and surface reconstruction. *Neuroimage* 1999; 9: 179–94.
- Diehl B, LaPresto E, Najm I, Raja S, Rona S, Babb T, et al. Neocortical temporal FDG-PET hypometabolism correlates with temporal lobe atrophy in hippocampal sclerosis associated with microscopic cortical dysplasia. *Epilepsia* 2003; 44: 559–64.
- Drazkowski J. An overview of epilepsy and driving. *Epilepsia* 2007; 48 (Suppl. 9): 10–12.
- Engel J, Pedley TA. *Epilepsy: A Comprehensive Textbook*. Philadelphia: Lippincott Williams & Wilkins; 2007.
- Englot DJ, Blumenfeld H. Functional MRI in basic epilepsy research. In: Schwartzkroin P, editor. *Encyclopedia of Basic Epilepsy Research*. London, UK: Elsevier; 2009a.
- Englot DJ, Blumenfeld H. Consciousness and epilepsy: why are complex-partial seizures complex? *Prog Brain Res* 2009b; 177: 147–70.
- Englot DJ, Mishra AM, Mansuripur PK, Herman P, Hyder F, Blumenfeld H. Remote effects of focal hippocampal seizures on the rat neocortex. *J Neurosci* 2008; 28: 9066–81.
- Englot DJ, Modi B, Mishra AM, DeSalvo M, Hyder F, Blumenfeld H. Cortical deactivation induced by subcortical network dysfunction in limbic seizures. *J Neurosci* 2009; 29: 13006–18.
- Fischl B, Sereno MI, Dale AM. Cortical surface-based analysis. II: inflation, flattening, and a surface-based coordinate system. *Neuroimage* 1999; 9: 195–207.
- Fisher R, Salanova V, Witt T, Worth R, Henry T, Gross R, et al. Electrical stimulation of the anterior nucleus of thalamus for treatment of refractory epilepsy. *Epilepsia* 2010; 51: 899–908.
- Gabr M, Luders H, Dinner D, Morris H, Wyllie E. Speech manifestations in lateralization of temporal lobe seizures. *Ann Neurol* 1989; 25: 82–7.
- Gloor P, Olivier A, Ives J. Loss of consciousness in temporal lobe epilepsy: observations obtained with stereotaxic depth electrode recordings and stimulations. In: Canger R, Angeleri F, Penry JK, editors. *Advances in epileptology: the XIth Epilepsy International Symposium*. New York: Raven Press; 1980. p. 349–53.
- Gotman J, Grova C, Bagshaw A, Kobayashi E, Aghakhani Y, Dubeau F. Generalized epileptic discharges show thalamocortical activation and suspension of the default state of the brain. *Proc Natl Acad Sci USA* 2005; 102: 15236–40.
- Guye M, Regis J, Tamura M, Wendling F, McGonigal A, Chauvel P, et al. The role of corticothalamic coupling in human temporal lobe epilepsy. *Brain* 2006; 129: 1917–28.
- Haider B, Duque A, Hasenstaub AR, McCormick DA. Neocortical network activity in vivo is generated through a dynamic balance of excitation and inhibition. *J Neurosci* 2006; 26: 4535–45.
- Hamandi K, Laufs H, Noth U, Carmichael DW, Duncan JS, Lemieux L. BOLD and perfusion changes during epileptic generalised spike wave activity. *Neuroimage* 2008; 39: 608–18.
- Helmstaedter C, Kockelmann E. Cognitive outcomes in patients with chronic temporal lobe epilepsy. *Epilepsia* 2006; 47 (Suppl. 2): 96–8.
- Hermann BP, Seidenberg M, Schoenfeld J, Davies K. Neuropsychological characteristics of the syndrome of mesial temporal lobe epilepsy. *Arch Neurol* 1997; 54: 369–76.
- Hogan RE, Kaiboriboon K, Bertrand ME, Rao V, Acharya J. Composite SISCO perfusion patterns in right and left temporal seizures. *Arch Neurol* 2006; 63: 1419–26.
- ILAE. Proposal for revised clinical and electroencephalographic classification of epileptic seizures. From the Commission on Classification and Terminology of the International League Against Epilepsy. *Epilepsia* 1981; 22: 489–501.
- Inoue Y, Mihara T. Awareness and responsiveness during partial seizures. *Epilepsia* 1998; 39 (Suppl. 5): 7–10.
- Jacoby A, Snape D, Baker GA. Epilepsy and social identity: the stigma of a chronic neurological disorder. *Lancet Neurol* 2005; 4: 171–8.
- Kobau R, Zahran H, Thurman DJ, Zack MM, Henry TR, Schachter SC, et al. Epilepsy surveillance among adults—19 states, behavioral risk factor surveillance system, 2005. *MMWR Surveill Summ* 2008; 57: 1–20.
- Labate A, Briellmann RS, Abbott DF, Waites AB, Jackson GD. Typical childhood absence seizures are associated with thalamic activation. *Epileptic Disord* 2005; 7: 373–7.
- Laurent A, Arzimanoglou A. Cognitive impairments in children with nonidiopathic temporal lobe epilepsy. *Epilepsia* 2006; 47 (Suppl. 2): 99–102.
- Laureys S, Tononi G. *The Neurology of Consciousness: Cognitive Neuroscience and Neuropathology*. London: Academic Press; 2008.

- Lee KH, Meador KJ, Park YD, King DW, Murro AM, Pillai JJ, et al. Pathophysiology of altered consciousness during seizures: Subtraction SPECT study. *Neurology* 2002; 59: 841–46.
- Lega BC, Halpern CH, Jaggi JL, Baltuch GH. Deep brain stimulation in the treatment of refractory epilepsy: update on current data and future directions. *Neurobiol Dis* 2010; 38: 354–60.
- Lieb JP, Dasheiff RB, Engel J Jr. Role of the frontal lobes in the propagation of mesial temporal lobe seizures. *Epilepsia* 1991; 32: 822–37.
- Lux S, Kurthen M, Helmstaedter C, Hartje W, Reuber M, Elger CE. The localizing value of ictal consciousness and its constituent functions: a video-EEG study in patients with focal epilepsy. *Brain* 2002; 125 (Pt 12): 2691–8.
- Menzel C, Grunwald F, Klemm E, Ruhlmann J, Elger CE, Biersack HJ. Inhibitory effects of mesial temporal partial seizures onto frontal neocortical structures. *Acta Neurol Belg* 1998; 98: 327–31.
- Milner B. Disorders of learning and memory after temporal lobe lesions in man. *Clin Neurosurg* 1972; 19: 421–46.
- Norden AD, Blumenfeld H. The role of subcortical structures in human epilepsy. *Epilepsy Behav* 2002; 3: 219–31.
- Pedley T. Classifications of seizures and epilepsy. In: Resor S, Kutt H, editors. *The Medical Treatment of Epilepsy*. New York: Informa Health Care; 1992. p. 8.
- Penfield W, Jasper HH. *Epilepsy and the functional anatomy of the human brain*. Boston: Little Brown; 1954.
- Posner JB, Saper CB, Schiff N, Plum F. *Plum and Posner's Diagnosis of Stupor and Coma*. 4th edn., New York: Oxford University Press; 2007.
- Rabinowicz AL, Salas E, Beserra F, Leiguarda RC, Vazquez SE. Changes in regional cerebral blood flow beyond the temporal lobe in unilateral temporal lobe epilepsy. *Epilepsia* 1997; 38: 1011–4.
- Rosenberg DS, Mauguiere F, Demarquay G, Ryvlin P, Isnard J, Fischer C, et al. Involvement of medial pulvinar thalamic nucleus in human temporal lobe seizures. *Epilepsia* 2006; 47: 98–107.
- Spencer SS, Williamson PD, Spencer DD, Mattson RH. Human hippocampal seizure spread studied by depth and subdural recording: the hippocampal commissure. *Epilepsia* 1987; 28: 479–89.
- Sperling MR. The consequences of uncontrolled epilepsy. *CNS Spectr* 2004; 9: 98–101106–9.
- Steriade M, Contreras D, Curro Dossi R, Nunez A. The slow (< 1 Hz) oscillation in reticular thalamic and thalamocortical neurons: scenario of sleep rhythm generation in interacting thalamic and neocortical networks. *J Neurosci* 1993; 13: 3284–99.
- Tae WS, Joo EY, Kim JH, Han SJ, Suh YL, Kim BT, et al. Cerebral perfusion changes in mesial temporal lobe epilepsy: SPM analysis of ictal and interictal SPECT. *Neuroimage* 2005; 24: 101–10.
- Van Paesschen W, Dupont P, Van Driel G, Van Billoen H, Maes A. SPECT perfusion changes during complex partial seizures in patients with hippocampal sclerosis. *Brain* 2003; 126: 1103–11.
- Yang L, Morland TB, Schmits K, Rawson E, Narasimhan P, Motelow JE, et al. A prospective study of loss of consciousness in epilepsy using virtual reality driving simulation and other video games. *Epilepsy Behav* 2010; 18: 238–46.