

# Variation of the Infrahyoid Muscle: Duplicated Omohyoid and Appearance of the Levator Glandulae Thyroideae Muscles

Deog-Im Kim,<sup>1</sup> Ho-Jeong Kim,<sup>2</sup> Jae-Young Park,<sup>2</sup> and Kyu-Seok Lee<sup>2</sup>

<sup>1</sup>Department of Anatomy, Catholic Institution for Applied Anatomy, College of Medicine, The Catholic University of Korea, Seoul;

<sup>2</sup>Department of Anatomy, Kwandong University College of Medicine, Gangneung, Korea.

Received: November 21, 2008

Revised: March 23, 2009

Accepted: March 27, 2009

Corresponding author: Dr. Kyu-Seok Lee,  
Department of Anatomy, Kwandong University  
College of Medicine, 522 Naegok-dong,  
Gangneung 210-701, Korea.  
Tel: 82-33-649-7473, Fax: 82-33-641-1074  
E-mail: kslee@kd.ac.kr

· The authors have no financial conflicts of interest.

The embryologic origin of the omohyoid muscle is different from that of the other neck muscles. A number of variations such as the absence of muscle, variable sites of origin and insertion, and multiple bellies have been reported. However, variations in the inferior belly of the omohyoid muscle are rare. There have been no reports of the combined occurrence of the omohyoid muscle variation with the appearance of the levator glandulae thyroideae muscle. Routine dissection of a 51-year-old female cadaver revealed a duplicated omohyoid muscle and the appearance of the levator glandulae thyroideae muscle. In this case, the two inferior bellies of the omohyoid muscle were found to originate inferiorly from the superior border of the scapula. One of the inferior bellies generally continued to the superior belly with the tendinous intersection. The other inferior belly continued into the sternohyoid muscle without the tendinous intersection. In this case, the levator glandulae thyroideae muscle appeared on the left side, which attached from the upper border of the thyroid gland to the inferior border of the thyroid cartilage. These variations are significant for clinicians during endoscopic diagnosis and surgery because of the arterial and nervous damage due to iatrogenic injuries. The embryologic origins of the omohyoid and levator glandulae thyroideae muscles may be similar based on the descriptions in the relevant literature.

**Key Words:** Variation, omohyoid muscle, levator glandulae thyroideae muscle, infrahyoid muscle

## INTRODUCTION

The omohyoid muscle is an infrahyoid muscle and consists of two bellies united by an intermediate tendon. This muscle is an important landmark in the neck because it divides the anterior and posterior cervical triangles into smaller triangles.<sup>1</sup> It passes behind the sternocleidomastoid muscle and lies superficial to the internal jugular vein, the brachial plexus, phrenic nerve, and transverse cervical artery and vein.<sup>1-3</sup> Many studies reported variations in the omohyoid muscle and referred to the duplicated omohyoid muscle as a rare variation of the omohyoid muscle.<sup>1,2,4-6</sup>

The levator glandulae thyroideae muscle has been reported to occur infrequently and is described as an accessory muscle.<sup>6</sup> This muscle has been reported by some

© Copyright:

Yonsei University College of Medicine 2010

This is an Open Access article distributed under the terms of the Creative Commons Attribution Non-Commercial License (<http://creativecommons.org/licenses/by-nc/3.0>) which permits unrestricted non-commercial use, distribution, and reproduction in any medium, provided the original work is properly cited.

authors and the function and embryological origin of this muscle have been the subject of debate since the first report by Winslow in 1743.<sup>7</sup> In 1964, Mori classified this muscle into five types based on their origin and insertion.<sup>8,9</sup>

Although there is a high frequency of variation in the cervical region, the duplicated omohyoid muscle combined with the occurrence of the levator glandulae thyroideae muscle is rare.<sup>2,5</sup> This study reported rare variations in the infrahyoid muscle group and classified the variations according to previous studies.

## CASE REPORT

This variation was observed during routine dissection of a 51-year-old Korean female. We observed a duplicated omohyoid muscle on the right side and the levator glandulae thyroideae muscle on the left side (Fig. 1). The classification of the omohyoid muscle by Loth is based on forms, intermediate tendon, attachment, and innervation.<sup>6</sup> Mori classified the levator glandulae thyroideae muscle into five types according to their origin and insertion.<sup>8,9</sup>

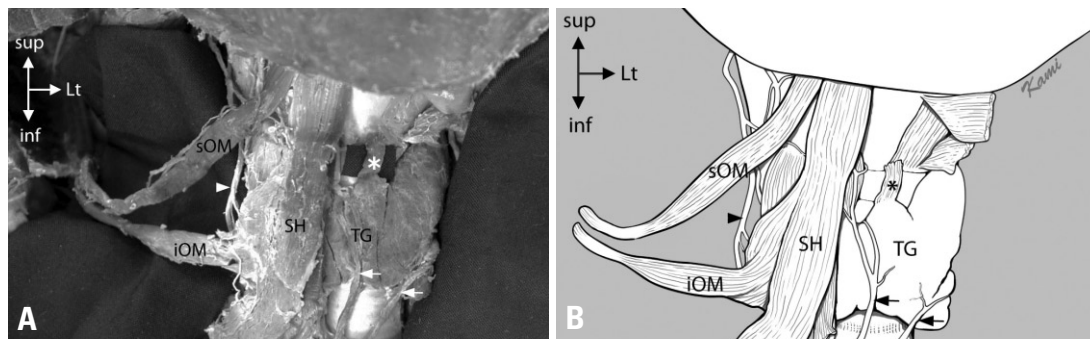
The superiorly positioned omohyoid muscle showed a typical appearance of the normal superior and inferior bellies with the intermediate tendon in between. The inferiorly positioned muscle was similar to the superiorly positioned muscle which was united with the sternohyoid muscle at the medial part of the clavicle. The classification of the superior omohyoid muscle by Loth was as follows: 1) omohyoid muscle is present and has an intermediate tendon (Type V); 2) incomplete intermediate tendon but with no constriction of the muscle belly at the site of the tendon (Type II); 3) attachment to the superior border of the scapula (Type IV); and 4) to be supplied by the ansa cervicalis. The location of the attachment of the inferior omohyoid muscle to the scapula was the same as in the case of the superior omohyoid muscle. The inferior omohyoid muscle did not have an intermediate tendon and the innervated nerve was the ansa cervicalis.

The levator glandulae thyroideae muscle originated superiorly from the inferior border of the thyroid cartilage and was inserted inferiorly on the sheath of the thyroid gland, particularly the isthmus. This finding would be best categorized as thyreoglandularis according to Mori's classification. This muscle measures one square centimeter on each side.

## DISCUSSION

Anderson has theorized that the origin of the superior belly of the omohyoid muscle differs from that of the inferior belly.<sup>1,2,10</sup> For this reason, several authors have reported variations in the omohyoid muscle.<sup>1,2,5,10</sup> The variations in the superior belly are more common than those in the inferior belly. The action of the omohyoid muscle depresses the hyoid bone after it has been elevated, and it has been suggested that this muscle tenses the lower part of the deep cervical fascia in prolonged inspiratory efforts, reducing the tendency for soft parts to be sucked inward.<sup>3</sup> Some reported that the omohyoid muscle is activated during depression of the mandible and head rotation. In addition, the fibrosis and contracture of a unilateral omohyoid muscle has been found to cause torticollis.<sup>11</sup> Others described the omohyoid muscle as involved in the dilation of the external and internal jugular veins during the opening of the mouth<sup>12</sup> and would then presumably facilitate venous return to the heart.<sup>10</sup> Recently, this muscle has been used as a landmark for a feasible study that used an endoscope for exploration of the brachial plexus,<sup>13</sup> for the treatment of a bowed vocal fold using the transposition of this muscle, and for the restoration of vocal cord abduction.<sup>14,15</sup> In this case, superior and inferior omohyoid muscles may play a role in the depression of the hyoid bone with the sternohyoid muscle.

The levator glandulae thyroideae muscle is described as an occasionally unpaired or paired muscle that extends from the hyoid bone to the isthmus of the thyroid gland, more frequently on the left side.<sup>8</sup> After the first report of



**Fig. 1.** Variations of the infrahyoid muscles. (A) Photograph of variations of the infrahyoid muscles. (B) Schematic drawing of these variations. sOM, superior omohyoid muscle; iOM, inferior omohyoid muscle; SH, sternohyoid muscle; TG, thyroid gland; asterisk, \*levator glandulae thyroideae muscle; arrow head, ansa cervicalis. arrow, inferior thyroid vein.

the levator glandulae thyroideae muscle in 1743,<sup>4</sup> Lehr indicated that the prevalence of this muscle is one in 203 cases (0.49%),<sup>9</sup> and Watanabe and Suda<sup>16</sup> reported a prevalence of this muscle in six out of seven cadavers (85.7%). Harjeet, et al.<sup>17</sup> determined the prevalence of the levator glandulae thyroideae muscle to be 19.8%. It is believed that the function of this muscle is to elevate the thyroid gland.<sup>18</sup> The embryologic origin of this muscle has been greatly debated. Some authors suggested that the levator glandulae thyroideae muscle is an embryologic derivation of the cricothyroid muscle.<sup>7</sup> Eisler reported that this muscle is derived from the cricothyroid muscle, thyrohyoid muscle, and inferior constrictor of the pharynx.<sup>19</sup> Watanabe and Suda<sup>17</sup> proposed that the presence of this muscle is entirely genetic and it seems that the levator glandulae thyroideae muscle presented here is a derivative of the infrahyoid muscles. In this case, we think that the embryologic origin of the levator glandulae thyroideae muscle may be similar to that of the omohyoid muscle.

Overall, the variations of the omohyoid muscle and the levator glandulae thyroideae muscle are derived from the infrahyoid muscle group and are clinically significant.<sup>8,11</sup> Hence, correct information about muscular variation is important for avoiding iatrogenic injuries when performing surgery or examining the neck region. The need to understand muscular variation is of greater importance than before because of the increased number of endoscopic surgeries and the development of diagnosis using images.

## ACKNOWLEDGEMENTS

We would like to thank Kwan-Hyun Youn for drawing the figure.

## REFERENCES

- Hatipoğlu ES, Kervancıoğlu P, Tuncer MC. An unusual variation of the omohyoid muscle and review of literature. *Ann Anat* 2006; 188:469-72.
- Rai R, Nayak SR, Ranade AV, Prabhu LV, Vadgaonkar R. Duplicated omohyoid muscle and its clinical significance. *Rom J Morphol Embryol* 2007;48:295-7.
- Gray H, Williams PL, Bannister LH. *Gray's anatomy: The anatomical basis of clinical practice*. 39th ed. New York: Churchill Livingstone;2006.
- Winslow JB. *Exposition anatomique de la structure du corps humain*. Amsterdam: Wetstein;1743.
- Sukekawa R, Itoh I. Anatomical study of the human omohyoid muscle: regarding intermediate morphologies between normal and anomalous morphologies of the superior belly. *Anat Sci Int* 2006;81:107-14.
- Loth E. *Anthropologie des parties Molles*. Paris: Werner Wachsmuth;1931.
- Lehr RP Jr. Musculus levator glandulae thyroideae: an observation. *Anat Anz* 1979;146:494-6.
- Loukas M, Merbs W, Tubbs RS, Curry B, Jordan R. Levator glandulae thyroideae muscle with three slips. *Anat Sci Int* 2008; 83:273-6.
- Mori M. Statistics on the musculature of the Japanese. *Okajimas Folia Anat Jpn* 1964;40:195-300.
- Tubbs RS, Salter EG, Oakes WJ. Unusual origin of the omohyoid muscle. *Clin Anat* 2004;17:578-82.
- Shih TY, Chuang JH. Fibrosis of the omohyoid muscle--an unusual cause of torticollis. *J Pediatr Surg* 1998;33:741-2.
- Patra P, Gunness TK, Robert R, Rogez JM, Heloury Y, Le Hur PA, et al. Physiologic variations of the internal jugular vein surface, role of the omohyoid muscle, a preliminary echographic study. *Surg Radiol Anat* 1988;10:107-12.
- Krishnan KG, Pinzer T, Reber F, Schackert G. Endoscopic exploration of the brachial plexus: technique and topographic anatomy--a study in fresh human cadavers. *Neurosurgery* 2004;54:401-8.
- Kojima H, Hirano S, Shoji K, Omori K, Honjo I. Omohyoid muscle transposition for the treatment of bowed vocal fold. *Ann Otol Rhinol Laryngol* 1996;105:536-40.
- Crumley RL. Muscle transfer for laryngeal paralysis. Restoration of inspiratory vocal cord abduction by phrenic-omohyoid transfer. *Arch Otolaryngol Head Neck Surg* 1991;117:1113-7.
- Watanabe S, Suda M. On the musculus levator glandulae thyroideae of the Ainu. *Saporro Igacu Zasshi* 1962;21:115-20.
- Harjeet A, Sahni D, Jit I, Aggarwal AK. Shape, measurements and weight of the thyroid gland in northwest Indians. *Surg Radiol Anat* 2004;26:91-5.
- Gregory JK, Guse DM. Unique variant of levator glandulae thyroideae muscle. *Clin Anat* 2007;20:966-7.
- Eisler P, Der M. Levator glandulae thyroideae und verwandte praelaryngeale Muskelbildungen. *Anat Anz* 1900;17:183-9.