

ASCI 2010 standardized practice protocol for cardiac magnetic resonance imaging: a report of the Asian society of cardiovascular imaging cardiac computed tomography and cardiac magnetic resonance imaging guideline working group

ASCI CCT and CMR Guideline Working Group · Carmen W. S. Chan ·
Byoung Wook Choi · Masahiro Jinzaki · Kakuya Kitagawa · I-Chen Tsai ·
Hwan Seok Yong · Wei Yu

Received: 29 August 2010 / Accepted: 15 September 2010 / Published online: 6 October 2010
© The Author(s) 2010. This article is published with open access at Springerlink.com

Abstract These practice guidelines are recommended by the Asian Society of Cardiovascular Imaging (ASCI), the sole society in Asia designated for cardiovascular imaging, to provide a framework to healthcare providers for suggested essential elements in cardiac magnetic resonance (CMR) examinations of different disease spectra. The guideline is composed of recommendations on the general technique, acquisition of some basic modules, and protocols on stress tests. The protocols for specific diseases are provided in a table format for quick reference to be easily utilized for everyday clinical CMR.

Keywords Cardiac magnetic resonance imaging · Practice guideline · Stress protocol · ASCI · Asia

Abbreviations

ACLS	Advanced cardiac life support
ASCI	Asian society of cardiovascular imaging
CMR	Cardiac magnetic resonance
ECG	Electrocardiogram
ETL	Echo train length
FSL	Fast spin echo
GRE	Gradient echo
GRE-EPI	Gradient echo-echo planar imaging
HOCM	Hypertrophic obstructive cardiomyopathy

C. W. S. Chan (✉)
Division of Cardiology, Department of Medicine,
Queen Mary Hospital, 102 Pok Fu Lam Road, Hong
Kong, China
e-mail: carmen.ws@gmail.com

B. W. Choi
Department of Radiology, Research Institute of
Radiological Science, Severance Hospital, Yonsei
University Health System, Seoul, Korea

M. Jinzaki
Department of Diagnostic Radiology,
Keio University School of Medicine,
Tokyo, Japan

K. Kitagawa
Department of Diagnostic Radiology, Mie University
School of Medicine, Tsu, Japan

I.-C. Tsai
Department of Radiology, Taichung Veterans General
Hospital, Taichung, Taiwan

H. S. Yong
Department of Radiology, Korea University Guro
Hospital, Seoul, Korea

W. Yu
Department of Radiology, Beijing Anzhen Hospital,
Capital Medical University, Beijing, China

IR	Inversion recovery
LGE	Late gadolinium enhancement
LPA	Left pulmonary artery
LV	Left ventricle
LVOT	Left ventricular outflow tract
MPA	Main pulmonary artery
MR	Magnetic resonance
PA	Pulmonary artery
PC	Phase contrast
RPA	Right pulmonary artery
RF	Radio frequency
RR	Relative risk
RV	Right ventricle
RVOT	Right ventricle outflow tract
SSFP	Steady state free precession
TE	Echo time
TR	Repetition time
TI	Inversion time

Introduction

As the healthcare system, resource allocation, and pattern of diseases [1, 2] in Asia are different from those in Western Society, this practice protocol is recommended by the Asian Society of Cardiovascular Imaging (ASCI), the sole society dedicated to cardiovascular imaging in Asia, to provide a framework for the suggested essential elements in cardiac magnetic resonance (CMR) examinations.

It must be emphasized that this guideline has been built on previously published guidelines from various professional societies [3–6], but is customized for CMR practice in Asia with its unique characteristics and where thalassemia [7–9] and valvular heart disease are common. The ultimate decision regarding the propriety of any specific procedure must be made after mutual communication with the referring physicians; the understanding of individual patient's condition; and the availability of resources, knowledge and technology provided by their respective centers by the responsible individuals participating and performing the CMR procedures.

The practice protocol starts with recommendations on the general technique and is followed by techniques on the acquisition of some basic modules. Recommended practice protocols on stress tests with separate checklists and monitoring sheets are

provided. Protocols for specific diseases are summarized in a table format for quick reference.

Guidelines

Recommended practice protocol for CMR examination

Patient preparation

1. Check for any contraindication for MR examination, stress study, and contrast administration, if needed.
2. Obtain informed consent for the MR examination.
3. Advise patient on fasting before examination. This is not mandatory, but is advised.
4. Have patient stop intake of caffeine-containing food and beverages, theophylline or dipyridamole at least 24 h before adenosine study; avoid beta-blocker and nitrates for dobutamine study.
5. Educate and provide practice to patients on the breathing instruction.
6. Provide the patient with ear plugs.
7. Prepare the skin of the chest and/or abdomen for optimal attachment of electrodes for cardiac and respiratory gating.
8. Position the patient in the best comfortable supine position. Have the patient place the arms above the head to decrease wrap artifact. It is acceptable to put the arms along the side or crossed over the chest if the patient cannot tolerate arms overhead for extended periods of time.

Equipment and safety

1. Monitoring equipment (blood pressure, electrocardiogram, intercom communication with patients)
2. Resuscitation facilities :
 - i. emergency resuscitation policy in place
 - ii. availability of resuscitation team with medical/nursing staff having ACLS accreditation
 - iii. logistics for transferring patient to designated resuscitation area outside scanner
 - iv. resuscitation trolley with full set of emergency medications and equipment

- v. external pacer and defibrillator
- vi. oxygen supply
- vii. beta-blockers, nitrates, and aminophylline at hand

3. Stress MRI testing.

Detail on safety and equipment needed is listed in the performance protocol for the adenosine and dobutamine studies

Recommended practice protocol on basic modules

See Fig. 1 for a quick reference on the acquisition of major imaging planes described below.

Left ventricular (LV) structure and function module

All scans are recommended to be performed as breathhold, multiphase steady state free precession

(SSFP) imaging at the end of the expiratory phase using all elements on the cardiac coil. All 17 segments of the heart can be covered by a combination of three short axis and two long axis views (four chambers and two chambers). Scout imaging—multistack three plane localizers: transtransaxial, coronal, sagittal

1. Calibrate for parallel imaging technique, if it is to be used.
2. Shimming
3. Transaxial (8–10 mm) set of SSFP or fast spin echo (FSE) images through the chest.
4. Vertical long axis scout cine images
 - i. The vertical long axis scout cine plane is prescribed from the axial localizer at the level of mitral and tricuspid valves.
 - ii. The slice through the LV apex and centre of the mitral valve is prescribed.

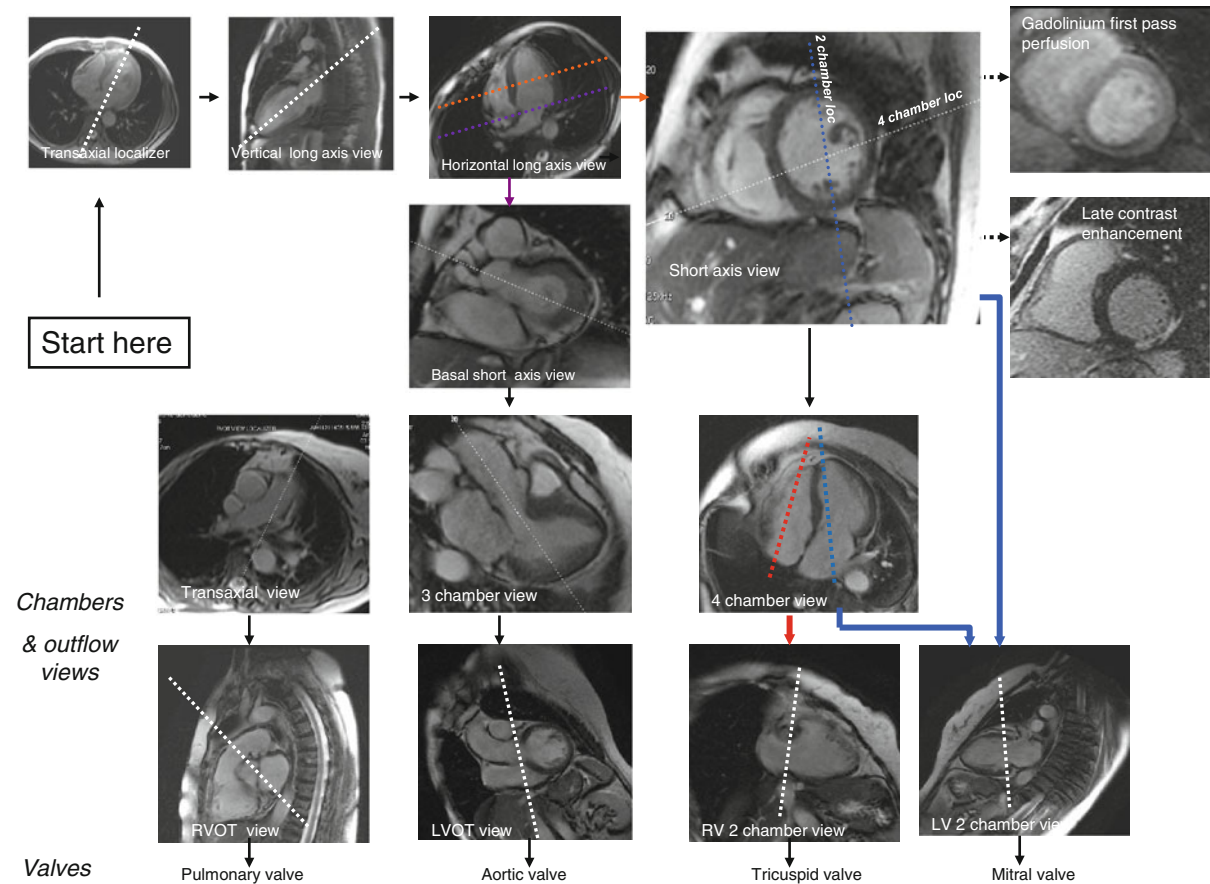


Fig. 1 A road map for major imaging planes of the cardiac magnetic resonance study

5. Horizontal long axis scout cine images.
The horizontal long axis scout cine plane is prescribed from the end systolic phase of the vertical long axis scout cine image.
 - i. Position the slice at the center of the mitral valve and angulate through the LV apex.
 - ii. Scroll through the diastolic images to ensure the left atrium is included and properly imaged.
6. Short axis cine images.
The short axis cine planes are prescribed from previously acquired long axis scout cines at diastole, starting from the mitral valve plane through the LV apex, covering the whole ventricle perpendicular to the interventricular septum on horizontal long axis scout cine images.
 - i. Slice thickness 6–8 mm; no gap
 - ii. Temporal resolution ≤ 45 ms between phases
 - iii. Parallel imaging to shorten scanning time
7. Other long axis cine images
 - i. The four chamber cine plane is prescribed from the vertical long axis scout cine and short axis cine images. The cut plane should pass through the LV apex and centre of mitral valve on the vertical long axis scout cine image. On the short axis cine image, angulate the cut plane so that it passes through the center of the LV chamber and lower corner of the RV border sure to avoid bisecting the LV outflow tract in the basal short axis view.
 - ii. The two chamber cine image is prescribed by a cut plane that bisects the LV apex and centre of the mitral valve in the four chamber view, as well as passing through the mid LV chamber in the short axis view. The cut plane needs to be in parallel to the ventricular septum in both views.
 - iii. The three chamber cine image is prescribed by a cut plane parallel to the long axis with the bisecting mitral valve and apex as well as the bisecting LV outflow tract in basal short axis view.
 - iv. The LV outflow tract (LVOT) long axis is obtained in the oblique coronal plane from the true axial scout images by positioning the

slice through the aortic root and directing it toward the LV apex.

8. Additional views of cine images.
A contiguous stack of transaxial steady state free precession cine images from the top of the aortic arch to the inferior wall of the LV is recommended for congenital heart disease.

Right ventricular (RV) structure and function module

RV short axis views are acquired in a similar fashion to the LV structure and function module. Use a transaxial stack of cines covering the RV for best identification of the tricuspid valve plane.

1. Right ventricular two chamber long axis view
 - i. Obtain the right ventricular two chamber long axis images from four chamber images
 - ii. Position the centre of the slice in the middle of the tricuspid valve and angulate through the RV apex. Scroll through phases to ensure the slice passes through the end-systolic and end-diastolic RV apex of the four chamber images.
2. Right ventricular outflow view (RVOT).
Prescribe by placing the slice through the centre of main pulmonary artery and the RV apex through a set of axial images.
3. Right ventricular inflow and outflow view.
An inflow/outflow plane of the RV can be acquired using a three-point plane.
 - i. Place the first point on the tricuspid valve of the four chamber view.
 - ii. Place the second point on the RV apex of the two chamber RV view.
 - iii. Place the third point on the pulmonary valve of the RVOT view.

Gadolinium first pass perfusion module

1. Use scout imaging as per the LV structure and function module.
2. Use saturation-recovery imaging with gradient echo-echo planar imaging (GRE-EPI) hybrid, GRE, or SSFP readout.

3. Use at least three short axis slices per each heart beat (basal, mid, and apical level of LV). Add one slice in four chamber (for septal/lateral segment ischemia) or two chamber view (for anterior/inferior segment) if the length of the RR interval permits.
4. Acquire the apical short axis slice first and the most basal short axis last during the cardiac cycle to minimize cardiac motion artifacts.
5. Use a slice thickness of 8–10 mm, in-plane resolution, $\sim <3$ mm; twofold acceleration and temporal resolution <100 ms or shorter.
6. Do a dry run at the end expiration for 5–10 phases to check and correct any position and phase wrap artifacts.
7. Use the following parameters:
 - i. Give contrast (0.05–0.1 mmol/kg, 3–7 ml/s) followed by at least 30 ml saline flush (5–7 ml/s)
 - ii. Start breathhold during early phases of contrast infusion before contrast reaches the LV cavity.
 - iii. Readout for 50–60 heart beats to capture the contrast wash-in and wash-out through LV myocardium.

Late gadolinium enhancement (LGE) module

1. Wait for 10 min after administration of cumulative dose of 0.1–0.2 mmol/kg gadolinium. A shorter delay time may be considered if lower doses of contrast are used.
2. Use 2D segmented inversion recovery GRE imaging during the end of the diastolic phase.
3. Prescribe the slices at the identical location, views, and thicknesses as for cine imaging (short- and long-axis views).
4. In-plane resolution, ~ 1.4 – 1.8 mm; adjust acquisition duration to a shorter RR interval in tachycardia.
5. Set inversion time to null normal myocardium.
6. Adjust the read-out according to heart rate. Every other heart beat in normal setting of heart rate; every heart beat in the setting of bradycardia, and every third heart beat in the setting of tachycardia or arrhythmia.

T2-weighted imaging

1. Consider using either body coil or functional surface coil intensity correction algorithms.
2. Use breathhold, pre-contrast segmented FSE imaging (double inversion recovery).
3. Select slice locations based on the suspected area of acute edema or inflammation on cine images.
4. Use a thick (10–12 mm) slice.
5. Obtain short axis, mid ventricular slices by multiple breathholds, spoiled gradient echo sequences with nine echo time (5.6–18 ms) for T2* measurement for iron detection. Adjust the TR between the 9 RF (segment) pulses according to the different TE times.

Valvular flow and shunt assessment module

1. Quantitative flow measurement
 - i. For the flow velocity and volume, the plane of measurement should be perpendicular to the vessel and distal to valve leaflet tips of interest. Adapt velocity encoding to actual velocity by the lowest velocity without aliasing, and use the lowest TE possible for high velocity jet flows.
 - ii. Specific plane for phase contrast (PC) flow acquisition.
For the acquisition of different chamber views stated below, please refer to the basic modules on structure and function of LV and RV in Sections A & B.
 - (a) Mitral Valve: Plan on the end-systolic two chamber and four chamber cine images. The center of the slice is placed in the middle of the mitral valve and angulated parallel to the mitral valve.
 - (b) Tricuspid Valve: Plan on true four-chamber and RV two-chamber images at the end systolic phase. The center of the slice is placed in the middle of the tricuspid valve and angulated parallel to the tricuspid valve.
 - (c) Aortic Valve: Alignment of the imaging plan for the aortic valve is from the

three chamber and LVOT views. The imaging plane should be positioned just above the aortic valve, yet just below the origin of the coronary arteries. The LVOT view is prescribed perpendicular to the three chamber view.

- (d) **Pulmonary Valve:** Align the imaging plane from two orthogonal RVOT views and place the plane just above the pulmonary valve. The first RVOT view is prescribed from an oblique plane through the main PA and RV on a set of axial images. The second RVOT plane is prescribed perpendicular to the first RVOT.
- (e) **Pulmonary Arteries: *Main pulmonary artery (MPA)***
Prescribe from sagittal localizer and obtain a few cine slices parallel to the MPA. The imaging plane for flow acquisition should be perpendicular to the direction of flow to the MPA on these images. The usual peak velocity is 180 cm/s. The encoding velocity recommended for the first measurement or for flow measurement is 180 cm/s.
Left pulmonary artery (LPA) and right pulmonary artery (RPA) Imaging planes through the LPA and RPA should be perpendicular to the direction of flow and proximal to the first branching vessel. In general, these planes are usually 1–1.5 cm distal to the MPA bifurcation. The usual velocity for peak measurement is 60–120 cm/s. The recommended encoding velocity for the first measurement or for flow measurement is 200 cm/s.
- (f) **Ascending Aorta:** Prescribe the imaging plane from the coronal localizer. The flow acquisition is performed perpendicular to the flow direction of the ascending aorta, about 1.5–2 cm above the aortic valve at the pulmonary bifurcation level. The usual peak velocity measurement is 100–160 cm/s. The recommended encoding velocity for the first measurement or for flow measurement is 200 cm/s.

2. Qualitative assessment

- i. Use gradient echo or hybrid gradient echo/echo planar imaging as either is better in visualizing the severity of regurgitant jets or turbulence across shunts.
- ii. For the morphology and planimetry of valve orifice, optimize the angle and level with SSFP in the plane of the valve of interest and use three contiguous 5 mm-thick high resolution cines transecting the line of the jet and moving from orifice level to immediately downstream.
- iii. Specific plane for assessment:
 - (a) Mitral valve: horizontal and vertical long axis, LVOT view
 - (b) Aortic valve: LVOT and coronal view
 - (c) Tricuspid valve: horizontal long axis and transaxial view
 - (d) Pulmonary valve: RV long axis or RVOT view

Recommended protocol for adenosine stress test

1. Follow the checklist attached and set up according to the monitoring sheet for adenosine stress myocardial perfusion test.
2. Perform LV structure and function module as listed or alternatively acquire these images at between stress and rest perfusion to shorten scanning time.
3. Start continuous adenosine infusion (at least 3 min, preferably 4–6 min continuous infusion of 140 µg/kg body weight/min) and then
 - i. Perform the gadolinium first pass perfusion module; update the heart rate in response to the heart rate increase caused by adenosine.
 - ii. Gadolinium is injected (0.05–0.1 mmol/kg) during the last minute of adenosine infusion.
 - iii. Stop adenosine infusion after imaging for 50–60 heart beats when the gadolinium has passed through LV myocardium.
 - iv. Continuous ECG monitoring, oxygen saturation monitoring and repeated BP measured at baseline, during infusion, and for at least 2 min post-infusion of adenosine (see the monitoring sheet).

Table 1 A quick reference on the recommended study protocol in specific diseases (optional items are highlighted in blue)

Study protocol for specific diseases	Ischaemic heart disease		Arrhythmogenic right ventricular cardiomyopathy (ARVD)	Non-ischaemic cardiomyopathy (including myocarditis)	Valvular heart disease	Pericardial disease	Cardiac masses	Congenital heart disease
	Acute myocardial infarction	Chronic ischaemic heart disease						
LV function and structure module	✓	✓	✓	✓	✓	✓	✓	✓
RV function and structure module			✓	✓	✓			✓
Late gadolinium module	✓	✓	✓ T1 null for RV	✓	✓	✓	✓	✓
Adenosine perfusion module		✓		✓ If a mixed of ischaemic & nonischaemic etiology is suspected				
Dobutamine perfusion module		1. Low dose infusion (10 µg/kg/min × 5–10 min) for contractile reserve 2. High dose for inducible perfusion defects, wall motion and viability assessment		✓ If a mixed of ischaemic and nonischaemic etiology is suspected				
T2 weighting module	✓			✓ 1. T2 W Triple IR if acute edema/necrosis is suspected 2. T2* for myocardial iron in Thalassaemia		✓	✓ With and without fat suppression across the mass & surrounding structure	

Table 1 continued

Study protocol for specific diseases	Ischaemic heart disease Acute myocardial infarction	Chronic ischemic heart disease	Arrhythmogenic right ventricular cardiomyopathy (ARVD)	Non-ischemic cardiomyopathy (including myocarditis)	Valvular heart disease	Pericardial disease	Cardiac masses	Congenital heart disease
T1 weighted Fast spin echo			With and without fat suppression	T1 W spin echo (ETL = 2) before and immediately after infusion of 0.1 mmol/kg of gadolinium if myocardial hyperemia and capillary leak is suspected [10]		✓	✓	
Phase velocity				At outflow tract if evidence of HOCM; or at any site of flow turbulence	According to the valvular lesion of interest			1. Through main PA and ascending aorta for Qp/Qs in shunt lesions; visualize turbulence flow across shunt lesion by in plane/through plane velocity encoded gradient echo sequence 2. Through respective valvular lesion for regurgitation volume and gradient across the target valve 3. Through plane at the level of aortic coarctation to measure peak velocity 4. Flow volume at right and left PA if unilateral branch of PA stenosis is suspected
Others	Repeat perfusion study and/or early post contrast T1 W GRE with long TI (400 ms -600 ms) within first 3 min of contrast administration to detect microvascular obstruction [11]		1. Transaxial cine images including RVOT/RV & an vertical long axis RV with tricuspid inflow 2. Consider use only the anterior surface coil to improve resolution	1. Triple IR (turbo spin echo with inversion suppression for blood and fat or T2 W as an alternative as stated above) for detection of edema	Also refer to valvular and shunt assessment module	1. Real time imaging of the ventricles during dynamic breathing maneuvers for interdependence 2. T1 W tagging at the level of thickened pericardium (2–3 short and long axis images)	1. First pass perfusion through the mass	Also refer to valvular and shunt assessment module

4. Rest Perfusion
 - i. Perform only after at least 10 min washout period for the gadolinium from stress perfusion imaging.
 - ii. Repeat perfusion imaging without adenosine using same dose of gadolinium and at the same slice location, again update the heart rate.
 - iii. Consider skipping if the stress perfusion is free from artifact. However, additional gadolinium may be considered for late gadolinium enhancement imaging (for a cumulative total dose of 0.1–0.2 mmol/kg).
5. Perform the LGE module after waiting for about 10 min after the last dose of contrast.

Recommended protocol for dobutamine stress test

Low dose dobutamine infusion at 10 µg/kg for 5–10 min is an alternative to look for contractile reserve only.

1. Follow the attached checklist and set up according to the monitoring sheet for dobutamine stress myocardial perfusion test.
2. Follow baseline LV structure and function module.
3. Dobutamine continuous infusion:
 - i. Increase the dobutamine infusion in increments of 10 µg/kg body weight/minute every 3 min starting at 10 µg/kg body weight/min until target heart rate [$85\% \times (220 - \text{age})$] is reached.
 - ii. Add atropine 0.3 mg in fractional doses up to 2 mg, if heart rate response is poor.
 - iii. Repeat 3 short axis (basal, mid ventricular, and distal views) and 3 long axis cine views during each increment of dobutamine dosing.
 - iv. Continuously monitor ECG and oxygen, and measure BP at baseline, during each stage and at least 10 min after stress test (see the monitoring sheet).
 - v. View cine loops online as they are being acquired at each stage during real-time or almost at real-time.
 - vi. Optimize the temporal resolution at every dosage as the heart rate increases.
- vii. Stop test at detection of any new wall motion or thickening abnormality; systolic blood pressure increase >240 mmHg and/or diastolic blood pressure >120 mmHg; Blood pressure decrease >20 mmHg below baseline systolic blood pressure and/or decrease >40 mmHg from a previous level; severe chest pain or other intractable symptoms; complex cardiac arrhythmias or achievement of peak heart rate.
4. Perform first pass perfusion at peak stress with gadolinium at 0.05–0.075 mmol/kg as described in the perfusion module, wait for 20 min before acquisition of rest perfusion.
5. Perform the LGE module after waiting for at least 10 min after the last dose of gadolinium injection (at a cumulative dose of 0.1–0.2 mmol/kg).

Conclusion

The elements of the above practice guidelines recommended by ASCI are based on the currently available acquisition technology and knowledge on specific diseases. ASCI will continue to observe the field and provide the most up-to-date information to assist in the delivery of the best patient care (Table 1).

Acknowledgments The working group would like to acknowledge Mr Lawrence Yip, the senior radiographer, Queen Mary Hospital, Hong Kong for the acquisition of images and Dr Stephen CW Cheung, the consultant radiologist, Queen Mary Hospital, Hong Kong for the contribution on the worksheets for stress studies.

Declaration The members of the working group have nothing to declare on the potential conflict of interest.

Open Access This article is distributed under the terms of the Creative Commons Attribution Noncommercial License which permits any noncommercial use, distribution, and reproduction in any medium, provided the original author(s) and source are credited.

Appendix

See Tables 2, 3, 4, 5, 6, and 7.

Table 2 Checklist for adenosine stress myocardial test

Pre-procedure	Checked
<p>I. Check for contraindication for adenosine stress test</p> <ol style="list-style-type: none"> 1. Known hypersensitivity to adenosine 2. Known or suspected bronchoconstrictive or bronchospastic disease 3. Heart block more than first degree 4. Significant sinus bradycardia (resting heart rate <45 bpm) 5. Systemic arterial hypotension (<90 mmHg) or severe arterial hypertension 6. Recent myocardial infarction within 3 days <p>II. Obtain informed consent</p> <p>III. Perform pre-procedure 12 leads ECG and review by doctor in charge</p> <p>IV. Place two angiocatheters intravenously to each arm:</p> <ol style="list-style-type: none"> 1. One IV 20G in antecubital fossa for contrast 2. One IV 20–22G for adenosine infusion <p>V. Set up infusion pump for adenosine:</p> <p>Drugs dosage: adenosine 0.14mg/kg/min</p> <p>Patient's body weight (BW) = _____ kg; Adenosine concentration _____mg/ml</p> <p>$0.140 \text{ (mg/kg/min)} \times \text{BW (kg)} / \text{Adenosine concentration (mg/ml)} =$</p> <p>Infusion rate _____ (ml/min) = _____ (ml/h)</p> <p>Total dose of adenosine to be administrated:</p> <p>$0.14 \text{ (mg/kg/min)} \times \text{BW (kg)} \times \text{Infusion time (min)} =$ _____ mg</p>	
<p>During-procedure</p> <ol style="list-style-type: none"> 1. Oxygen 2 l/min per nasal cannula 2. Set BP cuff to manual mode. Place BP cuff opposite arm as med administration. 3. Record baseline vital signs- prior to medication administration 4. Aminophylline 125 mg in 50 ml normal saline IVB over 5–6 min prn chest pain and shortness of breath 5. Start adenosine infusion at am/pm (time). Continue vital sign monitoring as shown 	
<p>Post procedure</p> <ol style="list-style-type: none"> 1. Perform post stress ECG and review 2. Record final vital signs prior to discharge. Report any patient complaints to doctor in charge 	

Table 3 Patient monitoring during adenosine stress cardiac MR examination

Time after start of adenosine infusion	Blood pressure (mmHg)	Heart rate/min	SaO2 reading(%)	Symptoms
Baseline				
30 secs				
2 mins				
3.5 mins				
6 mins (intermediate after scan)				
8 mins				
10 mins				
Before discharge				
Please indicate the reason(s) for premature termination:				
<input type="checkbox"/> Persistent or symptomatic AV block <input type="checkbox"/> Significant drop in systolic blood pressure <input type="checkbox"/> Persistent or symptomatic hypotension <input type="checkbox"/> Severe respiratory difficulty <input type="checkbox"/> Others _____				

Ref: potential side effects during adenosine infusion

1. Flushing, chest pain, palpitations and breathlessness
2. Transient heart block
3. Transient sinus tachycardia
4. Bronchospasm

Table 4 Checklist for dobutamine stress myocardial test

Pre-procedure	Checked
I. Check for contraindication for dobutamine stress test	
1. Severe systemic arterial hypertension ($\geq 220/120$ mmHg)	
2. Unstable angina	
3. High grade aortic stenosis (aortic valve area < 1 cm ² /peak aortic valve gradient > 50 mmHg)	
4. Uncontrolled or complex cardiac arrhythmias	
5. Haemodynamically significant hypertrophic obstructive cardiomyopathy	
6. Uncontrolled heart failure	
7. Myocarditis, endocarditis and pericarditis	
8. History of sudden death	
9. Aortic dissection/high grade aortic aneurysm	
10. Mobile left ventricular or left atrial thrombus	
II. Check list for contraindications for atropine	
1. Advance heart block	
2. Glaucoma	
3. Pyloric stenosis	
4. Obstructive uropathy	
5. Myasthenia gravis	
II. Obtain informed consent	
III. Perform pre-procedure 12 leads ECG and review by doctor in charge	
IV. Place two angiocatheters intravenously to each arm:	
1. One IV 20G in antecubital fossa for contrast	
2. One IV 20–22G for adenosine infusion	
V. Set up infusion pump for dobutamine infusion:	
VI. Additional medication to be ready for use in examination room	
1. TNG table	
2. Metropolol 5 mg/ml	
3. Atropine 0.6 ml \times 3 ampules	
4. NS flush	
During-procedure	
1. Oxygen 2 l per nasal cannula	
2. Set BP cuff to manual mode. Place BP cuff opposite arm as med administration.	
3. Record baseline vital signs- prior to medication administration	
4. Record time at the start of dobutmaine infusion. Continue vital sign monitoring whenever change of dosage and prn	
Post procedure	
1. Perform post stress ECG and review	
2. Record total amount of drugs given	
3. Record final vital signs prior to discharge. Report any patient complaints to doctor in charge	

Table 5 Patient monitoring during dobutamine stress cardiac MR examination

Target heart rate _____ bpm (220-age x 85%)		Start Time: _____ End Time: _____				
Time	Drug/dose/rate	BP (mmHg)	HR (bpm)	SaO2 (%)	Pain scale (0-10)	Assessment/intervention
	Baseline					
	Dobutamine 50 mg in 50 ml NS @ 10 mcg/kg/min = _____ ml/h					
	Dobutamine 50 mg in 50 ml NS @ 20mcg/kg/min = _____ ml/h					
	Dobutamine 50 mg in 50 ml NS @ 30mcg/kg/min = _____ ml/h					
	Dobutamine 50 mg in 50 ml NS @ 40mcg/kg/min = _____ ml/h					
	Dobutamine 50 mg in 50 ml NS @ _____mcg/kg/min = _____ ml/h					
	Total volume of Dobutamine administrated = _____ ml					
	Atropine 0.3 mg IV 1 st dose					
	Atropine 0.3 mg IV 2 rd dose					
	Atropine 0.3 mg IV 3 rd dose					
	Atropine 0.3 mg IV 4 th dose					
	Atropine 0.3 mg IV 5 th dose					
	Atropine 0.3 mg IV 6 th dose					
	Total dose of atropine administrated=____ mg					
	5 minutes after stress test					
	10 mintues after stress test					
	Pre-discharge					
Other medications at recovery phase: _____						

Was target HR achieved: Y/N

Reasons for termination:

- Target heart rate
- Severe chest pain
- Arrhythmias
- BP decrease >20 mmHg systolic below baseline systolic BP or decrease > 40 mmHg form a previous level
- Max dose of stress
- More than two sites wall motion abnormality
- BP >220/120 mmHg
- Patient cannot tolerate due to other reasons

Table 6 Adenosine infusion protocol (0.14 mg/kg/min over 6 min) adenosine concentration: 3 mg/ml

Wt (kg)	Wt (lbs)	Adenosine (mg/min)	Adenosine (ml/h)	Adenosine total dose	Wt (kg)	Wt (lbs)	Adenosine (mg/min)	Adenosine (ml/h)	Adenosine total dose
40	88	5.6	112	34	75	165	10.5	210	63
41	90	5.7	114	34	76	167	10.6	213	64
42	92	5.9	118	35	77	169	10.8	216	65
43	95	6.0	120	36	78	172	10.9	218	66
44	97	6.1	122	37	79	174	11.1	221	66
45	99	6.3	126	38	80	176	11.2	224	67
46	101	6.4	129	39	81	178	11.3	227	68
47	103	6.6	132	39	82	180	11.5	230	69
48	106	6.7	134	40	83	183	11.6	232	70
49	108	6.9	137	41	84	185	11.8	235	71
50	110	7.0	140	42	85	187	11.9	238	71
51	112	7.1	143	43	86	189	12.0	241	72
52	114	7.3	146	44	87	191	12.2	244	73
53	117	7.4	148	45	88	194	12.3	246	74
54	119	7.6	151	45	89	196	12.5	249	75
55	121	7.7	154	46	90	198	12.6	252	76
56	123	7.8	157	47	91	200	12.7	255	76
57	125	8.0	160	48	92	202	12.9	258	77
58	128	8.1	162	49	93	205	13.0	260	78
59	130	8.3	165	50	94	207	13.2	263	79
60	132	8.4	168	50	95	209	13.3	266	80
61	134	8.5	171	51	96	211	13.4	269	81
62	136	8.7	174	52	97	213	13.6	272	81
63	139	8.8	176	53	98	216	13.7	274	82
64	141	9.0	179	54	99	218	13.9	277	83
65	143	9.1	182	55	100	220	14.0	280	84
66	145	9.2	185	55	101	222	14.1	283	85
67	147	9.4	188	56	102	224	14.3	286	86
68	150	9.5	190	57	103	227	14.4	288	87
69	152	9.7	193	58	104	229	14.6	291	87
70	154	9.8	196	59	105	231	14.7	294	88
71	156	19.9	199	60	106	233	14.8	297	89
72	158	10.1	202	60	107	235	15.0	300	90
73	161	10.2	204	61	108	238	15.1	302	91
74	163	10.4	207	62	109	240	15.3	305	92

Table 7 Adenosine infusion protocol (0.14 mg/kg/min over 6 min) adenosine concentration: 2 mg/ml

Wt (kg)	Wt (lbs)	Adenosine (mg/min)	Adenosine (ml/h)	Adenosine total dose	Wt (kg)	Wt (lbs)	Adenosine (mg/min)	Adenosine (ml/h)	Adenosine total dose
40	88	5.6	168	34	75	165	10.5	315	63
41	90	5.7	171	34	76	167	10.6	318	64
42	92	5.9	177	35	77	169	10.8	324	65
43	95	6.0	180	36	78	172	10.9	327	66
44	97	6.1	183	37	79	174	11.1	333	66
45	99	6.3	189	38	80	176	11.2	336	67
46	101	6.4	192	39	81	178	11.3	339	68
47	103	6.6	198	39	82	180	11.5	345	69
48	106	6.7	201	40	83	183	11.6	348	70
49	108	6.9	207	41	84	185	11.8	354	71
50	110	7.0	210	42	85	187	11.9	357	71
51	112	7.1	213	43	86	189	12.0	360	72
52	114	7.3	219	44	87	191	12.2	366	73
53	117	7.4	222	45	88	194	12.3	369	74
54	119	7.6	228	45	89	196	12.5	375	75
55	121	7.7	231	46	90	198	12.6	378	76
56	123	7.8	234	47	91	200	12.7	381	76
57	125	8.0	240	48	92	202	12.9	387	77
58	128	8.1	243	49	93	205	13.0	390	78
59	130	8.3	249	50	94	207	13.2	396	79
60	132	8.4	252	50	95	209	13.3	399	80
61	134	8.5	255	51	96	211	13.4	402	81
62	136	8.7	261	52	97	213	13.6	408	81
63	139	8.8	264	53	98	216	13.7	411	82
64	141	9.0	270	54	99	218	13.9	417	83
65	143	9.1	273	55	100	220	14.0	420	84
66	145	9.2	276	55	101	222	14.1	423	85
67	147	9.4	282	56	102	224	14.3	429	86
68	150	9.5	285	57	103	227	14.4	432	87
69	152	9.7	291	58	104	229	14.6	438	87
70	154	9.8	294	59	105	231	14.7	441	88
71	156	19.9	597	60	106	233	14.8	444	89
72	158	10.1	303	60	107	235	15.0	450	90
73	161	10.2	306	61	108	238	15.1	453	91
74	163	10.4	312	62	109	240	15.3	459	92

References

1. American Heart Association (2009) International cardiovascular disease statistics. Available at <http://www.americanheart.org/downloadable/heart/1236204012112INTL.pdf>. Accessed on 6 June 2010
2. Modell B, Darlison M (2008) Global epidemiology of haemoglobin disorders and derived service indicators. *Bull World Health Organ* 86(6):480–487
3. Hendel RC, Budoff MJ, Cardella JF et al (2009) ACC/AHA/ACR/ASE/ASNC/HRS/NASCI/RSNA/SAIP/SCAI/SCCT/SCMR/SIR 2008 Key data elements and definitions for cardiac imaging: A report of the American college of cardiology/American heart association task force on clinical data standards (writing committee to develop clinical data standards for cardiac imaging). *Circulation* 119(1): 154–186
4. Hendel RC, Patel MR, Kramer CM et al (2006) ACCF/ACR/SCCT/SCMR/ASNC/NASCI/SCAI/SIR 2006 appropriateness criteria for cardiac computed tomography and cardiac magnetic resonance imaging: a report of the American college of cardiology foundation quality strategic directions committee appropriateness criteria working group, American college of radiology, society of cardiovascular computed tomography, Society for cardiovascular magnetic resonance, American society of nuclear cardiology, North American society for cardiac imaging, society for cardiovascular angiography and interventions, and society of interventional radiology. *J Am Coll Cardiol* 48(7):1475–1497
5. Kramer CM, Barkhausen J, Flamm SD et al (2008) Standardized cardiovascular magnetic resonance imaging (CMR) protocols, society for cardiovascular magnetic resonance: board of trustees task force on standardized protocols. *J Cardiovasc Magn Reson* 10:35
6. Cerqueira MD, Weissman NJ, Dilsizian V et al (2002) Standardized myocardial segmentation and nomenclature for tomographic imaging of the heart: a statement for healthcare professional from the cardiac imaging committee of the council on clinical cardiology of the American Heart Association. *Circulation* 105(4):539–542
7. Todd D, Lai MC, Braga CA et al (1969) Alpha-thalassaemia in Chinese: cord blood studies. *Br J Haematol* 16(6):551–556
8. Li AM, Lee FT, Todd D (1982) The screening of Chinese cord blood for haemoglobinopathies. *Hum Hered* 32(1): 62–70
9. Ghosh A, Woo JS, Wan CW et al (1985) Evaluation of a prenatal screening procedure for beta-thalassaemia carriers in a Chinese population based on the mean corpuscular volume (MCV). *Prenat Diagn* 5(1):59–65
10. Friedrich MG, Sechtem U, Schulz-Menger J et al (2009) Cardiovascular magnetic resonance in myocarditis: a JACC white paper. *J Am Coll Cardiol* 53(17):1475–1487
11. Mather AN, Lockie T, Nagel E et al (2009) Appearance of microvascular obstruction on high resolution first-pass perfusion, early and late gadolinium enhancement CMR in patients with acute myocardial infarction. *J Cardiovasc Magn Reson* 11:33