



Published in final edited form as:

Arch Surg. 1988 August ; 123(8): 1021–1022.

Right Trisegmentectomy With a Synthetic Vena Cava Graft

Shunzaburo Iwatsuki, MD, Satoru Todo, MD, and Thomas E. Starzl, MD, PhD

Department of Surgery, University Health Center of Pittsburgh, University of Pittsburgh, and the Veterans Administration Medical Center, Pittsburgh

Abstract

In the course of a right trisegmentectomy of the liver, nearly the entire length of the retrohepatic vena cava was replaced with a Dacron graft. Patency of the graft was proved by a venacavogram a year later.

Replacement of the vena cava during hepatic resection must be a rare occurrence. We have reported only one such case, using a vena caval allograft.¹ The performance of grafting in this location has been notoriously poor, and it is widely believed that a prosthesis or vena caval graft cannot be expected to remain open. We report herein an unusual experience in the course of right trisegmentectomy whereby almost all of the retrohepatic vena cava was replaced with a Dacron graft, leaving only the entrance of the left hepatic vein.

Report of a Case

A 54-year-old woman underwent exploratory surgery in another city by a competent hepatic surgeon who closed the incision when finding that a leiomyosarcoma had extensively invaded the retrohepatic vena cava (Fig 1). Three weeks later the subcostal portion of the previous thoracoabdominal incision was reopened and combined with an upper midline extension. Right hepatic trisegmentectomy was carried out including total excision of the caudate lobe. The vena cava from just above the entrance of the renal veins to just below the diaphragm was included with the specimen, leaving only the left hepatic vein for outflow from the retained lateral segment. A 22-mm woven Dacron graft was placed in the defect by end-to-end anastomoses (Fig 1).

The patient recovered promptly from the operation. Three weeks and 12 months later, inferior venacavograms were obtained that showed the graft to be widely patent (Fig 2). Although the tumor was extensive and of a relatively unfavorable cell type, there has been no evidence of recurrence for 12 months.

Comment

Our experience with this case has shown the feasibility of vena cava replacement with a prosthesis. The initial plan with our patient was to interpose a segment of vena cava allograft obtained from one of the cadaveric liver donors as we have reported previously.¹ However, the diameters of the vena cava grafts available were too small and the prosthetic option was exercised.

Although, to our knowledge, there is no reported experience of this kind in the literature, we learned by oral communication in February 1987 from Professor Ozawa, MD, from Kyoto

University, Japan, of a similar experience using a Gore-Tex graft.² In the Japanese case, as in ours, the graft has remained patent for a long time afterward.

Acknowledgments

This study was supported by research grants from the Veterans Administration, Washington, DC, and Project Grant No. AM 29961 from the National Institutes of Health, Bethesda, Md.

References

1. Starzl TE, Koep LJ, Weil R III, et al. Right trisegmentectomy for hepatic neoplasms. *Surg Gynecol Obstet* 1980;150:208–214. [PubMed: 7352313]
2. Kumada K, Yamaoka Y, Fukui K, et al. Extended right hepatic lobectomy: Combined resection of inferior vena cava and its reconstruction by EPTFE graft (Gore-Tex®). *Surgery*. in press.

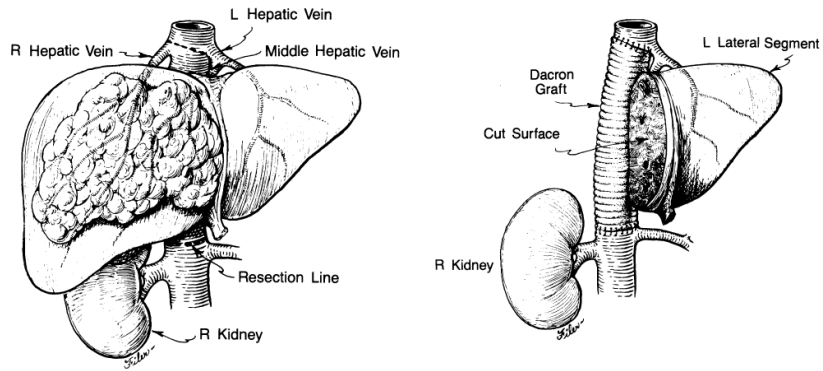


Fig 1. Diagrammatic illustration of hepatic lesion (left) and appearance at completion of operation (right).

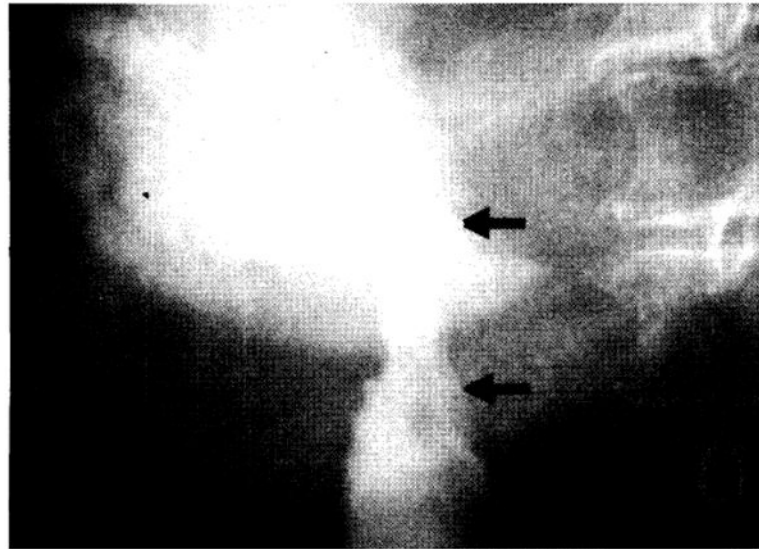


Fig 2. Venacavogram obtained one year after operation, showing graft (arrows) to be patent.