

doi: 10.3325/cmj.2010.51.509

# Survey of Croatian Dentists' Restorative Treatment Decisions on Approximal Caries Lesions

Anja Baraba<sup>1</sup>, Ivica Anić<sup>1</sup>,  
Sophie Doméjean-Orliaguet<sup>2</sup>, Ivar Espelid<sup>3</sup>,  
Anne B. Tveit<sup>4</sup>, Ivana Miletić<sup>1</sup>

<sup>1</sup>Department of Endodontics and Restorative Dentistry, School of Dental Medicine, University of Zagreb, Croatia

<sup>2</sup>Department of Restorative Dentistry and Endodontics, University of Auvergne, Clermont-Ferrand, France

<sup>3</sup>Department of Pedodontics, Faculty of Dentistry, University of Oslo, Oslo, Norway

<sup>4</sup>Department of Cariology, Faculty of Dentistry, University of Oslo, Oslo, Norway

**Aim** To assess Croatian dentists' restorative treatment decisions on approximal caries lesions, including treatment threshold and restorative methods and materials.

**Methods** Croatian translation of the questionnaire assessing restorative treatment decisions on approximal caries, previously validated and used in Norway and Sweden, was distributed to a random sample (n=800) of Croatian dentists. A total of 307 (38%) dentists answered the questionnaire. The assessed variables were treatment threshold for hypothetical approximal caries lesion and the most favored types of restorative techniques and materials.

**Results** A third of the respondents (39%, 95% confidence interval [CI], 34-44%) would intervene for an approximal caries lesion at the dentin-enamel junction, but a larger proportion (42%; 95% CI, 36-48%) would treat a caries lesion confined to the enamel. For restoration of approximal caries, the majority (66%; 95% CI, 61-71%) would use composite resin.

**Conclusion** Croatian dentists tend to restore approximal caries lesions when the lesions are confined to the enamel and their development can still be arrested.

Received: July 13, 2010

Accepted: October 18, 2010

**Correspondence to:**

Anja Baraba  
Department of Endodontics and Restorative Dentistry  
School of Dental Medicine, University of Zagreb  
Gundulićeva 5  
10 000 Zagreb, Croatia  
[baraba@sfzg.hr](mailto:baraba@sfzg.hr)

Caries diagnosis remains a major challenge in dentistry. Since clinical pattern of caries in industrialized countries is changing and a growing proportion of caries shows slow progression and late cavitation (1), there is an increased risk of hidden approximal caries, ie, the caries that can progress beneath sound enamel surface. In this type of caries, visual examination alone is often insufficient (2) and the use of bitewing radiographs is required (3,4,5). Besides clinical and radiographic findings, the dentist's decision on restorative threshold and restorative techniques and materials is influenced by patient's characteristics such as age (6), dental hygiene, dietary habits, and fluoride uptake.

Better understanding of demineralization and remineralization of caries lesions and availability of products for mineralization of caries lesions confined to the enamel have resulted in new minimally invasive approaches in restorative dentistry. These approaches can preserve healthy hard dental tissues and therefore should be used in preference to operative treatments indicated when the caries lesion has reached the dentin-enamel junction or cavitation stage (7). However, it is unclear to what extent these approaches have been adopted in Croatia.

In addition to variations in materials and techniques, dentists in different countries differ in how well they detect approximal caries lesions (8) and how they plan treatment (9-19). Since dentists' preferences for restorative treatment are often difficult to be directly inferred from patient files, anonymous questionnaire is used. For example, studies from Norway and Sweden (9,15) that used an anonymous questionnaire showed a relationship between dentists' preferences for restorative treatment and their age and type of practice.

To assess variations among Croatian dentists in the treatment threshold and restorative methods and materials, a pilot study using the survey from Sweden (15) was conducted among Croatian dentists in Split-Dalmatia county (20). The study found that dentists tended to restore caries lesions when the approximal lesion had reached the dentin-enamel junction or had just penetrated the dentin, and that they preferred to use tunnel preparation and composite resin material (20). The present study was designed as an extension of the pilot study and included more dentists, from all parts of Croatia.

## METHODS

### Dentist recruitment

The questionnaire (9,15) was translated from English to Croatian and then back translated by the same bi-

lingual dentist. It was distributed to the dentists selected using a random number table – 400 from the list of dental practitioners of the Croatian Dental Society and 400 from a list of dentists attending congresses. These dentists were employed in the national dental care service, Public Dental Health Services (PDHS), private practices, and private practices under contract with the Croatian Institute for Health Insurance (CIHI). The group included 28 dentists from Split-Dalmatia county who had participated in the pilot study (20). Responses were collected from 307 (38%) dentists.

### Questionnaire

The anonymous questionnaire assessed dentists' treatment threshold for hypothetical approximal caries and the most favored types of restorative techniques and materials. All questions referred to a hypothetical 20-year-old patient who visited the dentist annually, had good oral hygiene, and low caries activity.

The survey asked the following multiple-choice questions (9,15):

Question 1: Which lesion(s) do you think require(s) immediate restorative treatment (Figure 1)? That is, the lesion(s) for which you would not postpone restorative treatment under any circumstances. Answer: 1) outer half of enamel; 2) inner half of enamel; 3) enamel-dentin junction; 4) outer 1/3 of dentin; 5) outer half of dentin; 6) inner half of dentin.

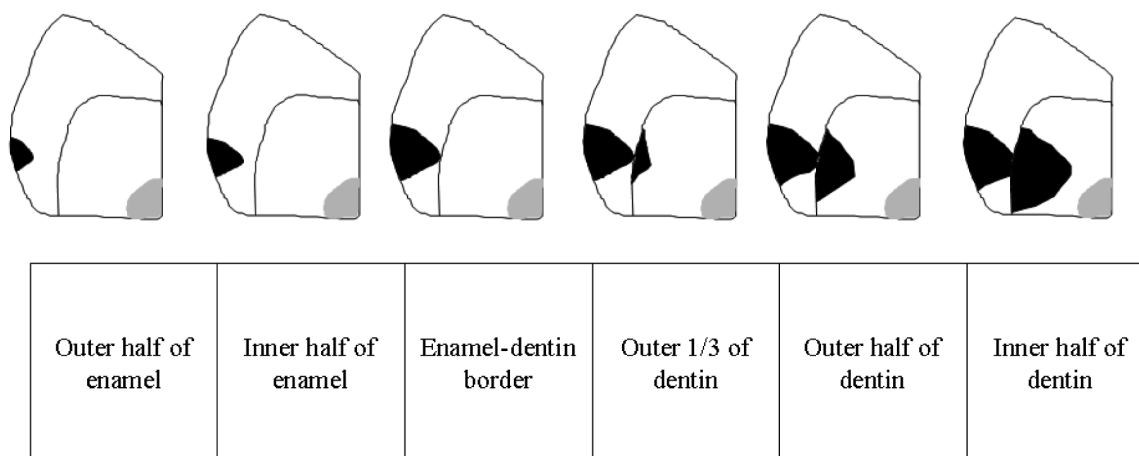
Question 2: Which type of preparation would you prefer for the smallest of the lesions you decided to drill and fill? Answer: 1) traditional class II preparation; 2) tunnel preparation; 3) saucer-shaped preparation.

Question 3: What restorative material would you choose for the smallest approximal lesion that you would restore? Answer: 1) amalgam; 2) composite resin; 3) conventional glass ionomer cement (GIC); 4) resin-modified GIC; 5) composite resin in combination with GIC.

### Statistical analysis

Chi-square test was used to compare results for treatment threshold, preferred preparation technique, and preferred restorative materials for different subgroups of dentists defined by age, sex, and type of practice. Statistical analysis was performed using Statistica 7.0 (StatSoft, Tulsa, OK, USA), with a *P* value lower than 0.05 considered significant.

Figure 1.



Six different radiographic stages of approximal caries lesion. In the question 1 of the questionnaire on management of approximal caries lesions, respondents had to indicate which stage was the smallest approximal caries lesion they would restore operatively.

## RESULTS

Respondents had an age range from 25 to 65 years (median, 42). Distribution by age, sex, and type of practice is shown in Table 1 and decisions about restorative threshold, restorative technique, and restorative material for approximal caries lesion according to age, sex, and type of practice in Table 2. Nearly half of the respondents (42%; 95% confidence interval [CI], 36-48%) would prepare a cavity for an approximal lesion confined to the enamel, while 39% (95% CI, 34-44%) would operatively restore the lesion at the dentin-enamel junction (Table 2). Respondents 45 years old and younger would postpone the restorative treatment until a more advanced stage of lesion progression than would older respondents ( $P < 0.001$ ).

**TABLE 1.** Distribution of Croatian dentists (n=307) who filled out the questionnaire on management of approximal caries lesions by age, sex, and type of practice

Variable	No. (%)
<b>Age (years):</b>	
≤45	202 (66)
>45	105 (34)
<b>Sex:</b>	
male	92 (30)
female	215 (70)
<b>Type of practice:</b>	
Public Dental Health Service	148 (48)
private practice under contract with the Croatian Institute for Health Insurance	80 (26)
private practice	79 (26)

The preferred cavity design was tunnel preparation technique, which was chosen by 46% of respondents (95% CI, 40-52%). Respondents 45 years old and younger preferred tunnel preparation, while older respondents preferred the traditional class II preparation ( $P = 0.017$ ).

The preferred restorative material for 66% of respondents was composite resin (95% CI, 61-71%). More respondents older than 45 years than those younger than 45 years would choose amalgam, GIC, or GIC in combination with composite resin ( $P = 0.012$ ). A larger proportion of younger respondents would use composite resin (Table 2).

## DISCUSSION

Our study demonstrated that Croatian dentists usually opted for the restoration of the approximal caries lesions at an early stage, when the lesion is confined to the enamel and its development can still be arrested. Although the response rate was rather low, the study population was representative of the different types of dental practices in the country, including PDHS, private practices, and private practitioners under the contract with the CIHI. Also, the treatment criteria that dentists report in questionnaire studies do not entirely reflect their clinical decisions, but still offer insight into their treatment philosophies (14,21). Dentists' decisions are also affected by age, dental status, and regular visits to the dentist (22). To limit the response variance, the questionnaire was based on a theoretical patient.

**TABLE 2.** Proportions of Croatian dentists choosing each of the possible responses in the questionnaire on management of approximal caries lesions

Responses to the question	Percentage (95% confidence interval) of dentists								
	of entire sample	≤45 y	>45 y	male	female	Public Dental Health Service	private practice in contract with Croatian Institute for Health Insurance	private practice	
<b>Smallest approximal caries lesion you would restore operatively?</b>									
outer half of enamel	10 (7-13)	3 (1-5)	19 (15-23)	9 (6-12)	10 (7-13)	1 (0-2)	0	1 (0-2)	
inner half of enamel	32 (27-37)	30 (25-35)	37 (32-42)	32 (27-3)	33 (28-38)	27 (22-32)	28 (23-33)	23 (18-28)	
enamel-dentin junction	39 (34-45)	45 (39-51)	32 (27-37)	35 (40-40)	42 (37-48)	66 (61-51)	71 (66-76)	72 (67-77)	
outer 1/3 of dentin	18 (14-22)	21 (16-26)	12 (8-16)	23 (18-28)	15 (11-19)	5 (3-7)	1 (0-2)	4 (2-6)	
outer half of dentin	1 (0-2)	1 (0-2)	0	1 (0-2)	0	1 (0-2)	0	0	
inner half of dentin	0	0	0	0	0	0	0	0	
<b>Preferred type of cavity preparation?</b>									
class II preparation	32 (27-37)	26 (21-31)	40 (35-46)	31 (26-36)	32 (27-37)	41 (46-47)	19 (15-23)	26 (21-30)	
tunnel preparation	46 (40-52)	53 (47-59)	36 (31-41)	47 (41-53)	46 (40-52)	37 (32-42)	62 (57-67)	48 (42-54)	
saucer-shaped preparation	22 (17-27)	21 (16-26)	24 (17-29)	22 (17-27)	22 (17-27)	22 (17-27)	19 (15-23)	26 (21-31)	
<b>The restorative material for approximal caries lesion?</b>									
amalgam	4 (2-6)	2 (0-4)	8 (5-11)	3 (1-5)	5 (3-7)	5 (3-7)	5 (3-7)	1 (0-2)	
composite resin	66 (61-51)	72 (67-77)	57 (51-63)	70 (65-75)	65 (60-70)	64 (59-69)	65 (60-70)	72 (67-77)	
conventional glass ionomer cement	4 (2-6)	4 (2-6)	4 (2-6)	4 (2-6)	4 (2-6)	3 (1-5)	3 (1-5)	8 (5-11)	
resin modified glass ionomer cement	9 (6-12)	7 (4-10)	11 (8-15)	10 (7-13)	8 (5-11)	7 (4-10)	14 (10-18)	6 (3-9)	
composite resin + glass ionomer cement	17 (13-21)	15 (12-19)	20 (16-24)	13 (9-17)	18 (14-22)	21 (16-26)	13 (9-17)	13 (9-17)	

Although our results illustrate a wide disparity in the management of carious lesions among Croatian practitioners, it seems that most of them would intervene at early stages of carious progression. Similar situation was found among French private practitioners and both public and private Iranian and Brazilian dentists (18,23-25), as well as in more than half of dentists in Western Australia and Norway (9,12).

As opposed to this, the majority of dentists in Scandinavia postponed the operative treatment until caries had reached the dentin, with younger dentists performing the operative procedure later (13,14). Younger dentists were inclined to postpone the operative treatment in our study as well. Sequential studies demonstrated that dentists in Norway shifted from early to late restorative treatment (9,14) most likely because of a decrease in the incidence and prevalence of caries. Croatian dentists may not have shifted to later treatment because they did not take this into account (26). Although, dentists in our earlier pilot study were more inclined to postpone restorative treatment of approximal caries than dentists in the pres-

ent study (20), Croatian dentists are still more inclined to operative dentistry, even though it runs contrary to current recommendations of a more preventive approach (7).

For the restoration of approximal lesions, more Croatian dentists preferred tunnel preparation, more conservative than the conventional class II preparation. This is similar to dentists from Split-Dalmatia county in our pilot study (20), as well as to Norwegian and Swedish dentists (14,15). Only a small proportion of our dentists chose carious lesions in the outer half of dentin as an indication for operative treatment, so tunnel preparation may be a good choice for smaller lesions (27), especially given the characteristics of the theoretical patient. While dentists younger than 45 years in our sample would choose tunnel preparation, older dentists would use the traditional class II technique, which can be explained by the influence of old cariology teaching programs based mainly on Black's approach (28). The number of dentists who preferred traditional class II preparation was higher than the number of those who preferred a saucer-shaped preparation, similar to the pi-

lot study results (20). This is despite the fact that saucer-shaped preparation spares sound dentin and is preferable to the class II preparation (29). In Norway, the number of dentists who chose saucer-shaped preparation techniques was similar to the number of those who chose traditional class II preparation (14), while dentists in France preferred saucer-shaped preparation to tunnel and class II preparation (18).

For approximal cavity restoration, the most frequently chosen material was composite resin. Rather low proportions of Croatian dentists chose GIC or amalgam. Similar results were obtained in our pilot study (20); in fact, no dentist reported using amalgam. Modern dentistry emphasizes the importance of esthetics in restorative treatment, and this influences both the patient's and dentist's decisions in treatment planning and selection of restorative material.

Comparisons between the present study and previous ones should be made with caution, since some of these were carried out over a decade ago (9-17). For example, a study from 1999 reported that in Norway a considerable percentage of dentists chose amalgam as a restorative material for caries lesion (14), but the use of amalgam in that country has been banned since 2008, essentially for environmental reasons (30).

In conclusion, the finding that Croatian dentists tend to restore approximal caries lesions at an early stage when the lesion is still confined to the enamel and can be remineralized demonstrates the need for more consistent teaching of cariology and restorative dentistry in dental schools, with an emphasis on minimally invasive treatment of caries lesions. Our study could be a first step in assessing and monitoring dental restorative treatment in Croatia, as well as in the development of guidelines for dentists' education and the promotion of modern approaches to caries management.

### Acknowledgments

This study was financed by the Ministry of Science, Education, and Sports of the Republic of Croatia as part of the research project Experimental and Clinical Endodontology (No. 065-0650444-0418).

### References

- Russell M, Pitts NB. Radiovisiographic diagnosis of dental caries: initial comparison of basic mode videoprints with bitewing radiography. *Caries Res.* 1993;27:65-70. [Medline:8448777](#) [doi:10.1159/000261518](#)
- Pitts NB. The use of bitewing radiographs in the management of dental caries: scientific and practical considerations. *Dentomaxillofac Radiol.* 1996;25:5-16. [Medline:9084279](#)
- Bloemendal E, de Vet HC, Bouter LM. The value of bitewing radiographs in epidemiological caries research: a systematic review of the literature. *J Dent.* 2004;32:255-64. [Medline:15053907](#) [doi:10.1016/j.jdent.2003.12.001](#)
- Hopcraft MS, Morgan MV. Comparison of radiographic and clinical diagnosis of approximal and occlusal dental caries in a young adult population. *Community Dent Oral Epidemiol.* 2005;33:212-8. [Medline:15853844](#) [doi:10.1111/j.1600-0528.2005.00216.x](#)
- Galcerà Civera V, Almerich Silla JM, Montiel Co JM, Forner Navarro L. Clinical and radiographic diagnosis of approximal and occlusal dental caries in a low risk population. *Med Oral Patol Oral Cir Bucal.* 2007;12:E252-7. [Medline:17468725](#)
- Akpata ES, Farid MR, al-Saif K, Roberts EA. Cavitation at radiolucent areas on proximal surfaces of posterior teeth. *Caries Res.* 1996;30:313-6. [Medline:8877083](#) [doi:10.1159/000262336](#)
- Mount GJ, Ngo H. Minimal intervention: a new concept for operative dentistry. *Quintessence Int.* 2000;31:527-33. [Medline:11203973](#)
- Hintze H, Wenzel A, Danielsen B, Nyvad B. Reliability of visual examination, fibre-optic transillumination, and bite-wing radiography, and reproducibility of direct visual examination following tooth separation for the identification of cavitated carious lesions in contacting approximal surfaces. *Caries Res.* 1998;32:204-9. [Medline:9577986](#) [doi:10.1159/000016454](#)
- Espelid I, Tveit A, Haugejorden O, Riordan PJ. Variation in radiographic interpretation and restorative treatment decisions on approximal caries among dentists in Norway. *Community Dent Oral Epidemiol.* 1985;13:26-9. [Medline:3855730](#) [doi:10.1111/j.1600-0528.1985.tb00414.x](#)
- Mileman PA, Espelid I. Decisions on restorative treatment and recall intervals based on bitewing radiographs. A comparison between national surveys of Dutch and Norwegian practitioners. *Community Dent Health.* 1988;5:273-84. [Medline:3196957](#)
- Nuttall NM, Pitts NB. Restorative treatment thresholds reported to be used by dentists in Scotland. *Br Dent J.* 1990;169:119-26. [Medline:2206665](#)
- Riordan PJ, Espelid I, Tveit AB. Radiographic interpretation and treatment decisions among dental therapists and dentists in Western Australia. *Community Dent Oral Epidemiol.* 1991;19:268-71. [Medline:1742991](#) [doi:10.1111/j.1600-0528.1991.tb00165.x](#)
- Mejare I, Sundberg H, Espelid I, Tveit B. Caries assessment and restorative treatment thresholds reported by Swedish dentists. *Acta Odontol Scand.* 1999;57:149-54. [Medline:10480281](#) [doi:10.1080/000163599428887](#)
- Tveit AB, Espelid I, Skodje F. Restorative treatment decisions

- on approximal caries in Norway. *Int Dent J.* 1999;49:165-72. [Medline:10858750](#)
- 15 Sundberg H, Mejre I, Espelid I, Tveit AB. Swedish dentists' decisions on preparation techniques and restorative materials. *Acta Odontol Scand.* 2000;58:135-41. [Medline:10933563](#) [doi:10.1080/000163500429271](#)
- 16 Espelid I, Tveit AB. A comparison of radiographic occlusal and approximal caries diagnoses made by 240 dentists. *Acta Odontol Scand.* 2001;59:285-9. [Medline:11680647](#) [doi:10.1080/000163501750541147](#)
- 17 Espelid I, Tveit AB, Mejre I, Sundberg H, Hallonsten AL. Restorative treatment decisions on occlusal caries in Scandinavia. *Acta Odontol Scand.* 2001;59:21-7. [Medline:11318041](#) [doi:10.1080/000163501300035724](#)
- 18 Domejean-Orliaguet S, Tubert-Jeannin S, Riordan PJ, Espelid I, Tveit AB. French dentists' restorative treatment decisions. *Oral Health Prev Dent.* 2004;2:125-31. [Medline:15646946](#)
- 19 Tubert-Jeannin S, Domejean-Orliaguet S, Riordan PJ, Espelid I, Tveit AB. Restorative treatment strategies reported by French university teachers. *J Dent Educ.* 2004;68:1096-103. [Medline:15466060](#)
- 20 Vrsalovic I, Baraba A, Anic I, Espelid I, Tveit AB, Miletic I. Restorative treatment decisions of dentists in Split and Dalmatia county on approximal and occlusal caries: a pilot study. *Acta Stomatol Croat.* 2009;43:126-36.
- 21 Mejre I, Kallest I C, Stenlund H. Incidence and progression of approximal caries from 11 to 22 years of age in Sweden: A prospective radiographic study. *Caries Res.* 1999;33:93-100. [Medline:9892776](#) [doi:10.1159/000016502](#)
- 22 Bader JD, Shugars DA. Descriptive models of restorative treatment decisions. *J Public Health Dent.* 1998;58:210-9. [Medline:10101697](#) [doi:10.1111/j.1752-7325.1998.tb02996.x](#)
- 23 Ghasemi H, Murtooma H, Torabzadeh H, Vehkalahti MM. Restorative treatment threshold reported by Iranian dentists. *Community Dent Health.* 2008;25:185-90. [Medline:18839727](#)
- 24 Traebert J, Wesolowski CI, de Lacerda JT, Marcenes W. Thresholds of restorative decision in dental caries treatment among dentists from small Brazilian cities. *Oral Health Prev Dent.* 2007;5:131-5. [Medline:17722440](#)
- 25 Traebert J, Marcenes W, Kreutz JV, Oliveira R, Piazza CH, Peres MA. Brazilian dentists' restorative treatment decisions. *Oral Health Prev Dent.* 2005;3:53-60. [Medline:15921338](#)
- 26 Rajic Z, Radionov D, Rajic-Mestrovic S. Trends in dental caries in 12-year old children in Croatia. *Coll Antropol.* 2000;24 Suppl 1:21-4. [Medline:10946460](#)
- 27 Strand GV, Nordbo H, Tveit AB, Espelid I, Wikstrand K, Eide GE. A 3-year clinical study of tunnel restorations. *Eur J Oral Sci.* 1996;104:384-9. [Medline:8930587](#) [doi:10.1111/j.1600-0722.1996.tb00096.x](#)
- 28 Black GV. *A work on operative dentistry*, 5th edition. Chicago (IL): Medico-Dental Pub Co; 1922.
- 29 Nordbo H, Leirskar J, von der Fehr FR. Saucer-shaped cavity preparations for posterior approximal resin composite restorations: observations up to 10 years. *Quintessence Int.* 1998;29:5-11. [Medline:9611469](#)
- 30 Jones DW. Has dental amalgam been torpedoed and sunk? *J Dent Res.* 2008;87:101-2. [Medline:18218833](#) [doi:10.1177/154405910808700203](#)