

Glomerular Complement Components in Human Glomerulonephritis

PIERRE J. VERROUST, CURTIS B. WILSON, NEIL R. COOPER,
THOMAS S. EDGINGTON, and FRANK J. DIXON

*From the Department of Experimental Pathology, Scripps Clinic and Research
Foundation, La Jolla, California 92037*

ABSTRACT 154 of 255 individual human renal biopsies studied by immunofluorescence contained varying combinations of immunoglobulins (Ig), complement (C) components C1q, C3, C4, C5, C6, C8, C3 proactivator (C3PA), and/or properdin. 10 patients had linear deposits of Ig in glomeruli characteristic of antiglomerular basement membrane (GBM) antibodies; nine patients had C3 deposits (minimal in three) with generally lesser amounts of C1q, C4, C5, C6, and/or C8. 118 of the patients had granular deposits of Ig, suggesting immune complex glomerulonephritis; 114 of these had deposits of C3, usually accompanied by C1q, C4, C5, and/or C6. These observations indicate that the entire C sequence is deposited in glomeruli in most Ig-mediated glomerulonephritides. However, certain cases of anti-GBM glomerulonephritis with few or no C deposits may utilize pathways of injury independent of C.

21 patients had granular C3 deposits without detectable Ig. C5, C6, and C8 were present in the majority of these patients while C1q was absent and scant C4 was observed in only two patients. The presence of only late-acting C components in the absence of Ig, C1q, and C4 suggests selective, possibly nonimmune activation of the alternate C pathway. Finally, five patients had granular deposits of C3, C5, C6, and/or C8 diffusely in all or most glomeruli with a lesser number of glomeruli having additional focal granular deposits of Ig, C1q, and C4. This observation suggests that at least two patterns of C activation can occur simultaneously, possibly trig-

gered by antecedent immune complex deposition and then perpetuated by an as yet undetermined mechanism.

INTRODUCTION

The concept that complement (C) participates in glomerulonephritis initiated by either nonglomerular antigen-antibody complexes or anti-glomerular basement membrane (GBM)¹ antibodies is supported by the association of decreased serum C levels and more directly by the demonstration of C3 deposits in the diseased glomeruli of experimental animals and humans (1). Most immune complexes can activate C1, which in turn can cleave C4 and C2 leading to the formation of the C3 convertase, C₄2. This enzyme can then initiate the sequential activation of the later components, C3 to C9, which are responsible for the biological properties related to inflammation, including the attraction of polymorphonuclear leukocytes. The C sequence starting at C3 can also be activated via an alternate pathway (2). This pathway, which may be activated selectively by immunologic as well as nonimmunologic stimuli (3), is closely related to the properdin system (4). It is believed that these stimuli activate properdin, which can then interact with C3 to acquire the capacity of activate C3PAse (5). C3PAse can then activate C3PA, which in turn can cleave C3 and activate C3 to C9. The C3b fragment generated in this process is by itself capable of activating C3PAse, thereby generating a positive feedback mechanism (6). As a consequence of this property of C3b, the feedback mechanism can be brought into play independently of properdin when C3b is produced by activation of the classical C142 pathway. The deposition of C components in glomeruli was therefore studied to

This work was presented in part at the Annual Meetings of the American Association of Immunologists held in Atlantic City, N. J., in April, 1973; Verroust, P. J., and C. B. Wilson. 1973. *Fed. Proc.* 32: 982.

This is Publication No. 716 from the Department of Experimental Pathology, Scripps Clinic and Research Foundation.

Received for publication 12 June 1973 and in revised form 31 August 1973.

¹ Abbreviations used in this paper: CHGN, chronic hypocomplementemic glomerulonephritis; GBM, glomerular basement membrane.

delineate further the roles of these two pathways of C activation in human glomerulonephritis. The patients studied were categorized according to the presumed immunopathogenesis of their renal disease based on the patterns of Ig deposition in their glomeruli. Clinical-pathologic classifications, although helpful in patient management, have little etiologic usefulness (1).

METHODS

Patient material. Snap-frozen renal biopsies from 255 patients (over 90% from adults) were submitted for immunopathological characterization from several transplantation and nephrology centers. Clinical information was obtained when possible from hospital summaries and a questionnaire completed by the patient's referring physician.

Antisera. The mechanism of immunopathologic injury was investigated by using antisera monospecific for immunoglobulin (Ig) G, A, and M. C1q, C4, C5, C6, C8, and C3PA were prepared by previously described methods (2). Antisera to C1q, C3, C4, C5, and C8 were obtained by repeated immunization of goats with 2–20 µg of the purified component in incomplete Freund's adjuvant. Antisera to C6 and C3PA were produced in rabbits immunized with 50 µg of purified C6 or C3PA. Before use, most of these antisera were absorbed with Cohn fraction II, FIII, FV, IgM, or IgA. When tested by immunodiffusion against normal human serum (neat or diluted), they gave only one line, which fused completely with the line obtained by reacting the antiserum with the immunizing protein. The anti-C3 used was also capable of detecting the C3 breakdown products C3b, C3c, and C3d. Fluoresceinated IgG fractions of each antiserum were used to stain fixed cryostat sections of snap-frozen tissue for immunofluorescent microscopy (7). The specificity of each antiserum was further ascertained at the level of sensitivity of immunofluorescence by blocking positive reactions by prior absorption with the relevant antigen. Other specificity controls included the lack of staining of "normal" renal biopsy tissue obtained from kidneys nephrectomized for neoplasia, as well as staining with fluoresceinated antialbumin and transferrin. Fluoresceinated antiproperdin was provided by Dr. N. G. Westberg (8).

RESULTS

The patients were divided into four groups according to the presence or absence of Ig and/or C3 in their glomeruli.

Group I—no Ig and C3. Biopsies from 101 patients, presumably nonglomerulonephritic or with advanced renal damage, had no detectable glomerular Ig, C1q, C3, or C4.

Group II—linear deposits of Ig. 10 patients, including eight with Goodpasture's syndrome, had linear deposits of Ig indicating anti-GBM antibodies (Table I). The presence of anti-GBM antibody was confirmed by elution of kidney tissue available in three patients and by detection in serum from six of eight patients studied. As previously described (7), the staining for C3 was considerably less intense than that for Ig in all patients except two, and in four did not exceed equivocal or trace amounts. The patterns of C3 deposition were often more irregular than that of IgG, tending to be interrupted and segmental (Fig. 1). C1q, C4, C5, C6, and C8 deposits were also more focal than Ig deposits and could not be detected in the patient without any definite C3 deposits. Scant irregular deposits of properdin were found in three of seven patients studied. Eight biopsies stained for C3PA were negative. All patients had proliferative glomerulonephritis, which in six was accompanied by marked crescent formation (Table II).

The presence or absence of C components in these patients did not clearly relate to the severity of their clinical course. Eight patients had rapidly progressive renal failure, including those four with only minimal or equivocal C component deposition. In contrast, the two patients who did not progress to severe renal functional impairment had detectable amounts of C bound in their glomeruli.

Group III—granular deposits of Ig and C3. Granular deposits of IgG with or without accompanying IgA or IgM, suggesting the presence of immune complexes,

TABLE I
Glomerular Ig and C Component Deposition in 149 Patients

| | C3 | C1q | C4 | C5 | C6 | C8 |
|----------------------|-------|-------|-------|-------|-------|-------|
| Linear: IgG* | 9/10 | 5/10 | 6/10 | 7/10 | 8/9 | 6/8 |
| Granular: IgG | 44/46 | 39/46 | 36/46 | 13/16 | 7/7 | ND |
| IgG, IgA | 29/29 | 18/29 | 27/29 | 9/10 | ND | ND |
| IgG, IgM | 17/19 | 14/19 | 13/19 | 9/12 | 8/10 | ND |
| IgG, IgA, IgM | 24/24 | 23/23 | 22/22 | 20/20 | 5/5 | ND |
| ‡No IgG, IgA, or IgM | 21/21 | 0/21 | 2/21 | 14/16 | 16/18 | 12/13 |

ND, not done.

* IgA and IgM were detected in one patient each in addition to IgG.

‡ Five patients studied for the presence of IgE were negative.

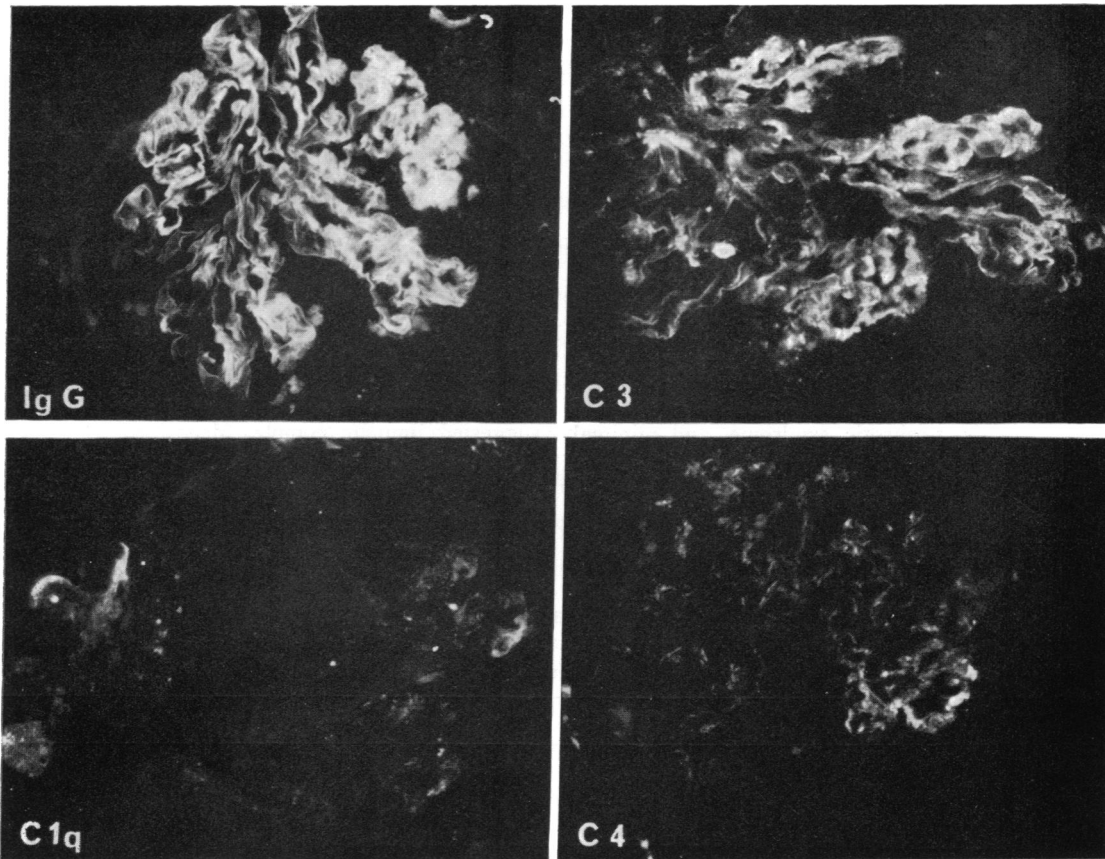


FIGURE 1 Linear deposits of IgG were present along the GBM of a patient (group II) with elution-confirmed anti-GBM antibody-induced glomerulonephritis. C3 deposits were less intense and not uniformly linear while even lesser quantities of C1q and C4 were present along segments of the GBM. (Stained with fluorescein isothiocyanate-conjugated antisera specific for the antigen listed in the lower left corner of each photomicrograph, original magnification $\times 250$.)

were present in 118 patients (Table I). The clinicopathological information available from 48 of these patients was sufficient to include them in Table II. Serum C levels, measured as either C3 or CH50, were subnormal in 5 of 14 cases. No obvious correlation was evident between C deposition and the Ig class present in the glomeruli, serum C level, or clinicopathological diagnosis. However, the initial components C1q and C4 were least frequent in patients with membranous and advanced chronic glomerulonephritis.

C3 was found in all but four of the 118 patients, and C5 or C6 or both were detected in almost all patients studied. Only two patients lacked both C5 and C6. One had diffuse proliferative glomerulonephritis with crescent formation and a rapidly progressive course and the other had membranous glomerulonephritis. The topography and the intensity of the staining for Ig and C were generally the same (Fig. 2); however, in some patients there was less C1q or C4 than other C compo-

nents. Both C1q and C4 were found in 87 patients; C1q alone appeared in 9 patients, and C4 alone in 11 patients. Neither C1q nor C4 could be detected in 11 cases. Information available from eight of these 11 patients revealed membranous glomerulonephritis in 3, advanced chronic glomerulonephritis in 2, and diffuse proliferative, focal proliferative, and proliferative crescent-forming glomerulonephritis in 1 each. Ig was present in only trace to 1+ quantities in nine of these patients, while two patients with membranous glomerulonephritis had Ig in 2-3+ quantities.

Group IV-granular deposits of C3 in the absence of Ig. In 21 of 26 patients, deposition of C3 was observed in the absence of detectable Ig (Table I, Fig. 3). The clinicopathological diagnoses available on 19 patients (Table II) were similar to those in group III except for the absence of membranous glomerulonephritis and a higher proportion of advanced chronic glomerulonephritis. Serum C levels available from the referring physi-

cians in nine patients were decreased only in the patient with membranoproliferative glomerulonephritis. Either C5, C6, or C8 was detectable in 16 of 18 patients studied, with 11 having all three components, 5 having C5 and C6, and 2 having C6 and C8. In contrast to group III, however, no C1q was evident and traces of C4 appeared in only two patients. In 12 patients studied, C3PA was present in a trace amount in one with an "embolic" glomerulonephritis associated with *Staphylococcus aureus* endocarditis and was present questionably in another with advanced chronic glomerulonephritis. Small amounts of properdin were detected in 6 of 14 patients studied and had no obvious predilection for any clinicopathologic category. One unusual woman in this group who had rheumatoid arthritis, nephrotic syndrome, and minimal glomerular changes on light microscopy had small quantities of C3 in glomeruli, a finding unusual for this histopathology.

The remaining five patients were remarkable because

two distinct staining patterns of Ig and C component deposition were present in adjacent glomeruli. Whereas heavy diffuse granular deposits of C3 and later C components (four biopsies studied) could be detected in almost all glomeruli, Ig (presumed immune complex), C1q, and C4 were found in a less intense granular pattern in a minority of glomeruli (usually the least damaged ones). Properdin found in two patients involved all the glomeruli in one and only the least damaged in the other. One biopsy stained for C3PA was negative. Four patients had advanced renal damage with normal C levels. One patient had membranoproliferative glomerulonephritis and decreased serum C levels; a previous biopsy had shown diffuse granular IgG and C3 deposits, which suggested immune complex deposition. These five patients would appear to represent a period of transition between patients in group III and group IV. As in the group IV patients, a large proportion had advanced chronic glomerulonephritis.

TABLE II
Correlation of Ig, C-Deposition and Clinical Pathologic Diagnosis in those Patients with Sufficient Clinical Information

| Clinical-pathologic diagnosis | IgG | IgA | IgM | C1q | C3 | C4 | C5 | C6 | C8 |
|---|-------|------|------|------|-------|-------|-------|------|-----|
| Linear glomerular Ig deposits | | | | | | | | | |
| PGN | | | | | | | | | |
| Diffuse with crescents | 6/6 | 1/6 | 0/6 | 3/6 | 6/6 | 4/6 | 5/6 | 5/5 | 4/5 |
| Diffuse | 4/4 | 0/4 | 1/4 | 2/4 | 3/4 | 2/4 | 2/4 | 3/4 | 2/3 |
| Granular glomerular Ig deposits | | | | | | | | | |
| PGN | | | | | | | | | |
| Diffuse with crescents | 4/4 | 0/4 | 1/4 | 3/4 | 3/4 | 3/4 | 3/4 | 0/1 | ND |
| Diffuse | 4/4 | 2/4 | 1/4 | 2/4 | 4/4 | 3/4 | 2/2 | 1/1 | ND |
| Focal | 7/7 | 6/7 | 5/7 | 6/7 | 6/7 | 6/7 | 5/5 | 1/1 | ND |
| MGN | 13/13 | 4/13 | 1/13 | 9/13 | 11/13 | 10/13 | 5/7 | 2/3 | ND |
| ACGN | 10/10 | 5/10 | 6/10 | 7/10 | 10/10 | 5/10 | 6/6 | 2/2 | 1/1 |
| MPGN | 6/6 | 2/6 | 1/6 | 6/6 | 6/6 | 6/6 | 1/1 | ND | ND |
| SLE* | 4/4 | 2/4 | 1/4 | 4/4 | 4/4 | 4/4 | 2/2 | ND | ND |
| Grangular glomerular C deposits in the absence of Ig | | | | | | | | | |
| PGN | | | | | | | | | |
| Diffuse | 0/3 | 0/3 | 0/3 | 0/3 | 3/3 | 0/3 | 1/2 | 2/2 | 1/2 |
| Focal | 0/2 | 0/2 | 0/2 | 0/2 | 2/2 | 0/2 | 1/1 | 1/1 | ND |
| ACGN | 0/11 | 0/11 | 0/11 | 0/11 | 11/11 | 1/11 | 10/11 | 11/1 | 9/9 |
| MPGN | 0/1 | 0/1 | 0/1 | 0/1 | 1/1 | 0/1 | 0/1 | 0/1 | ND |
| MC | 0/1 | 0/1 | 0/1 | 0/1 | 1/1 | 0/1 | 0/1 | 0/1 | ND |
| "Embolic" GN of endocarditis | 0/1 | 0/1 | 0/1 | 0/1 | 1/1 | 1/1 | 1/1 | 1/1 | 1/1 |
| Differing granular Ig and C3 deposits in adjacent glomeruli | | | | | | | | | |
| ACGN | 4/4 | 0/4 | 4/4 | 1/2 | 4/4 | 4/4 | 4/4 | 2/2 | 2/3 |
| MPGN | 0/1 | 0/1 | 1/1 | 1/1 | 1/1 | 1/1 | ND | ND | ND |

Abbreviations: ACGN, advanced chronic glomerulonephritis; GN, glomerulonephritis; MC, minimal change lesion; MGN, membranous glomerulonephritis; MPGN, membranoproliferative glomerulonephritis; ND, not done; PGN, proliferative glomerulonephritis; SLE, systemic lupus erythematosus.

* One patient each with diffuse PGN with crescents, diffuse PGN, focal PGN and MGN.

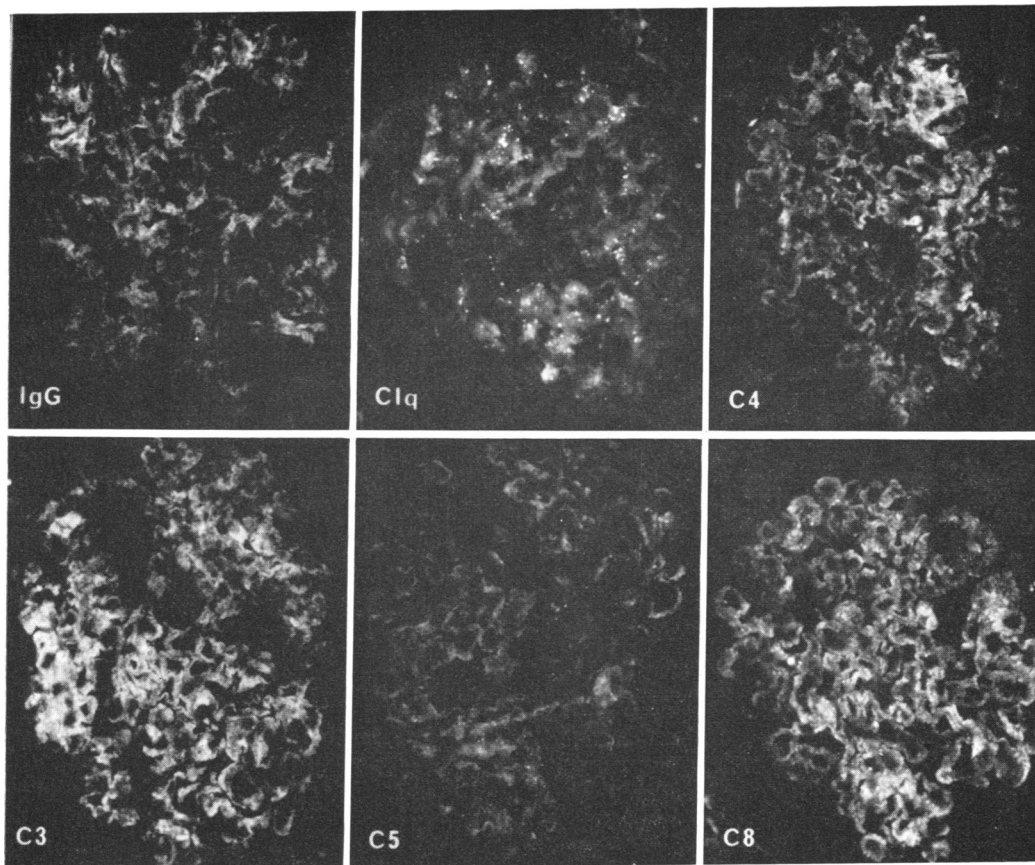


FIGURE 2 Granular deposits of IgG (presumed immune complex) were present along the GBM of a patient (group III) with membranous glomerulonephritis. C1q, C4, C3, C5, and C8 were found in similar intensity and distribution suggesting activation and deposition of the entire C sequence. (Stained with fluorescein isothiocyanate-conjugated antisera specific for the antigen listed in the lower left corner of each photomicrograph, original magnification $\times 250$.)

DISCUSSION

The presence of both early- (C1q, C4) and later- (C3, C5, C6, C8) acting C components in most cases of presumed immune complex and anti-GBM antibody-induced nephritis suggests activation of the entire C sequence via the classical pathway. This in turn could lead to feedback activation of the alternate C pathway by production of C3b. The immunofluorescent evidence of complement component deposition does not allow quantitation of the contribution of either pathway. Additional evidence of simultaneous classical and alternate pathway activation in Ig (presumed immune complex)-induced glomerular injury is that seen in systemic lupus erythematosus in which glomerular deposits of C4 and properdin (9) as well as decreased serum levels of C4 and C3PA (10) have been observed. In this situation the presence of properdin would indicate the activation of

the alternate C pathway independent of C3b feedback. The properdin deposition does not correlate with the presence of IgA (9) and its mechanism of activation is currently unknown.

The fact that 11 patients in this study had granular Ig and C3 deposits in the absence of detectable C1q and C4 suggests that in these cases activation favored the alternate pathway. The C component pattern could not be related to a predominance of IgA, which was present in only small amounts in three patients, and there were no other obvious clinicopathologic differences noted in this subgroup of granular Ig (presumed immune complex)-induced glomerulonephritis. Since serial studies were performed in only one patient in this report, differences in deposition and turnover rates cannot be excluded as a cause for different patterns of Ig and C3 component deposition. Little or no quantitative information is available regarding deposition or relative turn-

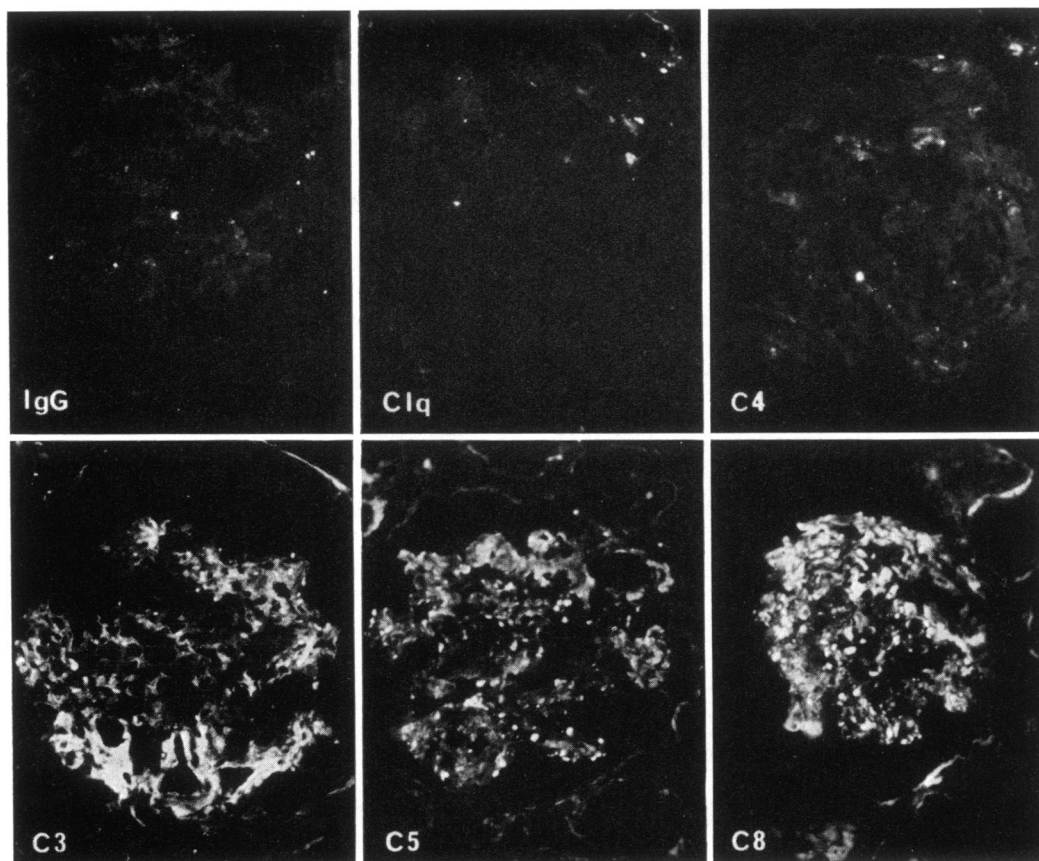


FIGURE 3 Intense granular deposits of C3 and more terminal C components, C5 and C8, were found in the absence of immunoglobulin (IgG, IgA, IgM) and initial C components C1q and C4 in a patient (group IV) with advanced chronic glomerulonephritis. (Stained with fluorescein isothiocyanate-conjugated antisera specific for the antigen listed in the lower left corner of each photomicrograph, original magnification $\times 250$.)

over rates of glomerular-bound Ig and C components; however, examination of experimental models of glomerulonephritis and of limited numbers of humans who have had serial biopsies suggests that C3 may persist after Ig is no longer detectable.²

IgG deposits without detectable C component deposition occur rarely in immune complex glomerulonephritis and in possibly 25% of anti-GBM antibody-induced glomerulonephritides (7), although the IgG subclasses deposited in the latter condition have an intrinsic capacity to fix C (11, 12). Glomerular injury in these instances may be mediated by C-independent pathways similar to those utilized by avian and some mammalian anti-GBM antibodies (13, 14).

The presence of glomerular C3, C5, C6, and C8 oc-

asionally with properdin in the absence of Ig, C1q, and C4 in 21 patients in this study suggests that alternate C pathway activation by nonimmune mechanisms may generate C3 and terminal C component deposition. The presence of C deposits in the absence of Ig (15) as well as depression of terminal serum C component levels (16, 17) in patients with chronic hypocomplementemic glomerulonephritis (CHGN) suggests the possibility of a similar mechanism. Although the serum of these patients may contain substances (18) that persist after nephrectomy and are capable of activating the alternate C pathway (19), there is as yet no evidence that this activation is responsible for glomerular C deposition. Indeed, we have attempted to induce glomerular C deposition in rabbits by daily administration of activators of the alternate C pathway such as inulin and zymosan. Although C3 deposits were observed in acute experi-

²Wilson, C. B. Unpublished observations.

ments, chronic administration did not result in selective C3 deposition.³

The initiating role of nonimmune C activation in CHGN must be accepted with further caution in view of the finding that granular deposits of Ig, C1q, and C4 are present at some time in over two-thirds of such patients (15). Not all these CHGN patients had Ig deposits when first examined, and some patients have been observed to lose detectable Ig when studied serially (15, 20). This finding plus our observation that roughly 10% of glomerulonephritic kidneys, usually those with advanced damage, contain C3 and more terminal C components in the absence of Ig suggest the possibility that the C3-associated phlogogenic response is perpetuated by alternate C pathway activation and is independent of continued Ig deposition.

We have observed that in some patients C component deposition suggesting alternate C pathway activation may occur in some glomeruli while adjacent glomeruli may contain Ig-associated classical pathway constituents. This may represent a transition between these two modes of complement activation. Several possibilities can be proposed to explain the change in the pathway of C activation: *a*) some of the immune-complex antigens may possess the capacity for direct activation of the alternate pathway; *b*) a large antigen excess may produce small complexes capable of activating the alternate pathway (21); *c*) bound C3b may activate the alternate pathway by the feedback mechanism (6); or *d*) the ability of pronase-altered GBM to activate the alternate pathway suggests that a parallel role may apply to GBM altered by previous immunological injury.⁴ There is currently little evidence leading us to favor one of these possibilities over another.

ACKNOWLEDGMENTS

The authors are grateful for the technical assistance of Ms. Marli West, the editorial and secretarial contribution of Ms. Phyllis Minnick and Ms. Karen Hazard, and illustrative aid of Ms. Karen Prescott and Mr. Gary Sanford. We are also indebted to the many physicians throughout the country who contributed the patient material utilized in this study.

This work was supported by U. S. Public Health Service Contract PH-43-68-621, U. S. Public Health Service Grant A1-07007, U. S. Public Health Service Research Career Development Award 5K4 A133,630-02, Atomic Energy Commission Contract AT(04-3)-410, and National Institutes of Health Research Grant HL 15216.

³ Verroust, P., C. B. Wilson, and F. J. Dixon. The lack of nephritogenicity associated with systemic activation of the alternate complement pathway. Submitted for publication.

⁴ Lambert, P. H. Personal communication.

REFERENCES

1. Wilson, C. B. 1973. Immunopathology of glomerulonephritis. In Textbook of Immunopathology. P. A. Miescher and H. J. Müller-Eberhard, editors. Grune & Stratton, Inc., New York. In press.
2. Müller-Eberhard, H. J. 1971. Biochemistry of complement. In Progress In Immunology. B. Amos, editor. Academic Press, Inc., New York. 553.
3. Götze, O., and H. J. Müller-Eberhard. 1971. The C3-activator system: an alternate pathway of complement activation. *J. Exp. Med.* 134: 90 S.
4. Goodkofsky, I., and I. H. Lepow. 1971. Functional relationship of factor B in the properdin system to C3 proactivator of human serum. *J. Immunol.* 107: 1200.
5. Götze, O., and H. J. Müller-Eberhard. 1973. The role of properdin in the alternate pathway of C activation. *J. Immunol.* 111: 288.
6. Müller-Eberhard, H. J., and O. Götze. 1972. C3 proactivator convertase and its mode of action. *J. Exp. Med.* 135: 1003.
7. Wilson, C. B., and F. J. Dixon. 1973. Antiglomerular basement membrane antibody-induced glomerulonephritis. *Kidney Int.* 3: 74.
8. Westberg, N. G., G. B. Naff, J. T. Boyer, and A. F. Michael. 1971. Glomerular deposition of properdin in acute and chronic glomerulonephritis with hypocomplementemia. *J. Clin. Invest.* 50: 642.
9. Rothfield, N., A. Ross, J. O. Minta, and I. H. Lepow. 1972. Glomerular and dermal deposition of properdin in systemic lupus erythematosus. *N. Engl. J. Med.* 287: 681.
10. Hunsicker, L. G., S. Ruddy, C. B. Carpenter, P. H. J. P. Merrill, H. J. Müller-Eberhard, and K. F. Austen. 1972. Metabolism of third and complement (C3) in nephritis. Involvement of classical and alternate (properdin) pathways for complement activation. *N. Engl. J. Med.* 287: 835.
11. McPhaul, J. J., and F. J. Dixon. 1971. Characterization of immunoglobulin G anti-glomerular basement membrane antibodies eluted from kidneys of patients with glomerulonephritis. II. IgG subtypes and *in vitro* complement fixation. *J. Immunol.* 107: 678.
12. Lewis, E. J., G. J. Busch, and P. H. Schur. 1970. Gamma G globulin subgroup composition of the glomerular deposits in human renal disease. *J. Clin. Invest.* 49: 1103.
13. Cochrane, C. G., E. R. Unanue, and F. J. Dixon. 1965. A role of polymorphonuclear leukocytes and complement in nephrotoxic nephritis. *J. Exp. Med.* 122: 99.
14. Henson, P. M. 1971. Release of biologically active constituents from blood cells and its role in antibody-mediated tissue injury. In Progress In Immunology. B. Amos, editor. Academic Press, Inc., New York. 155.
15. Michael, A. F., N. G. Westberg, A. J. Fisher, and R. L. Vernier. 1971. Studies on chronic membranoproliferative glomerulonephritis with hypocomplementemia. *J. Exp. Med.* 134: 208 s.
16. Gewurz, H., R. J. Pickering, S. E. Mergenhagen, and R. A. Good. 1968. The complement profile in acute glomerulonephritis, systemic lupus erythematosus and hypocomplementemic chronic glomerulonephritis: Con-

- trast and experimental correlations. *Int. Arch. Allergy Appl. Immunol.* **34**: 556.
17. Lewis, E. J., C. B. Carpenter, and P. H. Schur. 1971. Serum complement component levels in human glomerulonephritis. *Ann. Intern. Med.* **75**: 555.
 18. Vallota, E. H., J. Forristal, R. E. Spitzer, N. C. Davis, and C. D. West. 1970. Characteristics of a non-complement-dependent C3-reactive complex formed from factors in nephritic and normal serum. *J. Exp. Med.* **131**: 1306.
 19. West, C. D., E. J. Ruley, J. Forristal, and N. C. Davis. 1973. Mechanisms of hypocomplementemia in glomerulonephritis. *Kidney Int.* **3**: 116.
 20. Herdman, R. C., R. J. Pickering, A. F. Michael, R. L. Vernier, A. J. Fish, H. Gewurz, and R. A. Good. 1970. Chronic glomerulonephritis associated with low serum complement activity (chronic hypocomplementemic glomerulonephritis). *Medicine (Baltimore)*. **49**: 207.
 21. Lambert, P. H., L. Perrin, and M. J. Auderset. 1973. Quantitative studies of the conversion of C3PA (GBG) to C3A (GGG). *Fed. Proc.* **32**: 960.