

Laparoscopic Management of a Ruptured Giant Epidermoid Splenic Cyst

Andreas Kiriakopoulos, MD, Dimitrios Tsakayannis, MD,
Savas Papadopoulos, MD, Dimitrios Linos, MD

ABSTRACT

Background: Epidermoid splenic cysts are uncommon lesions of the spleen. They are known to become symptomatic as a consequence of enlargement, infection, or rupture, the latter being an exceedingly rare complication traditionally treated with open splenectomy. We herein report a unique case of a giant epidermoid splenic cyst that ruptured spontaneously and was successfully treated with the laparoscopic approach.

Conclusion: Laparoscopic surgery may be considered an initial treatment option in cases of very large epidermoid cysts even when rupture occurs.

Key Words: Spleen, Splenic cyst, Epidermoid splenic cyst, Laparoscopic splenectomy.

INTRODUCTION

Laparoscopic splenectomy is an established therapeutic option for the elective treatment of nonparasitic splenic cysts. Spontaneous or traumatic rupture constitutes an absolute indication for open surgery. We herein report a case of a ruptured giant epidermoid splenic cyst that was successfully treated with the laparoscopic method.

CASE REPORT

A 32-year-old woman was urgently admitted to our department with acute onset of pain in the left upper quadrant that radiated to the left shoulder. She had no history of antecedent abdominal trauma; however, she did have a 2-month history of mild abdominal pain and left shoulder discomfort. On physical examination, tenderness in the left upper quadrant, diminished bowel sounds, and abdominal guarding were noted. Computerized tomography of the abdomen revealed a large cystic lesion, evolving from the spleen measuring 16 cm x 14 cm with features indicative of intra- and extrasplenic rupture. Also, a significant amount of free peritoneal fluid was present (**Figure 1**). With the imaging diagnosis of ruptured splenic cyst, the patient underwent a successful laparoscopic splenectomy.

OPERATIVE TECHNIQUE

After the induction of general anaesthesia and endotracheal intubation, the patient was placed in the full, right lateral decubitus position with the table tilted at 20° to 30° and in a moderate reverse Trendelenburg position. Pneumoperitoneum was established with the open method (Hassan technique) through the umbilicus up to the level of 15 mm Hg. Four 10-mm trocars were subsequently inserted along the left costal margin, allowing for bimanual operative manipulations. Splenic mobilization commenced with division of the splenocolic ligament, ligation of inferior polar vessels and division and ligation of short gastric vessels by using Ligasure (USSC, Autosuture Co, Norwalk, CT). The next operative step was the hilar control, which was accomplished by multiple firings of the EndoGIA (USSC, Autosuture Co, Norwalk, CT) applied directly to the splenic vascular pedicle. Once the hilum

Department of Surgery, "Hygeia" Hospital, Athens, Greece (Drs Kiriakopoulos, Tsakayannis, Linos).

Department of Pathology, "Hygeia" Hospital, Athens, Greece (Dr Papadopoulos).

We have no financial interest in any commercial device, equipment, instrument, or drug referred to in this article. We also declare that we have no relevant financial support or any conflicts of interest. Additionally, the manuscript discussion does not include products for which we are not labelled.

Address reprint requests to: Dimitrios Linos, MD, Harvard Medical School, Director of 1st Surgical Clinic, "Hygeia" Hospital, 227 Kifissias Avenue, Kifissia 14561, Athens, Greece. Telephone: 01130 2106125001, Fax: 01130 2106126170, E-mail: dlinos@hms.harvard.edu

© 2005 by JSLS, *Journal of the Society of Laparoendoscopic Surgeons*. Published by the Society of Laparoendoscopic Surgeons, Inc.

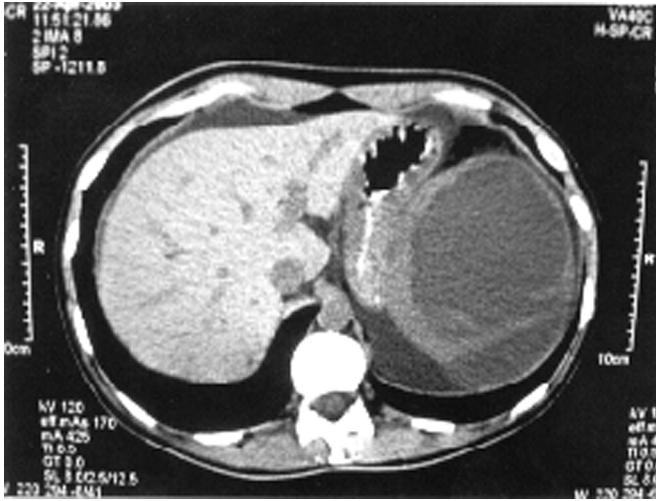


Figure 1. Computerized tomography of the abdomen, demonstrating the giant ruptured epidermoid splenic cyst and the intraperitoneal fluid.

was controlled, the ligamentous posterior peritoneal attachments were divided, preserving though the phrenic attachments. Subsequently, a specially designed retrieval bag was inserted through the left lower trocar site. After the entry of the spleen into the bag, the end of the bag was brought outside the abdomen through the umbilical trocar site. Then the spleen was morcellated with forceps and removed in large fragments. A drain was placed for 24 hours in the splenectomy bed.

Histologic examination revealed multiple splenic fragments with a total weight of 160g and dimensions of 18 cm x 14 cm x 7 cm. The bigger splenic fragment contained an empty cyst with dimensions of 9 cm x 6 cm with a fibrotic wall bearing epithelial lining (**Figures 2 and 3**). These findings were indicative of epidermoid splenic cyst.

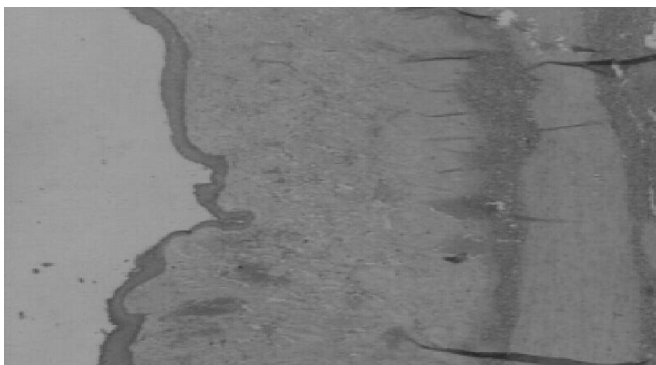

Figure 2. Histologic section revealing the epithelial lining of the splenic cyst.



Figure 3. Higher magnification view of the epithelial lining of the splenic cyst.

DISCUSSION

This report describes a rare case of a giant epidermoid splenic cyst that ruptured spontaneously and was successfully treated with laparoscopic splenectomy.

Nonparasitic splenic cysts are rare splenic lesions occurring in all age groups, probably resulting from a developmental anomaly, during which primitive mesothelium becomes entrapped within the splenic parenchyma.¹ Classifications of nonparasitic splenic cysts have generally divided them into “true” cysts, which bear an epithelial lining, and “false” or “posttraumatic” cysts, in which no lining can be demonstrated. However, the absence of an epithelial lining can be a spurious observation, so failure to identify scant remnants of this lining may lead to erroneous classification of a cyst.² Of the true splenic cysts, epidermoid cysts comprise 90%, whereas dermoid cysts are less common and comprise the remaining 10%.

Clinically, true splenic cysts may be completely asymptomatic, constituting an incidental finding during physical or radiologic examination or manifested with minor, non-specific symptoms, such as pain and abdominal distention due to cyst enlargement. Complications including infection and rupture are extremely rare; in a recent review, the reported overall complication rate was 5.2%, involving 6 cases of cyst rupture and 4 cases of cyst infection.³ Therefore, our case of spontaneous rupture of the giant splenic cyst is an exceedingly rare condition.

Nonoperative treatment is recommended for small cysts, up to 5 cm in diameter, if they are totally asymptomatic and the imaging characteristics are absolutely typical. When a splenic cyst is symptomatic or if the diagnosis is in doubt, operative therapy is warranted. Elective treatment options for nonparasitic splenic cysts include total splenectomy or some spleen-conserving variants, such as re-

removal of the cyst in its entirety along with a remnant of adjoining spleen (partial splenectomy) or leaving a small remnant of the cyst still affixed to the spleen (cystectomy or splenic decapsulation or partial cystectomy).^{4,5} Other limited treatments, such as percutaneous catheter drainage and sclerosis, have also been described; however, they are associated with high rates of recurrence or infection and have largely been abandoned.

Total splenectomy is the only method of operative treatment in the reported cases of ruptured epidermoid splenic cysts. Interestingly enough, although the application of the laparoscopic method is well documented in elective cases, it seems quite restricted in the urgent setting. Actually, no report has been published in the English literature about laparoscopic treatment of a ruptured epidermoid splenic cyst. Because our patient was hemodynamically stable, we opted for the laparoscopic approach, which was successfully completed.

CONCLUSION

It seems reasonable that acute rupture of an epidermoid splenic cyst does not constitute a contraindication for laparoscopic repair per se, and laparoscopic splenectomy may be attempted as an initial treatment option.

References:

1. Morgenstern L. Benign neoplasms of the spleen. In: Hiatt JR, Phillips EH, Morgenstern L, eds. *Surgical Diseases of the Spleen*. New York, NY: Springer; 1997;91–104.
2. Morgenstern L. Non-parasitic splenic cysts: pathogenesis, classification, and treatment. *J Am Coll Surg*. 2002;194(3):306–314.
3. Nakao A, Saito S, Yamano T, et al. Dermoid cyst of the spleen: report of a case. *Surg Today*. 1999;29(7):660–662.
4. Smith ST, Scott DJ, Burdick JS, Rege RV, Jones DB. Laparoscopic marsupialization and hemisplenectomy for splenic cysts. *J Laparoendosc Adv Surg Tech*. 2001;11(4):243–249.
5. Tsakayannis DE, Mitchell K, Kozakewich HP, Shamberger RC. Splenic preservation in the management of splenic epidermoid cysts in children. *J Pediatr Surg*. 1995;30:1468–1470.