

Laparoscopic Management of a Cystic Duct Cyst

Edward S. Chan, BA, Edward D. Auyang, MD, MS, Eric S. Hungness, MD

ABSTRACT

Background: Choledochal cysts are rare cystic dilations of the biliary tree. Though their cause is uncertain, these cysts are usually referred for surgical resection because of their association with developing malignancy. Traditionally, choledochal cysts have been classified under 5 main types. Not included in this classification are cysts of the cystic duct, a condition that is even rarer, with only 14 cases reported in the literature to date. We describe one such rare case of a cyst of the cystic duct that we successfully treated via laparoscopic resection.

Methods and Results: A 41-year-old male was found to have a biliary abnormality on a routine follow-up computed tomography (CT) scan for an unrelated medical condition. Further magnetic resonance cholangiopancreatography (MRCP) imaging identified a cystic dilation consistent with a Type II choledochal cyst. Laparoscopic resection was performed using a total of 5 trocars, at which time a cyst of the cystic duct was found instead of the expected Type II choledochal cyst. Intraoperative cholangiography was used as a surgical adjunct to confirm the anatomy, and resection of the cyst was completed without complications.

Conclusions: Our case adds to the body of reports showing that cysts of the cystic duct, while extremely rare, do occur and need to be recognized. Given the preoperative similarity between cystic duct cysts and other choledochal cysts, proposal for a new "Type VI" category for choledochal cysts may be considered so that clinicians can be prepared for this variation. Once recognized, cysts of the cystic duct can be safely and effectively removed by laparoscopic excision, as we have demonstrated.

Key Words: Choledochal cyst, Cystic duct cyst, Laparoscopy.

INTRODUCTION

Choledochal cysts are very rare biliary anomalies, occurring in about 1 in 100 000 in the Americas and Europe.¹ There are several proposed causes for their development including embryonic proliferation of biliary duct cells, the backflow of pancreatic juice into the biliary ducts, and obstruction of the common bile duct.¹⁻³ Patients presenting with choledochal cysts, regardless of the presence or absence of symptoms, are referred for surgical resection given the possibility for future development of malignancy.²⁻³

Traditionally, choledochal cysts have been classified under 5 main types, as described by Todani et al's modification of the Alonjo-Lej classification.⁴ Type I is a cyst of the common bile duct; type II is a cystic diverticulum coming off of the common bile duct; type III is a cyst in the intraduodenal portion of the common bile duct; type IV refers to multiple cysts in the intra- and extrahepatic biliary tract; and type V are single or multiple cysts in the intrahepatic ducts alone.

Not included in this classification are cysts of the cystic duct, a condition that is quite rare, with only 14 cases reported in the literature^{2,5-11} (**Figure 1**). Serena Serradel et al⁷ proposed including these cysts under a new "type VI" category. We describe one such rare case of a cystic duct cyst that we successfully treated via laparoscopic resection.

CASE REPORT

A 41-year-old male patient with a past medical history significant for nephrolithiasis was found to have cholelithiasis on a routine follow-up computed tomography (CT) scan (**Figure 2**). The CT scans and subsequent magnetic resonance cholangiopancreatography (MRCP) demonstrated a large cystic diverticular cavity arising from the inferior aspect of the common bile duct immediately proximal to its insertion on the pancreatic head and was suspicious for a type II choledochal cyst (**Figures 3, 4, and 5**). Based on these findings, the patient was referred to surgery. Upon interview, he reported occasional postprandial nausea once every 1 to 2 weeks after eating a large meal. His physical examination was unremarkable. Given that he was symptomatic with the

Northwestern University, Feinberg School of Medicine, Department of Surgery, Chicago, Illinois, USA (all authors).

Address correspondence to: Eric S. Hungness, MD, Department of Surgery, Northwestern University Feinberg School of Medicine, 676 N. St. Clair Street, Suite 650, Chicago, IL 60611, USA. E-mail: ehungnes@nmh.org

© 2009 by JLS, *Journal of the Society of Laparoendoscopic Surgeons*. Published by the Society of Laparoendoscopic Surgeons, Inc.

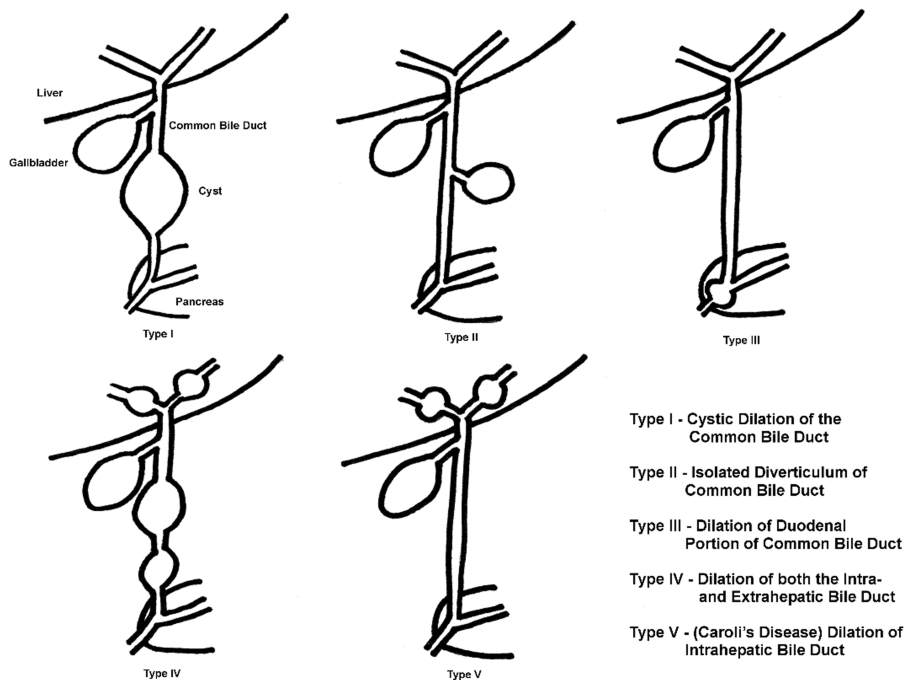


Figure 1. Cyst of the cystic duct.

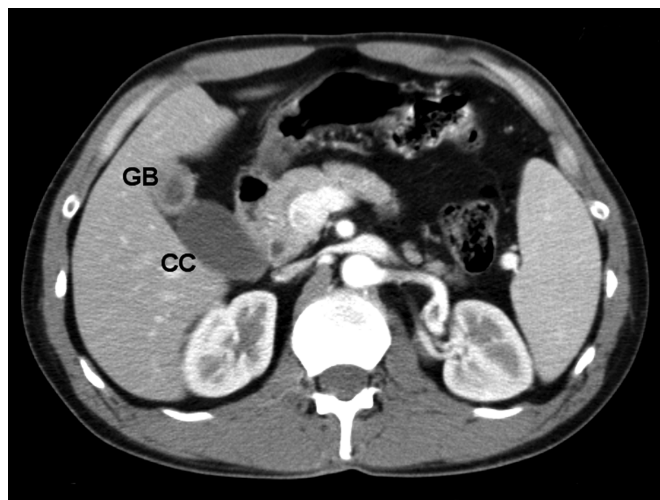


Figure 2. CT scan (GB=gallbladder, CC=choledochal cyst).

cyst being the likely cause and possible future development of malignancy, the patient was offered a laparoscopic surgical resection.

METHODS

Operative Technique

Pneumoperitoneum was established by using an open Hasson technique through a supraumbilical incision. An

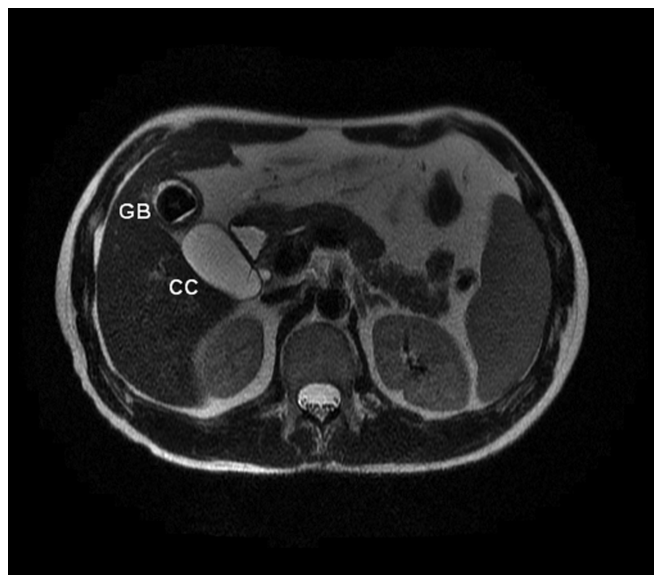


Figure 3. MRI (GB=gallbladder, CC=choledochal cyst).

additional 10-mm subxiphoid port and two 5-mm right-sided abdominal ports were placed in a fashion similar to that used in performing a standard laparoscopic cholecystectomy. An additional right-sided 5-mm port was placed to facilitate retraction and dissection.

A cystic lesion consistent with a choledochal cyst was identified inferior to the gallbladder. Dissection began in

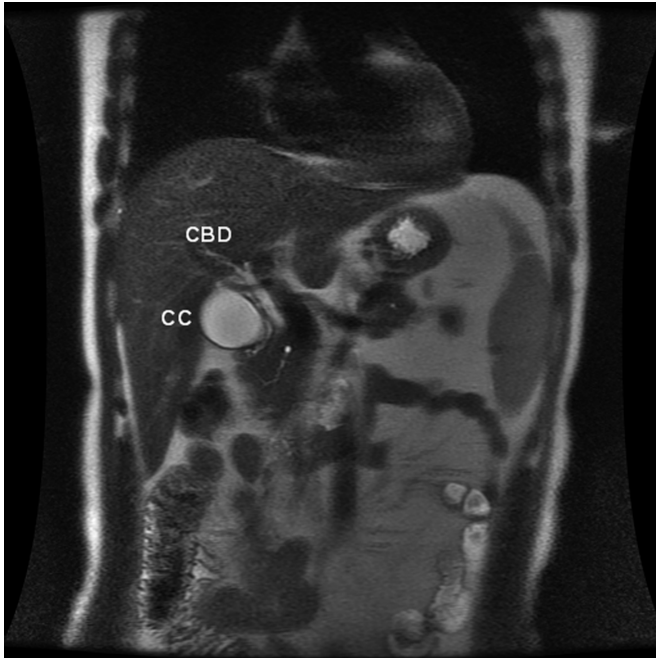


Figure 4. MRI (GB=gallbladder, CBD=common bile duct).

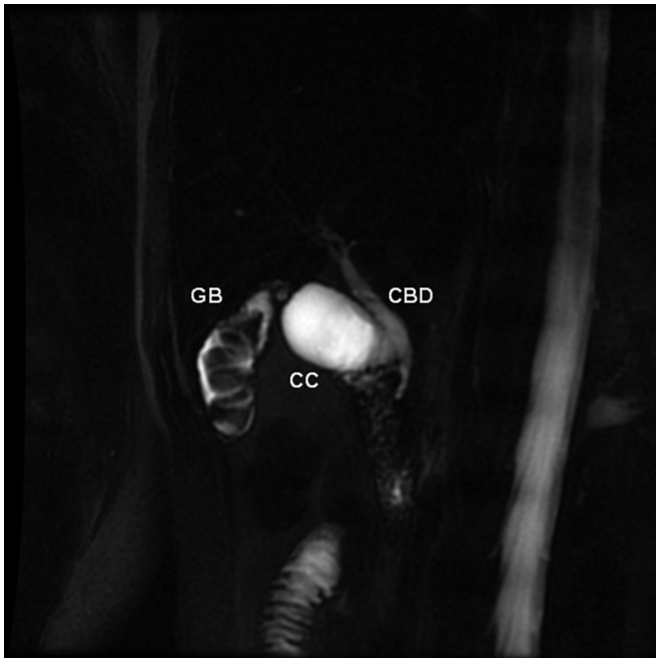


Figure 5. MRCP (GB=gallbladder, CC=choledochal cyst, CBD=common bile duct).

the lateral aspect of the plane between the gallbladder and the cyst. A wide dissection of the infundibulum of the gallbladder was then performed. Dissection of the gall-

bladder was hampered inferiorly by the location of the choledochal cyst and the presence of dense fibrous tissue.

The cyst itself was then dissected out, which led to the discovery of a narrowed, ductal-like structure exiting the cyst and inserting onto the common bile duct. A distal clip was placed on the side of the cyst and intraoperative cholangiography was performed. The cholangiogram demonstrated a normal-appearing common bile duct with free flow of contrast into the duodenum and up into the intrahepatic ductal branches. No additional duct led from the common bile duct into the gallbladder, suggesting that this was not a type II choledochal cyst, and that the cyst was instead arising from the cystic duct. The cystic duct was then divided distally with 2 proximal clips. A very long cystic artery going up onto the gallbladder wall was identified. The main tributaries of the cystic artery supplying the gallbladder and cyst were clip ligated. The gallbladder was then carefully dissected off the liver bed and removed.

The patient tolerated the procedure well without any acute complications and was discharged home on postoperative day one. The pathology analysis demonstrated a gallbladder with chronic cholecystitis and cholelithiasis and confirmed the cyst of the cystic duct. The patient had no postoperative complications.

DISCUSSION

Choledochal cysts in general are quite rare in the United States and Europe. For reasons still unknown, they occur more commonly in Asia, where the hospital admission rate for choledochal cysts is as high as 1 per 1000 admissions. They also occur in females almost 4 times more often than in males. The disease is still most commonly seen in young children, but in the United States and Europe, an increasing number of adult cases are being seen.^{1,12}

Although choledochal cysts are very rare, cysts of the cystic duct are even rarer. Nonetheless, enough cases have been reported to consider justification for Serena Serradel's proposal to add a "type VI" category to Todani's classification scheme for choledochal cysts. To our knowledge, ours is the 15th case of a cystic duct cyst reported in the literature.^{2,5-11} More widespread recognition and awareness of this type of cyst would benefit clinicians in the future who may encounter such cases.

Choledochal cysts have been associated with a classic triad of symptoms consisting of jaundice, right upper quadrant pain, and palpable abdominal mass. However,

less than 20% of choledochal cyst patients present with this triad. Abdominal pain, cholangitis, pancreatitis, and biliary peritonitis from cyst rupture are common, and many patients will present with fever, or nausea and vomiting.^{1,3} Children and adult patients have been shown to present with different symptoms; in one study, 9 of 11 (82%) children patients presented with at least 2 of the symptoms in the triad, whereas only 8 of 32 (25%) adult patients did. Adult patients also had signs and symptoms of pancreatitis, symptomatic gallstones, or acute cholecystitis, while no pancreatic or gallbladder pathology was primarily suspected in children.¹²

A review of the previous reports of cystic duct cysts shows that common symptoms for this rare type of cyst include epigastric and/or right upper quadrant pain (often stimulated by fat intake), cholangitis, jaundice, and fever. Our patient complained primarily of occasional postprandial nausea every 1 or 2 weeks after eating a large meal. The age of patients also varied, with at least half of them being over 16 years of age. The demographics and presentation for cystic duct cysts seem similar to those for choledochal cysts in general.

Management of choledochal cysts has evolved over time from enteric drainage to surgery. Drainage is associated with biliary stasis, recurrent infection, pancreatitis, and cholangitis.^{1,3} Surgical excision of the cyst is also now preferred because of the documented association between choledochal cysts and cancers of the gallbladder and common bile duct. The incidence of malignancy in choledochal cysts is reported at between 10% and 30%.³ The reason for malignancy in these cysts is not fully known, although pancreatic reflux, bile stasis, chronic inflammation and irritation, and infection have all been proposed as possible pathogeneses.^{1,2-4}

Surgical treatment for cystic duct cysts is relatively simple if the cyst has a narrow opening where it joins the common duct; cyst excision and cholecystectomy is sufficient, and no biliary reconstruction—as is common in treating type I and IV choledochal cysts—is necessary. If a wide opening is present between the cystic duct and the common duct, then a hepaticojejunostomy, hepaticoduodenostomy, or choledochal jejunostomy may need to be performed.⁹ Thus, surgical treatment for cystic duct cysts without wide openings is most similar to that of type II cysts, which also require cyst excision, but not the added burden of biliary reconstruction. Interestingly, just as cystic duct cysts are extremely rare, type II choledochal cysts are the rarest of types I-V, occurring in less than 2% of reported cases. The anatomical similarity between the 2

types has been reported on before; both Serena Serradel et al⁷ and Bode et al⁵ initially misdiagnosed their cases as type II cysts, and Loke et al⁹ also stated that their case of cystic duct cyst resembled a type II. Given this, one of the greater difficulties in managing cystic duct cysts is obtaining an accurate visualization of the anatomy to make the correct diagnosis. Bresciani et al² emphasize the importance of establishing the site of the cyst intraoperatively using adjuncts like intraoperative cholangiogram, just as we did.

Many cases of successful laparoscopic excision of choledochal cysts have been reported recently.^{1,3,13-16} Most of these involve type I cysts, and even with the added complication of biliary reconstruction, the results indicate that a laparoscopic approach to choledochal cyst excision is feasible and safe.⁵ Surgical treatment for cystic duct cysts (excluding those with a wide opening into the common duct) is similar to that for type II cysts; these are less complicated, and laparoscopic approaches to these have also been reported with good results.^{2-3,16} The only laparoscopic excision of a cystic duct cyst other than our case that we know of was done by Bresciani et al.²

CONCLUSION

Our case adds to the body of reports showing that cysts of the cystic duct, while extremely rare, do occur and need to be recognized. Given the preoperative similarity between cystic duct cysts and other choledochal cysts, the proposal for a new “Type VI” category for choledochal cysts may be considered so that clinicians can be prepared for this variation. Once recognized, cysts of the cystic duct can be safely and effectively removed by laparoscopic excision, as we have demonstrated.

References:

1. Lipsett PA, Pitt HA. Surgical treatment of choledochal cysts. *J Hepatobil Panc Surg.* 2003;10:352-359.
2. Bresciani C, Gama-Rodrigues J, Santos VR. Video-laparoscopic treatment of a sizeable cyst of the cystic duct. *Surg Lap and Endosc.* 1998;8:376-379.
3. Metcalfe MS, Wemyss-Holden SA, Maddern GJ. Management dilemmas with choledochal cysts. *Arch Surg.* 2003;138:333-339.
4. Todani T, Watanabe Y, Narusue M, Tabuchi K, Okajima K. Congenital bile duct cysts. *Am J Surg.* 1997;134:263-269.
5. Bode WE, Aust JB. Isolated cystic dilatation of the cystic duct. *Am J Surg.* 1983;145:828-829.
6. Kise Y, Uetsuji S, Takada H, Yamamura M, Yamamoto M.

Dilatation of the cystic Duct with its congenital low entry into the common hepatic duct. *Am J Gastroenter.* 1990;85:769–770.

7. Serena Serradel AF, Linares ES, Goepfert RH. Cystic dilatation of the cystic duct: a new type of biliary cyst. *Surgery.* 1991;109:320–322.

8. Benhidjeb T. Cystic duct cyst. *Surgery.* 1994;116:597–598.

9. Loke TKL, Lam SH, Chan CS. Choledochal cyst: an unusual type of cystic dilatation of the cystic duct. *Am J Roentgen.* 1999;173:619–620.

10. Baj M, Sengupta S, O'Donnell LJD. Choledochoceles of the cystic duct: a case report. *Internet Journal of Gastroenterology.* 2001;1(2).

11. Manickam S, Ramadan K, Adams BK. A rare choledochal cyst of the cystic duct with an anomalous pancreaticobiliary union in an adult patient. *Clin Rad Extra.* 2004;59:68–71.

12. Lipseet PA, Pitt HA, Colombani PM, Boitnott JK, Cameron JL. Choledochal cyst disease: a changing pattern of presentation. *Ann Surg.* 1994;220:644–652.

13. Hong L, Wu Y, Yan Z, Xu M, Chu J, Chen QM. Laparoscopic surgery for choledochal cyst in children: a case of 31 patients. *Euro J Ped Surg.* 2008;18:67–71.

14. Laje P, Questa H, Bailez M. Laparoscopic leak-free technique for the treatment of choledochal cysts. *J Laparoendo Adv Surg Tech, Part A.* 2007;17:519–521.

15. Abbas HMM, Yassin NA, Ammori BJ. Laparoscopic resection of type I choledochal cyst in an adult and roux-en-y hepaticojejunostomy: a case report and literature review. *Surg Lap End Percut Tech.* 2006;16:439–444.

16. Liu DC, Rodriguez JA, Meric F, Geiger JL. Laparoscopic excision of a rare type II choledochal cyst: case report and review of the literature. *J Ped Surg.* 2000;35:1117–1119.