

The Laparoscopic Management of Benign Bowel Fistulas

K. Moorthy, T. Shaul, BSc, R. J. E. Foley

ABSTRACT

Background: The presence of a fistula has usually been a factor predicting high conversion and complication rates following laparoscopic procedures for Crohn's disease and diverticulitis.

Methods: We studied retrospective data collected from the medical case notes of patients. A single surgeon carried out all these procedures from 1991 through 2001.

Results: Fourteen patients underwent 15 procedures. Six patients were males and 8 were females. The diagnosis was Crohn's disease in 10 patients and diverticulitis in 4. In 10 cases, the operation was the primary procedure, but 5 procedures were for recurrences. Two patients with diverticulitis and 3 with Crohn's disease had only the fistulae divided with the application of an Endo-GIA stapler across the fistulae (stapled fistulectomy). No bowel resections were carried out in these 5 patients. Four cases had to be converted due to bleeding (23%). The only postoperative complication was a single case of wound infection after conversion.

Conclusion: The presence of a fistula isn't necessarily an indication for conversion. If it is possible to dissect the loops free, we believe that a stapled fistulectomy is effective with a low incidence of fistula recurrence, especially in Crohn's disease.

Key Words: Management of benign bowel fistulas.

INTRODUCTION

Laparoscopic resections in diverticulitis and Crohn's disease have been shown to be safe and effective with considerable benefits to patients.¹⁻³ In most series that have been published so far, the presence of a fistula has usually been associated with a high conversion rate and a high rate of complications.⁴⁻⁶

The exact mechanism of fistula formation in Crohn's disease is still not clear, but both Crohn's disease and diverticulitis result from the extension of transmural inflammation into adjacent tissues. The fistula is internal if the communication is with another intraabdominal organ or external if it is with the skin.⁷ Usually only 1 diseased bowel segment is present, and the other bowel segment or the other organ is a "victim" of the process of extension.⁸

In some patients, the fistula may be the sole indication for the procedure, but usually enteroenteric or enterocolic fistulas are incidental operative findings.⁷

METHODS

The data were retrospectively collected from the medical case notes of the patients who had undergone laparoscopic surgery for bowel fistulas secondary to inflammatory conditions of the small and large intestine. A single surgeon carried out these procedures in the period between 1991 and 2001. All procedures were laparoscopic-assisted. The bowel was mobilized intracorporeally and then exteriorized through a 5-cm to 7-cm incision in the iliac fossae or through the lower end of a previous midline incision. The mesenteric vascular division and bowel resection was then carried out extracorporeally. Recently, the vascular division has been carried out intracorporeally. Bowel anastomosis was carried out either by a hand-sewn or stapled technique. In cases of left-sided resections, the rectum was stapled at the appropriate length, the diseased segment was exteriorized, the proximal bowel was stapled, a CEEA anvil was introduced into the proximal bowel loop, the bowel was then restored back into the abdomen, and pneumoperitoneum was reintroduced. The stapler was then introduced through the rectum and bowel continuity established. "Stapled fistulectomy" (**Figure 1**) was carried out by dissecting the plane

Department of Surgery, Bedford Hospital, Bedford, United Kingdom (all authors).

Address reprint requests to: K. Moorthy, Clinical Research Fellow, Dept of Surgical Oncology and Technology, Imperial College of Science, Technology and Medicine, 10th Floor, QEQM Building, St. Mary's Hospital, London W2 1NY, UK. Telephone: 0044 207 8861310, Fax: 0044 207 8861810, E-mail: k.moorthy@ic.ac.uk

© 2004 by JSLS, *Journal of the Society of Laparoendoscopic Surgeons*. Published by the Society of Laparoendoscopic Surgeons, Inc.

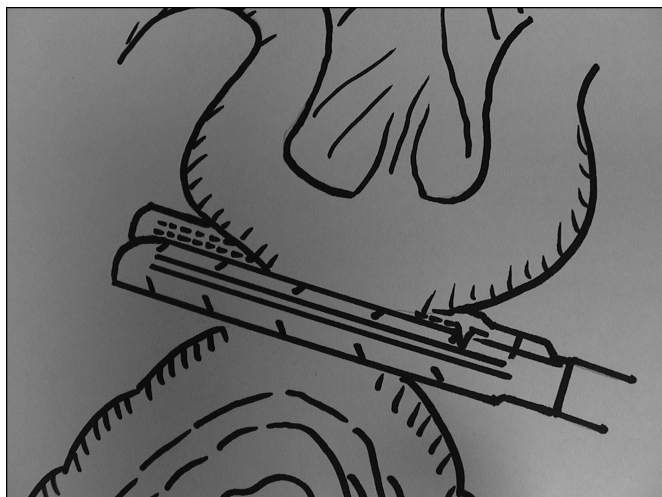


Figure 1. "Stapled fistulectomy."

between the diseased bowel segment and the victim bowel/organ, the fistula was identified, and an Endo-GIA stapler was used to transect the fistula. Univariate analysis of the factors predictive of conversion was done using Mann-Whitney and chi-square tests.

RESULTS

Fourteen patients underwent 15 procedures. Six patients were males and 8 were females. The diagnosis was Crohn's disease in 10 cases and diverticulitis in 4. All patients had their fistulas diagnosed preoperatively. Inves-

tigations consisted of Barium studies, colonoscopy, and computed tomography scan where appropriate. Among those patients with Crohn's disease, the fistulas were ileocolic in 3 cases, ileo-cutaneous in 1, colocutaneous in 1, colovesical in 1, ileo-vaginal in 1, and ileo-ileal in 3. The fistulas were colovesical in 4 and colovaginal in 1 amongst the cases with diverticulitis.

In 10 cases, the operation was the primary procedure, but 5 cases were for recurrences. Four procedures were performed after previous resections for Crohn's disease and one after the laparoscopic management of a colovesical fistula secondary to diverticulitis where only the fistula was divided with an Endo-GIA stapler.

All patients had normal inflammatory markers. **Table 1** gives the details of all the fistulas present in these patients with information about the procedure that was performed.

The mean blood loss was 238.4 mL (standard deviation, 155.6; median, 200). The mean operating time was 119.2 minutes (standard deviation, 38.93; median, 120).

Four cases had to be converted due to bleeding (23%). One was in a patient with diverticular disease who had a recurrence of his colovesical fistula. The other 3 conversions were in patients with Crohn's disease who had ileal fistulas, 2 of whom were being operated on for disease recurrence having had resections in the past. On univariate analysis, the factors predictive of conversion were the presence of a mass on clinical examination and surgery for recurrence.

Table 1.
Fistula Causes, Treatment, and Recurrence

Cause	Type of Fistula	Procedure	Recurrence of Fistula	Recurrence of Disease
Diverticulitis	Colovaginal 1	Division of fistula 1	Nil	Nil
	Colovesical 4	Sigmoid colectomy 3 Division of fistula 1	Nil 1	Nil Nil
Crohn's	Ileocolic 3	Right hemicolectomy 1	Nil	Nil
		Division of fistula 2	Nil	2
	Ileovaginal 1	Right hemicolectomy	Nil	Nil
	Ileocutaneous 1	Right hemicolectomy	Nil	Nil
	Ileoileal 3	Right hemicolectomy 1	Nil	Nil
		Small intestine resection+ Stricture 1	Nil	Nil
		Division of fistula+ Defunctioning ileostomy 1	Nil	Nil
Colovesical 1	Division of fistula	Nil	Nil	
Colocutaneous 1	Left hemicolectomy	Nil	Nil	

A single case of wound infection following conversion for a colovesical fistula was the only postoperative complication.

DISCUSSION

The difficulty in dissecting the plane between the inflamed bowel and the other loop into which the fistulizing has occurred (victim loop) often necessitates conversion or the resection of both loops of bowel. This is not necessary, and an attempt should be made to dissect this plane and transect the fistula to enable resection of the diseased loop and closure of the hole in the "victim" loop.⁸

In our earlier smaller series⁹ of patients with Crohn's disease undergoing laparoscopic surgery, we commented that division of the fistula with the help of an Endo-GIA stapler was associated with no recurrences after a median follow-up of 24 months. Since then with further follow-up (median, 59 months), the fistulas have not recurred though the inflammation has in 2 patients. One patient is still under treatment for disease recurrence. This patient had a biologically aggressive form of the disease, and before division of the fistula had already had a laparoscopic left anterior resection and a right hemicolectomy.

The idea of a stapled fistulectomy has been suggested earlier.¹⁰ Especially now, with accumulating evidence that newer treatment modalities such as Infliximab¹¹ may be effective in treating bowel fistulae in patients with Crohn's disease, it is likely that a laparoscopic stapled fistulectomy could be followed by the administration of these newer antiinflammatory agents or that this minimally invasive procedure could be reserved for those fistulas refractory to these agents.

However, this would only be possible if dissection in the plane between the affected loop and the other organ is possible. It will also be essential to ensure that no strictures are present distal to the fistula, preoperatively. This is especially pertinent to laparoscopic surgery as tactile sensation is lost. Of the 2 cases with sigmoid diverticulitis where a stapled fistulectomy was attempted, the fistula recurred in 1 patient with a colovesical fistula and was managed by a sigmoid resection.

The conversion rate of 23% in our series is nearly comparable to the rates reported.^{5,6} This rate is probably high because of the presence of a mass in 3 of the 4 cases that had to be converted and because a third of the cases underwent surgery for recurrence. Canin-Endres et al² commented on the high conversion rate in those cases of Crohn's disease where fistulas exist in combination with the presence of a mass.

The complication rate in our series is extremely low with only 1 case of postoperative wound infection. This is even lower than the rates reported in the literature so far.¹² This small series of patients demonstrates that when laparoscopic surgery is attempted by an experienced surgeon, the incidence of adverse effects can be reduced.

References:

1. Bemelman WA, Slors JFM, Dunker MS, et al. Laparoscopic-assisted vs open ileocolic resection for Crohn's disease. A comparative study. *Surg Endosc*. 2000;14:721-725.
2. Canin-Endres J, Salky B, Gattorno F, Edye M. Laparoscopically assisted intestinal resection in 88 patients with Crohn's disease. *Surg Endosc*. 1999;13:595-599.
3. Vargas DH, Ramirez RT, Hoffman GC, et al. Defining the role of laparoscopic-assisted sigmoid colectomy for diverticulitis. *Dis Colon Rectum*. 2000;43(12):1726-1731.
4. Bauer JJ, Harris MT, Grumbach NM, Gorfine SR. Laparoscopic-assisted intestinal resection for Crohn's disease. *Dis Colon Rectum*. 1995;38(7):712-715.
5. Joo JS, Agachan F, Wexner SD. Laparoscopic surgery for lower gastrointestinal fistulas. *Surg Endosc*. 1997;11:116-118.
6. Sher M, Agachan F, Bortol M, Nogueras J, Weiss E, Wexner S. Laparoscopic surgery for diverticulitis. *Surg Endosc*. 1997;11:264-267.
7. Lichtenstein GR. Treatment of fistulizing Crohn's disease. *Gastroenterology*. 2000;119:1132-1147.
8. Saint-Marc O, Turet E, Vaillant JC, Firleaux P, Parc R. Surgical management of internal fistulas in Crohn's disease. *J Am Coll Surg*. 1996;183(2):97-100.
9. Singh K, Prasad A, Saunders JHB, Foley RJE. Laparoscopy in the diagnosis and management of Crohn's disease. *J Laparoendosc Adv Surg Tech*. 1998;8(1):39-46.
10. Kusunoki M, Ikeuchi H, Yanagi H, Shoji Y, Yamamura T. Stapled fistulectomy to treat entero-enteric fistulas in Crohn's disease. *Surg Today*. 1997;27(6):574-551.
11. Present DH, Rutgeerts P, Targan S, et al. Infliximab for the treatment of fistulas in patients with Crohn's disease. *N Engl J Med*. 1999;340(18):1398-1405.
12. Poulin EC, Schlachta CM, Mamazza J, Seshadri PA. Should enteric fistulas from Crohn's disease or diverticulitis be treated laparoscopically or by open surgery? *Dis Colon Rectum*. 2000;43(5):621-627.

Presented as a poster presentation at the annual meeting of the European Association of Endoscopic Surgeons, Lisbon, Spain. June 2-6, 2002.