

Enterococcus faecalis Aggravates Pyelonephritis Caused by *Pseudomonas aeruginosa* in Experimental Ascending Mixed Urinary Tract Infection in Mice

NOBORU TSUCHIMORI,^{1*} RYOGO HAYASHI,¹ AKIO SHINO,²
TOSHIYUKI YAMAZAKI,³ AND KENJI OKONOJI¹

Pharmaceutical Research Laboratories III,¹ Drug Safety Research Laboratories,² and
Research Support Center,³ Takeda Chemical Industries, Ltd.,
Yodogawa-ku, Osaka, Japan

Received 11 March 1994/Returned for modification 16 June 1994/Accepted 28 July 1994

Mixed urinary tract infection was caused by simultaneous inoculation of 10^4 CFU each of *Enterococcus faecalis* TN2005 and *Pseudomonas aeruginosa* P9 into the bladders of CBA/J mice. Both organisms proliferated in the kidneys, and viable cell counts of *E. faecalis* TN2005 reached a peak level of 4.1×10^5 CFU per pair of kidneys within the first 24 h, while *P. aeruginosa* P9 counts increased more slowly. The number of *P. aeruginosa* P9 cells peaked at 8.3×10^6 CFU per pair of kidneys 5 days after infection. Five days after mixed infection, infiltration of neutrophils into the renal pelvis and renal medulla was observed. Immunohistochemical staining revealed the presence of *E. faecalis* antigen in the renal medulla. *P. aeruginosa* antigen was detected mainly in the renal pelvis 5 days after infection and in the renal medulla as well as the renal pelvis 14 days after infection. Mixed infection induced pyelonephritis within 5 days after mixed infection, while it was not observed until 14 days after infection with *P. aeruginosa* P9 alone. *P. aeruginosa* P9 inoculated together with *E. faecalis* TN2005 was more resistant to eradication from the kidneys by β -lactam antibiotics than *P. aeruginosa* P9 inoculated alone. These results suggest that *E. faecalis* TN2005 invades the renal medulla first in mixed urinary tract infection and induces histological changes which lead to aggravation of the pyelonephritis caused by *P. aeruginosa* P9.

Enterococcus faecalis is a part of the normal intestinal flora, and it has in the past been considered nonpathogenic. It has been, though, frequently isolated from patients in recent years (2, 10, 12), especially those who are suffering from superinfection with gram-negative rods in the urinary tract (5, 8). This increase in the frequency of isolation is considered to be due to the extensive use of cephalosporins, which are in most cases inactive against *E. faecalis* (1). The pathogenicity of *E. faecalis* in the urinary tract has been proved in animal models (4, 6, 11, 15, 18), but little is known about its role in the course of establishment of mixed urinary tract infection. In order to investigate the influence of *E. faecalis* on the formation of mixed urinary tract infection, we established a mouse model of ascending mixed urinary tract infection using *E. faecalis* and *Pseudomonas aeruginosa*. *P. aeruginosa* is one of the major pathogens of urinary tract infections in humans (17) and is most commonly isolated with *E. faecalis* (5, 8). We report here the role of *E. faecalis* in the establishment of mixed urinary tract infection on the basis of histopathological changes in the kidneys. Therapeutic effects of some β -lactam antibiotics are also reported.

MATERIALS AND METHODS

Mice. Four-week old female CBA/J mice were obtained from Charles River Japan, Inc. All mice were caged in groups

of 5 and given food and water ad libitum. Five-week old mice weighing 18 to 20 g were used for infection.

Microorganisms. *P. aeruginosa* P9 is a strain which is used for the urinary tract infection model established in our laboratory (14). This strain is hemolytic and produces protease and elastase but does not produce lipase and exotoxin A. It was grown on a Trypticase soy agar (TSA; BBL Microbiology Systems, Cockeysville, Md.) plate for 20 hr at 37°C. Cells were scraped, suspended in Trypticase soy broth (TSB; BBL Microbiology Systems), collected by centrifugation at $5,000 \times g$ for

TABLE 1. Influence of *E. faecalis* TN2005 inoculum size on experimental mixed urinary tract infection with *P. aeruginosa* P9

<i>E. faecalis</i> TN2005 inoculum size (CFU/mouse) ^a	No. of mice surviving (n = 5)	Bacterial recovery from kidneys ^b		No. of bacteria in kidneys (log CFU/pair of kidneys; mean \pm SD) ^c	
		<i>E. faecalis</i>	<i>P. aeruginosa</i>	<i>E. faecalis</i>	<i>P. aeruginosa</i>
10^3	5	5/5	4/5	2.54 ± 0.65	5.17 ± 2.04
10^4	5	5/5	5/5	4.08 ± 1.33	6.62 ± 0.85
10^5	4	4/4	4/4	5.22 ± 1.71	6.11 ± 1.32
10^6	5	5/5	3/5	5.65 ± 0.57	4.76 ± 2.42
10^7	5	5/5	5/5	7.04 ± 0.82	5.77 ± 0.38

^a Fifty microliters of bacterial suspension containing 10^3 to 10^7 CFU of *E. faecalis* TN2005 and 10^4 CFU of *P. aeruginosa* P9 was inoculated transurethrally.

^b Number of mice from whose kidneys bacteria were recovered/number of mice surviving.

^c Seven days after inoculation, the kidneys of surviving mice were homogenized in 4 ml of TSB. The homogenate was serially 10-fold diluted with TSB, and 0.1 ml of the sample was inoculated onto SF and NAC agar plates. Bacterial counts less than the detection limit (40 CFU per pair of kidneys) were regarded as 40 CFU to calculate the means.

* Corresponding author. Mailing address: Pharmaceutical Research Laboratories III, Takeda Chemical Industries, Ltd., 2-17-85 Jusohonmachi, Yodogawa-ku, Osaka 532, Japan. Phone: (06) 300-6836. Fax: (06) 300-6206.

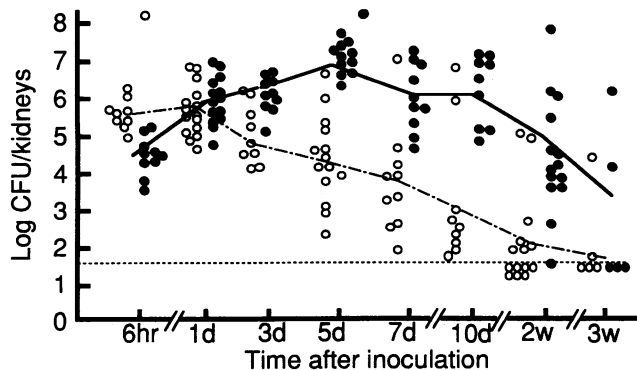


FIG. 1. Viable cell counts of *E. faecalis* TN2005 and *P. aeruginosa* P9 in the kidneys of mice after mixed urinary tract infection. Mice were transurethraly infected with 10^4 CFU of *E. faecalis* TN2005 and 10^4 CFU of *P. aeruginosa* P9. The kidneys were homogenized in TSB, and viable cell counts in the homogenates (per pair of kidneys) were determined as described in Materials and Methods. ○, *E. faecalis* TN2005; ●, *P. aeruginosa* P9. A dotted line indicates the limit of detection.

20 min at 20°C, suspended in TSB containing 15% glycerol, and stored at -80°C until use. The suspension, 5.7×10^9 CFU of bacteria per ml, was thawed at room temperature and diluted with TSB before being used for inoculation. When 10^4 CFU of *P. aeruginosa* P9 was inoculated alone, the survival rate was 100%, and the organism was recovered from the kidneys of all mice. Some mice died when 10^5 CFU or more of *P. aeruginosa* P9 was inoculated. Therefore, the inoculum size of *P. aeruginosa* P9 was fixed at 10^4 CFU per mouse in this study.

E. faecalis TN2005 is a nonhemolytic clinical isolate which was isolated in 1985 and was identified as *E. faecalis* type 2 by the API STREPT 20 test system (API, Montalieu-Vercieu, France). This strain was selected as a test organism from among six *E. faecalis* strains which could colonize in the kidneys of mice without decreasing the recovery of simultaneously inoculated *P. aeruginosa* P9, since it was recovered at higher rates; many colonies were formed on the plates imprinted with sections of the kidneys of mice that were infected with *E. faecalis* TN2005. In analytical experiments using *E. faecalis* TN2005, inocula were prepared by the same method as that described above for *P. aeruginosa* P9. The viable cell counts of *E. faecalis* TN2005 suspensions were 2.6×10^{10} CFU/ml.

Urinary tract infection. Infection was induced as described by Nishi and Tsuchiya (14). Briefly, mice were anesthetized by intraperitoneal administration of 50 mg of sodium pentobarbital (Nembutal; Abbott Laboratories, North Chicago, Ill.) per kg and were forced to void urine by gently compressing the bladder through the external abdominal wall. With a tuberculin syringe and a 23-gauge needle which had been blunted, 0.05 ml of a bacterial suspension was transurethraly inoculated into the bladder. Immediately after inoculation, the external urethral meatus was clamped for 6 h.

Detection of *E. faecalis* and *P. aeruginosa*. For selective growth of *E. faecalis* and *P. aeruginosa*, SF agar containing 0.05% sodium azide (Eiken Chemical, Tokyo, Japan) and NAC agar containing 0.0015% nalidixic acid (Eiken Chemical), respectively, were used.

For the qualitative detection of organisms in the kidneys, mice were killed by bleeding from the axillary arteries and veins under ether anesthesia, and the kidneys were removed

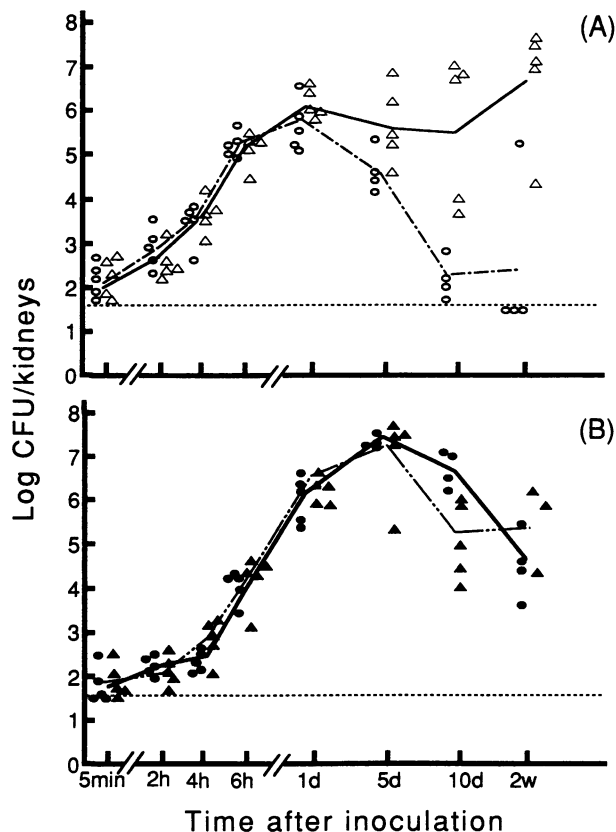


FIG. 2. Viable cell counts of *E. faecalis* TN2005 and *P. aeruginosa* P9 in the kidneys of mice with single or mixed urinary tract infections. Mice were transurethraly infected with 10^4 CFU of *E. faecalis* TN2005 and of *P. aeruginosa* P9 individually or simultaneously. (A) Viable cell counts of *E. faecalis* TN2005; (B) viable cell counts of *P. aeruginosa* P9; counts are per pair of kidneys. Δ and ▲, single infection; ○ and ●, mixed infection. Dotted lines indicate the limits of detection.

aseptically. Sections of the kidneys were imprinted onto the selection plates. The plates were incubated at 37°C for 48 h.

For quantitative detection, the kidneys were homogenized in 4 ml of TSB with a Teflon tissue homogenizer. Samples of the tissue homogenate were serially 10-fold diluted with TSB, and 0.1 ml of the sample was inoculated on the selection plates. Colonies were counted after 48 h of incubation at 37°C.

Histopathological examinations. The kidneys were fixed in Bouin's fluids and embedded in paraffin. Thin sections were made, stained with hematoxylin and eosin, and examined with a light microscope. The severity of renal pathology was expressed by a semiquantitative score of kidney changes by using the following criteria: 0, no abnormality; 1+, mild pyelitis with infiltration of a small amount of neutrophils in the renal pelvis; 2+, severe pyelitis with infiltration of moderate amount of neutrophils in the renal pelvis and renal cortex adjacent to the pelvis and thickening of the pelvic mucosa; 3+, pyelonephritis with infiltration of neutrophils in the renal pelvis and the renal medulla and thickening of pelvic mucosa; 4+, severe pyelonephritis with abscess formation. Renal scores were compared by the Mann-Whitney U test.

For immunohistochemical detection of bacterial antigen in the tissues, kidneys were fixed in ice-cold acetone and embedded in paraffin. Thin sections were stained with immune serum of rabbits immunized with heat-killed *E. faecalis* TN2005 or *P.*

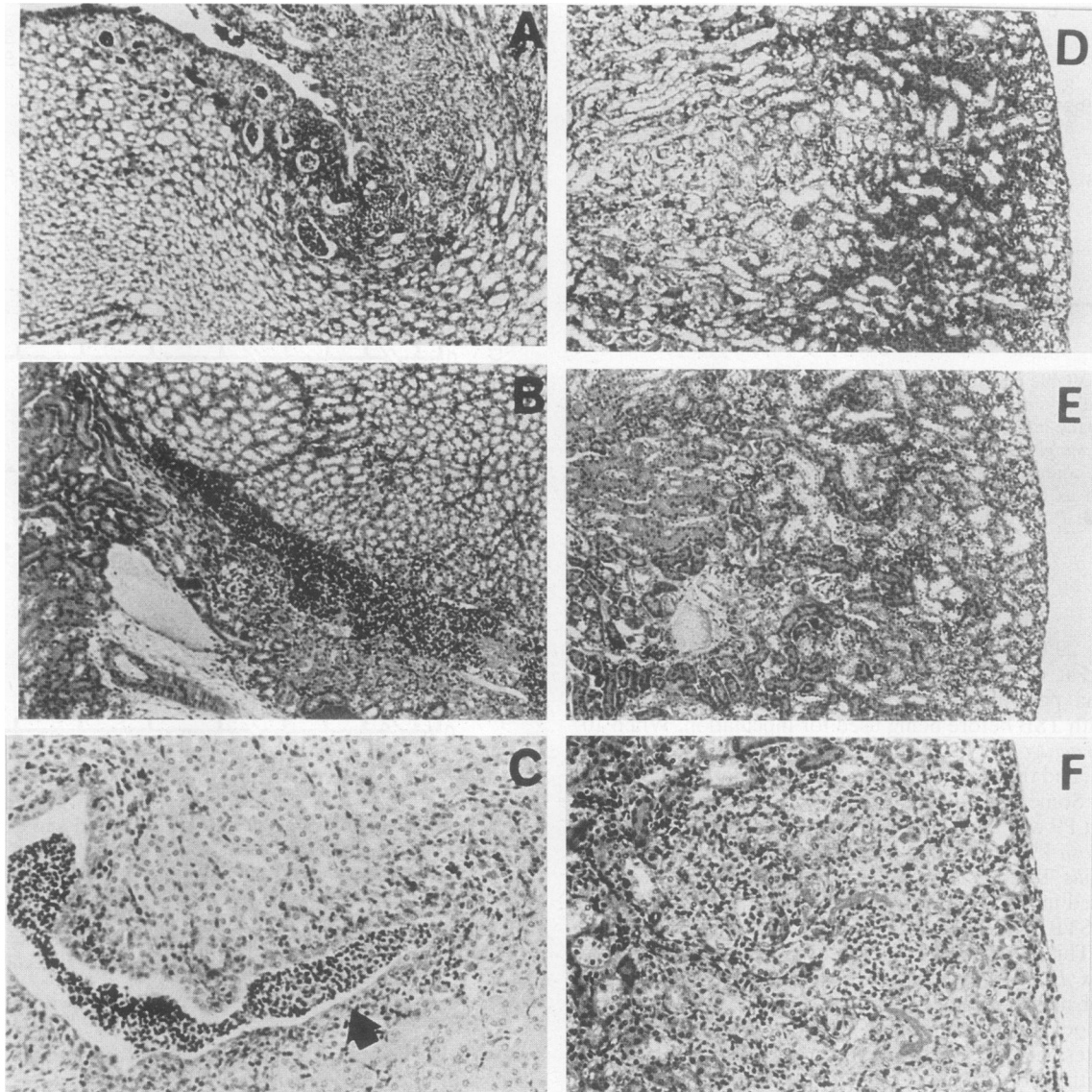


FIG. 3. Light micrographs of the kidneys of mice 5 days after infection. Mice were transurethrally inoculated with 10^4 CFU of *E. faecalis* TN2005 (A and D), 10^4 CFU of *P. aeruginosa* P9 (B and E), or 10^4 CFU each of *E. faecalis* TN2005 and *P. aeruginosa* P9 (C and F). Kidney sections were stained with hematoxylin and eosin. (A to C) Medulla; (D to F) cortex. Magnifications: $\times 85$ (A), $\times 85$ (B), $\times 170$ (C), $\times 85$ (D), $\times 85$ (E), and $\times 170$ (F). The arrow indicates thickening of the mucosal epithelium.

aeruginosa P9, with a Vectastain avidin-biotin peroxidase complex kit (Vector Laboratories, Burlingame, Calif.) as previously described by Hsu et al. (3).

Antibiotic treatment. Antibiotic was administered subcutaneously six times a day at 2-h intervals for 3 days starting the day after infection. The bacterial cell counts in the kidneys were determined 4 days after infection.

Antibiotics. Cefozopran (9) was synthesized in the Pharmaceutical Research Division of Takeda Chemical Industries, Ltd. Ceftazidime (Nippon Glaxo Co., Ltd., Tokyo, Japan) and ampicillin (Meiji-Seika, Tokyo, Japan) were obtained commercially. MICs were determined by an agar dilution method with an inoculum of ca. 10^4 CFU.

RESULTS

Effect of inoculum size. We examined the effect of the dose of *E. faecalis* TN2005 inoculated simultaneously with *P. aeruginosa* P9 on the recovery of the organisms from the kidneys 7 days after infection. As shown in Table 1, recoveries of *E. faecalis* TN2005 were proportional to the inoculum size. When 10^4 CFU of *E. faecalis* TN2005 was inoculated, all mice survived with positive bacterial recovery, and cell counts of *E. faecalis* and *P. aeruginosa* were 1.2×10^4 and 4.2×10^6 CFU per pair of kidneys, respectively. One mouse died when 10^5 CFU of *E. faecalis* TN2005 was inoculated, but the death might have been due to an accident since larger amounts of *E. faecalis* TN2005 caused no death. In order to compare the

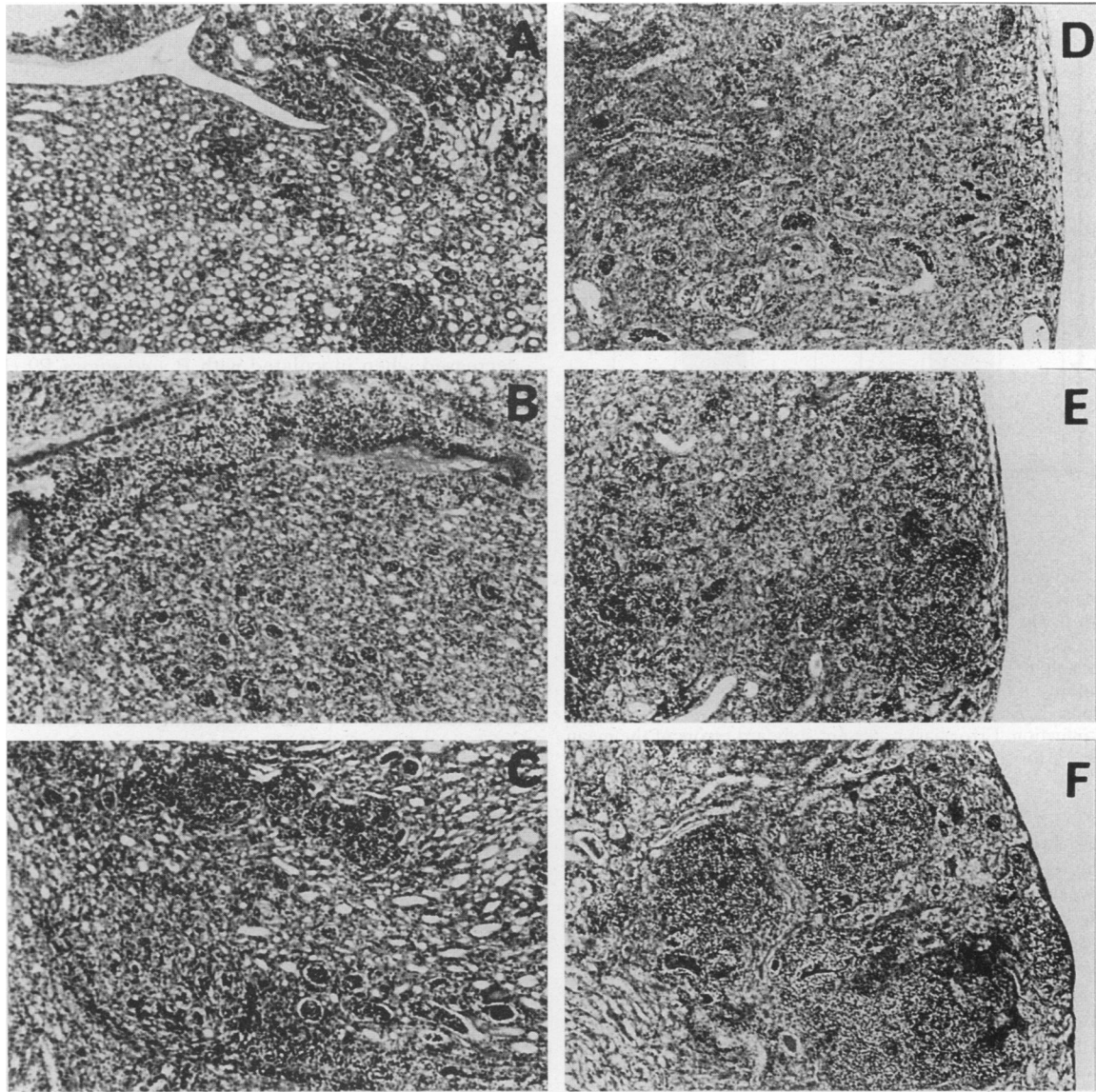


FIG. 4. Light micrographs of the kidneys of mice 14 days after infection. Mice were transurethally inoculated with 10^4 CFU of *E. faecalis* TN2005 (A and D), 10^4 CFU of *P. aeruginosa* P9 (B and E), or 10^4 CFU each of *E. faecalis* TN2005 and *P. aeruginosa* P9 (C and F). Kidney sections were stained with hematoxylin and eosin. (A to C) Medulla (magnification, $\times 85$); (D to F) cortex (magnification, $\times 85$).

pathogenicity of *E. faecalis* and *P. aeruginosa*, 10^4 CFU of *E. faecalis* TN2005 was inoculated together with 10^4 CFU of *P. aeruginosa* P9 in the following experiments.

Time course of viable cell counts in the kidneys. Changes in the bacterial populations in the kidneys of mice with mixed urinary tract infections were examined. Mice were transurethally inoculated with 10^4 CFU of *E. faecalis* TN2005 together with 10^4 CFU of *P. aeruginosa* P9. *E. faecalis* TN2005 counts increased rapidly in the kidneys, and viable cell counts reached a peak level of 4.1×10^5 CFU per pair of kidneys within the first 24 h and then began to decrease (Fig. 1). The cell count of *E. faecalis* TN2005 was 5.5×10^3 CFU per pair of kidneys 7 days after infection, and the organism had been cleared from half of the mice 14 days after infection. *P. aeruginosa* P9 proliferated more slowly, reached cell counts of 8.3×10^6 CFU per pair of kidneys 5 days after infection, and then decreased.

The cell count at 2 weeks after infection was more than 10^4 CFU per pair of kidneys.

Changes in the bacterial populations in the kidneys of mice inoculated transurethally with *E. faecalis* TN2005 or *P. aeruginosa* P9 or both organisms simultaneously were compared (Fig. 2). Cell counts of both *E. faecalis* TN2005 and *P. aeruginosa* P9 were about 10^2 CFU per pair of kidneys just after inoculation. *E. faecalis* TN2005 proliferated rapidly in the kidneys and reached peak levels of 10^5 to 10^6 CFU per pair of kidneys within the first 24 h. In contrast to mixed infection, the number of viable cells of *E. faecalis* TN2005 remained at the peak level for 2 weeks when these were inoculated alone. The time course of *P. aeruginosa* P9 cell counts was not affected by the presence of *E. faecalis* TN2005.

Histopathological analysis of the kidney. Histopathological changes in the kidneys are shown in Fig. 3 and 4, and the

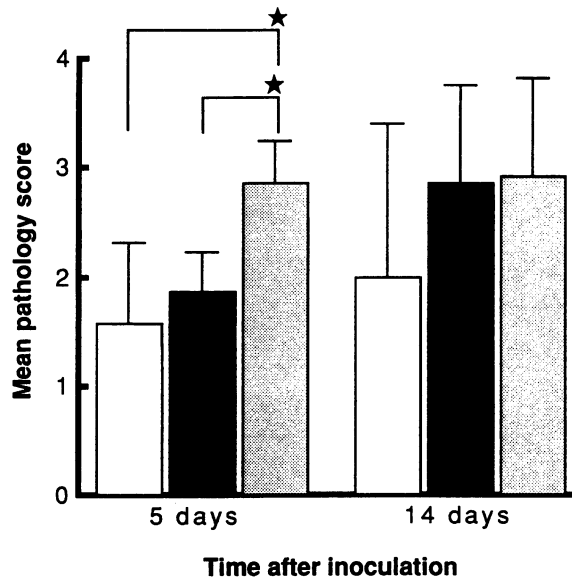


FIG. 5. Severity of histopathological lesions in the kidneys of mice 5 and 14 days after infection. Mice were transurethrally infected with 10^4 CFU of *E. faecalis* TN2005 and of *P. aeruginosa* P9 individually or simultaneously. The severity of histopathological lesions was determined from light micrographs of the kidneys. The criteria for the semiquantitative scores of renal pathology are described in Materials and Methods. □, *E. faecalis* TN2005 alone; ■, *P. aeruginosa* P9 alone; ▨, mixed infection. Error bars represent standard errors of the mean ($n = 7$). ★, P (for the bracketed pair) < 0.01 .

results are summarized in Fig. 5. Five days after infection, infiltration of neutrophils into the calyceal fornix of the renal medulla was observed when *E. faecalis* TN2005 was inoculated alone (Fig. 3A). *P. aeruginosa* P9 alone induced acute infiltration of neutrophils into the renal pelvis (Fig. 3B). Neither single infection induced histological changes in the renal cortex (Fig. 3D and E). In the case of mixed infection, infiltration of neutrophils into the calyceal fornix of the renal medulla and the renal pelvis was observed together with thickening of the mucosal membrane (Fig. 3C). In addition, slight infiltration of neutrophils into the tubules of the renal cortices was observed in some of these mice (Fig. 3F). Lesions in the kidneys were significantly ($P < 0.01$, Mann-Whitney U test) more severe in mice inoculated with *E. faecalis* TN2005 together with *P. aeruginosa* P9 than in mice inoculated with them individually (Fig. 5).

Fourteen days after inoculation, infiltration of neutrophils into tubules of the renal medullas and the renal pelvises become more prominent (Fig. 4C), and abscesses were seen in the renal cortices (Fig. 4F) in some mice with mixed infections. In mice infected with *E. faecalis* TN2005 alone, slight infiltration of neutrophils into the renal calyceal fornices of the renal medullas was observed (Fig. 4A), and some mice showed infiltration of neutrophils into tubules of the renal cortices (Fig. 4D). Histological changes caused by *P. aeruginosa* P9 alone (Fig. 4B) were similar to those observed in the mice with mixed infections. Abscesses were formed in the renal cortices in some mice (Fig. 4E). There were no significant differences in lesions in the kidneys in the mice infected with both bacteria and those infected with *P. aeruginosa* P9 alone (Fig. 5).

Localization of *E. faecalis* and *P. aeruginosa* antigens in the kidneys. *E. faecalis* and *P. aeruginosa* antigens in the kidneys were detected by immunohistochemical staining. Figure 6

shows the distribution of *E. faecalis* and *P. aeruginosa* antigens in renal sections from mice sacrificed 5 and 14 days after infection. Five days after single and mixed infection, *E. faecalis* antigen was detected in the renal medullas (Fig. 6A and B), whereas *P. aeruginosa* antigen was detected mainly in the renal pelvises of mice (Fig. 6C and D). In the renal cortices, both *E. faecalis* and *P. aeruginosa* antigens were detected 5 days after mixed infection (data not shown).

Fourteen days after infection, *E. faecalis* antigen was detected in the renal medullas of mice infected with *E. faecalis* alone (Fig. 6E) but was not detected in the kidneys of mice with mixed infections (Fig. 6F). These results are consistent with the viable cell counts of *E. faecalis* in the kidneys, which remained at a high level for 2 weeks when inoculated alone but decreased when inoculated with *P. aeruginosa* P9 (Fig. 2). *P. aeruginosa* antigen was detected not only in the renal pelvises but also in the renal medullas (Fig. 6G and H). *P. aeruginosa* antigen in the renal medullas was dispersed in mice with single infections (Fig. 6G) and focused in mice with mixed infections (Fig. 6H).

Eradication of microorganisms from the kidneys. We tried to eradicate the microorganisms from the kidneys of mice with single or mixed infections by administering ceftazopran, ceftazidime, or ampicillin. Antimicrobial agents were administered for 3 days starting the day after infection, and bacterial counts in the kidneys were determined 16 h after final administration. The plasma elimination half-lives of ceftazopran, ceftazidime, and ampicillin after administration to mice have been reported to be less than 1 h (7, 16), suggesting the absence of antibiotic contamination of the kidney homogenate at the time of assay. As shown in Fig. 7, ceftazopran and ceftazidime were effective in eradicating *P. aeruginosa* P9 from the kidneys in both single and mixed infections, though ceftazidime was slightly less effective against mixed infections than against single infections. Ampicillin was somewhat effective in eradicating *P. aeruginosa* P9 inoculated alone in spite of its weak in vitro activity. *P. aeruginosa* P9 inoculated with *E. faecalis* TN2005 was not eradicated by ampicillin. Viable cell counts of *E. faecalis* TN2005 were reduced significantly by ceftazopran and ampicillin but not by ceftazidime in either single or mixed infections (results will be published elsewhere).

DISCUSSION

When 10-fold-diluted cultures of eight *E. faecalis* strains were individually inoculated into the bladders of mice together with 10^4 CFU of *P. aeruginosa* P9, six of the *E. faecalis* strains could be recovered from the kidneys of all surviving mice (data not shown). When inoculated together with *P. aeruginosa* P9, *E. faecalis* TN2005 could be recovered from the kidneys of all infected mice even when the inoculum size was reduced to 10^3 CFU per mouse. These results indicate that the ability of *E. faecalis* to colonize the kidneys of mice is quite potent when inoculated into the bladder together with *P. aeruginosa* P9.

Six hours after the inoculation of 10^4 CFU each of *E. faecalis* TN2005 and *P. aeruginosa* P9, large numbers of both organisms were recovered from the bladder, kidneys, and urine. Small numbers of *E. faecalis* TN2005 and *P. aeruginosa* P9 were detected in the blood, but only 6 h postinoculation (data not shown). In a previous study, it was observed that external urethral obstruction after intrabladder inoculation induced vesicourethral reflux of the inoculum (13). Therefore, the inoculated organisms are considered to have reached the pelvis of the kidney via the ureter, though the possibility of blood-borne spread cannot be ruled out completely.

In the early stage of mixed infection, *E. faecalis* TN2005

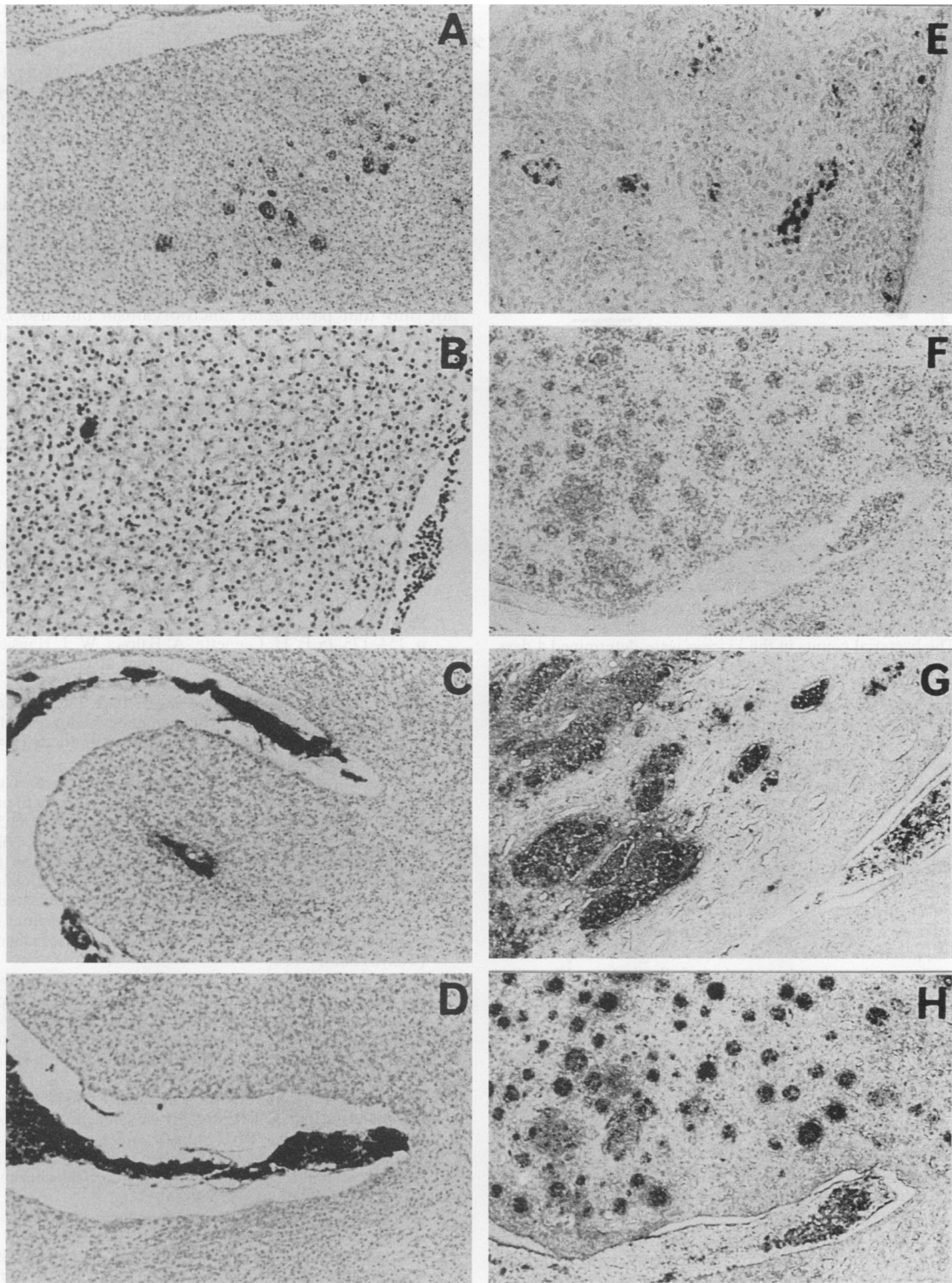


FIG. 6. Immunohistochemical staining of *E. faecalis* TN2005 and *P. aeruginosa* P9 antigens in sections of the kidneys of mice with urinary tract infections. Mice were transurethraally inoculated with 10^4 CFU of *E. faecalis* TN2005 (A and E), 10^4 CFU of *P. aeruginosa* P9 (C and G), or 10^4 CFU each of *E. faecalis* TN2005 and *P. aeruginosa* P9 (B, D, F, and H). Kidneys were obtained 5 days (A to D) or 14 days (E to H) after infection. Renal sections were stained immunohistochemically by use of anti-*E. faecalis* serum (A, B, E, and F) or anti-*P. aeruginosa* serum (C, D, G, and H). (A and C to H) Magnification, $\times 85$; (B) magnification, $\times 170$.

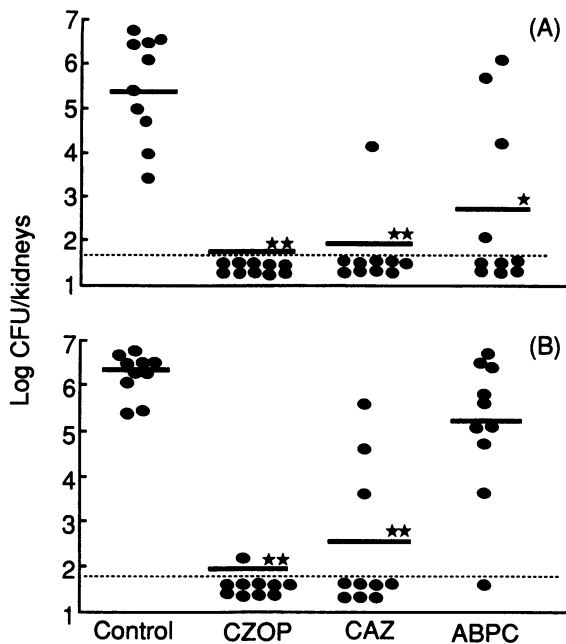


FIG. 7. Eradication of *P. aeruginosa* P9 cells from the kidneys by ceftazidime (CZOP), ceftazidime (CAZ), and ampicillin (ABPC). Mice were transurethrally inoculated with 10^4 CFU of *P. aeruginosa* P9 (A) or 10^4 CFU each of *E. faecalis* TN2005 and *P. aeruginosa* P9 (B). Each antibiotic was administered subcutaneously at a dose of 100 mg/kg of body weight six times a day for 3 days starting the day after infection. The bacterial counts in the kidneys were determined 4 days after infection. The MICs of ceftazidime, ceftazidime, and ampicillin against *P. aeruginosa* P9 were 0.78, 1.56, and >800 $\mu\text{g/ml}$, respectively, and those against *E. faecalis* TN2005 were 3.13, 6.25, and 0.78 $\mu\text{g/ml}$, respectively. Circles indicate bacterial counts as log CFU per pair of kidneys in each mouse, and horizontal bars indicate median values. Dotted lines indicate the limits of detection. \star , $P < 0.01$; $\star\star$, $P < 0.001$ versus control (Mann-Whitney U test).

proliferated rapidly in the kidneys. Slowly proliferating *P. aeruginosa* P9 seemed to displace *E. faecalis* TN2005 in the renal medulla and caused acute pyelonephritis 14 days after infection. These results suggest that, in mixed urinary tract infection, *E. faecalis* TN2005, which has a high affinity for the renal parenchyma, invades the renal medulla first, proliferates, and induces some changes which facilitate penetration and localization of *P. aeruginosa* P9 in the renal medulla leading to aggravated pyelonephritis.

Histopathological studies support the above idea. Five days after infection, *P. aeruginosa* P9 inoculated alone induced only pyelitis but *P. aeruginosa* P9 inoculated with *E. faecalis* TN2005 induced pyelonephritis, even though *E. faecalis* TN2005 showed only weak pathogenicity when inoculated alone. These results suggest that *E. faecalis* TN2005 accelerates the appearance of pyelonephritis caused by *P. aeruginosa* P9 in mixed urinary tract infection.

P. aeruginosa P9 in mixed infections was more resistant to eradication from the kidneys by treatment with β -lactam antibiotics than that in single infections. Yamasaki et al. also reported that *Proteus mirabilis* which was inoculated with *E. faecalis* into the mouse urinary tract was more resistant to treatment with β -lactam antibiotics than that inoculated alone (18). These findings may also indicate that *E. faecalis*, when causing mixed infection with gram-negative rods, aggravates urinary tract infections and makes them more difficult to treat.

The alternative conclusion that *P. aeruginosa* augments the pathogenicity of *E. faecalis* may be ruled out because *E. faecalis* TN2005 was eradicated from the kidneys within 14 days after mixed inoculation, while it was still present in the kidneys 14 days after infection when inoculated alone. Eradication of *E. faecalis* TN2005 from the kidneys is considered to be due to the massive neutrophil infiltration induced by *P. aeruginosa* P9 in mixed infections; *E. faecalis* TN2005 alone induced only slight infiltration of neutrophils.

Since *E. faecalis* is only weakly pathogenic, it has not attracted much attention clinically in spite of its resistance to most cephalosporins. However, we have shown here that, in a mixed urinary tract infection model, *E. faecalis* aggravated the pyelonephritis caused by *P. aeruginosa*. When *E. faecalis* is isolated with pathogenic microorganisms from urine samples, not only that pathogenic microorganism but also *E. faecalis* should be eradicated by treatment with appropriate antimicrobial agents to prevent aggravation of the infection.

ACKNOWLEDGMENT

We thank Akira Imada for his helpful suggestions in the preparation of the manuscript.

REFERENCES

- Etienne, J., M. Coulet, Y. Brun, J. Blanchon, F. Demoux, and J. Fleurette. 1988. Susceptibilities of streptococcal strains associated with infective endocarditis to nine antibiotics. *Chemotherapy (Basel)* 34:113-116.
- Facklam, R. R., and R. B. Carey. 1985. Streptococci and aerococci, p. 154-175. In E. H. Lennette, A. Balows, W. J. Hausler, Jr., and H. J. Shadomy (ed.), *Manual of clinical microbiology*, 4th ed. American Society for Microbiology, Washington, D.C.
- Hsu, S. M., L. Raine, and H. Fanger. 1981. Use of avidin-biotin-peroxidase complex (ABC) in immunoperoxidase techniques: a comparison between ABC and unlabelled antibody (PAP) procedures. *J. Histochem. Cytochem.* 29:577-580.
- Kalmanson, G. M., S. C. Sommers, and L. B. Guze. 1965. Pyelonephritis. Experimental ascending infection with progression of lesions in the absence of bacteria. *Arch. Pathol.* 80:529-516.
- Kaneko, H., K. Kitahara, T. Tominaga, H. Kishi, T. Nijima, and S. Iwamoto. 1984. Clinical studies of *Streptococcus faecalis* in urinary tract infections. *Chemotherapy (Tokyo)* 32:685-691.
- Kawabata, G., S. Arakawa, and S. Kamidono. 1988. Studies on the pathogenicity of *Enterococcus faecalis*: experimental ascending pyelonephritis in non-treated and diabetic mice. *Chemotherapy (Tokyo)* 36:617-631.
- Kita, Y., T. Yamazaki, and A. Imada. 1992. Comparative pharmacokinetics of SCE-2787 and related antibiotics in experimental animals. *Antimicrob. Agents Chemother.* 36:2481-2486.
- Kumazawa, J. 1985. Clinical superinfection in complicated urinary tract infections: therapy with broad-spectrum beta-lactam antibiotics in urology. *Infection* 13:96-99.
- Miyake, A., Y. Yoshimura, M. Yamaoka, T. Nishimura, N. Hashimoto, and A. Imada. 1992. Studies on condensed-heterocyclic azolium cephalosporins IV: synthesis and antibacterial activity of 7 β -[2-(5-amino-1,2,4-thiadiazol-3-yl)-2(z)-alkoxyimonoacetamido]-3-(condensed-heterocyclic azolium)methyl cephalosporins including SCE-2787. *J. Antibiot.* 45:709-720.
- Moellering, R. C., Jr. 1992. Emergence of *Enterococcus* as a significant pathogen. *Clin. Infect. Dis.* 14:1173-1178.
- Montgomerie, J. Z., G. M. Kalmanson, and L. B. Guze. 1977. Virulence of enterococci in experimental pyelonephritis. *Urol. Res.* 5:99-102.
- Musher, D. M. 1985. *Streptococcus faecalis* and other group D streptococci, p. 1152-1155. In G. L. Mandell, R. G. Douglas, and J. E. Bennett (ed.), *Principles and practice of infectious diseases*, 2nd ed. John Wiley & Sons, Inc., New York.
- Nakao, M., K. Kondo, A. Imada, and K. Tsuchiya. 1985. An electron microscopic study of pathogenesis of urinary tract infec-

- tion caused by *Pseudomonas aeruginosa* P9 in mice. Zentralbl. Bakteriologie Mikrobiologie Hygiene Ser. A **260**:369–378.
14. Nishi, T., and K. Tsuchiya. 1978. Experimental urinary tract infection with *Pseudomonas aeruginosa* in mice. *Infect. Immun.* **22**:508–515.
 15. Pichon, H., R. Glasscock, and G. M. Kalmanson. 1984. Experimental pyelonephritis: the effect of T-cell deficiency on the course of hematogenous enterococcal pyelonephritis in the mouse. *Am. J. Pathol.* **115**:25–30.
 16. Sugawara, S., I. Igarashi, and M. Tajima. 1974. Antibacterial activities of pivampicillin, a new orally active ampicillin ester. *Chemotherapy (Tokyo)* **22**:329–340.
 17. Warren, J. W., J. H. Tenny, J. M. Hoopes, H. L. Muncie, and W. C. Anthony. 1982. A prospective microbiologic study of bacteriuria in patients with chronic indwelling urethral catheters. *J. Infect. Dis.* **146**:719–723.
 18. Yamasaki, H., S. Arakawa, and S. Kamidono. 1991. Basic studies on the pathogenicity of *Enterococcus faecalis*: polymicrobial infection with *Enterococcus faecalis* and *Proteus mirabilis* in experimental ascending pyelonephritis models. *Chemotherapy (Tokyo)* **39**: 651–662.