

ADVANCES IN ENDOSCOPY

Current Developments in Diagnostic and Therapeutic Endoscopy

Section Editor: John Baillie, MB ChB, FRCP

Management of Benign Esophageal Strictures

Todd H. Baron, MD
Professor of Medicine
Mayo Clinic
Rochester, Minnesota

G&H What are the most common causes of benign esophageal strictures?

TB In the past, peptic strictures (ie, strictures related to reflux) of the distal esophagus were fairly common; however, such strictures are no longer prevalent, most likely because antireflux therapy has become very effective and is widely used. Currently, the most common causes of benign strictures of the esophagus are anastomotic strictures, which can develop following resection of the distal esophagus and proximal stomach for treatment of esophageal cancer or Barrett esophagus, and radiation-induced strictures, which frequently develop following treatment of head and neck cancer. In the latter patients, the strictures are located very proximally in the esophagus. Other causes include aggressive treatments for Barrett esophagus (such as photodynamic therapy) and nasogastric tube injury.

G&H Which of these strictures is most technically difficult to manage?

TB In my experience, strictures following radiation therapy for head and neck cancer are the most difficult to manage because they are refractory to dilation; in addition, radiation affects not only the lumen of the esophagus but the overall ability to swallow because of damage to the swallowing muscles, along with scarring of the cricopharyngeal muscle and hypopharynx. These strictures tend to be extremely difficult to dilate, and even when dilation is effective, many patients still cannot swallow because of difficulties with swallowing coordination.

The other reason that these strictures are more difficult to manage is their location. Because they are found

very high in the esophagus, there is not much room, if any, in which to place a stent above the stricture; in some patients, the stent must be placed above the cricopharyngeus, which is generally considered a contraindication to stent placement.

In addition, when stents are placed very proximally, patients often feel a foreign body sensation as well as pain.

G&H What is the standard treatment for benign esophageal strictures?

TB First-line treatment of benign esophageal strictures consists of dilation via a balloon or bougie. If the strictures are refractory to dilation and corticosteroid injection, the next option is often expandable stent placement. Stents are never used as a first-line treatment for benign strictures; they are reserved for patients who have failed previous therapy (usually multiple sessions of dilation). In refractory strictures, dilation does not open the stricture at all, or the stricture opens but then closes within a short period of time. The goal of stent placement is to hold the stricture open for prolonged periods of time, causing the stricture, or the tissue around it, to remodel so that the stricture does not recur when the stent is removed.

G&H What are the advantages and disadvantages of using bougie dilators compared to dilating balloons during esophageal stricture dilation?

TB Currently, there are no good data to support the superiority of one of these methods over the other; their use depends mostly upon personal preference. There are advantages and disadvantages to each technique. I tend to use bougie dilators (tapered dilators over a guidewire) for refractory strictures because they involve 2 mechanisms of dilation—a shearing force and a radial force—whereas balloon dilation involves only a radial force. Another advantage is that passage of a rigid dilator through a stricture proves that dilation has been achieved at least up to the diameter of the dilator; in contrast, with a balloon, it may not be possible, even at maximum inflation, to dilate the stricture to the maximum diameter of a rigid dilator. Also, over-the-wire dilators are reusable and, thus, associated with a lower cost.

On the other hand, balloon dilators can pass through a stricture without requiring removal of the endoscope and are mounted on small-diameter catheters, which allows passage through very tight strictures, where bougie dilators may not be able to pass.

G&H How are the sizes of dilators and balloons measured?

TB The diameters of balloons are measured in millimeters, whereas some bougie dilators are measured using the “French” gauge system, which has been used for hundreds of years. French gauge is a measure of circumference, which is $\pi \times$ diameter (in millimeters). French gauge is sometimes referred to as Charriere gauge, after the French surgical instrument maker who invented it. Three French equal 1 millimeter; thus, a 20-mm dilator equals 60 French. Bougie dilators range in size from 5 mm to 20 mm; esophageal dilating balloons range from 6 mm to 20 mm, though the catheters upon which they are mounted may be as small as 5 French (approximately 2 mm). In addition, balloons are available with 3 inflation sizes (eg, 10, 11, and 12 mm; or 14, 15, and 16 mm, depending upon inflation pressure).

G&H What is “the rule of three” for esophageal dilation?

TB The rule of three is applied only to tapered, over-the-wire dilators; there is no equivalent in balloon dilation. The idea is to start with a small dilator—a tapered dilator that is approximately the diameter of the stricture—and to move to progressively larger dilators. For example, if I started with a 9-mm dilator, I would next use a 10-, 11-, and 12-mm dilator, and so on, until I feel resistance to the passage of the dilator. The first dilator that causes resistance to passage counts as “one.” The rule of three states that only 2 additional dilators of sequential size should be passed (3 dilators in total). Thus, a physician should not skip dilator sizes (eg, a 10-mm dilator met with resistance should not be immediately followed by a 14-mm dilator).

This sequential rule is designed for safety because skipping the rule of three and going dramatically higher is believed to increase the risk of perforation, though I am unaware of any confirmatory studies. This rule is based upon common sense; in a patient with a 5-mm stricture, it is not reasonable to jump from a 6-mm dilator to a 20-mm dilator, whether using a balloon or an over-the-wire dilator.

However, there are situations where the rule of three can be violated. For example, if I know that a patient has a refractory stricture that was recently dilated to a large diameter of, say, 18 mm (particularly if it is a proximal, radiation-induced stricture) and the patient returns sev-

eral weeks later with a relatively tight, recurrent stricture, I have gone beyond the rule of three in this situation. Given the patient’s history, the patient has proven that the stricture can be safely expanded to a large diameter, in addition to the fact that the surrounding fibrosis is likely protective from a free perforation. The rule of three is more often violated when dilating balloons are used because they are frequently associated with greater than 3-fold dilation of the stricture diameter. On the other hand, a 20-mm balloon should not be used, for example, in a patient with a 2-mm stricture; a more reasonable approach would be to use a 12-mm diameter balloon and then have the patient return for another session using a dilating balloon with a larger diameter.

G&H If a perforation is suspected during dilation of an esophageal stricture, what steps should be taken?

TB Traditional management of this situation has been surgery, though there is increasing experience with nonsurgical management. Management choice depends upon the size and location of the perforation and the timing of recognition. Early recognition and immediate management are the most important factors for diverting secretions from the leak site and avoiding potential contamination of the mediastinum. Nonsurgical options include endoscopic placement of clips to close the perforation, placement of a nasogastric tube to evacuate and divert secretions, and administration of antibiotics. Fully covered, removable, expandable stents have been used for closure of large perforations and should be placed as soon as the perforation is recognized. For very proximal strictures, management may include nasogastric placement. It is important to keep in mind that if leakage consists of only air, it is resorbed as long as the hole closes; air by itself is generally not a cause of morbidity or mortality. If fluid is leaked (ie, secretions), infections can develop. Contrast studies, such as computed tomography and esophagography, can help to guide decision making.

G&H What alternatives to dilation can be used for managing difficult esophageal strictures?

TB Electroincision is an option in select patients with refractory or recurrent esophagogastric anastomotic strictures. The optimal stricture for this procedure is short, shelf-like, and membranous, rather than long and tapered. A needle-knife for endoscopic retrograde cholangiopancreatography is used to make radial incisions into the stricture, usually in 4 quadrants. I prefer to immediately follow with large-diameter balloon dilation (18–20 mm). Data suggest that this treatment option is safe and effective, with results superior to dilation alone.

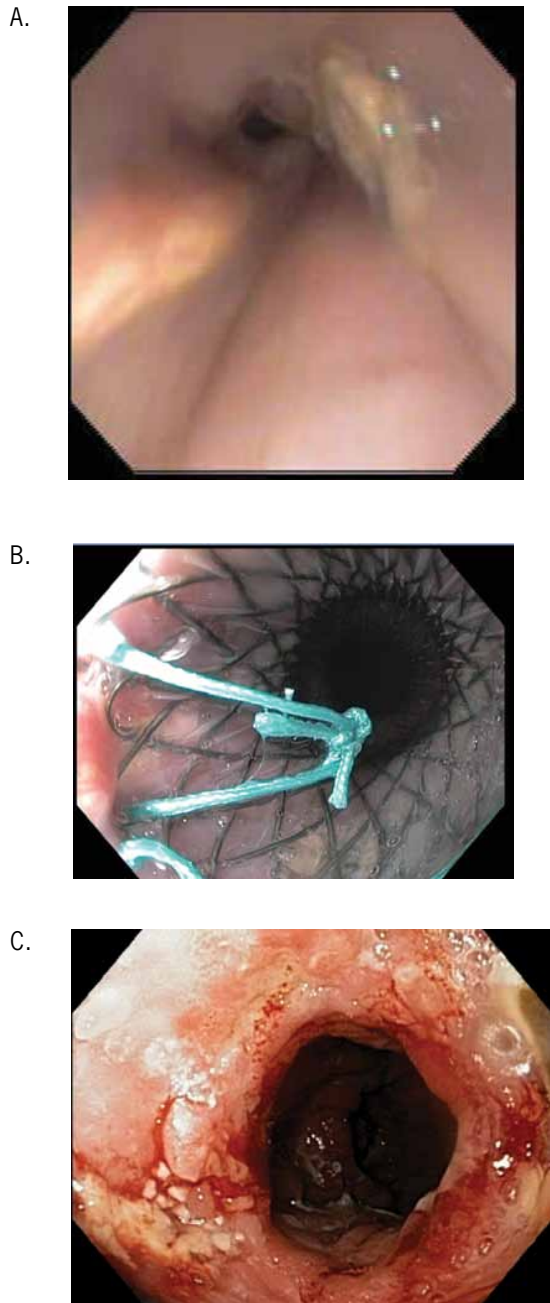


Figure 1. Endoscopic view of an esophagogastric anastomotic stricture (A). A fully covered, expandable, metal stent is placed in the patient (B). Endoscopic view of the area immediately following removal of the stent (C).

G&H What is the role of self-expandable stents in managing difficult esophageal strictures?

TB Currently, no self-expandable metal stents (SEMS) are approved by the US Food and Drug Administration (FDA) for benign esophageal disease. However, a

self-expandable plastic stent is approved for placement and subsequent removal in refractory benign esophageal strictures. This stent requires assembly (loading onto the delivery system), which can be cumbersome but is necessary, as the stent can lose its expansion memory if it remains constrained on the delivery system. Newer, more easily assembled plastic stents are being developed.

Over time, uncovered SEMS bury themselves deep into the esophageal wall and are not removable, creating long-term problems. Fully covered SEMS do not embed into tissue; autopsy studies and surgical resections have demonstrated that the covering of a stent prevents its metal wires from embedding into tissue, ensuring that the stent remains on the surface. Even though these stents are not approved for removability, they are starting to be placed for benign indications, such as refractory strictures, perforations, and postoperative leakage, and then are subsequently removed at an appropriate time (Figure 1).

G&H What were the findings of the study you and your colleagues conducted on stent placement in this patient population?

TB After placing a sizeable number of these metal stents in patients with benign disease, my colleagues and I conducted a retrospective study to determine outcomes. At the time of our study, the stent we tested was the only fully covered stent available. Several other fully covered stents are now commercially available; as these stents are configured differently, they may result in different outcomes than those associated with the stent we used.

There were several important findings in our study. First, all of the stents were removed without any difficulties, and some of these removals were quite delayed after insertion. Second, these stents were covered, which made them easy to remove but also resulted in a high rate of migration. In fact, migration occurred in approximately 35% of cases. No complications were associated with migrations; once the stent migrated, it generally passed into the stomach, where it was subsequently retrieved endoscopically. Unfortunately, stricture recurrence occurred in up to 50% of patients after stent removal.

G&H What complications are associated with stents?

TB Although self-expandable, fully covered, plastic and metal stents are reasonably effective, they are associated with several complications. Insertion complications include airway compromise from compression, aspiration, and complications related to sedation. Transient pain, nausea, and vomiting are not uncommon. As previously mentioned, stents often migrate, as their covering prevents tissue embedding. Although stent covers should

prevent damage, there have been several cases of stricture development at the contact points of the stent ends upon stent removal. Thus, although the original stricture resolves, the ends of the stents may create new strictures. It is unclear whether these new strictures occur because these patients are more susceptible to stricture formation. However, this complication is uncommon. Granulation tissue has also been found in some patients; a benign growth develops around the stent but resolves upon stent removal because the growth was merely an irritation caused by the stent. Some authors have also noted the development of tracheoesophageal fistulas and bleeding from stent-induced ulcers.

G&H Is there a role for steroid injection in the management of difficult esophageal strictures?

TB Prior to the consideration of placing a self-expandable stent, administration of injectable corticosteroids is usually undertaken. However, the literature that is most supportive of this treatment involves strictures related to peptic reflux, which are uncommon. It is unclear whether this treatment is effective in radiation-induced or anastomotic strictures; it is frequently assumed that this treatment works just as well in these patients, but we do not know for sure.

G&H When should a patient with a benign esophageal stricture be referred for surgery?

TB In most patients, surgery is the last treatment resort, as it is technically difficult and may lead to serious morbidity and mortality. Surgery usually requires opening the thorax and possibly the abdomen, depending upon the location of the stricture. Generally, patients with refractory strictures located in the more distal esophagus are technically easier to operate and resect, and there is more esophagus available proximal to the stricture. From the surgeon's technical perspective, strictures in the midesophagus, and certainly the proximal esophagus, are more difficult to operate, as they can be intimately involved with the airway.

G&H Is self-dilation a viable treatment option?

TB Self-dilation is effective, but patients often have difficulty mentally preparing for the procedure, as it can seem daunting to "swallow" a large dilator. The procedure is initiated by the physician, who dilates the stricture to a fairly large diameter and then immediately starts teaching the patient how to perform their own dilation by assisting them with passage of the dilator. Patients generally perform the procedure 1 or more times per day, usually indefinitely, to keep the stricture open. However, over

a long period of time, some patients eventually become stricture-free because they are dilating the stricture more frequently than would be readily accomplished using the healthcare system. Because patients may be resistant to accepting self-dilation as a treatment option, it is usually kept, along with surgery, as a last resort. Nevertheless, self-dilation can be effective and useful for management of benign esophageal strictures.

G&H What are the next steps in research in this area?

TB Ultimately, I foresee FDA-approval of fully covered SEMS for benign esophageal disease. However, I am unsure how long this process will take. Right now, it may not be worthwhile to pursue because SEMS are already available and FDA-approved for malignant disease, though physicians assume a liability for their off-label use. I believe that fully covered SEMS are relatively safe for use in benign disease, though physicians must explain to patients that the stents will be used off-label and discuss the associated risks and benefits of placement as well as alternative treatment options.

In addition, a next-generation self-expandable plastic stent is currently in development. The plastic stent currently on the market has not changed much in 8–10 years. There is speculation that the new stent will be more user-friendly and will reduce the migration rate.

There are also some recent data on biodegradable stents, which may be another avenue for future research.

Suggested Reading

- Bakken JC, Wong Kee Song LM, de Groen PC, Baron TH. Use of a fully covered self-expandable metal stent for the treatment of benign esophageal diseases. *Gastrointest Endosc*. 2010;72:712-720.
- Holm AN, de la Mora Levy JG, Gostout CJ, Topazian MD, Baron TH. Self-expanding plastic stents in treatment of benign esophageal conditions. *Gastrointest Endosc*. 2008;67:20-25.
- Dziletovic I, Fleischer DE. Self-dilation for resistant, benign esophageal strictures. *Am J Gastroenterol*. 2010;105:2142-2143.
- Sharma P, Kozarek R; Practice Parameters Committee of American College of Gastroenterology. Role of esophageal stents in benign and malignant diseases. *Am J Gastroenterol*. 2010;105:258-273; quiz 274.
- Ramage JI Jr, Rumalla A, Baron TH, et al. A prospective, randomized, double-blind, placebo-controlled trial of endoscopic steroid injection therapy for recalcitrant esophageal peptic strictures. *Am J Gastroenterol*. 2005;100:2419-2425.
- Osborn NK, Baron TH. The history of the "French" gauge. *Gastrointest Endosc*. 2006;63:461-462.
- Schembre D. Advances in esophageal stenting: the evolution of fully covered stents for malignant and benign disease. *Adv Ther*. 2010;27:413-425.
- van Heel NC, Haringsma J, Spaander MC, Bruno MJ, Kuipers EJ. Short-term esophageal stenting in the management of benign perforations. *Am J Gastroenterol*. 2010;105:1515-1520.
- Hordijk ML, van Hooft JE, Hansen BE, Fockens P, Kuipers EJ. A randomized comparison of electrocautery incision with Savary bougienage for relief of anastomotic gastroesophageal strictures. *Gastrointest Endosc*. 2009;70:849-855.