

Prophylactic Laparoscopic Gastrectomy for Hereditary Diffuse Gastric Cancer: A Case Series in a Single Family

David Hackenson, BS, David A. Edelman, MD, Tim McGuire, MD,
Donald W. Weaver, MD, John D. Webber, MD

ABSTRACT

Background: Hereditary diffuse gastric carcinomas (HDGCs) are particularly troubling because of autosomal dominant inheritance, high penetrance, early age of onset, and a lack of effective treatment once symptomatic. HDGC is further complicated by difficulty of effective screening. Gastrectomy provides definitive treatment for CDH1 mutation-positive patients. Attempting to minimize the morbidity and mortality of this procedure via a laparoscopic approach is appropriate.

Methods: Six consanguineous patients, 21 to 51 years of age, were identified as carriers of the CDH1 gene mutation. All of the patients' gastric mucosa was normal by endoscopic appearance and biopsy. After appropriate multispecialty counseling, all patients elected to undergo a laparoscopic total gastrectomy. Demographics, genealogy, operative approach, outcomes, and pathology were reviewed.

Results: All gastrectomies were completed using a laparoscopic approach. Gross examination of resected stomachs was unremarkable. Histological examination demonstrated multiple foci of invasive signet ring adenocarcinoma in all patients. There were no anastomotic leaks, one small bowel obstruction requiring reoperation, and one esophageal stricture requiring dilation.

Conclusions: This series demonstrates the utility and safety of the laparoscopic approach for prophylactic total gastrectomy for carriers of the CDH1 gene mutation. It serves to highlight that patients with CDH1 mutations may be more likely to undergo gastrectomy if they are offered the lower risk laparoscopic approach.

Key Words: Total laparoscopic gastrectomy.

INTRODUCTION

An estimated 21,130 new cases of gastric cancer occurred in the United States in 2009, and this represents a decrease in incidence.¹ This decline was accompanied by a decrease in mortality; however, it is unlikely that familial gastric cancers share similar fortunes. Hereditary Diffuse Gastric Cancers (HDGCs) represent 1% to 3% of all gastric cancers, and of those, up to 53% can be attributed to mutations in the CDH1 gene.²⁻⁴ These familial cancers demonstrate autosomal dominant inheritance and high penetrance. The 5-year survival is <20% if the diagnosis is made after the patient is symptomatic.⁵ This is compounded by the lack of reliable screening for early stage resectable tumors.⁶

Heuristics like the number and age of onset for family clusters of diffuse gastric cancer can identify those patients at highest risk, and testing of affected individuals and relatives can identify the presence of CDH1 mutations. After appropriate counseling, asymptomatic members of that family can then be screened for a CDH1 mutation. For patients with a CDH1 mutation of unknown significance, or in familial gastric cancer without an identifiable CDH1 mutation, the literature does not support any recommendations at this time. For patients with an identified CDH1 mutation, prophylactic surgery is a logical solution.

However, it is estimated that the risk of fatal HDGC exceeds the approximate 1% mortality risk of a gastrectomy for patients over 20 years of age.⁶ Physicians should present to patients the strong evidence supporting prophylactic gastrectomies and help them understand the range of surgical and nonsurgical options available. Knowledge that a laparoscopic gastrectomy can minimize the morbidity and mortality associated with the surgery may help ease the decision-making process.

METHODS

This is a case series of 6 consanguineous patients identified as carriers of the CDH1 gene mutation. After appropriate multispecialty counseling, all patients elected to undergo a laparoscopic total gastrectomy. After Institutional Review Board approval, demographics, genealogy,

Department of Surgery, Wayne State University, Detroit, Michigan, USA (all authors).

Address correspondence to: David A. Edelman, MD, Division of Minimally Invasive Surgery, Department of Surgery, Wayne State University, 3990 John R Street, Detroit, MI 48201, USA. E-mail: dedelman@med.wayne.edu

DOI: 10.4293/108680810X12924466007449

© 2010 by JLS, *Journal of the Society of Laparoendoscopic Surgeons*. Published by the Society of Laparoendoscopic Surgeons, Inc.

operative approach, outcomes, and pathology were reviewed.

RESULTS

Demographics

The series comprised 6 patients, 3 males and 3 females. The age range was 21 to 51 years old with an average of 38.2 years. All patients had their surgeries performed at the Karmanos Cancer Institute of Detroit, by a team of minimally invasive surgeons. All of the patients were residents of the state of Michigan at the time of their surgeries.

Genealogy

The patients were suspected of having hereditary gastric cancer when 2 relatives died of gastric cancer in their early thirties. The disease affected 2 separate generations of the family with the first affected family member (individual II-5, **Figure 1**) dying of gastric cancer at age 32. Individual II-5 had 5 siblings, 4 of whom were alive and could be tested. Three of the 4 agreed to genetic testing and were found to carry a CDH1 mutation. Individual II-4 was not tested, and her CDH1 status is currently unknown. She has 2 young girls, ages 11 and 8, who also have not been tested. Several children of the 3 CDH1 positive siblings (II-1, II-2, II-6) have been tested and have been found to carry the CDH1 gene (III-4, III-9, III-10). The CDH1 status of the remaining family members is unknown. Individual III-1 died in her early thirties, and although her CDH1 status was unknown, given her age, disease course, and

the presence of the mutation in her mother, it is highly likely that she was CDH1 positive. Of the family members known to have undergone genetic testing, 6 of 6 have tested positive for the CDH1 mutation. It is presumed that the 2 who died prior to testing indeed also carried the gene defect.

Surgery

All patients were asymptomatic at the time of their testing and surgery and had no abnormal abdominal findings on physical examination. All patients had genetic counseling prior to testing and surgery. All patients were screened endoscopically and were free of any gross gastric disease. Random gastric biopsies were performed in all cases. The biopsies were unremarkable.

All patients underwent a laparoscopic Roux-en-Y esophagojejunostomy. In all cases, the Roux limb was brought up to the esophagus in a retrocolic orientation. The esophageal anastomosis was performed with an Orvil (25-mm, 3.5-mm Covidien, Norwalk, CT) that was passed transorally. The jejunojunctionostomy was performed with a linear stapler (EndoUniversal GIA, Covidien). All hernia-site defects were closed including Peterson's defect, the jejunal mesentery, and the mesocolic window. A drain was left near the site of the esophagojejunostomy and was removed before the patient was discharge from hospital. No intraoperative endoscopy was used to test the integrity of the anastomosis, and no radiologic leak tests were performed postoperatively. All cases were done using 5 ports, 4 of which were 5-mm ports (**Figure 2**). A fifth 12-mm port placed in the left anterior axillary line at the

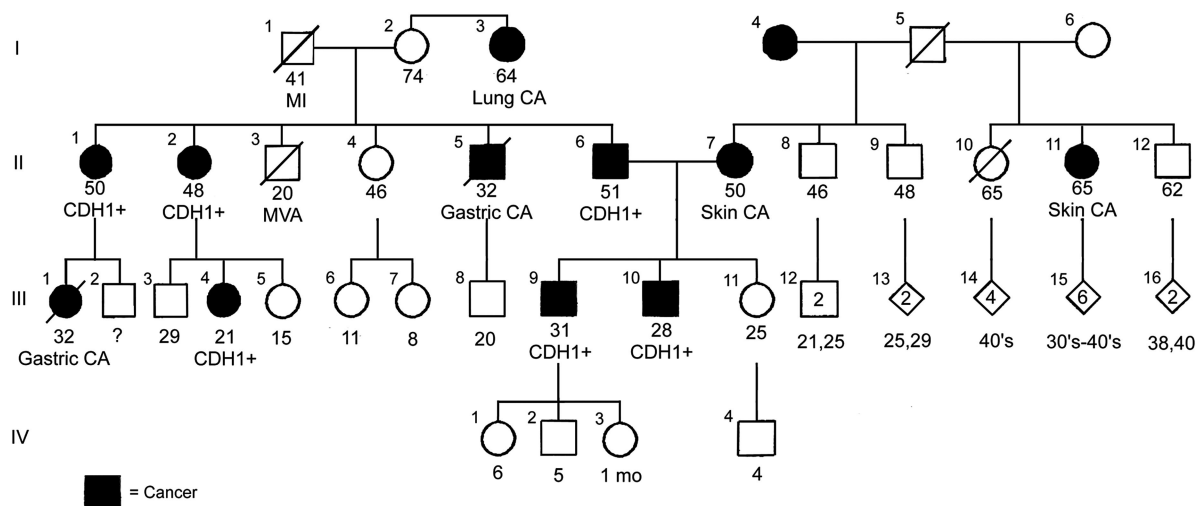


Figure 1. Family genealogy of hereditary gastric cancer.

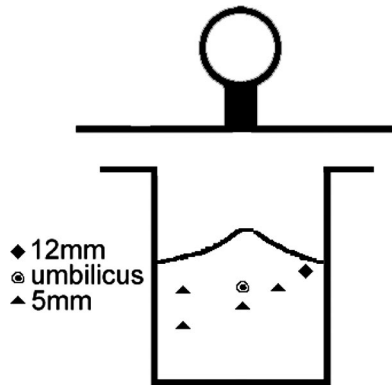


Figure 2. Trocar location for laparoscopic gastrectomy.

costal margin was used as the stapling port. This incision was extended at the end of the case to extract the stomach via an endocatch appliance.

Operative time ranged from 287 minutes to 372 minutes with an average time of 292 minutes. The mean length of stay (LOS) was 7.8 days (median 5 days, range 3 to 23). Postoperatively, the patients were placed on regular surgical wards and advanced in diet starting with clear liquids. All patients were seen back in the clinic and were found to be doing well.

One patient developed a stricture at the esophageal anastomosis that was treated successfully by endoscopic balloon dilatation. One patient developed nausea and vomiting on postoperative day 5 and was subsequently diagnosed with a small bowel obstruction secondary to adhesions around the mesocolic window. Operative repair, including lysis of adhesions and revision of the mesocolic window, was completed on postoperative day 10. The jejunojunostomy anastomosis appeared healthy and was without leaks at the time of reoperation. Subsequently, the patient developed a hydropneumothorax, drained once by ultrasound-guided aspiration and once by CT-guided aspiration. The remainder of the hospital course was uncomplicated, and this patient was discharged on hospital day 23.

Pathology

All of the stomachs were examined after removal from the body and were found to be grossly normal. Microscopic examination of the specimens showed that each had multiple microscopic foci of invasive signet ring cell carcinoma. The mean number of foci was 8.2 (median 4, range 2 to 19). The number of foci was reported for 5 of 6 patients; the sixth patient was noted to have multiple foci but no count was provided by the pathologist. All of the

foci of invasive carcinoma were confined to the lamina propria, and the largest focus noted was 0.5cm. All of the lymph nodes were negative. The mean lymph node harvest was 12.3 (median 10.5, range 5 to 25). All patients were staged as pT1N0MX.

DISCUSSION

Prophylactic gastrectomy in HDGC is a definitive treatment. Patients with a CDH1 mutation have a 70% to 80% risk of developing DGC over their lifetime, and the 5-year survival for symptomatic DGC is <20%. Genetic counseling and genetic testing are mandatory before offering a prophylactic total gastrectomy to any patient. Families suspected of possessing a CDH1 gene mutation should be screened by using the modified criteria as proposed by Suriano et al,⁷ and genetic testing can be offered to appropriate patients. In those found to carry a CDH1 mutation, prophylactic gastrectomy is advised.

Because of incomplete penetrance, some 20% to 30% of CDH1 mutation carriers will not develop DGC. Screening techniques, while contributing to the decline in overall gastric cancer mortality, are insufficient for early DGC, because of its tendency to underlie normal gastric mucosa. Two modalities, PET-CT and chromo-endoscopy have shown some potential for identifying early stage DGC, but both have limitations that prevent them from being implemented as an alternative to prophylactic gastrectomies.⁶

Total gastrectomy is not without complications. Overall, the 30-day mortality for total gastrectomy ranges from 3% to 6%.⁸ This is not surprising considering that gastrectomies are usually performed in older, sicker patients. In younger, healthier populations undergoing total gastrectomy, such as those with HDGC, morbidity and mortality has been estimated to be in the 1% to 2% range.⁹ One recent retrospective study of laparoscopic-assisted total gastrectomy patients (not specifically HDGC) showed no perioperative mortality among 131 patients and a postoperative morbidity rate of 19%.¹⁰ Postoperative complications included a range from ileus (2.3%) to anastomotic leak requiring reoperation (0.8%), with the most common being wound complications (5.3%). Even these results may overestimate perioperative morbidity for prophylactic gastrectomies, as complications were not reported by tumor stage, and 24 patients (18%) were TNM stage II or greater.

Long-term morbidity after total gastrectomy includes alterations in eating habits, dumping syndrome, diarrhea

and weight loss, and should be independent of surgery method. There is typically a 10% to 15% decrease in body weight, which is principally body fat. Dumping syndrome occurs in 20% to 30% of patients but tends to improve with time.¹¹ Overall, laparoscopic gastrectomies have demonstrated decreased perioperative morbidity and mortality over open¹²; patients had early return of bowel function, tolerated oral intake early, and were discharged earlier than those undergoing open procedures. The patients in this study were on average started on clear liquid diets by postoperative day 5.8 (median 4, range 2 to 20) and had an average LOS of 7.8 days as previously noted. This is in comparison with open gastrectomies where the average length of stay ranged from 10 days to 18 days.^{13,14} Earlier discharge and less morbidity may be significant factors in patients' decision to have a laparoscopic prophylactic gastrectomy.

The patients in this series selected the surgeon for his prior work in performing a hand-assisted laparoscopic total gastrectomy, which was reported as the first laparoscopic-assisted gastrectomy for HDGC.¹⁵ There is at least one additional report of prophylactic laparoscopic gastrectomies for CDH1 mutation carriers.¹⁶ Most literature comments on the dilemma of incomplete penetrance when prophylactic gastrectomies are offered to CDH1 positive patients. What is less clear is whether the outcomes of previously reported prophylactic surgeries have been discussed. Over 92% of prophylactic surgeries reported in the literature have shown one or more foci of signet ring cell adenocarcinoma.¹⁷ This makes these surgeries curative, rather than prophylactic. Considering the expected 5-year survival difference, the distinction between curative (in T1N0M0) and prophylactic surgeries may be irrelevant, though no data have been published to support this conclusion. However, the semantics may help patients decide. Being cured of cancer is arguably a more powerful motivator for surgery than is prevention of cancer by that same surgery. That does raise the issue of oncologic staging. When performed as prophylaxis, there is little concern for oncologic staging, because there is no cancer to stage. When surgery is therapeutic, staging becomes an issue. In the past, laparoscopic total gastrectomy has been criticized, because doubts remain concerning its ability to satisfy oncologic staging criteria met during more conventional open surgery. In general, most CDH1 positive patients undergoing a therapeutic (nee prophylactic) gastrectomy have early carcinoma, either in-situ or confined to the lamina propria. Guidelines given by the International Gastric Cancer Linkage Consortium (IGCLC) indicate that it is essential to document the complete

removal of gastric mucosa by histologically identifying esophageal and duodenal mucosa at the 2 ends of the surgical specimen.⁹ Additionally, the American Joint Committee on Cancer (AJCC) recommends that at least 15 lymph nodes be examined for staging purposes, but does allow for pN0 staging to be based on examination of resected nodes.¹⁸ Multiple studies of gastric cancer have indicated that for early stages of disease, the laparoscopic approach allows appropriate resection of gastric tissue and adequate harvest of D1 lymph nodes.¹⁹ Extension to D2 lymph nodes for early stage cancer presented additional risk without significantly altering the 5-year survival.²⁰ There is no reason to believe these results cannot be extrapolated to early DGC.

CONCLUSION

Minimally invasive surgery is playing an increasing role in the management of disease. This is highlighted in our case series, where we demonstrate the utility and safety of the laparoscopic approach toward prophylactic total gastrectomy in a family with HDGC. All of the patients in this series treated with gastrectomy demonstrated microscopic foci of invasive adenocarcinoma with no evidence of local or distant spread. Thus, these surgeries were curative, rather than prophylactic.

While current screening techniques are inadequate to make the distinction between prophylactic and curative surgery for these early stage patients, pre- and perioperative patient counseling should highlight the realities inherent in the data. Laparoscopic total gastrectomy not only provides a cure, but also satisfies oncologic staging requirements and provides for quicker recovery and decreased morbidity. We feel it is well suited for asymptomatic CDH1 positive patients in HDGC families. This recommendation comes with screening by family history, genetic counseling, consultation with a multi-specialty team, and the recommendation that the surgery should only be performed by a surgeon experienced in performing laparoscopic total gastrectomies. Moreover, this series demonstrates that gastrectomies can be performed successfully utilizing a laparoscopic approach minimizing morbidity compared with open gastrectomies. We believe that the laparoscopic approach should be offered as first-line therapy to CDH1-positive patients.

References:

1. Jemal A, Siegel R, Ward E, et al. Cancer statistics. *CA Cancer J Clin.* 2009;59:225–249.

2. Brooks-Wilson AR, Kaurah P, Suriano G, et al. Germline E-cadherin mutations in hereditary diffuse gastric cancer: assessment of 42 new families and review of genetic screening criteria. *J Med Genet.* 2004;41:508–517.
3. Kaurah P, MacMillan A, Boyd N, et al. Founder and recurrent CDH1 mutations in families with hereditary diffuse gastric cancer. *JAMA.* 2007;297:2360–2372.
4. Lynch HT, Silva E, Wirtzfeld D, Hebbard P, Lynch J, Huntsman DG. Hereditary diffuse gastric cancer: prophylactic surgical oncology implications. *Surg Clin North Am.* 2008;88:759–778, vi–vii.
5. Norton JA, Ham CM, Van Dam J, et al. CDH1 truncating mutations in the E-cadherin gene: an indication for total gastrectomy to treat hereditary diffuse gastric cancer. *Ann Surg.* 2007;245:873–879.
6. Guilford P, Blair V, More H, Humar B. A short guide to hereditary diffuse gastric cancer. *Hered Cancer Clin Pract.* 2007;5:183–194.
7. Suriano G, Yew S, Ferreira P, et al. Characterization of a recurrent germ line mutation of the E-cadherin gene: implications for genetic testing and clinical management. *Clin Cancer Res.* 2005;11:5401–5409.
8. Liedman B, Andersson H, Bosaeus I, Hugosson I, Lundell L. Changes in body composition after gastrectomy: results of a controlled, prospective clinical trial. *World J Surg.* 1997;21:416–420, discussion 420–411.
9. Caldas C, Carneiro F, Lynch HT, et al. Familial gastric cancer: overview and guidelines for management. *J Med Genet.* 1999;36:873–880.
10. Jeong GA, Cho GS, Kim HH, Lee HJ, Ryu SW, Song KY. Laparoscopy-assisted total gastrectomy for gastric cancer: a multicenter retrospective analysis. *Surgery.* 2009;146:469–474.
11. Miholic J, Meyer HJ, Muller MJ, Weimann A, Pichlmayr R. Nutritional consequences of total gastrectomy: the relationship between mode of reconstruction, postprandial symptoms, and body composition. *Surgery.* 1990;108:488–494.
12. Usui S, Yoshida T, Ito K, Hiranuma S, Kudo SE, Iwai T. Laparoscopy-assisted total gastrectomy for early gastric cancer: comparison with conventional open total gastrectomy. *Surg Laparosc Endosc Percutan Tech.* 2005;15:309–314.
13. Francescutti V, Choy I, Biertho L, Goldsmith CH, Anvari M. Gastrectomy and esophagogastrectomy for proximal and distal gastric lesions: a comparison of open and laparoscopic procedures. *Surg Innov.* 2009;16:134–139.
14. Pugliese R, Maggioni D, Sansonna F, et al. Total and subtotal laparoscopic gastrectomy for adenocarcinoma. *Surg Endosc.* 2007;21:21–27.
15. Francis WP, Rodrigues DM, Perez NE, Lonardo F, Weaver D, Webber JD. Prophylactic laparoscopic-assisted total gastrectomy for hereditary diffuse gastric cancer. *JLS.* 2007;11:142–147.
16. Mayrbaeurl B, Keller G, Schauer W, et al. Germline mutation of the E-cadherin gene in three sibling cases with advanced gastric cancer: clinical consequences for the other family members. *Eur J Gastroenterol Hepatol.* 2010 Mar;22(34):306–310.
17. Ziogas D, Roukos DH. CDH1 testing: can it predict the prophylactic or therapeutic nature of total gastrectomy in hereditary diffuse gastric cancer? *Ann Surg Oncol.* 2009;16:2678–2681.
18. Greene FL. The American Joint Committee on Cancer: updating the strategies in cancer staging. *Bull Am Coll Surg.* 2002;87:13–15.
19. Kitano S, Yasuda K, Shiraishi N. Laparoscopic surgical resection for early gastric cancer. *Eur J Gastroenterol Hepatol.* 2006;18:855–861.
20. Hartgrink HH, van de Velde CJ, Putter H, et al. Extended lymph node dissection for gastric cancer: who may benefit? Final results of the randomized Dutch gastric cancer group trial. *J Clin Oncol.* 2004;22:2069–2077.