

Psoriasiform Eruption Triggered by Recombinant Granulocyte-Macrophage Colony Stimulating Factor (rGM-CSF) and Exacerbated by Granulocyte Colony Stimulating Factor (rG-CSF) in a Patient with Breast Cancer

Colony-stimulating factors (CSFs) are commonly used for the treatment of neutropenia following chemotherapy and for the mobilization of peripheral blood stem cells (PBSC). We recently experienced a rare case of a new onset of psoriasiform eruption by GM-CSF (granulocyte-macrophage colony-stimulating factor) which was exacerbated by G-CSF (granulocyte colony-stimulating factor) in a patient with breast cancer. A 36-year-old woman had received neoadjuvant chemotherapy (cyclophosphamide, epirubicin and 5-fluorouracil), modified radical mastectomy and adjuvant chemotherapy with paclitaxel and mitoxantrone followed by GM-CSF administration for the treatment of locally advanced breast cancer. She had developed a psoriatic skin lesion on face and both upper arms during leukocyte recovery in spite of no previous history of psoriasis. Next, the chemotherapy course was complicated by a flare of mild psoriatic skin lesion, although CSF was changed into G-CSF due to GM-CSF-associated psoriasis. Subsequently, she had had high-dose chemotherapy and autologous peripheral blood stem cell transplantation for consolidation therapy. GM-CSF was administered for the mobilization of PBSC and post-transplant period, but psoriatic skin lesion did not appear. During 6 months after PBST, psoriasiform eruption did not appear.

Key Words: Psoriasis, psoriasiform eruption; Granulocyte-macrophage colony-stimulating factor; Granulocyte colony-stimulating factor

Seok Goo Cho, Young Min Park,[‡] Hanlim Moon, Kyung Mee Kim,[†] Sang Soo Bae, Gi Bum Kim, Hwan Suk Cho, Chun Choo Kim, Kung Shick Lee

Departments of Internal Medicine, Dermatology*, and Clinical Pathology[†], College of Medicine, The Catholic University of Korea, Seoul, Korea

Received: June 11, 1998

Accepted: July 22, 1998

Address for correspondence

Seok Goo Cho, M.D.

Division of Hemato-Oncology, Department of Internal Medicine, Kang Nam St. Mary's Hospital, College of Medicine, The Catholic University of Korea, 505, Banpo-dong, Socho-gu, Seoul 137-701, Korea

Tel: +82-2-590-2281, Fax: +82-2-590-2772

INTRODUCTION

Colony-stimulating factors (CSFs) such as granulocyte-macrophage colony-stimulating factor (GM-CSF) and granulocyte colony-stimulating factor (G-CSF) have been introduced in oncology practice as supportive measures to reduce complications related to myelosuppression of anti-cancer therapy (1). Also, CSF-mobilized peripheral blood stem cells (PBSCs) are more commonly used to rescue hematopoietic stem cells for high-dose therapy and autologous transplant than autologous bone marrow cells. Recently G-CSF has been used to mobilize PBSCs in healthy individuals for allogeneic transplantation (2, 3).

Various adverse effects associated with the administration of CSFs have been reported for several decades. Most of them include constitutional symptoms, such as fever, bone pain, myalgia, headaches and chills which could be easily controlled. We recently experienced CSF-

associated psoriasiform eruption in a patient with breast cancer.

CASE REPORT

A 36-year-old woman was admitted to our hospital and was diagnosed as invasive ductal cancer (T3N2M0). She had received neoadjuvant chemotherapy (cyclophosphamide 600 mg/m², epirubicin 90 mg/m² and 5-fluorouracil 600 mg/m²) and modified radical mastectomy. The surgical specimen showed negative hormone receptor and axillary node involvement (one among twenty-six). She received adjuvant chemotherapy with paclitaxel (170 mg/m²) and mitoxantrone (12 mg/m²) following GM-CSF administration for 11 days (400 µg/day, subcutaneously, D6-D16). At day 19, her initial course of adjuvant chemotherapy was complicated by small maculopapular skin

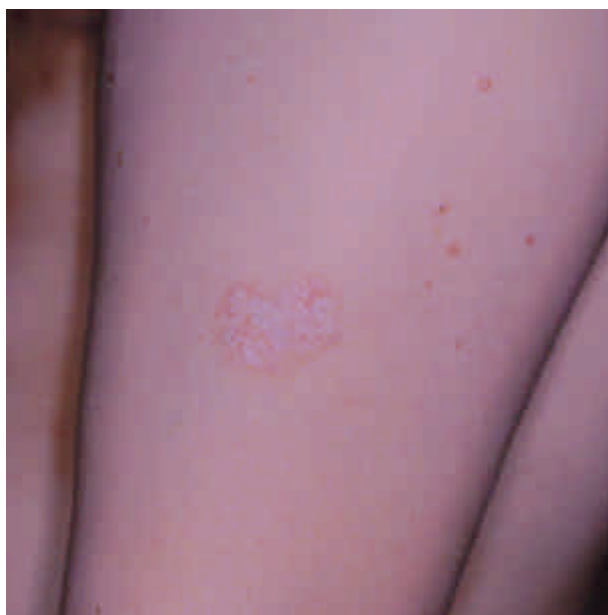

Fig. 1. Maculopopular eruption on deltoid area at day 19. Patient with breast cancer received GM-CSF therapy (400 $\mu\text{g}/\text{day}$, sc) for chemotherapy-induced neutropenia and developed skin lesion at the injection site of recombinant GM-CSF.

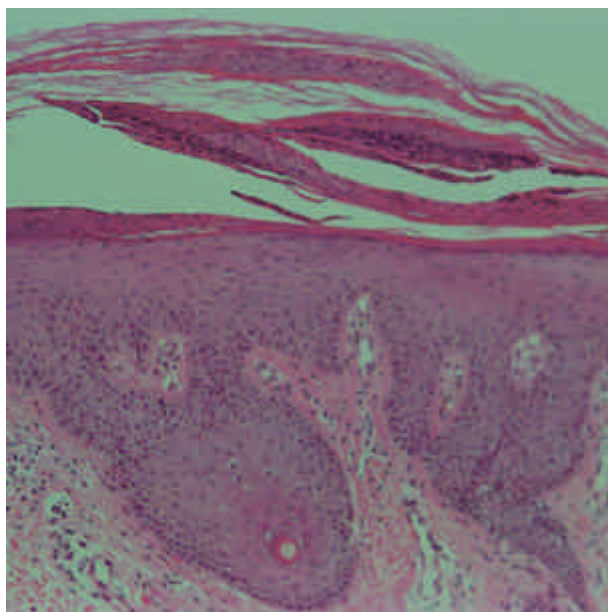


Fig. 2. Photomicrograph of psoriasis vulgaris showing hyperkeratosis, parakeratosis, Munro microabscess and elongation of rete ridges (H&E, $\times 100$). Biopsy specimen was obtained from the injection site of recombinant GM-CSF at day 20.

eruption on the GM-CSF injection site during leukocyte recovery (Fig. 1). The skin biopsy specimen showed marked hyperkeratosis, parakeratosis and Munro's abscess in the cornual layer. In addition, elongation of rete ridges, with thickening in their lower portion, was also noted

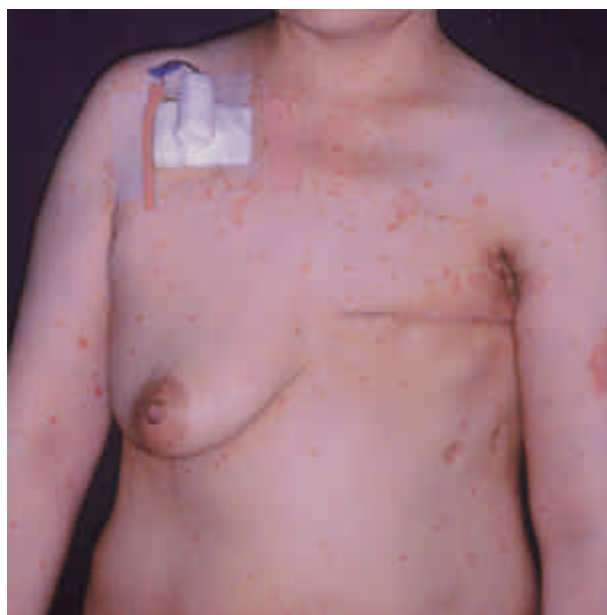

Fig. 3. Severe systemic flare of psoriasiform eruption appeared after changing GM-CSF into G-CSF at day 38.

and the dermal papillae were elongated and edematous (Fig. 2). But, she had no previous history and family one of psoriasis.

Next, the course was complicated by a flare of psoriatic skin lesion at D38 after administering G-CSF for 12 days (250 $\mu\text{g}/\text{day}$, subcutaneously, D16-D28) instead of GM-CSF (Fig. 3). There was no known aggravating factors including streptococcal infection, emotional stress, alcohol, lithium and beta blockers except G-CSF. We decided to perform high-dose therapy including ifosfamide 16 g/m^2 , carboplatin 1.8 g/m^2 and etoposide 1.5 g/m^2 (ICE regimen) and autologous peripheral blood stem cell transplantation (PBSCT) because of high risk for relapse. Although the newly onset psoriasiform eruption was triggered by GM-CSF, it was aggravated by G-CSF and so, we preferred GM-CSF for the mobilization of PBSC. While leukocyte count was increased to 34,500/ μL , it did not recur during mobilization. During the post-transplant period, psoriatic skin lesion did not develop in spite of daily administration of GM-CSF for 30 days (400 $\mu\text{g}/\text{day}$, subcutaneously, D1-D30). She recovered and was discharged without any problem. Up to 6 months after PBSCTS, she had no skin lesions (Table 1).

DISCUSSION

There are three reports in which CSFs could be responsible for the induction or exacerbation of psoriasis (4, 5,

Table 1. Summary of clinical course during chemotherapy

	Adjuvant chemotherapy (paclitaxel+mitoxantrone)		High dose chemotherapy (ICE regimen)
	First cycle	Second cycle	
GM-CSF (400 µg, sc)	D6-D16	Not used	D1-D30 after PBSCT
G-CSF (250 µg, sc)	Not used	D16-D28	Not used
Skin lesion	Maculopapular eruption on deltoid area at D19	A flare of psoriasiform lesion at D38	No skin lesion
Skin biopsy	Done at D20	Not done	Not done
WBC	3,500/µL at D19	2,900/µL at D38	Reached to 34,500/µL during mobilization

6). Feliu et al. reported that psoriasis worsened after treatment with G-CSF in a patient with small-cell lung cancer (4). Kelly et al. reported that psoriasis was exacerbated with GM-CSF therapy in a patient with refractory anemia with excess blasts (RAEB) (5). Kazerouni-Meunier et al. described induction of psoriasis by G-CSF in a patient with human immunodeficiency virus (HIV) infection (6).

Psoriasis is a chronic epidermal proliferative disease of unpredictable course and has many inducing or worsening factors. In our case, psoriasiform skin lesion is different from classical form. Our case did not show Koebner phenomenon because systemic flare-up of skin lesions was developed regardless of operation wound and multiple injection sites of G-CSF. We thought that this lesion was newly developed because patient had no past and family history and there were no known aggravating factors including streptococcal infection, emotional stress, alcohol, lithium, beta blockers and so on. In our case, as well as in other cases, induction or worsening of psoriasis coincided with an increase in the leukocyte count and administering GM- or G-CSF. However, during the course of mobilizing PBSCs, although rechallenged GM-CSF increased leukocyte count to 15,000, skin lesion did not previously appear when GM-CSF or G-CSF had been given. Although we can not explain exactly this phenomenon, desensitization might be induced by rechallenged GM-CSF.

Many recombinant CSFs including interferon alpha, beta and gamma, have been reported to be associated with psoriasis at the injection site (7). It has been shown that the level of GM-CSF at lesional skin was correlated to an increase of inflammatory cytokines (Type I), such as tumor necrosis factor- α (TNF- α) and interleukin-6 (IL-6) (8). Monocytes in psoriatic skin have been shown to enhance neutrophil function by GM-CSF (9). Although it is difficult to demonstrate the role of them in the pathogenesis of psoriasis, both GM-CSF and G-CSF have been found to be closely associated with its flare-up. Recently, cutaneous reactions have been shown following

administration of G-CSF (10 µg/kg) in healthy volunteers: toxic folliculitis with syringometaplasia in one volunteer and a psoriasiform eruption in another (10). So, considering that GM-CSF and/or G-CSF may induce or exacerbate psoriasis or cutaneous reactions, both should be cautiously administered to healthy donors in allogeneic PBSCs.

In summary, we experienced CSF-associated psoriasiform eruption which was triggered by GM-CSF and exacerbated by G-CSF but its flare was not induced by rechallenged GM-CSF. Further clinical evaluation will be necessary to find out the role of CSFs in the pathogenesis of psoriasis or psoriasiform eruption.

REFERENCES

1. Welte K, Gabrilove J, Bronchoud MH, Platzer E, Morstyn G. *Filgrastim (r-metHuG-C-CSF). the first 10 years. Blood* 1996; 88: 1907-29.
2. Anderlini P, Korbling M, Dale D, Gratwohl A, Schmitz N, Stoneck D, Howe C, Leitman S, Horowitz M, Gluckman E, Rowley S, Przepiorka D, Champlin R. *Allogeneic blood stem cell transplantation: consideration for donors. Blood* 1997; 90: 903-8.
3. Bishop MR, Taratolo SR, Jackson JD, Anderson JR, Schmitz-Pokorny K, Zacharias D, Pavletic ZS, Pirruccello SJ, Vose JM, Bierman PJ, Warkentin PI, Armitage JO, Kessinger A. *Allogeneic-Blood Stem-cell collection following mobilization with low-dose granulocyte colony-stimulating factor. J Clin Oncol* 1997; 15: 1601-7.
4. Feliu J, Díaz R, Contreras F, Casado M, Espinosa E, Barón MG. *Worsening psoriasis after treatment with G-CSF in a patient with small-cell lung cancer. J Natl Cancer Institute* 1997; 89: 1315-6.
5. Kelly R, Marsden RA, Bevan D. *Exacerbation of psoriasis with GM-CSF therapy [letter]. Br J Dermatol* 1993; 128: 468-9.
6. Kazerouni-Meunier F, Descamps V, Picard-Dahan C, Bouscrat F, Cremieux A, Crickx B, Belaich S. *Induction of pustular*

- psoriasis by granulocyte colony-stimulating factor in a patient with HIV infection. Eur J Dermatol 1996; 6: 353-4.*
7. Asnis LA, Gaspari AA. *Cutaneous reactions to recombinant cytokine therapy. Am Acad Dermatol 1995; 33: 393-410.*
 8. Bonifati C, Carducci M, Fei PC, Sacerdoti TG, Fazio M, Ameglio F. *Correlated increases of tumour necrosis factor- α , interleukin-6 and granulocyte monocyte-colony stimulating factor levels in suction blister fluids and sera of psoriatic patients-relationships with disease severity. Clin Exp Dermatol 1994; 19: 383-7.*
 9. Pigatto PD, Pigatto LB, Bigardi A, Altomare F, Finze AF. *Factors secreted by untreated psoriatic monocytes enhance neutrophil functions. J Invest Dermatol 1990; 94: 372-6.*
 10. Paul C. *Cutaneous effects of granulocyte colony-stimulating factor in healthy volunteers. Arch Dermatol 1998; 134: 111-2.*