

A Case of Disseminated *Trichosporon beigeli* Infection in a Patient with Myelodysplastic Syndrome after Chemotherapy

Trichosporonosis is a potentially life-threatening infection with *Trichosporon beigeli*, the causative agent of white piedra. The systemic infection by this fungus has been most frequently described in immunocompromised hosts with neutropenia. Here, we report the first patient with disseminated infection by *T. beigeli* in Korea, acquired during a period of severe neutropenia after chemotherapy for myelodysplastic syndrome. The patient recovered from the infection after an early-intensified treatment with amphotericin B and a rapid neutrophil recovery. The disseminated infection by *T. beigeli* is still rare, however, is an emerging fatal mycosis in immunocompromised patients with severe neutropenia.

Key Words : *Trichosporon*; Immunocompromised Host; Myelodysplastic Syndromes; Amphotericin B

Jong-Chul Kim, Yang Soo Kim,
Chul-Sung Park, Jae-Myung Kang,
Baek-Nam Kim, Jun-Hee Woo,
Jiso Ryu, Woo Gun Kim

Department of Internal Medicine, University of Ulsan
College of Medicine, Seoul, Korea

Received : 21 June 2000
Accepted : 14 August 2000

Address for correspondence

Jun-Hee Woo, M.D.
Division of Infectious Diseases, Asan Medical Center,
UUCM, 388-1 Poongnap-dong, Songpa-gu, Seoul
138-736, Korea
Tel: +82.2-2224-3300, Fax: +82.2-2224-6970
E-mail: junheewoo@amc.seoul.kr

INTRODUCTION

Trichosporon beigeli is found in soil and occasionally as a part of the normal flora in human skin (1). The fungus is a causative agent of white piedra, an innocuous superficial hair shaft infection in immunocompetent individuals, and rarely of disseminated trichosporonosis in immunocompromised patients (1). Recently, with more aggressive chemotherapy for malignant diseases and increasing use of broad-spectrum antibiotics, a large number of cases of disseminated trichosporonosis have been reported (1, 2).

Here, we describe the first case of disseminated *T. beigeli* infection in a Korean patient, during a neutropenic period by chemotherapy for myelodysplastic syndrome. The other reported case in Korea was a patient with advanced gastric cancer and normal neutrophil count and without systemic symptoms (2).

CASE REPORT

A 41-yr-old male patient, with myelodysplastic syndrome of refractory anemia with an excess of blasts in transformation received an induction chemotherapy with cytosine arabinoside and idarubicin. On the fifth day of the chemotherapy, his absolute neutrophil count (ANC) declined to 142/ μ L, which prompted the treatment with granulocyte colony stimulating factor (G-CSF). On the 14th day, his bone marrow

showed complete clearance of the neoplastic cells and hypocellular marrow. The patient's cytopenia was supported with multiple transfusions of red blood cells, platelets, and plasma. On the 15th day, administration of empirical broad-spectrum antibiotics was promptly started because of the development

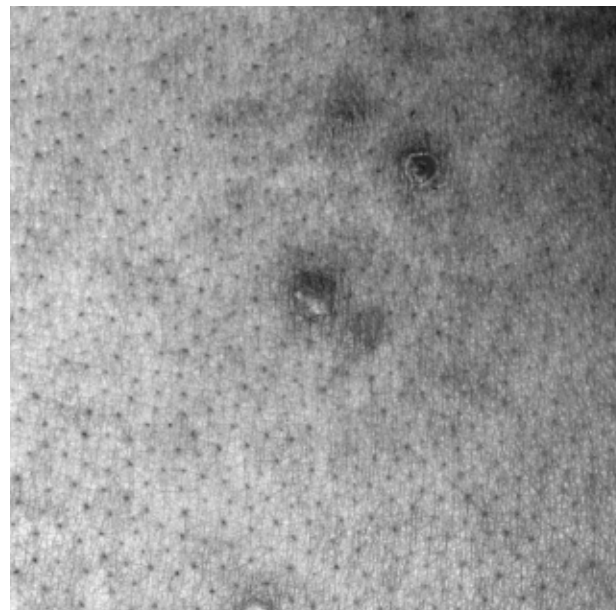


Fig. 1. Skin lesion, trunk: multiple erythematous nodules subsequently proved to be due to *Trichosporon beigeli* by biopsy.

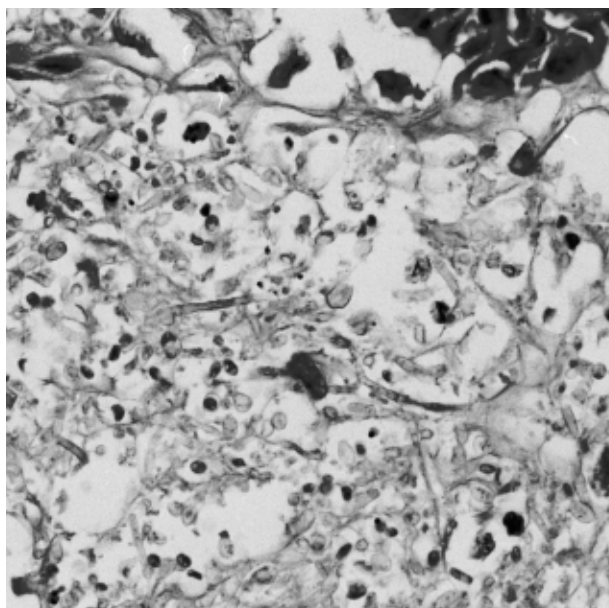


Fig. 2. Skin biopsy, trunk: the central area of dermal necrosis contains narrow, irregularly septate pseudohyphae and large pleomorphic yeast forms of fungi with arthroconidia and blastoconidia, which are morphologically consistent with *T. beigelii* (H&E, $\times 200$).

of fever and dry cough with both lower lungs infiltrates of reticulonodular pattern. Erythematous maculonodular skin lesions were noticed on his face and trunk as well (Fig. 1). Three days later, he was still febrile and chest radiography showed progression of the infiltration. A prompt empirical administration of amphotericin B was started. On the 20th day, fever continued and pneumonic infiltration in both lower lungs was aggravated despite negative sputum cultures. Central venous catheter was then removed and antibiotic agents were changed to imipenem, vancomycin and amphotericin B. On the 25th day of the chemotherapy, the multiple skin nodules had extended to the extremities and skin biopsy was done on the trunk (Fig. 2). At this point, blood cultures taken prior to antifungal therapy revealed a growth of *T. beigelii* (Fig. 3), which was identified by Microscan Rapid Yeast ID panel (Dade Behring, U.S.A.). However, repeated urine, sputum, and central venous catheter tip cultures were negative. On the 26th day, ANC was $748/\mu\text{L}$, then G-CSF was discontinued. On the 30th day, the fever subsided with a good recovery of white cell count and the patient continued to receive high dose amphotericin B (1 mg/kg) daily. On the 44th day, chest radiograph was normal and skin nodules resolved completely. Follow-up blood, urine, and sputum cultures were negative, and cumulative total amphotericin B dose was 1,430 mg. However, three days later, fever developed again with skin nodules on the face. A combination therapy with amphotericin B (1.5 mg/kg/day) and itraconazole was initiated. Two days later, the patient became afebrile and skin lesions resolved. Antifungal treatment was continued on an

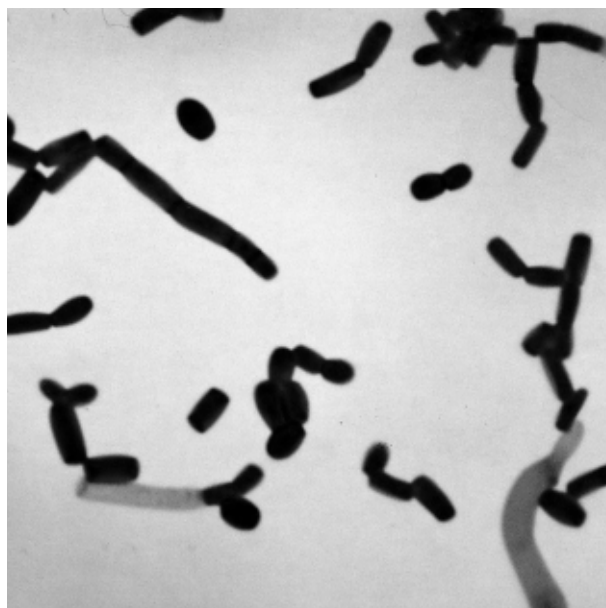


Fig. 3. Microscopic morphology of *T. beigelii* from the colony on agar plate: true hyphae and pseudohyphae with blastoconidia are seen singly or in short chains (Gram stain, $\times 400$).

outpatient basis (amphotericin B, a total dose of 3,144 mg). Neither further chemotherapy nor bone marrow transplantation was performed for fear of reactivation of the fungal infection. One month later, the patient died of septic shock, but *T. beigelii* was not detected in any of the microbiological isolates.

DISCUSSION

T. beigelii is classically associated with superficial hair infections, known as white piedra. More recently, it has been recognized as an opportunistic pathogen that can cause a potentially fatal systemic infection in immunocompromised hosts (1, 2). Patients with hematologic malignancies receiving cytotoxic chemotherapy have been most frequently reported to develop trichosporonosis. However, trichosporonosis has also been reported in non-neutropenic patients (1, 2).

A review of the literature suggests that the origin of *T. beigelii* is generally exogenous. Now, the three most common portals of entry are thought to be the respiratory tract, gastrointestinal, and skin (wound or catheter-associated) (1, 3, 4). Cytotoxic anti-cancer drug (cytosine arabinoside) may injure the mucosa of the gastrointestinal tract, and broad-spectrum antibiotics can severely disrupt the normal microbiologic flora of the gastrointestinal tract. Trichosporon may then colonize, proliferate, and invade the blood vessels through the disrupted mucosal barrier. Hematogenous dissemination is usually rapid and widespread (5). However, in *T. beigelii*

pneumonia, the fungi were present predominantly in the bronchoalveolar spaces. It is generally regarded that the lung involvement is primary rather than secondary from hematogenous spread (5). In this case, the patient presented with fever, respiratory symptoms and chest radiograph abnormalities, followed by skin manifestations. Surveillance fungal cultures of stool and sputum were not performed, however, central venous catheter tip culture was negative. Therefore, we presumed the respiratory tract was the portal of entry, although the gastrointestinal tract can not be excluded.

The clinical manifestations of trichosporonosis are variable. The lung, kidneys, skin, liver, spleen, and heart are the most frequently affected organs. Cutaneous involvement occurs in approximately 30% of patients with trichosporonosis (3). The lesions are most frequently described as purpuric papules and nodules with central necrosis or ulceration. The trunk, arms, and face were most commonly involved (6). Biopsy and culture specimens of cutaneous lesions associated with a disseminated disease may help establish an early diagnosis. The most frequent histologic pattern is dermal invasion by fungal elements. Vasculitis and blood vessel thrombosis have also been reported (6). Although the microscopic appearance can be confused with *Candida* or *Aspergillus*, a close observation of biopsy specimens containing *T. beigeli* reveals pseudohyphae, the presence of numerous rectangular arthroconidia, and a few blastoconidia permitting an accurate diagnosis. Fungal culture of cutaneous lesions is positive in greater than 90% of cases and can minimize the possibility of mistaken histologic identification (6). Diagnosis of trichosporonosis relies mostly on characterization of the yeast from blood cultures. In the present case, although we did not culture the skin biopsy specimen, blood cultures were positive.

The clinical manifestations of *T. beigeli* pneumonia are fever unresponsive to antibacterial agents, dyspnea, cough, bloody sputum, fungemia, associated skin lesions, chorioretinitis, hematuria, renal failure, and liver dysfunction due to a disseminated infection (5). In neutropenic patients, the most frequent pattern of pulmonary infiltrates on chest radiographs is diffuse alveolar infiltrates. Diffuse interstitial infiltrates and patchy reticulonodular infiltrates may also appear. In non-neutropenic patients, however, lobar consolidation or bronchopneumonia is the major characteristic on chest radiographs, and cavitation can sometimes be observed in the infiltration. Because chest radiographs of *T. beigeli* pneumonia may show diffuse infiltrates, differential diagnosis from pneumonia due to Cytomegalovirus or *Pneumocystis carinii* is important (5).

Established treatment modality for *T. beigeli* is not available for several reasons. First, the antifungal susceptibility test is currently not standardized. Walsh et al. demonstrated that the growth of some strains of *T. beigeli* were inhibited, but they were not killed, at safely achievable serum concentrations of amphotericin B (7). In addition, there are conflicting results regarding the susceptibilities to flucyto-

sine, miconazole, and ketoconazole (1). For example, Gold et al. demonstrated that the MICs of the latter three drugs varied according to the testing methods (8). Second, the correlation between the in vitro antifungal susceptibility and the clinical response is not clearly defined yet (9). Third, the minimum lethal concentrations which are more important than MICs in predicting the antifungal activity against *T. beigeli* in neutropenic patients, are many times greater than the MICs and cannot be tolerated by the patient (3, 7). Fourth, neutropenia is obviously an important factor in triggering a disseminated trichosporonosis because polymorphonuclear cells play a major role in the defense against the fungal infection. It appears that a successful therapy has been achieved in the majority of patients recovering from myelosuppression. On the other hand, persistent severe neutropenia is almost always associated with therapeutic failure (10). Lastly, the activity of amphotericin B varies by strains, exhibiting a good in vivo response in some and relative resistance in others, which suggests that the *T. beigeli* species may be a heterogeneous group of the organisms (11).

Recently, some reports indicated azoles (e.g. fluconazole and SCH-39304) were effective in clearing the fungi in tissue with a good safety profile, and thus could represent an alternative to amphotericin B for the treatment of trichosporonosis (7, 10, 12, 13). Anaissie et al. suggest that amphotericin B and azoles act synergistically against murine trichosporonosis (10). In neutropenic patients, the success of treatment was associated with resolution of neutropenia and pretreatment of human monocytes with granulocyte-macrophage colony-stimulating factor (GM-CSF), or interferon- γ , which resulted in an enhanced fungicidal activity (14). However, the agent most commonly used to treat patients with trichosporonosis is still amphotericin B. Additional agents used in combination with amphotericin B, such as rifampin and azoles, have occasionally been shown to be synergistic in vitro (11). Hematopoietic growth factor is also recommended in neutropenic patients (14). In the present case, the therapy was initiated with administration of G-CSF and amphotericin B. The patient recovered with increase in white blood cell counts but relapsed after the discontinuation of the therapy. Therefore, the combination therapy with amphotericin B and itraconazole was started which attained remission.

With the increased employment of intensive cytotoxic chemotherapy and the use of extended courses of antibiotic therapy, infections due to opportunistic fungi are increasing. Recognition of *T. beigeli* as a potential pathogen, especially in susceptible clinical settings, will lead to the early identification of this potentially serious infection and the establishment of appropriate treatment will improve survival. Disseminated infection with *T. beigeli* is still rare, however, is an emerging fatal mycosis in immunocompromised patients with profound neutropenia.

REFERENCES

1. Hoy J, Hsu KC, Rolston K, Hopfer RL, Luna M, Bodey GP. *Trichosporon beigelii* infection: a review. *Rev Infect Dis* 1986; 8: 959-67.
2. Rhee CH, Song SY, Lee H, Peck KR, Kim S, Kang WK, Song JH. A case of *Trichosporon beigelii* fungemia in an advanced gastric cancer patient treated with anticancer chemotherapy. *Korean J Infect Dis* 1999; 31: 252-6.
3. Walsh TJ. *Trichosporonosis*. *Infect Dis Clin North Am* 1989; 3: 43-52.
4. Haupt HM, Merz WG, Beschoner WE, Vaughan WP, Saral R. Colonization and infection with *Trichosporon* species in the immunosuppressed host. *J Infect Dis* 1983; 147: 199-203.
5. Tashiro T, Nagai H, Nagaoka H, Goto Y, Kamberi P, Nasu M. *Trichosporon beigelii* pneumonia in patients with hematologic malignancies. *Chest* 1995; 108: 190-5.
6. Nahass GT, Rosenberg SP, Leonardi CL, Penneys NS. Disseminated infection with *Trichosporon beigelii*. *Arch Dermatol* 1993; 129: 1020-3.
7. Walsh TJ, Melcher GP, Rinaldi MG, Lecciones J, Mcgough DA, Kelly P, Lee J, Callender D, Rubin M, Pizzo PA. *Trichosporon beigelii*, an emerging pathogen resistant to amphotericin B. *J Clin Microbiol* 1990; 28: 1616-22.
8. Gold JWM, Poston W, Mertelsmann R, Lange M, Kiehn T, Edwards F, Bernard E, Christiansen K, Armstrong D. Systemic infection with *Trichosporon cutaneum* in a patient with acute leukemia: report of a case. *Cancer* 1981; 48: 2163-7.
9. Grauer ME, Bokemeyer C, Bautsch W, Freund M, Lin H. Successful treatment of a *Trichosporon beigelii* septicemia in a granulocytopenic patient with amphotericin B and granulocyte colony-stimulating factor. *Infection* 1994; 22: 283-5.
10. Anaissie E, Gokaslan A, Hachem R, Rubin R, Griffin G, Robinson R, Sobel J, Bodey G. Azole therapy for trichosporonosis: clinical evaluation of eight patients, experimental therapy for murine infection, and review. *Clin Infect Dis* 1992; 15: 781-7.
11. Anaissie EJ, Hachem R, Karyotakis NC, Gokaslan A, Dignani MC, Stephens LC, Tin-U CK. Comparative efficacies of amphotericin B, triazoles, and combination of both as experimental therapy for murine trichosporonosis. *Antimicrob Agents Chemother* 1994; 38: 2541-4.
12. Walsh TJ, Lee JW, Melcher GP, Navarro E, Bacher J, Callender D, Reed KD, Wu T, Gabriel LB, Pizzo PA. Experimental *Trichosporon* infection in persistently granulocytopenic rabbits: implications for pathogenesis, diagnosis, and treatment of an emerging opportunistic mycosis. *J Infect Dis* 1992; 166: 121-33.
13. Woo J-H, Chung DR, Ryu J. Systemic antifungal agents. *Korean J Med Mycol* 1997; 2: 110-22.
14. Lyman CL, Garrett KF, Pizzo PA, Walsh TJ. Response of human-polymorphonuclear leukocytes and monocytes to *Trichosporon beigelii*: host defense against an emerging opportunistic pathogen. *J Infect Dis* 1994; 170: 1557-65.