

Recurrent Pseudotumor Cerebri in Systemic Lupus Erythematosus : A Case Report

Pseudotumor cerebri is an uncommon manifestation of neuropsychiatric systemic lupus erythematosus (SLE), and is characterized by an elevated intracranial pressure, papilledema with occasional abducens nerve paresis, absence of a space-occupying lesion or ventricular enlargement, and normal cerebrospinal fluid chemical and hematological constituents. Pseudotumor cerebri has been reported in a few sporadic cases in patients with systemic lupus erythematosus. However, the recurrent pseudotumor cerebri in patients with systemic lupus erythematosus which has been rarely reported, has not been reported in Korea. We experienced a 30-yr-old female patient with SLE who was presented with second attack of severe intractable headache. She was diagnosed pseudotumor cerebri twice and successfully treated with corticosteroid. Headache is the common symptom in patients with neuropsychiatric SLE and attributable to various causes. We suggest that it is important to define the cause of headache in patients with SLE and pseudotumor cerebri should be included in the spectrum of clinical manifestations during the course of SLE as a cause of headache.

Key Words : *Pseudotumor Cerebri; Lupus Erythematosus, Systemic*

Wan Hee Yoo, Ji Hyun Park,
Hyun Kag Kim, Tae Sun Park,
Hong Sun Baek

Department of Internal Medicine, Medical School,
Chonbuk National University and Research
Institute of Clinical Medicine, Chonju, Korea

Received : 13 November 2000
Accepted : 1 February 2001

Address for correspondence

Wan Hee Yoo, M.D.
Division of Rheumatology, Department of Internal
Medicine, Medical School, Chonbuk National
University and Research Institute of Clinical
Medicine, 634-18, Keumam-dong, Duckjin-gu,
Chonju 561-712, Korea
Tel : +82.63-254-1609, Fax : +82.63-250-1672
E-mail : ywhim@moak.chonbuk.ac.kr

INTRODUCTION

Systemic lupus erythematosus (SLE) is one of the most unpredictable systemic connective tissue diseases. Headache is a common symptom in SLE patients (1-3) but whether there is a unique syndrome attributable to SLE is not clear. Different types of headache may occur in SLE due to various underlying conditions. Pseudotumor cerebri (PC) is an uncommon syndrome of neuropsychiatric SLE and one of the causes of headache in SLE patients. In 1968 Bettman et al. (4) first reported a patient with concomitant SLE and PC. Since then PC has been reported in a few sporadic cases in adult patients with SLE (5, 6). However, recurrent PC in patients with SLE, which has been reported rarely (7-11), has not been reported in Korea.

Here, we describe a 30-yr-old female patient with SLE who was afflicted with recurrent PC. This case illustrates that the possibility of PC should be taken into account in the differential diagnosis of headache during the course of SLE.

CASE REPORT

A 30-yr-old woman was referred to our department due to intractable headache, dizziness, fatigue, nausea and vomiting. She had been well until two weeks before admission,

when she experienced severe frontal headache. The severity of her headache increased over one week prior to admission. She was diagnosed with SLE five year earlier in accord with the ACR criteria (12): malar rash, arthritis, photosensitivity, thrombocytopenia (85,000/ μ L), and positive results for anti-nuclear antibody (1:320, speckled pattern), anti-dsDNA, and anti-Ro antibodies. She had symptoms of elevated intracranial pressure: headache, diplopia, nausea and vomiting. Ophthalmologic examination showed bilateral papilledema and the findings of brain CT scan was normal. A lumbar puncture produced clear acellular cerebrospinal fluid (CSF) with an opening pressure above 300 mmH₂O. Treatment with prednisolone 60 mg/day was started on the basis of a diagnosis of PC associated with SLE. After 3 months of treatment, relief of the signs and symptoms with normal CSF opening pressure. She had been well for the next five year with low dose prednisolone and hydroxychloroquine (300 mg/day) until her headache recurred.

At the current admission, her vital signs were body temperature of 37.7°C, blood pressure of 100/60 mmHg, pulse rate of 79/min, and respiration rate of 17/min. A faint and pink maculopapular rash was noted over the face. No palpable lymph nodes were noted. An ophthalmologic examination revealed bilateral papilledema but visual acuity and visual fields were normal. Neurological examination was normal.

Laboratory results showed a white blood cell count of 3,200/ μ L, hemoglobin of 9.1 g/dL, reticulocytosis of 1.1%, and platelet count of 235,000/ μ L. Erythrocyte sedimentation rate (ESR) was 80 mm/hr. Serum electrolytes, liver and kidney function test results were normal. Coagulation test results were normal, with prothrombin time of 100% (INR 1.0), activated partial thromboplastin time of 38.0 sec (normal, 29.8-41.8). Immunoglobulin profiles demonstrated an elevated level of IgG upto 1,810 mg/dL (normal, 751-1,560) and normal levels of IgA and IgM. Antinuclear antibody titer was 1:640 (speckled pattern) and anti-dsDNA antibody was 114 IU/mL (normal, <7). Anti-Ro, anti-RNP tests were both positive. Complement levels were decreased: C3, 60.9 mg/dL (normal, 65-125) and C4, 7.19 mg/dL (normal, 12-43). Tests for anticardiolipin antibody (IgG, IgM) and lupus anticoagulant were negative. Hormonal profile showed normal levels of TSH, free T3, T4, FSH, LH, estrogens, progesterone, prolactin, and cortisol.

A lumbar puncture showed clear acellular CSF with an opening pressure of above 280 mmH₂O (normal, <60-160 mmH₂O) and glucose and protein concentrations of 30.6 mg/dL (normal, 15-45) and 62 mg/dL (normal, 50-75), respectively. CSF bacteria cultures and tests for viral antibody of varicella-zoster, herpes simplex, influenza A, B, cytomegalovirus, adenovirus, and Epstein-Barr virus were all negative. The findings of brain magnetic resonance images were normal (Fig. 1).

The patient was diagnosed with recurrent PC representing as a flare-up of neuropsychiatric SLE. Treatment with prednisolone 60 mg daily and azathioprine 100 mg/day was started, and subsequently the prednisolone was tapered by

dose to 10 mg/day over 8 weeks. After three months of follow-up, the patient's signs and symptoms were noted to be relieved.

DISCUSSION

Neuropsychiatric SLE includes the neurologic syndromes of the central, peripheral, and autonomic nervous system and psychiatric syndromes observed in patients with SLE after excluding other causes. Since the first report of stupor and coma in SLE by Hera and Kaposi (13) in 1875, a multitude of neuropsychiatric syndromes have been reported in SLE patients. Neuropsychiatric affliction in SLE has become well established with a frequency of as high as 14 to 75% (14), and PC has been reported in a few cases of adult patients with neuropsychiatric SLE (5, 6).

Diagnosis of PC requires increased intracranial pressure (CSF pressure >200 mmH₂O) without clinical, laboratory, or radiological evidence of a space-occupying lesion or hydrocephalus. This patient fulfilled all of these criteria for PC. The patient manifested the symptoms and signs suggesting increased intracranial pressure as intractable headache, nausea, vomiting and bilateral papilledema. The increased intracranial pressure was determined by lumbar puncture during which opening pressure of CSF showed above 280 mmH₂O. The chemical and hematological compositions of the CSF were normal. The last criterion was satisfied by the absence of radiological abnormalities in findings of MRI scan.

Although PC is known to be associated with various conditions, the etiology of the disease is unknown. In addition,

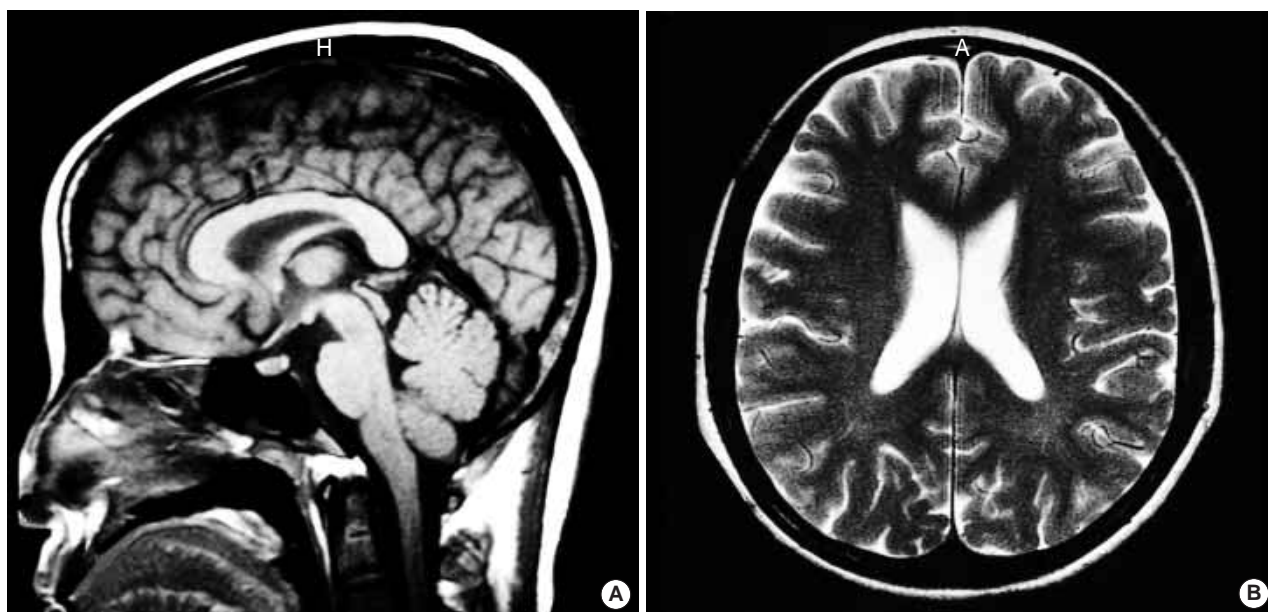


Fig. 1. Brain MRI images (T1-weighted sagittal and T2-weighted axial) show normal sized ventricle and subarachnoid space without space-occupying lesion.

diverse therapeutic agents, including vitamin A, tetracycline, nalidixic nitrofurantoin, sulfa derivatives, lithium, phenytoin and indomethacin, have been used in this disorder. The systemic conditions of PC are primarily endocrinological abnormalities such as hypo- and hyperthyroidism, hypoparathyroidism, adrenal insufficiency, Cushing's syndrome and oral contraceptives. Pregnancy, obesity (particularly among women), anemia, hypertension and rare cases of sarcoidosis were reported to be associated with PC (15). SLE is one of the enlisted diseases underlying PC, albeit not common (5-11, 14-19).

The following conditions rendered it reasonable think that SLE was attributable to PC in this patient: she did not have menstrual irregularities or endocrinopathies; she was not on contraceptive pills, antibiotics or vitamins, which are known to induce PC. Corticosteroid therapy could not be implicated because this patient was receiving only low dose of prednisolone at the time of diagnosis of PC.

The pathophysiologic mechanism of PC in SLE remains unknown. It is not clear whether the overproduction of CSF, relative absorptive failure of CSF, or increased cerebral blood flow is associated with the pathogenesis of PC in SLE (16). On the other hand, PC in SLE has been attributed to cerebral venous thrombosis in some cases. The patients in these cases had lupus anticoagulant or anticardiolipin antibodies that were assumed to induce a hypercoagulable state that eventuated in cerebral venous thrombosis (6, 9, 17). Thrombotic obliteration of the arteriolar or venous vascular bed might have affected the arachnoid villi and eventually have caused PC in this patient. However, vasculitis, immune complex precipitation or even direct antibody injury may all result in a similar dysfunction (11). In this patient, the test for serum anticardiolipin antibody and lupus anticoagulant test were negative and evidence of sagittal or other venous or arterial thromboses was not demonstrated in MRI scans. The laboratory and radiological findings along with the gradual onset and progression of PC-related symptoms in this patient favored the latter hypothesis as a causative condition.

SLE-associated PC usually indicates a favorable outcome. The most critical sequela of PC is the permanent visual impairment. In a recent prospective study (18), a large proportion of patients were found to have some visual loss including blind spot enlargement in at least one eye on follow-up. Furthermore, recurrent PC (7-11), chronic low-grade papilledema, and death from progressive renal disease have been observed in some patients (19). Corticosteroid is currently the mainstay of the treatment of PC in patients with SLE (19), and acetazolamide, intravenous mannitol and furosemide are also used. In addition, plasmapheresis, azathioprine, cyclophosphamide and other immunosuppressive agents can be used in the treatment of such patients.

In conclusion, we described a 30-yr-old female patient with SLE who presented with second attack of severe intractable headache. She was diagnosed recurrent PC, as a neuropsychy-

chiatric SLE. Headache is the commonest symptom encountered in patients with neuropsychiatric SLE and is attributable to different syndromes. It is important to define the cause of headache in patients with SLE, since there is no typical pattern in the benign headache of lupus. Although the underlying mechanisms of the cerebral manifestations are not always readily identifiable, we suggest that PC should be included in the spectrum of neuropsychiatric manifestations during the course of SLE.

REFERENCES

1. Isenberg DA, Meyrick-Thomas D, Snaith ML, McKeran RO, Royston JP. *A study of migraine in systemic lupus erythematosus. Ann Rheum Dis* 1982; 41: 30-2.
2. Kovacs JA, Urowitz MB, Gladman DD. *Dilemmas in neuropsychiatric lupus. Rheum Dis Clin North Am* 1993; 19: 795-814.
3. Amit M, Molad Y, Levy O, Wysenbeek AJ. *Headache in systemic lupus erythematosus and its relation to other disease manifestations. Clin Exp Rheumatol* 1999; 17: 467-70.
4. Bettman JW Jr, Daroff RB, Sanders MD, Joyt WF. *Papilledema and asymptomatic intracranial hypertension in systemic lupus erythematosus. A fluorescein angiographic study of resolving papilledema. Arch Ophthalmol* 1968; 80: 189-93.
5. Edmund K, Patrick C. *Pseudotumor cerebri in systemic lupus erythematosus. J Rheumatol* 1989; 16: 113-5.
6. Kaplan R, Springate G, Feld L, Cohen M. *Pseudotumor cerebri associated with cerebral venous sinus thrombosis, internal jugular vein thrombosis, and systemic lupus erythematosus. J Pediatr* 1985; 107: 266-8.
7. Silberg DH, Laties SS. *Increased pressure in disseminated lupus erythematosus. Arch Neurol* 1973; 29: 88-90.
8. Parnass SM, Goodwin JA, Patel DV, Levinson DJ, Reinhard JD. *Dural sinus thrombosis: a mechanism for pseudotumor cerebri in systemic lupus erythematosus. J Rheumatol* 1987; 14: 152-5.
9. Chevalier X, de Bandt M, Bourgeois P, Kahn MF. *Primary Sjögren's syndrome preceding the presentation of systemic lupus erythematosus as a benign intracranial hypertension syndrome. Ann Rheum Dis* 1992; 51: 808-9.
10. Ogura N, Atsumi T, Sagawa A, Jodo S, Amasaki Y, Nakabayashi T, Watanabe I, Mukai M, Fujisaku A, Nakagawa S. *Systemic lupus erythematosus associated with benign intracranial hypertension: a case report. Ryumachi* 1992; 32: 66-72.
11. Horoshovski D, Amital H, Katz M, Shoenfeld Y. *Pseudotumour cerebri in SLE. Clin Rheumatol* 1995; 14: 708-10.
12. Tan EM, Cohen AS, Fries JF, Masi AT, McShane DJ, Rothfield NF, Schaller JG, Talal N, Winchester RJ. *The 1982 revised criteria for the classification of systemic lupus erythematosus. Arthritis Rheum* 1982; 25: 1271-7.
13. Hebra F, Kaposi M. *On diseases of the skin including the exanthemata. Vol. IV. Tay W, editor/translator. London: The New Sydenham Society* 1875: 14-47.
14. Asherson RA, Denburg SD, Denburg JA, Carbotte RM, Futrell N.

- Current concepts of neuropsychiatric systemic lupus erythematosus. Postgrad Med J 1993; 69: 602-8.*
15. Ahlskog JE, O'Neill BP. Pseudotumor cerebri. *Ann Intern Med 1982; 97: 249-56.*
 16. Li EK, Ho PCP. Pseudotumor cerebri in systemic lupus erythematosus. *J Rheumatol 1989; 16: 113-6.*
 17. Nampoory MR, Johny KV, Gupta RK, Constandi JN, Nair MP, al-Muzeiri I. Treatable intracranial hypertension in patients with lupus nephritis. *Lupus 1997; 6: 597-602.*
 18. Wall M, George D. Idiopathic intracranial hypertension. A prospective study of 50 patients. *Brain 1991; 114: 155-80.*
 19. Green L, Vinker S, Amital H, Amir T, Bar-Dayyan Y, Levi Y, Schoenfeld Y. Pseudotumor cerebri in systemic lupus erythematosus. *Semin Arthritis Rheum 1995; 25: 103-8.*