

Hanja Alexia with Agraphia After Left Posterior Inferior Temporal Lobe Infarction: A Case Study

Korean written language is composed of ideogram (Hanja) and phonogram (Hangul), as Japanese consists of Kanji (ideogram) and Kana (phonogram). Dissociation between ideogram and phonogram impairment after brain injury has been reported in Japanese, but few in Korean. We report a 64-yr-old right-handed man who showed alexia with agraphia in Hanja but preserved Hangul reading and writing after a left posterior inferior temporal lobe infarction. Interestingly, the patient was an expert in Hanja; he had been a Hanja calligrapher over 40 yr. However, when presented with 65 basic Chinese letters that are taught in elementary school, his responses were slow both in reading (6.3 sec/letter) and writing (8.8 sec/letter). The rate of correct response was 81.5% (53 out of 65 letters) both in reading and writing. The patient's performances were beyond mean-2SD of those of six age-, sex-, and education-matched controls who correctly read 64.7 out of 65 and wrote 62.5 out of 65 letters with a much shorter reaction time (1.3 sec/letter for reading and 4.0 sec/letter for writing). These findings support the notion that ideogram and phonogram can be mediated in different brain regions and Hanja alexia with agraphia in Korean patients can be associated with a left posterior inferior temporal lesion.

Key Words : Alexia; Agraphia; Hanja; Hangul; Kana; Kanji; Chinese letter; Ideogram; Phonogram

Jay C. Kwon, Hyun Jeong Lee,*
Juhee Chin, Young Mi Lee, Hyanghee Kim,
Duk L. Na

Department of Neurology, Samsung Medical Center, Sungkyunkwan University School of Medicine; Department of Neurology, Youngdong Severance Hospital, Yonsei University College of Medicine*, Seoul, Korea

Received : 27 July 2001
Accepted : 5 October 2001

Address for correspondence

Duk L. Na, M.D.
Department of Neurology, Sungkyunkwan University, Samsung Medical Center, 50 Ilwondong, Kangnam-ku, Seoul 135-710, Korea
Tel : +82.2-3410-3591, Fax : +82.2-3410-0052
E-mail : dukna@smc.samsung.co.kr

INTRODUCTION

Very few countries in the world use languages that can be written in both ideogram, a graphic record of a meaning, and phonogram, a graphic record of a sound. Reading or writing impairment of these two written systems after brain damage may provide information about whether or not phonogram and ideogram are mediated in different brain regions.

Many studies of phonogram and ideogram originated from Japanese in which dual orthographic system is employed; Kana (phonograms) and Kanji (ideograms) (1-12). Japanese authors have found a double dissociation between Kana and Kanji impairments in brain-damaged patients and reported that Kanji is processed mainly in left posterior inferior temporal area (4-9). On the contrary, there have been few studies on Korean written language (13, 14), another orthographic system that also uses both phonogram (Hangul) and Chinese ideogram (Hanja). We report a man with alexia and agraphia for Hanja but intact reading and writing for Hangul after a left posterior inferior temporal lobe infarction. Interestingly, the patient was an expert in Hanja as he had been a calligrapher over 40 years.

MATERIALS AND METHODS

Case Report

A 64-yr-old right-handed man was admitted to our department because of a blurred vision and paresthesia on the right extremities. Three days before admission, on waking up, he felt narrowed right visual field with dizziness and headache in addition to paresthesia and clumsiness in the right extremities. On the next morning, he noticed a weakness on his right arm and could not remember the names of his close friends.

His past medical history revealed a gout 13 yr before, a pneumonia 10 yr before, and hypertension for several years for which he had been on antihypertensive drugs intermittently. The history of diabetes mellitus or episodes of stroke was denied. He was a social drinker and non-smoker. He was educated for 12 yr and learned Hanja since childhood. He had been a Hanja calligrapher over 40 yr and he once received an award in a famous national calligraphy contest.

On physical examination, blood pressure was 150/100 mmHg but heart beat was regular. He was fully conscious and oriented to time, place, and person. He scored 27/30 on

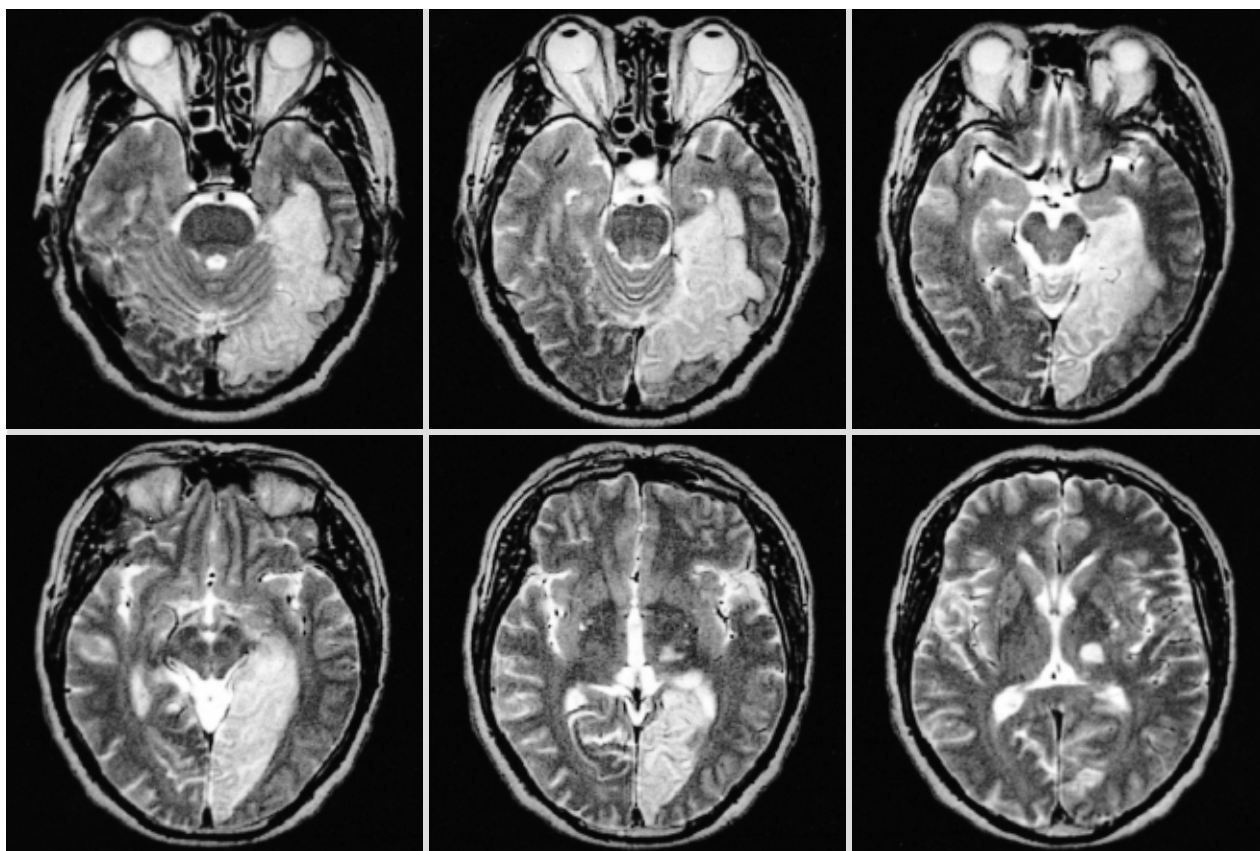


Fig. 1. T2-axial brain MR images show an infarct involving the left lingual, fusiform, and parahippocampal gyri and a lacune in the left thalamus.

the Korean-version of Mini-Mental State Examination; he failed to recall 3 words presented a few minutes earlier. Cranial nerve examination showed right homonymous hemianopsia. Other neurologic examinations were significant for hypesthesia in the right limbs and hyperreflexia with Babinski sign on the right. Motor power and cerebellar function were intact and no carotid bruits were present.

Blood tests including VDRL, and coagulation battery were within normal ranges except for blood sugar before meal (122 mg/dL) and 2 hr after meal (140 mg/dL), and HbA1c (7.10%), which indicated mild diabetes mellitus. Echocardiography showed dilated cardiomyopathy, while 24-hr holter monitoring was normal. Brain magnetic resonance imaging (MRI) performed 2 days after admission disclosed an infarct involving left lingual and fusiform gyri and a lacune in the left thalamus (Fig. 1).

The Korean-version of the Western Aphasia Battery (15) was performed 3 days after admission. Spontaneous speech was fluent (9/10) despite intermittent hesitancy and paraphasia. Comprehension (9.3/10) and repetition (9.3/10) of spoken language were functional. However, his naming ability was moderately impaired (6.4/10). To evaluate naming function in more detail, the Korean-version of the Boston Naming

Test (K-BNT) (16) was performed and he marked only 17/60, which was below 1 percentile. Naming difficulty was also extended to proper nouns; he even failed to name his grandsons and granddaughters. Collectively, his language abnormalities were consistent with anomic aphasia.

Hangul can be arrayed vertically as well as horizontally. When presented with paragraphs, the patient preferred reading paragraphs with vertical orientation to those with horizontal orientation, which was probably explained by his right homonymous hemianopsia and neglect dyslexia. Otherwise his reading performance for Hangul was flawless. The patient was also excellent in writing Hangul except that he occasionally made regularization errors in writing words with irregular orthography (e.g. '값어치' was written as '가버치').

Neuropsychological assessment was performed eight days after admission and the results are presented in Table 1. In summary, the patient had mild memory disturbance and decreased semantic word fluency in addition to naming difficulty. Other test not presented in Table 1 was a test for color agnosia. He could not name 7 out of 10 different colors but when a pair of the 10 colors were presented randomly on the table and asked to match them, he had no impairment. Thus he was considered to have color anomia rather than color

Table 1. Results of neuropsychologic tests

Cognitive domain/ neuropsychologic tests	Results
Attention	
Digit span	
Forward; backward	6; 2 (47% ile; 4% ile)
Language & related functions	
K-WAB*	
Fluency	9/10
Auditory comprehension	9.3/10
Repetition	9.3/10
Naming	6.4/10
K-BNT [†]	17/60 (5 days after the onset) (<1% ile)
	24/60 (11 days after the onset) (<1% ile)
Reading/Writing (Hangul)	Normal
Calculation	Normal
Finger naming	Normal
Right-left orientation	Normal
Praxis: pantomiming gesture	Normal
Visuospatial	
Copy of Rey-Osterrieth complex figure	36/36
Memory	
Hopkins Verbal Learning Test	
Free recall (1st; 2nd; 3rd trial)	0/12; 3/12; 3/12 (sum 6/36, <1% ile)
20-minute delayed recall	0/12 (<1% ile)
Frontal/executive	
Fist-edge-palm	Normal
Luria loop/alternating square & triangle	Normal
Controlled oral word association	
Animal; supermarket items	6; 3 (sum 9, <1% ile)
K-MMSE [‡]	27/30

*K-WAB: Korean version of the Western Aphasia Battery. [†]K-BNT: Korean version of the Boston Naming Test. [‡]K-MMSE: Korean version of the Mini-Mental State Examination.

agnosia. Tests for prosopagnosia or object visual agnosia were not performed.

Hanja reading and writing

The patient and six age- and education- matched control subjects received Hanja reading and writing tests as follows. Controls consisted of only men who had no previous neurologic or psychiatric illness. They were aged 69.0 ± 13.1 yr (range, 55 to 88) and educated for 12.5 ± 3.8 yr.

For Hanja reading, we presented 65 Chinese letters that were selected from 100 basic letters taught in elementary school (Appendix). Each letter was printed in black with a font size 170 (5 × 5 cm) on a white card (10.5 × 10 cm in size). The examiner measured the time in sec from the presentation of the card to the subject's response. If the subject responded "I don't know" or if 10 sec elapsed before the

Table 2. Results of Hanja reading and writing in the patient and controls

	Hanja reading		Hanja writing	
	Correct response (%)	Response time per letter (sec)	Correct response (%)	Response time per letter (sec)
Patient	53/65 (81.5%)	6.3	53/65 (81.5%)	8.8
Controls (n=6)	99.5±0.8 (%)	1.3±0.2	96.3±3.6 (%)	4.0±0.8

response, it was considered incorrect.

Hanja reading was followed by Hanja writing that was performed with the same 65 letters used in reading. When given the meaning and the sound of the letter (for instance, 'east' and /dong/ for '東'), the subject was to write it down. As in the reading tasks, if the subject responded "I don't know" or if 10 sec elapsed before the response, it was considered incorrect. The examiner also measured the reaction time in seconds from the presence of card to the completion of subject's writing.

RESULTS

Control subjects made errors only in 0.3 letters (range, 0-1) out of 65 letters in Hanja reading (correct response rate, 99.5 ± 0.8%). The reaction time per letter was 1.3 ± 0.2 (sec). Errors in Hanja writing were observed in 2.5 letters (range, 0-5) out of 65 letters (correct response rate, 96.3 (3.6%). The reaction time per letter was 4.0 ± 0.8 (sec) (Table 2).

The patient misread or made "don't know" response in 12 letters out of 65 letters (correct response rate, 81.5%), which exceeded mean-2SD of the control subjects' performance. The mean reaction time for reading was 6.31 sec per letter, which also exceeded the reference range. In Hanja writing, the patient also made errors in 12 letters out of the 65 letters. Although the number of errors was coincidentally the same as in reading, the errors were not observed in the same letters. It took average 8.8 sec per letter for the patient to write Hanja, which was also out of reference range (Table 2).

DISCUSSION

Our patient, after a left posterior inferior temporal lobe infarction, showed impairments in Hanja reading and writing. In contrast, Hangul reading and writing were intact. It may not be easy to determine the presence of Hanja impairment in Korean patients after a brain injury because ordinary Korean people do not use Hanja as much as they used to. Therefore it is difficult to evaluate the premorbid state of Hanja ability. Also, there is a wide variation in Hanja reading and writing capability according to the patient's educational level. Interestingly, our patient was an expert for Hanja, who

had been a Hanja calligrapher for 40 yr. Nevertheless, he could not correctly read 12 out of basic 65 Hanja letters taught in elementary school. With the same letters, he also could not write 12 out of 65 letters. In order to substantiate the patient's results, we presented the same letters to 6 age- and education- matched control subjects. The controls made errors only in 0.3 out of 65 letters in reading and 2.5 out of 65 letters. The reaction times for reading and writing Hanja were significantly longer in the patient than in controls.

Normally Hanja reading is known to be processed by semantic as well as lexical route. Hanja alexia results from a damage in the lexical route and different behaviors would occur according to the presence or absence of disruption of semantic route. That is, patients with preserved semantic route could tell the meaning of the Chinese letters (Hanja) even if they could not read them; patients with disruption of semantic route could not even tell the meaning of the letters. Unfortunately, we did not specifically investigate whether or not the semantic route was damaged in our patient. But on a retrospective review of the videotape, our patient occasionally reported the meaning of the letters which he could not read them (in 4 out of 12 incorrectly read letters).

Studies about reading and writing impairments of Chinese letter were mostly originated from Japan (1-11). Japanese investigators reported many cases that showed a greater impairment of reading or writing in Kanji than in Kana. On the contrary, other studies demonstrated the opposite pattern, which indicates a double dissociation between Kana and Kanji processing (12, 17). Other investigators further showed that Kanji alexia can be dissociated from Kanji agraphia (3-5, 9). Our patient showed an impairment for both reading and writing of Hanja. If tests had been performed with more complex Chinese letters, we might have found a dissociation between reading and writing. However, this could not be done because the patient refused further tests.

Multiple brain regions have been reported to be associated with dyslexia and dysgraphia of Kanji. According to the Medline search, out of the 27 reported cases of dyslexia or dysgraphia of Kanji, 15 cases had lesions in the left posterior inferior temporal area, 6 cases in the frontal area, 2 cases in the parietal area, 2 cases in the thalamus, 1 case in the frontoparietal area, and 1 case in the superior temporal area. Thus, the critical neuroanatomical structure associated with the presence of impairment of Chinese letters seems to be the left posterior inferior temporal area, which is consistent with the result of our case.

Functional activation studies using MRI or positron emission tomography (PET) are new noninvasive methods for mapping human brain functions. Recently, Nakamura *et al.* reported a functional MRI study that investigated cerebral activation during Kanji writing (18). They demonstrated an activation in the left posterior inferior temporal area, reproducing the results of the previous studies. Compared to this study, the Chinese investigators obtained a rather larger extent

of activation during Chinese letter reading; the left frontal, posterior inferior temporal area, right occipital, and parietal areas and cerebellum (19, 20). A functional MRI study has been also performed in Korea, which investigated Hangul and Hanja processing (21). The authors observed that, compared to Hanja reading, Hangul reading activated bilateral supramarginal gyri. On the other hand Hanja reading, compared to Hangul reading, activated bilateral fusiform gyri, as in studies from Japan and China, but interestingly, a greater activation was observed in the right fusiform gyri than in the left. Different brain regions might have been activated, although the same Chinese letters are used in Korea, Japan, and China, depending on the factors including the frequency of their use in everyday activities, age at the learning of Chinese letters, and whether the Chinese is primary or secondary language.

How a dual system of phonogram and ideogram is processed in the brain is not only of scientific interest but of practical concern in terms of rehabilitation. If one system is damaged, the rehabilitation can take place via the other system. Further studies about Hangul and Hanja are needed in a large number of cases.

REFERENCES

1. Sakurai Y, Takeuchi S, Takada T, Horiuchi E, Nakase H, Sakuta M. *Alexia caused by a fusiform or posterior inferior temporal lesion. J Neurol Sci* 2000; 178: 42-51.
2. Kawahata N, Nagata K, Shishido F. *Alexia with agraphia due to the left posterior inferior temporal lobe lesion-neuropsychological analysis and its pathogenetic mechanisms. Brain Lang* 1988; 33: 296-310.
3. Kawahata N, Tagawa K, Hirata Y, Nagata K, Shishido F. [A case of alexia with agraphia due to infarction in the left inferior-posterior temporal lobe]. *Rinsho Shinkeigaku* 1987; 27: 420-7. Japanese.
4. Mochizuki H, Ohtomo R. *Pure alexia in Japanese and agraphia without alexia in kanji. The ability dissociation between reading and writing in kanji vs kana. Arch Neurol* 1988; 45: 1157-9.
5. Iwata M. *Neural mechanism of reading and writing in the Japanese language. Funct Neurol* 1986; 1: 43-52.
6. Kawamura M, Hirayama K, Hasegawa K, Takahashi N, Yamaura A. *Alexia with agraphia of Kanji (Japanese morphograms). J Neurol Neurosurg Psychiatry* 1987; 50: 1125-9.
7. Jibiki I, Yamaguchi N. *The Gogi (word-meaning) syndrome with impaired Kanji processing: alexia with agraphia. Brain Lang* 1993; 45: 61-9.
8. Sugishita M, Otomo K, Kabe S, Yunoki K. *A critical appraisal of neuropsychological correlates of Japanese ideogram (Kanji) and phonogram (Kana) reading. Brain* 1992; 115: 1563-85.
9. Soma Y, Sugishita M, Kitamura K, Maruyama S, Imanaga H. *Lexical agraphia in the Japanese language. Pure agraphia for Kanji due to left posteroinferior temporal lesions. Brain* 1989; 112: 1549-61.
10. Sato M, Yamamoto Y, Shimazaki S, Watanabe K. [A case of alexia with agraphia following left occipital lobe]. *No To Shinkei* 1987; 39:

- 215-20. Japanese.
11. Shiota J, Kawamura M, Isono O, Hirayama K. [Alexia with agraphia produced by localized infarction in the inferior posterior region of the left temporal lobe]. *No To Shinkei* 1986; 38: 1051-5. Japanese.
 12. Tanaka Y, Yamadori A, Murata S. Selective Kana agraphia: a case report. *Cortex* 1987; 23: 679-84.
 13. Kim H, Na DL. Dissociation of pure Korean words and Chinese-derivative words in phonological dysgraphia. *Brain Lang* 2000; 74: 134-7.
 14. Kwon MS, Park HS, Shim HS, Nam KC, Lee JH. Dual systems of Korean reading: presentation of cases with selective impairment of Hanja or Hangul after brain damage. *Proceedings in The Korean Academy of Speech-language pathology and audiology* 2000;188-93.
 15. Kim H, Na DL. *PARADISE·Korean version-the Western Aphasia Battery*. Seoul: Paradise welfare foundation; 2001.
 16. Kim H, Na DL. Normative data on the Korean version of the Boston Naming Test. *J Clin Exp Neuropsychol* 1999; 21: 127-33.
 17. Grossman M, Nakada T. A letter is a letter is a letter: pure alexia for kana. *Neurology* 2001; 56: 699-701.
 18. Nakamura K, Honda M, Okada T, Hanakawa T, Toma K, Fukuyama H, Konishi J, Shibasaki H. Participation of the left posterior inferior temporal cortex in writing and mental recall of kanji orthography: a functional MRI study. *Brain* 2000; 123: 954-6.
 19. Chee MW, Weekes B, Lee KM, Soon CS, Schreiber A, Hoon JJ, Chee M. Overlap and dissociation of semantic processing of Chinese characters, English words, and pictures: evidence from fMRI. *Neuroimage* 2000; 12: 392-403.
 20. Tan LH, Spinks JA, Gao JH, Liu HL, Perfetti CA, Xiong J, Stofer KA, Pu Y, Liu Y, Fox PT. Brain activation in the processing of Chinese characters and words: a functional MRI study. *Hum Brain Mapp* 2000; 10: 16-27.
 21. Lee KM. Functional MRI comparison between reading ideographic and phonographic scripts. Abstract presented in the 6th Annual Meeting of Cognitive Neuroscience Society, San Francisco, U.S.A. 2000: 4.

Appendix. Stimuli used in Hanja reading and writing

用	生	十	工	火	石	三	木	田	下	七	小	忠	母	東	北	出
月	父	同	白	正	五	兄	門	有	力	男	主	女	右	內	左	四
目	臣	口	兩	上	食	花	風	市	高	世	時	川	王	亡	名	子
民	南	長	雨	車	化	少	水	九	中	江	山	心	老			