

Outcome of Postoperative Intratumoral Bleomycin Injection for Cystic Craniopharyngioma

Total excision is a treatment of choice in preventing the relapse of craniopharyngioma, but for tumors involving an extensive area, it is often associated with an increased risk of complications. We have performed a partial or subtotal tumor removal followed by repeated injection of bleomycin into the remaining tumor through a subcutaneous reservoir as postoperative adjuvant therapy. A retrospective review of clinical, radiological, and surgical data was performed for 10 patients (5 males and 5 females; age, 3-65 yr; follow-up duration, 12-79 months) with cystic craniopharyngiomas. The measurements of lactate dehydrogenase (LDH) level at each aspiration were performed. The shrinkage and/or stabilization of tumor was initially noted in all cases. The recurrence of tumor was seen in 4 cases (40%). The decreased or increased level of LDH was interpreted as tumor shrinkage or recurrence, respectively. The transient toxic reactions were observed in 3 patients (30%). Our study demonstrates that postoperative bleomycin injection for cystic craniopharyngioma, although does not appear to eradicate the tumor, decreases and stabilizes the tumor size, when used as an adjuvant therapy in young patients.

Key Words : Craniopharyngioma; Bleomycin; Cysts; Lactate Dehydrogenase

Dong Hyuk Park, Jung Yul Park,
Joo Han Kim, Yong Gu Chung,
Hoon Kap Lee, Ki Chan Lee,
Jung Keun Suh

Department of Neurosurgery, College of Medicine,
Korea University, Seoul, Korea

Received : 8 August 2001
Accepted : 13 November 2001

Address for correspondence

Jung Yul Park, M.D.
Department of Neurosurgery, College of Medicine,
Korea University, 126-1 Anam-dong, 5-Ga,
Sungbuk-gu, Seoul 136-705, Korea
Tel : +82-2-920-5712, Fax : +82-2-929-0629
E-mail : jypark@kumc.or.kr

INTRODUCTION

Craniopharyngiomas are histologically benign tumors that originate from epithelial rests or from areas of squamous metaplasia related to the hypophysis. Despite recent advances in aggressive and conservative approaches to these tumors and their benign histological nature, they are associated with a significant morbidity.

There are two major opposing views as to the surgical approach to these lesions (1). The ideal approach is a total excision, owing to the fact that a partial or subtotal excision will bring sooner or later to a recurrence. However, because a total excision is not always possible in every case and often results in major deficits such as hypothalamic dysfunction and adjacent nerve injury, a palliative operation in combination with radiotherapy or chemotherapy may be preferred.

In 1985, Takahashi et al. demonstrated a reduction of the cystic portion in four of seven children with cystic craniopharyngioma after direct injection of bleomycin into the cyst (1). Ever since, this result has been confirmed by several authors (2-7). The rationales for application of intratumoral bleomycin injection as an adjuvant therapy for craniopharyngioma are: 1) in most cases, the tumor is associated with a cyst; 2) it is an epithelial tumor; 3) although the ideal treatment for craniopharyngioma is a complete excision, total removal is not

possible in many cases, where the tumor locates adjacent to the hypothalamus, pituitary gland, optic apparatus, or intracranial artery causing adhesion; 4) although the remaining tumor may be treated with external or interstitial irradiation, this may cause serious side effects; and 5) intracystic application of bleomycin may provide a long duration of effective concentration.

Here, we report long-term results of intratumoral bleomycin injection for craniopharyngioma in our cases, together with a review of literature, focusing mainly on the feasibility and limitations of the modality.

MATERIALS AND METHODS

Patients

A total of 10 patients (5 males and 5 females; age range, 3-65 yr; mean age, 30.2 yr) who were treated for cystic craniopharyngioma with partial or subtotal tumor removal and postoperative intratumoral injections of bleomycin from 1992 to 1999 was included. The follow-up duration ranged from 12 to 79 months (mean, 33.9 months).

All patients were evaluated for endocrine dysfunction with baseline hormonal profile. Headache and visual disturbance

resulting from the mass effect were the most common clinical findings, whereas personality change and disorientation were observed less frequently.

Methods

The neuro-radiological assessment and endocrine study were performed before and after surgical treatment. Because the tumor, of a cystic or mixed type, adhered to the surrounding structures, only a partial or subtotal removal of tumor was performed. For the cases with only cystic type, stereotactic surgery was performed under general anesthesia. The cyst was punctured and a catheter was inserted into the cyst using the sliding stylets of the stereotactic system. A side-inlet reservoir (Ommaya reservoir) was attached to the catheter, and replaced under the skin. Cytological examination of the cyst fluid revealed that these tumors were craniopharyngiomas. However, for the mixed type, solid portions were surgically excised much as possible to prevent the recurrence from these regions and to establish the histological diagnosis, while the remaining cystic portions were left intact. A silastic catheter was then inserted into the center of cyst and connected with Ommaya reservoir percutaneously. Bleomycin was injected repeatedly through a subcutaneous Ommaya reservoir firmly connected to a catheter placed in the cystic portion after operations. The protocol of bleomycin injection was mainly adopted from Takahashi et al. (1) with minor modifications. Briefly, the administration of bleomycin started 10-15 days after operation. This time interval was reported to be sufficient to establish the secured position without any leakage (1). However, each case was confirmed of radiologic control (injection of contrast into the cyst) which demonstrated the absence of any leakage from cyst. The intervals of each bleomycin injection were 2-7 days and the dosage of bleomycin was 2-5 mg in average. Bleomycin was delivered after aspiration of 2-6 mL of cystic fluid. The injection was performed slowly and discontinued if side effects (hypersomnia, mental change, and visual disturbance, etc) occurred.

The total dose was 15-180 mg. The measurements of lactate dehydrogenase (LDH) at each aspiration were compared. Shunt placement was required in some patients for the treatment of hydrocephalus at the time of initial resection or during follow-up period.

RESULTS

Table 1 summarizes the clinical results of the ten patients. Initially, the remission (shrinkage or stabilization of tumor size) was demonstrated in all patients by CT or MRI studies compared with preoperation state (Fig. 1-4). Finally, for the functional outcome, eight patients returned to a full social life successfully after treatment for follow-up period. Recurrence was seen in four (40%) patients during follow-up, all of these having mixed type. These patients underwent reoperations (partial or subtotal removal) and two of them received adjunctive radiotherapy. The second intratumoral bleomycin chemotherapy was done after reoperation in one patient. Another patient died after reoperation due to meningitis and fulminant pneumonia. The mean time to progression (interval from initial remission to recurrence) of these 4 patients was 16.3 months. After 6 yr of follow-up, there was one patient kept in a bed-ridden state after the first cycle of chemotherapy. This was considered be a toxic reaction of bleomycin.

Repeated intratumoral injection of bleomycin brought to a gradual clearing in coloration of the cystic fluid and a decrease in LDH activity, especially the L₄ and L₅ fractions, except of two cases. In these two cases, the LDH activity was initially decreased and the L₄ and L₅ fractions were nearly flat at first 2 months, however, the activity increased to 1,000-2,000 units and the L₄ and L₅ fractions were also elevated progressively. Despite these findings, there was no recurrence in these cases based on radiologic studies. In recurred cases, LDH activity was increased up to 3,000 units along with elevations of L₄ and L₅ fractions, compared with the decreased LDH activity and normal levels of L₄ and L₅ fractions before

Table 1. Summary of clinical cases (n=10)

Patient	Age (yr), Sex	Clinical findings	Final functional outcome	Follow-up period (mos)	Toxic reaction	LDH level	Recur/Hydro	TTP (mos)
1	4, F	Gait disturbance, nystagmus	good	30	-	< 500	-/-	
2	14, M	Hemiparesis, short stature	poor	79	?	< 2,000	-/-	
3	11, F	Drowsiness, hyperprolactinemia	good	60	-	< 500	-/+	
4	17, M	Personality change, incontinence, ataxia	good	18	visual disturbance	> 3,000	+/+	6
5	65, M	Incontinence, disorientation	dead	13	cerebellar infarction	> 3,000	+/+	12
6	65, F	General weakness, hemianopsia	good	12	-	< 1,000	-/-	
7	35, F	Headache, visual disturbance	good	26	hypersomnia memory impairment	< 1,000	-/-	
8	47, M	Gait disturbance, papilledema	good	40	-	> 3,000	+/+	25
9	41, F	Headache, personality change	good	28	transient mental change	> 3,000	+/+	22
10	3, M	Hemiparesis	good	33	-	< 2,000	-/-	

M: Male, F: Female, Good: normal independent functioning, Poor: bed ridden, Recur: recurrence, Hydro: hydrocephalus, DI: diabetes insipidus, ?: not determined, but may be toxic reaction, TTP: time to progression.

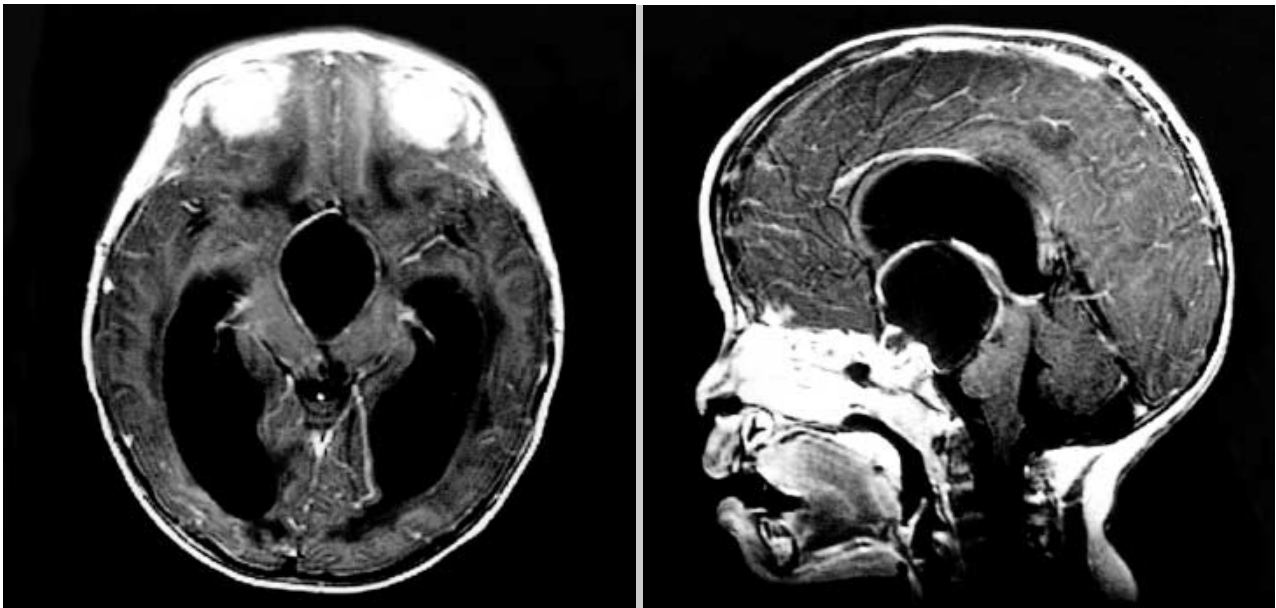


Fig. 1. Preoperative brain MRI in a 3-yr-old boy who presented with right hemiparesis (Patient No. 10).

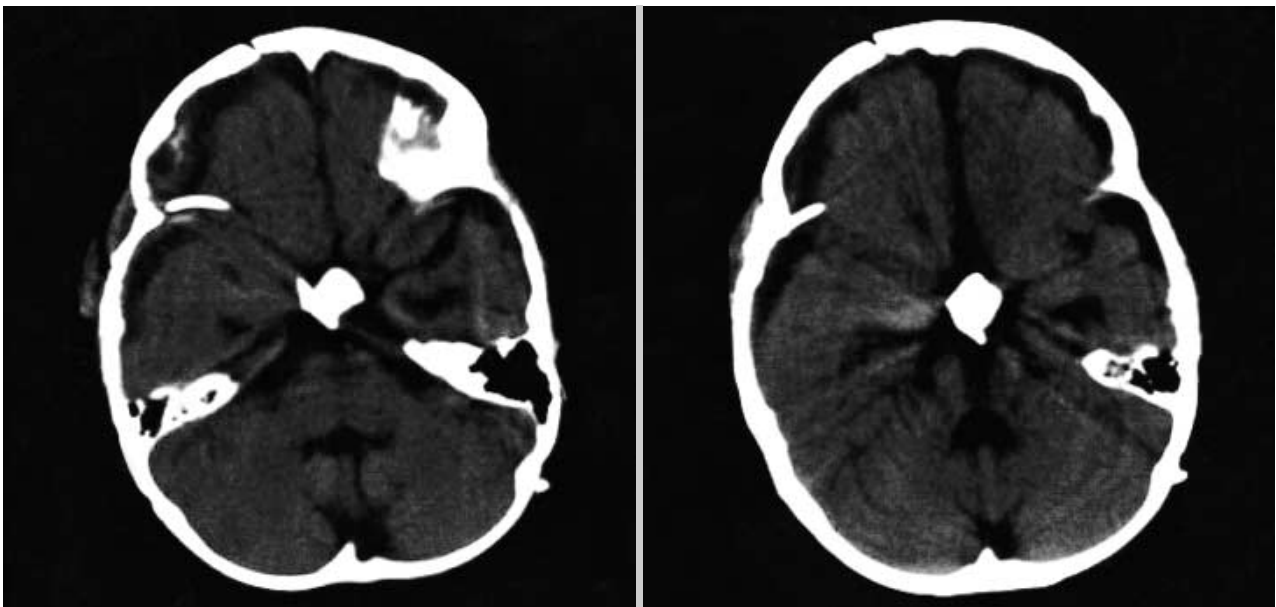


Fig. 2. Brain CT taken 20 months after a partial tumor removal and postoperative intracavitary bleomycin injection in Patient No. 10.

recurrence. Therefore, the very high LDH activity with elevation of L_4 and L_5 isozyme fractions can be considered as a marker of recurrence.

Complications from operation and chemotherapy were transient diabetes insipidus in 3 cases (30%), subdural fluid collection in 2 (20%), meningitis in 1 (10%), wound infection in 1 (10%), and toxic reactions such as hypersomnia, mental and personality change, memory impairment and visual disturbance in 3 (30%). One patient developed a cerebellar infarction two months after the administration of bleomycin.

DISCUSSION

Craniopharyngioma is a common benign intracranial tumor occurring in childhood and young adults but may be observed in any age group. Histologically, this tumor exhibits benign stratified epithelium (8). Despite its benign nature, it often causes neurological and endocrinological impairment, or even death, because it may involve such vital structures as the hypothalamus, optic nerves, and pituitary stalk. Hence, optimal therapy for craniopharyngioma is still controversial. Many

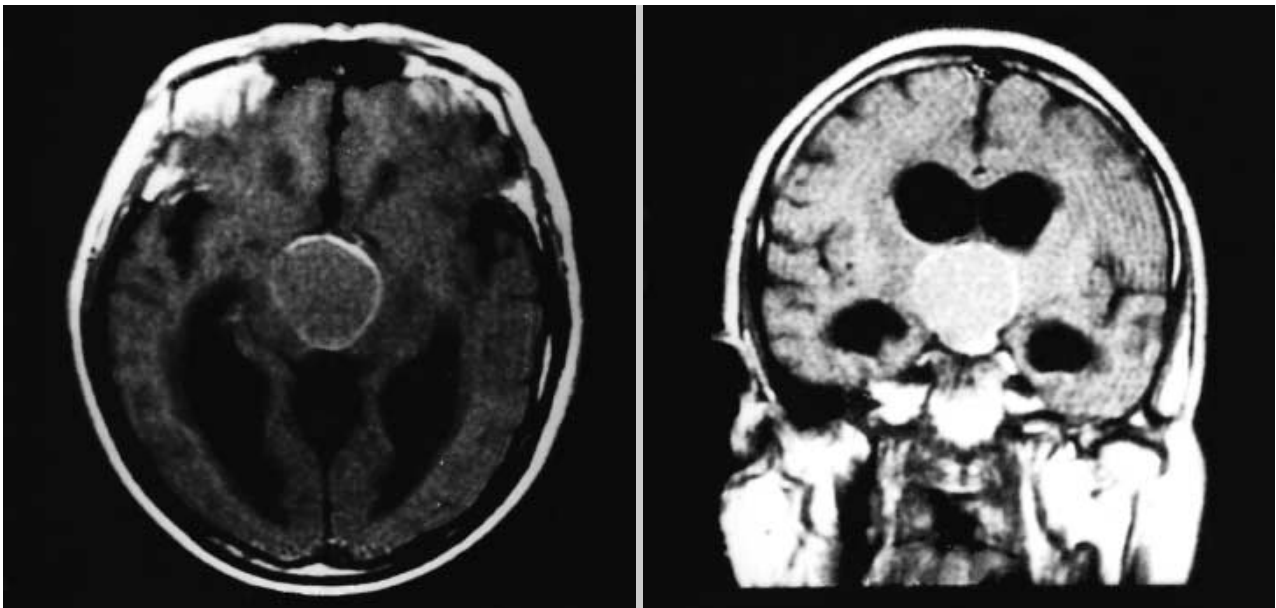


Fig. 3. Preoperative brain MRI in a 65-yr-old female who presented with general weakness and hemianopsia (Patient No. 6).

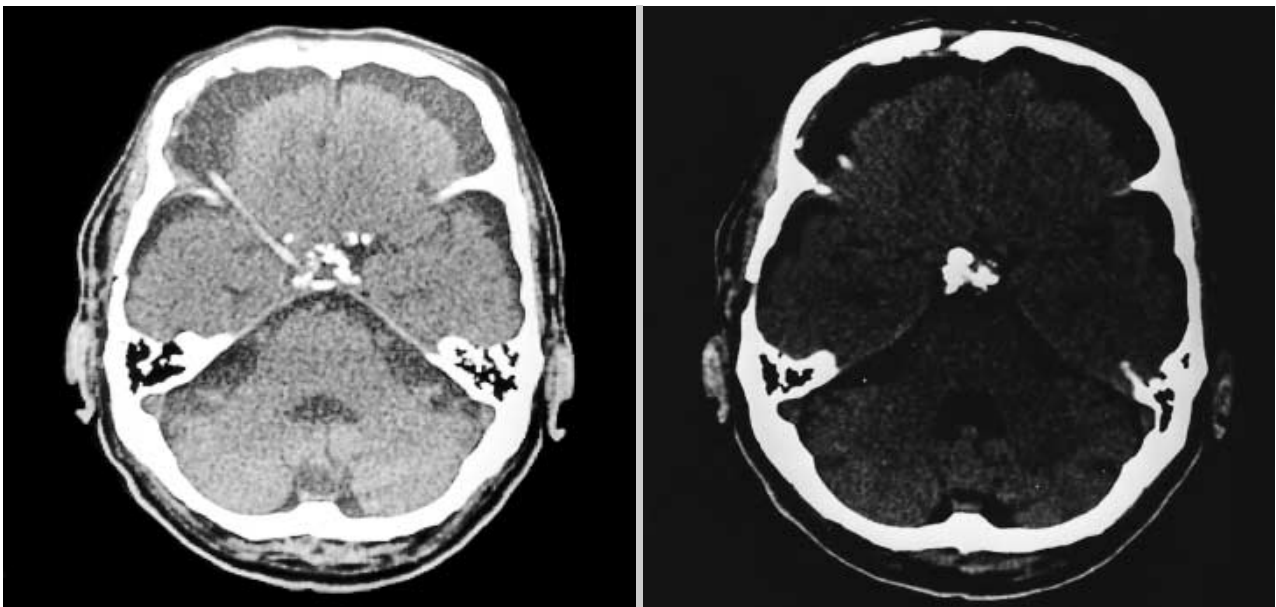


Fig. 4. Brain CT of Patient No. 6 six months after a partial tumor removal and intracavitary bleomycin injection.

neurosurgeons believe that total excision is the only reliable approach to prevent recurrence (9-13). However, even after total resection, the recurrence rate is high in the first 3 yr after surgery and the severity of endocrinological disturbances such as diabetes insipidus and related impairment in growth and development tend to correlate with extensiveness of resection (1, 5). In the series of Yasargil et al., the overall mortality rate and recurrence rate were 17% and 7%, respectively, even after aggressive radical excision of the tumors (14). Some series indicated that the radical surgical intervention was asso-

ciated with a 40% incidence of hypothalamic damage and a 19% incidence of visual impairment (15, 16). These results led other surgeons to favor a conservative surgical approach combined with external radiotherapy, radiosurgery, colloidal radioisotope intracavitary irradiation, and intracavitary bleomycin injection (1-7, 17-19). Radiotherapy may be effective in preventing the recurrence of tumor when total excision is impossible, however, because craniopharyngioma is histologically a benign tumor occurring adjacent to the hypothalamus and pituitary gland, radiotherapy should be considered

carefully, especially in childhood and young adults.

Because these tumors frequently present with cystic components and only 10% of them are completely solid (7, 20), they constitute a special clinical entity with respect to its treatment. Other alternatives to radical surgery in cystic craniopharyngioma have also been described, including drainage techniques and intracavitary injection of radioactive colloidal solutions or chemotherapeutic agents. The antineoplastic properties of bleomycin, an antibiotic produced by *Streptomyces verticillus*, were first discovered by Umezawa and the coworkers in 1966 (21). Its action is based mainly on the inhibition of DNA synthesis and, to a lesser extent, RNA synthesis. Bleomycin also inhibits the synthesis of proteins. It was found to be effective on various types of epithelial tumors and cellular cultures of craniopharyngioma. Several studies demonstrated that intracystic application of bleomycin decreased the secretion of cystic fluid and caused tumor cells to degenerate (1-4). Although there were great variations among the reported series with respect to treatment protocol, size of cyst, timing of injections, number of treatment cycles, and dose of bleomycin, most reports favored the intracavitary bleomycin injection (1-7). Takahashi et al. presented their results of seven patients who had received multiple bleomycin injections (1). Most of the patients with tumors of a cystic type survived, and were able to live a full social life. The recent report by Savas et al. showed that polycystic craniopharyngioma was successfully treated with intracavitary use of bleomycin (6). On the other hand, the patients with tumors of a mixed or solid type experienced tumor recurrence and had poor outcomes. The advantages of bleomycin over the surgical resection of the cystic craniopharyngioma is the simplicity and feasibility of repeating the cycles of bleomycin without additional surgical approach and the possibility of sparing residual endocrinologic functions of the hypophysis (16). Moreover, even in case of recurrence after administration of bleomycin, prior treatment with bleomycin did not interfere or cause any additional difficulties during second operation. The total LDH activity and pattern of its fractions, namely, elevated L₄ and L₅ fractions, were closely related to the tumor malignancy and recurrence (1). In our series, 4 recurrent cases were of a mixed type and had a high level of total LDH (>3,000 units) during follow-up. These results indicate that the local injection of bleomycin is not effective against craniopharyngioma of a mixed or solid type, but is markedly effective against that of a cystic type. Thus, the type of the tumor and LDH level may be considered important prognostic factors.

Interstitial pneumonia, pulmonary fibrosis, fever, scleroderma-like changes in the skin, and alopecia have been reported as adverse reactions to bleomycin administration (6). Theoretically, bleomycin may also pose serious problems involving direct actions of the drug on normal brain tissue if the drug leaks out of the cyst, although only a few such cases have been reported (1, 4, 22, 23). Haisa et al. reported a case

of cystic craniopharyngioma in which toxic effects of bleomycin on the hypothalamus were observed after intracavitary administration of bleomycin (22). We believe that the post-treatment symptoms of three patients of our series, although transient, such as hypersomnia, thermal dysfunction, memory impairment, and behavioral changes, were the toxic effects of bleomycin on the hypothalamus. Broggi et al. reported a patient who experienced a stroke in the middle cerebral artery 3 months after completion of the treatment (4). They proposed that the ischemic lesion might have been mediated by vasospasm secondary to bleomycin leakage in the middle cerebral artery cistern. One patient in our series developed ipsilateral superior cerebellar artery territory infarction 2 months after intracavitary bleomycin injection. It is unclear whether this was directly due to the bleomycin. Despite its potential toxicities, the majority of toxicity were transient and not serious.

The postoperative adjunctive intracavitary bleomycin injection may be recommended when total excision of cystic craniopharyngioma seems dangerous or not possible, especially in young patients. The advantage of its use in young children with cystic craniopharyngioma is that it can control the tumor permitting further growth of the patient until a new treatment is available. Careful and meticulous application and handling of the technique will not only aid in producing better outcome but also will reduce its potential complications.

REFERENCES

1. Takahashi H, Nakazawa S, Shimura T. Evaluation of postoperative intratumoral injection of bleomycin for craniopharyngioma. *J Neurosurg* 1985; 62: 120-7.
2. Broggi G, Franzini A. Bleomycin for cystic craniopharyngioma. *J Neurosurg* 1996; 84: 1080-1.
3. Broggi G, Giorgi C, Franzini A, Leocata F, Riva D. Therapeutic role of intracavitary bleomycin administration in cystic craniopharyngioma. In: Broggi G, editor, *Craniopharyngioma: Surgical Treatment*. Milan: Springer-Verlag, 1995; 113-9.
4. Broggi G, Giorgi C, Franzini A, Servello D, Solero CL. Preliminary results of intracavitary treatment of craniopharyngioma with bleomycin. *J Neurosurg Sci* 1989; 33: 145-8.
5. Cavalheiro S, Sparapani FVDC, Franco JOB, da Silva MC, Braga FM. Use of bleomycin in intratumoral chemotherapy for cystic craniopharyngioma: case report. *J Neurosurg* 1996; 84: 124-6.
6. Savas A, Arasil E, Batay F, Seleuki M, Kanpolat Y. Intracavitary chemotherapy of polycystic craniopharyngioma with bleomycin. *Acta Neurochir (Wien)* 1999; 141: 547-9.
7. Spaziante R, de Divitis E. Drainage techniques for cystic craniopharyngiomas. *Neurosurg Q* 1997; 7: 183-208.
8. Burger PC, Scheithauer BW. Craniopharyngiomas. In: Burger PC, Scheithauer BW, editors, *Tumors of the Central Nervous System, in Atlas of Tumor Pathology*, Washington, DC, Armed Forces Institute

- of Pathology*, 1994; 349-54.
9. Duff JM, Meyer FB, Ilstrup DM, Laws ER Jr, Schleck CD, Scheithauer BW. Long-term outcomes for surgically resected craniopharyngiomas. *Neurosurgery* 2000; 46: 291-305.
 10. Gordy PD, Peet MM, Kahn EA. The surgery of the craniopharyngiomas. *J Neurosurg* 1949; 6: 503-17.
 11. Kahn EA, Gosch HH, Seeger JF. Forty-five years experience with the craniopharyngiomas. *Surg Neurol* 1973; 1: 5-12.
 12. Katz EL. Late results of radical excision of craniopharyngiomas in children. *J Neurosurg* 1975; 42: 86-90.
 13. Matson DD, Crigler JF Jr. Management of craniopharyngioma in childhood. *J Neurosurg* 1969; 30: 377-90.
 14. Yasargil MG, Curcic M, Kis M, Siegenthaler G, Teddy PJ, Roth P. Total removal of craniopharyngiomas: approaches and long-term results in 144 patients. *J Neurosurg* 1990; 73: 3-11.
 15. Brada M, Thomas DG. Craniopharyngioma revisited. *Int J Radiat Oncol Biol Phys* 1993; 27: 471-5.
 16. Hoffman HJ, De Silva M, Humphreys RP, Drake JM, Smith ML, Blasser SI. Aggressive surgical management of craniopharyngiomas in children. *J Neurosurg* 1992; 76: 47-52.
 17. Hoff JT, Patterson RH Jr. Craniopharyngiomas in children and adults. *J Neurosurg* 1972; 36: 299-302.
 18. Shapiro K, Till K, Gtant DN. Craniopharyngiomas in childhood. A rational approach to treatment. *J Neurosurg* 1979; 50: 617-23.
 19. Shillito J Jr. Management of craniopharyngioma in childhood, In: O'Brien MS, editor, *Pediatric Neurological Surgery*. New York: Raven Press, 1978; 59-73.
 20. Lunsford LD, Pollock BE, Kondziolka DS, Levine G, Flickinger JC. Stereotactic options in the management of craniopharyngioma. *Pediatr Neurosurg* 1994; 21(Suppl 1): 90-7.
 21. Umezawa H, Maeda K, Takeuchi Y, Okami Y. New antibiotics, Bleomycin A and B. *J Antibiot (Tokyo)* 1966; 19: 200-9.
 22. Haisa T, Ueki K, Yosida S. Toxic effects of bleomycin on the hypothalamus following its administration into a cystic craniopharyngioma. *Br J Neurosurg* 1994; 8: 747-50.
 23. Sagoh M, Murakami H, Hirose Y, Mayanagi K. Occlusive cerebrovasculopathy after internal radiation and bleomycin therapy for craniopharyngioma: case report. *Neurol Med Chir (Tokyo)* 1997; 37: 920-3.