

A Case of Cerebral Infarct in Combined Antiphospholipid Antibody and Ovarian Hyperstimulation Syndrome

Ovarian hyperstimulation syndrome is a serious complication of ovulation induction and has a diverse clinical spectrum from edema to thromboembolism. Antiphospholipid antibody syndrome, one of the well known hypercoagulable states, can be also manifested as an arterial or venous thrombosis and recurrent spontaneous abortion. Sometimes a patient with antiphospholipid antibodies might not notice a miscarriage and seek for assisted reproduction treatment, which harbors a chance of developing ovarian hyperstimulation syndrome. If this happens, the ovarian hyperstimulation syndrome can exacerbate the thrombotic complication of underlying antiphospholipid antibody syndrome, resulting in a catastrophic vascular event. The authors experienced a case of middle cerebral artery infarct, which developed during ovarian hyperstimulation syndrome in a 33-yr-old woman with a previous history of fetal loss. An elevated titer of anticardiolipin antibodies was noticed and persisted thereafter. The authors suggest screening tests for the presence of antiphospholipid antibodies before controlled ovarian hyperstimulation.

Key Words : Antiphospholipid Syndrome; Ovarian Hyperstimulation Syndrome; Cerebrovascular Disorders

Eun-Jung Koo, Joung-Ho Rha,
Byoung-Ick Lee*, Myeong-Ok Kim†,
Choong-Kun Ha

Departments of Neurology, Obstetrics and Gynecology*, and Rehabilitation Medicine†, Inha University Medical College, Incheon, Korea

Received : 20 July 2001
Accepted : 24 September 2001

Address for correspondence

Joung-Ho Rha, M.D.
Department of Neurology, Inha University Medical College, 7-206, 3-ga, Choong-gu, Shinheung-dong, Incheon 400-103, Korea
Tel : +82-32-890-3418, Fax : +82-32-890-3864
E-mail : jhrha@inha.ac.kr

INTRODUCTION

Antiphospholipid antibodies such as anticardiolipin antibody and lupus anticoagulant are polyclonal and polyclonal antibodies directed against certain phospholipids, and are known to be associated with a hypercoagulable state (1). If a patient with antiphospholipid antibodies develops one of the clinical manifestations of venous or arterial thrombosis, thrombocytopenia, or recurrent miscarriage, the patient can be diagnosed as an antiphospholipid antibody syndrome (APAS). When there are no other underlying diseases such as systemic lupus erythematosus (SLE), it is classified as primary APAS. Sometimes the spontaneous abortion can be unnoticed to the patient, and she may erroneously regard herself as infertile. Whether a patient has just antibodies or APAS, the patient with antiphospholipid antibodies can be a candidate of assisted reproduction treatment such as in vitro fertilization (IVF), which harbors a chance of developing an ovarian hyperstimulation syndrome (OHSS), the most fearful complication of ovulation induction.

OHSS is an iatrogenic, potentially lethal complication during ovulation induction (2). The pathophysiologic hallmark is a massive accumulation of extravascular exudates combined with a profound intravascular volume depletion and hemoconcentration. Its clinical manifestations are diverse from mild edema and oliguria to electrolyte imbalance, massive ovarian enlargement, tense ascites and pleural effusion, renal fail-

ure, and thromboembolic events. Thus if OHSS develops in a hypercoagulable state like APAS, the thrombotic potential will be synergistically enhanced, making a vicious cycle and resulting in serious thromboembolic complications. We describe a case of OHSS complicated by a cerebral infarct in a patient with APAS.

CASE REPORT

A 33-yr-old woman was admitted to a local infertility clinic due to mild dyspnea and progressive abdominal distention. She had been on the course of ovulation induction during IVF, and the embryo transfer was done 11 days before admission. Under an impression of OHSS, she was conservatively treated with balancing fluid and electrolytes and paracentesis with some improvement. Three days after admission, she suddenly developed left hemiparesis and dysarthria, and was transferred to the emergency room of our hospital. She had a past obstetrical history of pregnancy via IVF one year before, which resulted in a spontaneous abortion. At that time, she also experienced mild OHSS and hypertension, which was treated by oral antihypertensive medication.

At the emergency room, her blood pressure was 140/110 mmHg and pulse rate was 110 beats per minute. Physical examination revealed a distended abdomen with ascites. On neurological examination, she showed mild disorientation, dys-

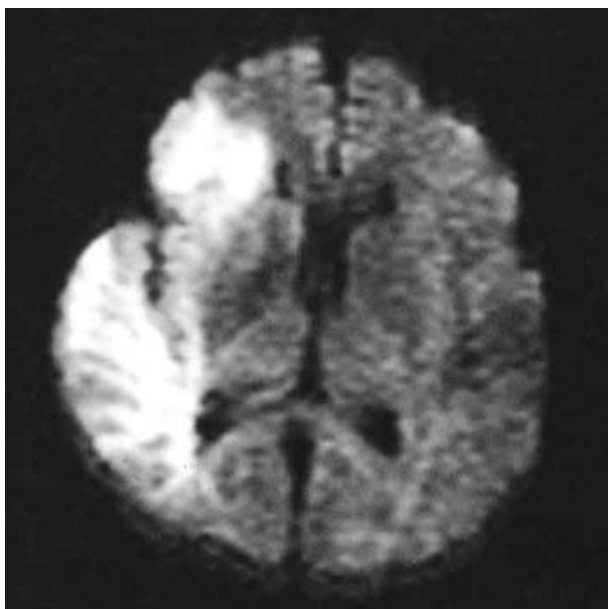


Fig. 1. Brain magnetic resonance diffusion weighted image showing an acute right middle cerebral artery infarct.

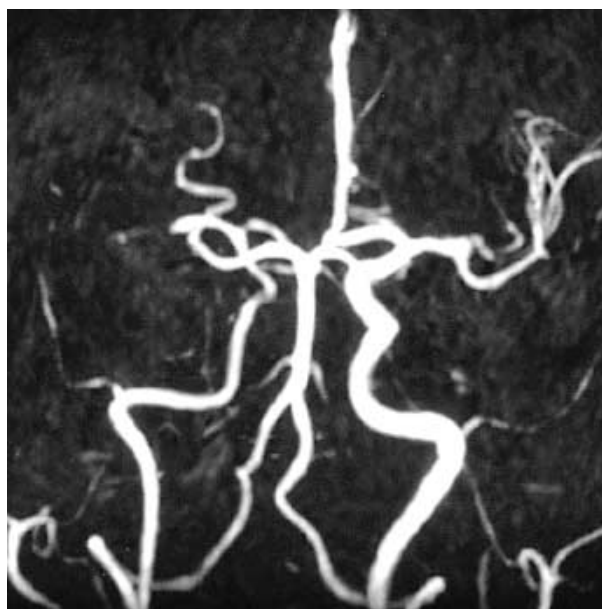


Fig. 2. Brain magnetic resonance angiography demonstrating a right middle cerebral artery occlusion.

arthria, left facial palsy, left visual field defect, and right gaze preponderance. Left-sided hemiparesis, hypesthesia, and hemineglect were also detected. The left hemiparesis later progressed to a complete hemiplegia. With an impression of acute right supratentorial stroke, brain magnetic resonance image (MRI) and angiography (MRA) were done. Brain MRI showed a bright high signal intensity in the right middle cerebral artery (MCA) territory on diffusion-weighted image, suggesting an acute MCA infarct (Fig. 1). MRA demonstrated an occlusion of the right MCA (Fig. 2). Etiologic workup for the young age stroke, including laboratory tests for hypercoagulable state were performed. On complete blood counts, WBC was elevated (14,500/ μ L), and hemoglobin (10.4 g/dL) and hematocrit (32.4%) were slightly decreased. Platelet counts were normal (235,000/ μ L). Mild hyponatremia (130 mEq/L) was detected. On coagulation profile, her prothrombin time was 13.5 sec, activated partial prothrombin time was 22.1 sec, both in normal ranges. However, a decreased level of protein S and elevated anticardiolipin Ig M level were noticed and persisted thereafter (Table 1). Transthoracic echocardiography

did not find any cardiac abnormalities. Abdominal ultrasonography showed ascitic fluid in the pelvis and bilaterally enlarged ovaries with multiple follicles. A test for pregnancy was positive. Her neurologic status was stabilized after a few days but her symptoms of OHSS, such as abdominal pain and dyspnea, worsened despite supportive treatment. The pregnancy was terminated by dilatation and curettage on the 16th hospital day. After termination, her general condition recovered within a few days and a physical therapy was started. After 3 month, the left-sided weakness improved significantly and she could walk with an assisting device by herself.

DISCUSSION

Thromboembolism is a rare but serious complication of OHSS, most of which is venous in origin from the lower extremities (3), and there has been few reports of cerebral infarct complicating OHSS in the literature (4-6). In part of these cases, the laboratory tests for the hypercoagulable state including antiphospholipid antibody were performed, but there has been no case with positive results. Despite the rarity of the reported cases, we think that ischemic stroke in combined OHSS and APAS like our case can occur, because a patient with APAS might miss the spontaneous abortion and seek for the management of infertility, as previously mentioned.

The exact cause of thromboembolism in OHSS is still not completely understood. An induced secondary hypercoagulable state due to the hemoconcentration has been suggested (3). However in our case, the initial hematocrit and hemo-

Table 1. Summary of patient's coagulation laboratory findings

	On Admission	1 Month	2 Months	Normal Range
Anticardiolipin Ig M	16.1	12.7	46.2	<12.5 MPL [†]
Anticardiolipin Ig G	Negative	Negative	-	<20.0 GPL [‡]
Lupus anticoagulant	Negative	-	-	-
Protein C	135	120	-	70-140%
Protein S	43	63	62	71-103%
Antithrombin III	100	-	-	80-120%

* - : not performed, [†]MPL: Ig M phospholipid unit, [‡]GPL: Ig G phospholipid unit.

globin levels were decreased, against for the hemoconcentration. The decreased levels of hemoglobin and hematocrit are partly due to the effect of hemodiluting treatment for OHSS at the infertility clinic. However, as there has been some reports of OHSS that developed thromboembolism without the evidence of hemoconcentration (5), it is possible that the hemoconcentration may not be the sole underlying mechanism of the thromboembolism, at least in some cases including ours.

The activation of hemostatic system is another possible explanation of the thromboembolism in OHSS (7). Decreased levels of antithrombin III and prekallikrein are frequently detected in OHSS, and the time course is also consistent with the thromboembolic complication (8). A growing body of evidences indicate that the activation of hemostasis and plasma kinin system are the underlying pathogenesis of thromboembolism in OHSS, though what triggers the activation is still obscure.

In our case, a decreased level of protein S was detected. Although the protein S level can be decreased by the pregnancy itself, in our case the decreased level of protein S persisted after the termination of the pregnancy. So despite the relatively small decrease, we could not rule out the possibility that the decreased level of the protein S contributed to the development of thromboembolism in this case. On the other hand, the Ig M anticardiolipin antibody titer was highly and persistently elevated. With the history of spontaneous abortion and cerebral infarct, the diagnosis of APAS could be easily made. Although APAS itself can cause cerebral infarct, in this case the ischemic stroke developed in the middle of OHSS. Since OHSS itself has a thromboembolic potential, the authors think that there must have been a synergistic effect.

Natural pregnancy is nowadays allowed in a majority of SLE patients. However, regarding the consequences of assisted reproduction treatment in the SLE or primary APAS patients, only little information is available (9). Huong *et al.* tried ovulation induction in four SLE patients, but failed in all, while one developed venous thrombosis (10). Recently, Guballa *et al.* retrospectively analysed 68 cycles of ovulation induction/IVF in 19 SLE and primary APAS patients (11), in whom prophylactic treatment with heparin or aspirin was used. Even though the pregnancy was possible, the overall outcome was poor due to the high rate of fetal and maternal complications. Thrombotic events were not noticed in this series. From our experience and these reports, the authors recommend the screening test for the antiphospholipid anti-

bodies before ovulation induction, because there may be a risk of fetal and maternal complications including cerebrovascular accidents. Prophylactic treatment with antiplatelet agents or anticoagulants are possible preventive measures against thrombotic complications.

REFERENCES

1. Coull BM, DeLoughery TG, Feinberg WM. *Coagulation abnormalities in stroke*. In: Barnett HJM, Mohr JP, Stein BM, Yatsu FM, editors, *Stroke Pathophysiology, Diagnosis, and Management 3rd edition*. Philadelphia: Churchill Livingstone 1998; 963-78.
2. Navot D, Bergh PA, Laufer N. *Ovarian hyperstimulation syndrome in novel reproductive technologies: prevention and treatment*. *Fertil Steril* 1992; 58: 249-61.
3. Stewart JA, Hamilton PJ, Murdoch AP. *Thromboembolic disease associated with ovarian stimulation and assisted conception techniques*. *Hum Reprod* 1997; 12: 2167-73.
4. El Sadek MM, Amer MK, Fahmy M. *Acute cerebrovascular accidents with severe ovarian hyperstimulation syndrome*. *Hum Reprod* 1998; 13: 1793-5.
5. Aboulghar MA, Mansour RT, Serour GI, Amin YM. *Moderate ovarian hyperstimulation syndrome complicated by deep cerebrovascular thrombosis*. *Hum Reprod* 1998; 13: 2088-91.
6. Yoshii F, Ooki N, Shinohara Y, Uehara K, Mochimaru F. *Multiple cerebral infarctions associated with ovarian hyperstimulation syndrome*. *Neurology* 1999; 53: 225-7.
7. Kodama H, Fukuda J, Karube H, Matsui T, Shimizu Y, Tanaka T. *Status of the coagulation and fibrinolytic systems in ovarian hyperstimulation syndrome*. *Fertil Steril* 1996; 66: 417-24.
8. Kodama H, Takeda S, Fukuda J, Miya H, Shimizu Y, Murata M, Tanaka T. *Activation of plasma kinin system correlates with severe coagulation disorders in patients with ovarian hyperstimulation syndrome*. *Hum Reprod* 1997; 12: 891-5.
9. Wechsler B, Huong DL, Vauthier-Brouzes D, Lefebvre G, Gompel A, Piette JC. *Can we advise ovulation induction in patients with SLE?* *Scand J Rheumatol Suppl* 1998; 107: 53-9.
10. Huong DL, Wechsler B, Piette JC, Arfi S, Gallinari C, Darbois Y, Frances C, Godeau P. *Risks of ovulation-induction therapy in systemic lupus erythematosus*. *Br J Rheumatol* 1996; 35: 1184-6.
11. Guballa N, Sammaritano L, Schwartzman S, Buyon J, Lockshin MD. *Ovulation induction and in vitro fertilization in systemic lupus erythematosus and antiphospholipid syndrome*. *Arthritis Rheum* 2000; 43: 550-6.