

## Adult-onset Still's Disease with Vesiculopustules on the Hands and Feet

Adult-onset Still's disease (AOSD) is a rare systemic inflammatory disorder of unknown etiology characterized by an evanescent rash, intermittent spiking high fever, arthralgia, and a variety of systemic features. We describe a 46-yr-old woman with Still's disease who presented with a 2-month history of a symmetrical vesiculopustular eruptions only on both hands and feet. Skin biopsy specimens of both vesicle and pustule revealed fibrin thrombi deposition in the small dermal vessels with little inflammation, subepidermal bulla, and ischemic necrosis of the overlying epidermis, which were consistent with a vasculopathic reaction. Her skin lesions gradually disappeared in response to conventional AOSD therapy, as elevated serum ferritin levels, an index of disease activity, decreased. To the best of our knowledge, this is the first case of vesiculopustular lesions as a skin manifestation of AOSD.

**Key Words :** Still's Disease, Adult-Onset; Skin Manifestations

**Jee Bum Lee, Jae Wook Kim,  
Shin Seok Lee\*, Seong Jin Kim,  
Young Ho Won, Seung Chul Lee**

Departments of Dermatology and Internal  
Medicine\*, Chonnam National University Medical  
School, Gwangju, Korea

Received : 15 November 2001  
Accepted : 29 December 2001

**Address for correspondence**

Seung-Chul Lee, M.D.  
Department of Dermatology, Chonnam National  
University Medical School, 8 Hak-dong, Dong-gu,  
Gwangju 501-757, Korea  
Tel : +82-62-220-6682, Fax : 82-62-222-4058  
E-mail : schul@chonnam.ac.kr

### INTRODUCTION

Still's disease is a variant form of juvenile rheumatoid arthritis, first reported by Still in 1896 (1). Subsequently, it has been known that it is a systemic inflammatory disease rather than simply a joint illness (2). In 1971, a similar syndrome occurring in adolescents and adults was described by Bywaters (3) who coined the term adult-onset Still's disease (AOSD). In contrast to the typical skin manifestation of AOSD, the so-called Still's rash, which manifests as evanescent, salmon pink, maculopapular eruptions on the trunk and proximal extremities in more than two thirds of patients (4-8), there have been only a few reports on unusual skin manifestations of AOSD, including acne or eczematoid lesions, purpura, and urticaria (4, 9, 10). We describe a case of AOSD in a Korean woman with vesiculopustular eruptions on both hands and feet instead of the typical skin rashes of AOSD. The skin lesions resolved simultaneously with other symptoms in response to therapy.

### CASE REPORT

A 46-yr-old Korean woman visited our dermatology clinic for the evaluation of vesiculopustules on her hands and feet of 2-month history. She had been diagnosed as AOSD 1 month prior to this visit, according to the criteria of Yamakuchi and Ohta (11), and had suffered from a high fever of up to 39°C,

especially in the evening, which was accompanied by headache, nausea, and persistent pain in the neck, shoulder, knee, and hip joints. Her past history revealed that she had experienced multiple joint pain about 10 yr before and had been treated with corticosteroid and analgesics. She had developed an allergic reaction to aspirin several years before. Her family history was unremarkable. She was hospitalized for the evaluation of the high fever and polyarthralgia. Examination revealed the presence of abnormally elevated hepatic enzyme levels (AST 177 U/L, ALT 43 U/L) and moderate splenomegaly. She also had mild anemia (hemoglobin 10.1 g/dL), thrombocytopenia (36,000/ $\mu$ L), elevated erythrocyte sedimentation rate [108 mm/hr; normal range (N), 0-15], markedly elevated levels of serum ferritin (12,758.4  $\mu$ g/L; N, 7-320), lactate dehydrogenase (>2,250 U/L; N, 220-470), and creatine kinase (341 U/L; N, 0-172). There was no evidence of hemolytic anemia from direct and indirect Coomb's test. Other blood chemistry tests, including serum creatinine, blood urea nitrogen, cryoglobulin, and cold agglutinin were normal, and urinalysis was not specific. Blood and urine cultures and cerebrospinal fluid findings revealed no evidence for bacterial, fungal, or viral infection. Computerized tomographic scan of the brain was normal. Several serologic markers including antinuclear antibody, antineutrophil cytoplasmic antibody, rheumatoid factor, and anti-double strand DNA antibody were not reactive. By the criteria of Yamakuchi and Ohta (11), she was diagnosed as AOSD, and accordingly treatment with oral

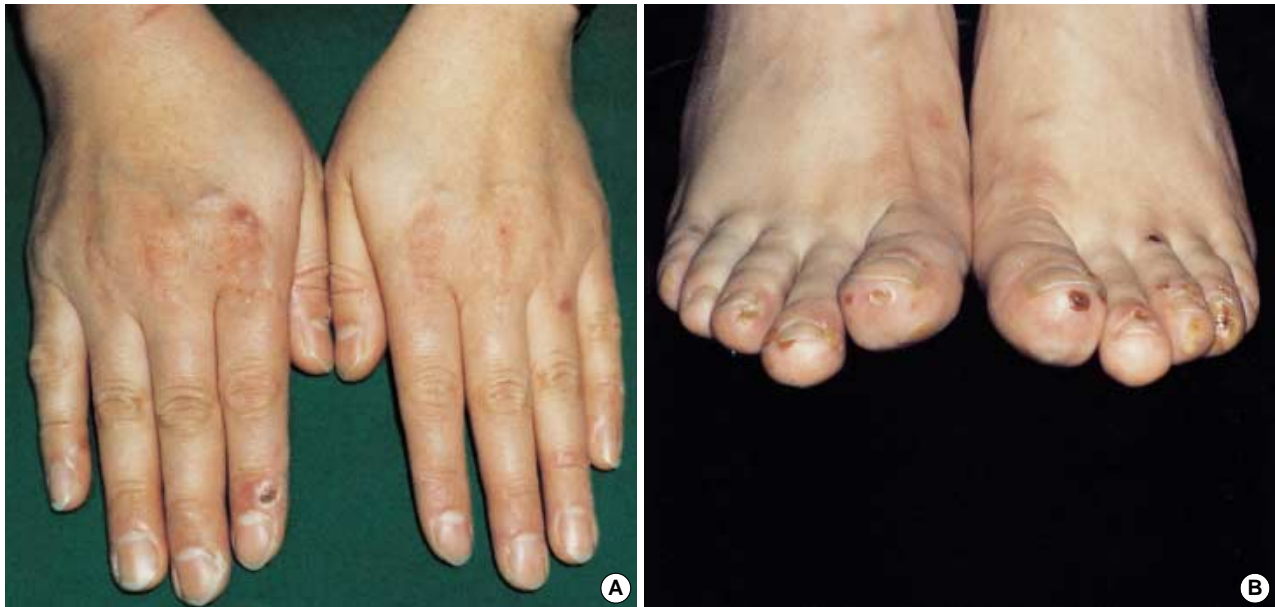

Fig. 1. Multiple discrete vesiculopustules with crusts are seen on the tips of the fingers (A) and toes (B).

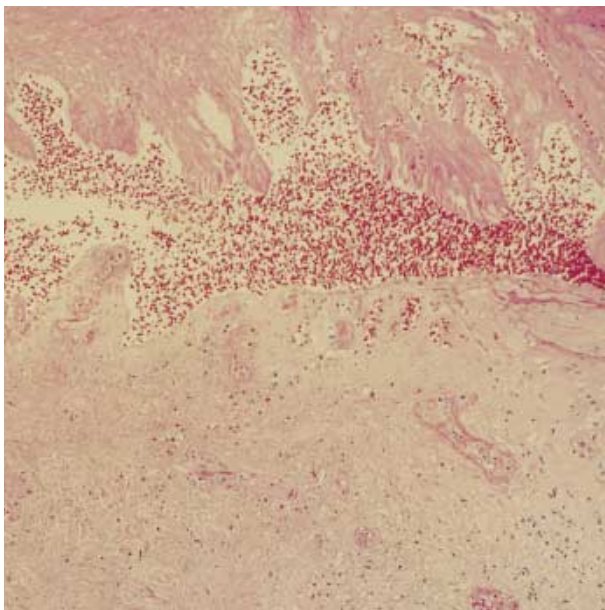


Fig. 2. The skin biopsy from the vesicle shows fibrin deposit in the vessels, subepidermal bulla, ischemic necrosis of the overlying epidermis, and a few inflammatory cells infiltrating the dermis (H&E,  $\times 200$ ).

non-steroidal anti-inflammatory drugs (NSAID) was initiated.

During hospitalization, she was referred to our dermatology department for the evaluation of a few vesicles and pustules instead of typical skin rash of AOSD. The lesions were multiple, painful, discrete, and distributed exclusively on the hands and feet, especially on the toetips (Fig. 1). The Tzanck test of the lesion was negative and bacterial and fungal cultures from

the pus failed to reveal any causative organisms. Skin biopsy specimens obtained from both vesicle and pustule showed the deposition of fibrin thrombi in small vessels with little inflammation in the upper and mid-dermis, subepidermal bulla, and ischemic necrosis of the overlying epidermis (Fig. 2). The results of direct immunofluorescence study of the vesicular lesion were all negative for IgG, IgM, IgA, C3, C4, and fibrinogen around the small vessels in the dermis. To rule out other diseases causing vasculopathic reactions in the skin, we performed other laboratory tests, including proteins C and S, prothrombin time, and activated partial thromboplastin time, all of which were normal.

The patient gradually improved with conventional therapy for AOSD, namely oral NSAID and amitriptyline. Interestingly, as the systemic symptoms improved gradually, serum ferritin levels decreased and her skin lesions also resolved. In spite of the disappearance of high fever, she still complained of mild polyarthralgia and intermittent attacks of a few vesicles on the hands and feet during the 6 months of follow-up period. She is now under control with NSAID and low-dose corticosteroid (5 mg/day).

## DISCUSSION

The clinical features of AOSD resemble the systemic form of juvenile rheumatoid arthritis, occurring in adults, usually at 16-35 yr of age (5). Several sets of diagnostic criteria have been proposed due to the absence of characteristic serologic abnormalities or etiologic agents, and most of the cases do not present with the full-blown syndrome (12). In this regard, the criteria of Yamakuchi and Ohta are a practical guide, in which inter-

mittent high fever, arthralgia, typical rash, and leukocytosis are proposed as major criteria, and sore throat, lymphadenopathy and/or splenomegaly, liver dysfunction, and negative rheumatoid factor (RF) and antinuclear antibody (ANA) are proposed as minor criteria (11). Five or more criteria, including 2 major ones, should be present to make a diagnosis of AOSD. Our patient fulfilled the criteria of AOSD by the presence of fever, arthralgia, splenomegaly, liver dysfunction, negative RF, and negative ANA.

The typical rash in Still's disease is asymptomatic, and is described as salmon pink, macular or maculopapular eruptions. It occurs on the trunk and extremities when the evening fever spikes. Skin biopsies of the rash reveal only nonspecific inflammatory reaction in the dermis, with mild or moderate perivascular infiltration of polymorphonuclear and/or mononuclear leukocytes (5). Although Still's rash is present in more than 85% of patients, and is believed to be almost pathognomonic, it is regarded as an inherently nonspecific finding (12). Bambery et al. (4) pointed out that they could not find the rash as well in India because of the natural pigmentation. In South Korea, the reported prevalence of the typical rash is about 50% (8). As Still's rash is evanescent, a fixed rash is thought to be atypical in AOSD, and has been reported rarely as acne or eczematoid lesions (9), purpura with histological vasculitis (4), urticarial lesions (10), and peau d'orange-like infiltrated lesions (13). Previous reports have described erythematous confluent papules and plaques in AOSD, but these resolved synchronously with other systemic symptoms upon treatment (14, 15). Our patient presented with a 2-month history of vesiculopustules limited to both hands and feet rather than typical Still's rash, which were difficult to observe due to the natural pigmentation. To the best of our knowledge, there have been no reports on AOSD with vesicular or pustular skin eruption in the English literature.

In this case, the histologic findings revealed the presence of fibrin thrombi in the small vessel with scarce inflammatory cell infiltration, suggestive of vasculopathy. Bambery et al. (4) previously reported one case of AOSD with cutaneous vasculitis that manifested as palpable purpura, but cutaneous vasculopathy has not been identified until now. Although it is not clear how vesiculopustules developed on the hands and feet, they could have developed secondary to the vasculopathic reaction, which occurs occasionally in the coagulopathies associated with connective tissue diseases such as lupus erythematosus and antiphospholipid antibody syndrome (16, 17). The involved vessel walls in the dermis may have degenerated and fibrin thrombi deposited, followed by ischemic necrosis of the overlying epidermis and subepidermal bulla formation.

Interestingly, the skin lesions gradually subsided as other systemic symptoms improved: the vesiculopustular lesions gradually decreased in number as the joint pain diminished in severity; and the cutaneous lesions subsided simultaneously with the normalization of serum ferritin level. Serum levels of ferritin are known to change in proportion to AOSD disease activity (5, 8). Ferritin is a kind of acute phase reactant, and

Motoo et al. reported it can be increased in combination with lactate dehydrogenase and adenosine deaminase as a result of hepatic damage (18). In this regard, vesiculopustules might be related with AOSD disease activity, and the underlying ischemic necrosis is presumed to induce such lesions in the peripheral portions of the extremities.

Although the exact relation between vasculopathy in the skin and AOSD remains unclear, their synchronous evolution with the systemic symptoms and their response to therapy suggest that vesiculopustules on the hands and feet may be a novel skin manifestation in AOSD.

## REFERENCES

1. Still GF. *On a form of chronic joint disease in children. Med Chir Trans 1897; 80: 1-13; reprinted Am J Dis Child 1978; 132: 195-200.*
2. Schaller JG, Wedgwood RJ. *Juvenile rheumatoid arthritis. Pediatrics 1972; 50: 940-53.*
3. Bywaters EG. *Still's disease in the adult. Ann Rheum Dis 1971; 30: 121-33.*
4. Bambery P, Thomas RJ, Malhotra HS, Kaur U, Bhusnurmath SR, Deodhar SD. *Adult onset Still's disease: clinical experience with 18 patients over 15 years in northern India. Ann Rheum Dis 1992; 51: 529-32.*
5. Ohta A, Yamaguchi M, Kaneoka H, Nagayoshi T, Hiida M. *Adult Still's disease: review of 228 cases from the literature. J Rheumatol 1987; 14: 1139-46.*
6. Pouchot J, Sampalis JS, Beaudet F, Carette S, Decary F, Salusinsky-Stembach M, Hill RO, Gutkowski A, Harth M, Myhal D, Senecal J-L, Yeadon C, Esdaile JM. *Adult Still's disease: manifestations, disease course, and outcome in 62 patients. Medicine (Baltimore) 1991; 70: 118-36.*
7. Reginato AJ, Schumacher HR Jr, Baker DG, O'Connor CR, Ferreiros J. *Adult onset Still's disease: experience in 23 patients and literature review with emphasis on organ failure. Semin Arthritis Rheum 1987; 17: 39-57.*
8. Lee E-B, Song Y-W. *Clinical analysis of adult onset Still's disease-22 cases in Korea. Korean J Rheumatol 1995; 2: 52-9.*
9. Ohta A, Yamaguchi M, Tsunematsu T, Kasukawa R, Mizushima H, Kashiwagi H, Kashiwazaki S, Tanimoto K, Matsumoto Y, Akizuki M, Ota T. *Adult Still's disease: a multicenter survey of Japanese patients. J Rheumatol 1990; 17: 1058-63.*
10. Setterfield JF, Hughes GRV, Kobza-Black A. *Urticaria as a presentation of adult Still's disease. Br J Dermatol 1998; 138: 906-8.*
11. Yamakuchi A, Ohta A. *Adult Still's disease. Nippon Naika Zasshi 1991; 80: 1771-4.*
12. Weyand CM, Wortmann R, Klippel JH. *Primer on the rheumatic disease: an official publication of the Arthritis Foundation. 11th ed. Marietta: Longstreet press 1998: 316-8.*
13. Phillips WG, Weller R, Handfield-Jones SE, Kobza-Black A. *Adult Still's disease. Br J Dermatol 1994; 130: 511-3.*
14. Lubbe J, Hofer M, Chavaz P, Saurat J-H, Borradori L. *Adult-onset Still's disease with persistent plaques. Br J Dermatol 1999; 141: 710-3.*

15. Kaur S, Bamberry P, Dhar S. *Persistent dermal plaque lesions in adult onset Still's disease. Dermatology* 1994; 188: 241-2.
16. Magro CM, Crowson AN. *The cutaneous pathology associated with seropositivity for antibodies to SSA(Ro): a clinicopathologic study of 23 adult patients without subacute cutaneous lupus erythematosus. Am J Dermatopathol* 1999; 21: 129-37.
17. Barnhill RL, Busam KJ. *Vascular diseases. In: Elder D, Elenitsas R, Jaworsky C, Johnson B Jr. Lever's histopathology of the skin. 8th ed. Philadelphia: Lippincott-Raven, 1997: 185-208.*
18. Motoo Y, Ohta H, Okai T, Sawabu N. *Adult-onset Still's disease: hepatic involvement and various serum markers relating to the disease activity. Jpn J Med* 1991; 30: 247-50.