

Tractographic Analysis of Historical Lesion Surgery for Depression

Jan-Christoph Schoene-Bake^{1,2,6}, Yaroslav Parpaley^{3,6}, Bernd Weber^{1,2}, Jaak Panksepp⁴, Trevor A Hurwitz⁵ and Volker A Coenen^{*,3}

¹Department of Epileptology, University of Bonn Medical Center, Bonn, Germany; ²Department of NeuroCognition/Imaging, Life & Brain Center, Bonn, Germany; ³Stereotaxy and MR based OR Techniques/Department of Neurosurgery, University of Bonn Medical Center, Bonn, Germany; ⁴Department of VCAPP, College of Veterinary Medicine, Washington State University, Pullman, WA, USA; ⁵Department of Psychiatry, University of British Columbia, Vancouver, CA, USA

Various surgical brain ablation procedures for the treatment of refractory depression were developed in the twentieth century. Most notably, key target sites were (i) the anterior cingulum, (ii) the anterior limb of the internal capsule, and (iii) the subcaudate white matter, which were regarded as effective targets. Long-term symptom remissions were better following lesions of the anterior internal capsule and subcaudate white matter than of the cingulum. It is possible that the observed clinical improvements of these various surgical procedures may reflect shared influences on presently unspecified brain affect-regulating networks. Such possibilities can now be analyzed using modern brain connectivity procedures such as diffusion tensor imaging (DTI) tractography. We determined whether the shared connectivities of the above lesion sites in healthy volunteers might explain the therapeutic effects of the various surgical approaches. Accordingly, modestly sized historical lesions, especially of the anatomical overlap areas, were 'implanted' in brain-MRI scans of 53 healthy subjects. These were entered as seed regions for probabilistic DTI connectivity reconstructions. We analyzed for the shared connectivities of bilateral anterior capsulotomy, anterior cingulotomy, subcaudate tractotomy, and stereotactic limbic leucotomy (a combination of the last two lesion sites). Shared connectivities between the four surgical approaches mapped onto the most mediobasal aspects of bilateral frontal lobe fibers, including the forceps minor and the anterior thalamic radiations that contacted subgenual cingulate regions. Anatomically, convergence of these shared connectivities may derive from the superolateral branch of the medial forebrain bundle (MFB), a structure that connects these frontal areas to the origin of the mesolimbic dopaminergic 'reward' system in the midbrain ventral tegmental area. Thus, all four surgical anti-depressant approaches may be promoting positive affect by converging influences onto the MFB.

Neuropsychopharmacology (2010) **35**, 2553–2563; doi:10.1038/npp.2010.132; published online 25 August 2010

Keywords: depression; lesion surgery; limbic system connectivity; medial forebrain bundle; probabilistic tractography

INTRODUCTION

Depression is the most common psychiatric disorder in the Western world, which is usually associated with psychiatrically significant dysphoria, compromised psychological functioning, and impoverished quality of life (Kessler *et al*, 2003). In 1990, the prevalence of depression in the United States was about 11 million (Greenberg *et al*, 1993). Despite various psychotherapies, an increasing array of medications, and the widespread availability of electroconvulsive

therapy, treatment failures have remained all too common, as highlighted by recent multi-center STAR*D studies (for an overview and related treatment considerations, see Shelton *et al*, 2010). In the face of severe disabling illness and with the ever-present risk of suicide, other more invasive biological interventions have been pioneered and refined over the past century. These have included magnetic and electric stimulation of the brain and 'psychiatric surgery'. The latter had its advent in the end of the nineteenth century starting with topectomies, pioneered by the Swiss psychiatrist Gottlieb (Burckhard, 1891) (for history, see Kotowicz, 2005). Target selection was based on limited knowledge of brain anatomy and function available at that time. During the following 30 years, the understanding of neurophysiology grew rapidly and a number of cognitive and emotional functions were mapped to specific locales and circuits within the brain. Prefrontal leucotomies were introduced by the Portuguese neuro-

*Correspondence: Professor VA Coenen, Stereotaxy and MR based OR Techniques/Department of Neurosurgery, University Hospital Bonn Medical Center, Sigmund-Freud-Strasse 25, Bonn 53127, Germany, Tel: +4 92 282 871 6503, Fax: +4 92 282 871 6772, E-mail: volker.coenen@ukb.uni-bonn.de

⁶These authors contributed equally to this work.

Received 20 April 2010; revised 5 July 2010; accepted 27 July 2010

logist Moniz (1937) with the aim of disconnecting pathogenetically implicated pathways. Outcome studies of treated patients showed moderate to good effects on mood and motivation. However, leucotomy had significant side effects: postoperative epilepsy, alterations of personality and various cognitive deficits in abstract thinking, imagination, creativity, and social appropriateness. Evolving neuroscientific knowledge and the desire to avoid or minimize side effects led to target refinements. Precise lesion placements became possible with the use of stereotactic procedures that replaced the open surgical approaches (Spiegel *et al*, 1947).

Various operations specifically designed for the treatment of major depression were developed in the second half of the twentieth century (Richardson, 1973; Knight, 1969; Bailey *et al*, 1973; Meyerson and Mindus, 1988). Four main lesion sites, alone or in combination, were identified. (i) In anterior capsulotomy (AC), a bilateral lesion is placed stereotactically in the inferior third of the anterior limb of the internal capsule (ALIC) (Meyerson and Mindus, 1988; Talairach *et al*, 1949). Both radiosurgery and diathermy have been used to create the lesion, with reported benefits in ~48% of previously treatment-resistant patients (Meyerson and Mindus, 1988). (ii) Anterior cingulotomy (ACT) has been performed using both open surgical and stereotactic approaches. A diathermal lesion is placed in the anterior third of the cingulate gyrus 2–4 cm posterior to the anterior tip of the lateral ventricle, 7 mm lateral to the midline, and 1 mm dorsal above the ventricular shadow (Bailey *et al*, 1973). In recent reviews, reported success rates have been ~34% (Hodgkiss *et al*, 1995). ACT was probably the least effective of the surgical procedures. (iii) Subcaudate tractotomy (SCT) was introduced by Knight in the 1950s (Knight, 1969; Bridges *et al*, 1994). Initially, radioactive seeds were placed in the target region posterior to the orbito-frontal cortex. Later, the lesions were created using heat or cryoablation. SCT was moderately beneficial, with improvement reported in ~35% of the depressed patients (Hodgkiss *et al*, 1995). (iv) Stereotactic limbic leucotomy (LL) is a combination of both bilateral ACT and SCT (Richardson, 1973). In diverse studies, rates of improvement of 50% (Mitchell-Heggs *et al*, 1976; Kim *et al*, 2002) to 78% (Cosgrove and Rauch, 2003; Montoya *et al*, 2002) have been reported (Mitchell-Heggs *et al*, 1976; Kim *et al*, 2002; Kelly *et al*, 1973; Diering and Bell, 1991). Thus, LL stands out as the clinically most effective lesioning procedure for depression. For an idealized illustration of the foci of the different targets, see Figure 1.

The four historical surgical approaches have all been individually effective in alleviating treatment-resistant depressions, albeit with variable efficacy. Benefit from such diverse and seemingly unrelated lesion locations may simply reflect the complexity of the underlying emotional circuitries that have been disrupted. Alternative explanations may be that the lesions disrupt specific affective systems or all the lesions influence the arousability of a shared system, which influences the affective status or modifies the psychological influences arising indirectly from the distal shared connectivities of the various treatments rather than direct affective consequences of the lesion sites themselves.

Modern developments in brain imaging allow us to consider such options. For instance, diffusion tensor

imaging (DTI) tractography (Malykhin *et al*, 2008) allows identification of white matter tracts *in vivo*, potentially revealing white matter architectures that provide information about the integrity and organization of relevant underlying fiber tracts. DTI, by measuring the direction-dependent diffusion of water molecules, characterizes the predominant direction of fibers within white matter. Probabilistic tractography can be used to model and map tracts based on given neuroanatomically situated 'seeds'. This method has been used in several studies to characterize the connectivity of cortical and subcortical structures (Behrens *et al*, 2003; Johansen-Berg *et al*, 2005; Cohen *et al*, 2009). In the domain of psychiatric surgery, this approach has already been used to analyze the connections of two targets (ALIC and subcallosal subgenual white matter, previously denominated as Cg25) utilized for deep brain stimulation (DBS) in the treatment of depression (Gutmann *et al*, 2009).

The current study is designed to identify, in a cohort of normal individuals, potentially unidentified fiber connectivities of the aforementioned historical anti-depressive surgical lesion sites that may be involved in historical lesioning procedures for major depression. The virtual 'seed lesions' we employed were intentionally designed to be estimates of actually used lesions, representing the smallest common overlap areas of the aforementioned historical lesion targets. Our hope was that identification of common overlapping fiber connectivities affected in all successful lesion targets may reveal new target sites for future stereotactically guided DBS interventions in treatment of refractory depression.

MATERIALS AND METHODS

Scans were taken of 53 subjects (17 male; 7 left-handed, average age 27 ± 9.35 years). None of the subjects had a history of neurological or psychiatric disease and all were screened for mood disorders using the Beck Depression Inventory (BDI) questionnaire (Beck *et al*, 1961). The ethics committee of the University of Bonn approved the study and all participants gave their written informed consent.

Magnetic resonance imaging was performed on a 3-T scanner (Magnetom Trio, Siemens, Erlangen, Germany). An eight-channel head coil was used for signal reception. All subjects underwent the same imaging protocol consisting of whole-brain T1-, T2-, and diffusion-weighted structural imaging. The total study time was 110 min per subject. Diffusion-weighted data were obtained using an in-house EPI DTI sequence (60 gradient directions, TR = 12 s, TE = 100 ms, 72 axial slices, resolution 1.7 mm^3). Additionally, seven data sets with no diffusion weighting (b_0 , $b\text{-value} = 0 \text{ s/mm}^2$) were acquired initially and interleaved after each block of 10 diffusion-weighted images as anatomical reference for motion correction. The high angular resolution of the diffusion weighting directions improves the robustness of probability density estimation by increasing the signal-to-noise ratio (SNR) and reducing directional bias. To further increase SNR, scanning was repeated three times for averaging.

Processing and Analysis of DWI Data

All imaging data were transferred to a cluster of Linux workstations for processing with an in-house protocol

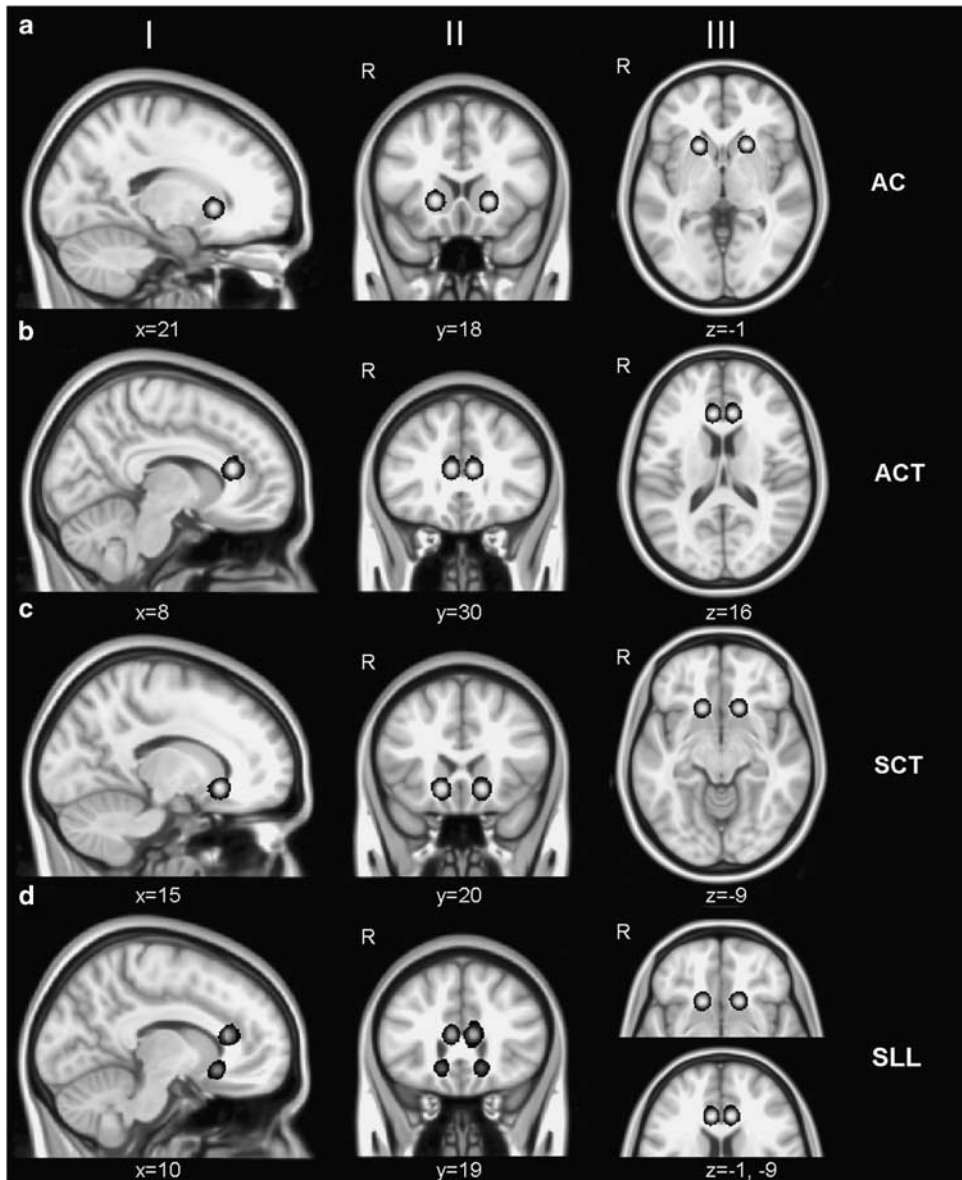


Figure 1 Mean probability maps of simulated lesions. (a) Anterior capsulotomy (AC); (b) anterior cingulotomy (ACT), I—sagittal, II—coronal, III—axial; (c) subcaudate tractotomy (SCT); and (d) stereotactic limbic leucotomy (SLL), converted in MNI space.

using FSL 4.1.3 tools (<http://www.fmrib.ox.ac.uk/fsl>). Motion correction was applied on all images using seven-parameter global rescale registration with a mutual information cost function and tri-linear interpolation as implemented in FLIRT (Jenkinson and Smith, 2001). All baseline b_0 images were aligned to a reference b_0 image and the resulting linear transformation matrixes were then applied to the diffusion-weighted images following each baseline b_0 image. After correction for eddy currents, the three repetitions were averaged to improve the signal-to-noise-ratio. A binary mask differentiating between brain and skull structures was calculated for brain extraction using BET and applied to all images. BedpostX was run on the preprocessed data to generate the basis for probabilistic tractography using ProbtrackX.

Simulation of Lesions (Selection of Regions of Interest)

Lesion masks were placed bilaterally based on original descriptions of lesion locations and published MRI examinations of lesioned patients (Kim *et al*, 2002; Coenen and Honey, 2009). MNI coordinates are shown in Table 1.

1. AC: anterior limb of the capsula interna, 20 mm lateral to the midline, and 5 mm behind the tip of the frontal horns of the lateral ventricles at the level of the inter-commissural plane.
2. ACT: anterior cingulum, 2–4 cm posterior to the anterior tip of the lateral ventricle, 7 mm lateral to the midline, and 1 mm dorsal to the roof of lateral ventricle.
3. SCT: Frontobasal subcortical white matter above the orbito-frontal cortex, 15 mm from the midline, 10 mm

Table 1 Simulation of Target Sites and Mean Target Location in MNI152 Space

Operation	Target	MNI152 coordinates of simulation (mm)	
		Right side	Left side
Anterior capsulotomy (AC)	Anterior limb of internal capsule	x = 21 (19–23) y = 18 (16–20) z = -1 (1–3)	x = -19 (-17–21) y = 17 (15–19) z = -1 (3–1)
Anterior cingulotomy (ACT)	Bilateral anterior cingulum	x = 8 (6–10) y = 30 (28–32) z = 16 (14–18)	x = -7 (-5–9) y = 30 (28–32) z = 16 (14–18)
Subcaudate tractotomy (SCT)	Bilateral subcaudate white matter	x = 15 (13–17) y = 20 (18–22) z = -9 (-7–11)	x = -14 (-12–16) y = 20 (18–22) z = -9 (-7–11)
Limbic leucotomy (LL)	Bilateral anterior cingulum and subcaudate white matter	Combination of ACT and SCT	Combination of ACT and SCT

above the planum sphenoidale, and at the most anterior aspect of the sella.

4. LL: combination of ACT and SCT ROIs.

Masks formed by spheres of 10 mm diameter were manually placed within the individual MPRage-T1-image by two experienced neurosurgeons. The T1 image with the accompanying lesion masks was then transferred to the individual native diffusion space using linear transformations. The individual lesions (ROIs) over all subjects were statistically analyzed using the NPM tool (Nonparametric Mapping, part of MRICron, Version 03/2009 (Rorden *et al*, 2007)). Mean and standard deviation maps were calculated and analyzed using a threshold of 0.05 probability (displaying lesion location across 95% of subjects). A maximum deviation of 2 mm in any direction (*x/y/z*) was determined. Figure 1 shows the overlap of the individual lesion sites transferred to MNI space.

Probabilistic Tractography

Estimation of tracts was done as previously reported (Cohen *et al*, 2009), using published methods in the FSL environment (Behrens *et al*, 2003). Fiber tracking was done probabilistically, using 5000 tract-following samples at each voxel. We used a dual-fiber model as implemented in the latest version of BedpostX. This model helps account for issues related to crossing fibers, and produces more reliable results compared with a single-fiber model (Behrens *et al*, 2007). The result is a brain image in which all voxels have a value that represents the connectivity (number of fibers from the probabilistic analysis) between that voxel and the voxels in the seed region (ie, the lesion). One advantage of the probabilistic tractography is that it accounts for uncertainty inherent in local fiber directions, and thus estimates a spatial probability distribution of connectivity from the seed regions. All tractography was done in each subject's native space. All results images were visually inspected to ensure correct normalization and tracking. The resulting statistical maps were then thresholded at 0.01 (99% likelihood of connectivity) and their values

normalized to a range of 0–100 000 and transferred into MNI152-1 mm-standard space for cross-subject analysis. To generate population-based probability maps, all subjects' probability maps (after thresholding) of one seed were combined. This was done in two different ways. First, a mean tract for the selected seed was calculated by adding up all single-subject tracts and calculating a mean image using NPM, thus retaining the quantitative strength of the probability. A threshold of 0.01 was then applied to the mean image to only show voxels with a 99% likelihood of connectivity to the respective seed region (lesion). Furthermore, the individual maps were binarized and then also added up and used as a basis for calculation of a mean image. As reported by Gutmann *et al* (2009) the result map was thresholded to show voxels common to 75% or more of the subjects. As the results of these two approaches were identical, we assumed the results to be reliable and the applied thresholds to be valid. The resulting pathways connected to each seed (lesion sites, white circles) are shown in Figure 2. An overlap analysis (representing a Venn diagram of all tracts) was then performed to detect common patterns, resulting in a network of pathways that was possibly affected by all surgical treatments described above (Figure 3). The allocation of white matter tracts to the resulting statistical maps was done using various atlases (Mori *et al*, 2008, Mazziotta *et al*, 2001).

RESULTS

The results are listed in Table 2 with a detailed overview of the connectivity analysis of each lesion site. Modern target sites for DBS in depression are seen as areas of overlap:

AC-, ACT- and SCT-simulated lesion sites gave rise to fiber tracts (Figure 2) that demonstrated several areas of overlap (Figure 3). These consisted of forceps minor, frontothalamic fibers, area Cg25, and medial frontobasal white matter with frontothalamic connectivity. Distal connectivities of these mapped projections are largely divergent. However, common to all simulated lesion sites

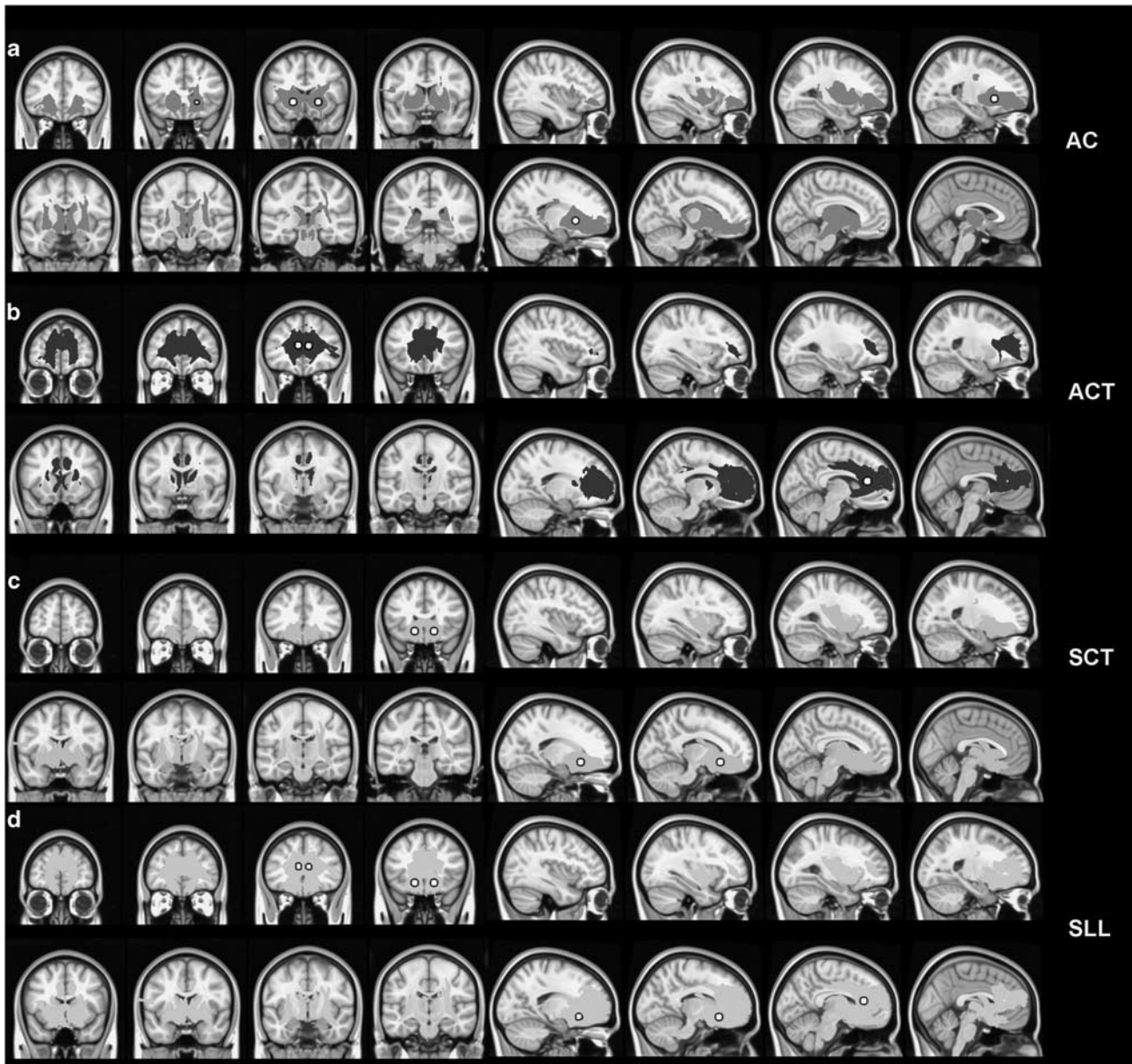


Figure 2 Mean probability-tracking maps for AC (a, red), ACT (b, blue), SCT (c, green), and SLL (d, cyan). Maps indicate areas with up to 99% connectivity likelihood, $n = 53$. The white spheres show the respective lesion sites. The color reproduction of this figure is available on the html full text version of the manuscript.

were connections to the frontal pole, the amygdala/hippocampal complex, and dorsal thalamus. For the frontal pole, the majority of fibers projecting from the SCT travel primarily medially along the forceps minor, whereas the AC target fibers travel more laterally primarily via the anterior thalamic radiation. For the amygdalohippocampal region, all sites appeared to send fibers through the medial temporal lobe within the uncinate fasciculus.

AC and SCT shared more areas in common with each other than with ACT and included the corona radiata, brainstem, and periaqueductal gray matter. The pattern of shared connectivity between ACT and AC included anterior thalamic radiation, forceps minor, inferior fronto-occipital fasciculus, fasciculus uncinatus, genu of the corpus callosum. ACT–SCT overlap covered a relatively small area,

including anterior thalamic radiation, forceps minor inferior fronto-occipital fasciculus, and uncinate fasciculus.

DISCUSSION

This study capitalized on data about the spatial localization of lesion sites historically demonstrated to be partly effective in the treatment of chronic depression. Connectivity analysis of these sites with advanced MR technology has now revealed (i) previously unrecognized underlying white matter projections and (ii) with overlapping distal anatomical structures. This new information may be useful in directing the search for more effective targets for stereotactic DBS interventions, as well as smaller potential lesion

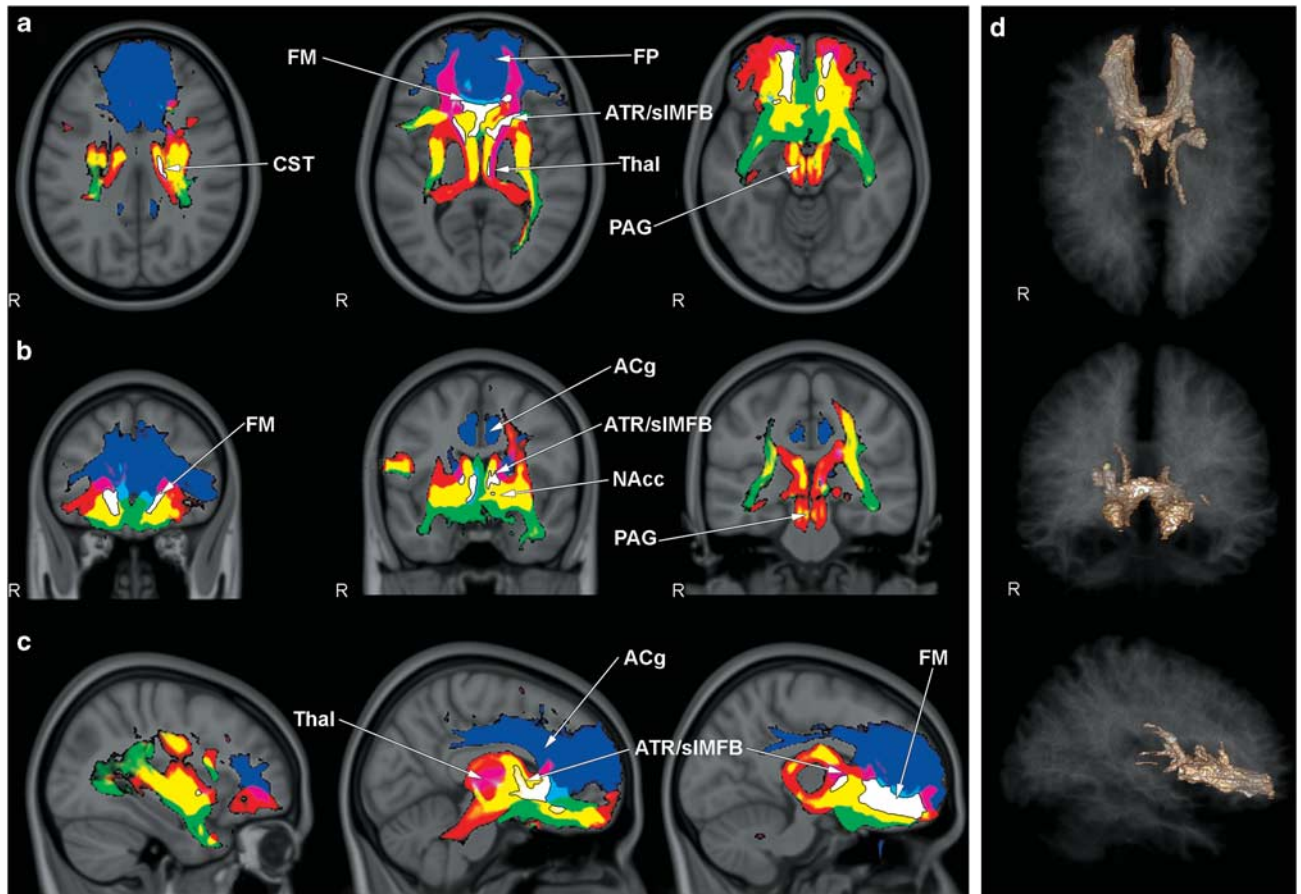


Figure 3 Intersection of connectivity maps of AC (red), ACT (blue), and SCT (green) tracking results. Overlap of AC and ACT shown with magenta, AC and SCT in yellow, and ACT and SCT in cyan. The white area shows overlapping of AC, ACT, and SCT mean probability-tracking maps in axial (a), coronal (b), and sagittal (c) slices. (d) 3D representation of AC/ACT/SCT intersection area. Acg, anterior cingulate gyrus; ATR, anterior thalamic radiation; CST, corticospinal tract; FM, forceps minor; FP, frontal pole; Nacc, accumbens nucleus; PAG, periaqueductal grey matter; sIMFB, superolateral branch of medial forebrain bundle; Thal, thalamus.

sites. This may have both anatomical and functional implications for understanding the efficacy of the four major types of ablative procedures historically used to treat intractable depressions.

AC has found its most common use in the treatment of obsessive-compulsive disorders (OCDs) (Christensen *et al*, 2002; Greenberg *et al*, 2003), but is also a target for the treatment of refractory depression. The physiological idea behind AC lesions is that interruption of the frontothalamic connections may attenuate negative ruminations that commonly accompany depression (Christensen *et al*, 2002; Aboosh and Cosgrove, 2008), which may be mediated by self-reflective medial fronto-cortical 'resting state' and self-referential networks (Northoff *et al*, 2006; Northoff, 2010). More specifically, AC may be producing benefit by interrupting the connection between the anterior thalamic nucleus and cingulate gyrus—a component of Papez's limbic circuit that has been implicated in regulating emotionality (MacLean, 1990; Papez, 1995). However, benefits may also derive from severing more distal connectivities, such as those to the many emotional circuits of the brainstem (Panksepp, 1998). In our DTI tractography results, we traced fibers to the frontal poles bilaterally, forceps minor including the genu of the corpus callosum, frontomedial, frontoorbital

and subcallosal cortex, and medial temporal lobe, but also to the brainstem and cerebellum. These brainstem linkages are likely mediated by more posteriorly and medially placed AC target locations that sever frontopontine and cortico-nuclear tracts. Brainstem structures that regulate the expression of mood include the medial forebrain bundle (MFB), especially through the superolateral branch of the MFB (sIMFB) (Coenen *et al*, 2009). The MFB is located in the inferior and lateral parts of the ALIC and connects the ventral tegmental area (VTA) to the nucleus accumbens (NAcc). NAcc (Schlaepfer *et al*, 2008) features prominently in reward seeking and appetitive motivational processing (Alcaro *et al*, 2007; Delgado, 2007). Recent DBS studies targeting the shell of the NAcc have demonstrated good clinical effects in patients with depression, an effect that may be mediated by interconnections to limbic and prefrontal regions, especially Cg25 (Gutmann *et al*, 2009; Schlaepfer *et al*, 2008). Area Cg25 appears to be a pivotal node in mood regulation. It is activated during sadness, and DBS that targets this area can effectively treat refractory clinical depression (Gutmann *et al*, 2009; Hamani *et al*, 2009).

The MFB, and more specifically its superolateral branch, is, according to our analysis, a potentially significant

Table 2 Stratification of Connection Likelihood of Lesion Target Sites

Structure	Surgical procedure							
	ACT		AC		SCT		LL	
	Left	Right	Left	Right	Left	Right	Left	Right
Anterior thalamic radiation/superolateral branch of the medial forebrain bundle	+++	+++	+++	+++	+++	+++	+++	+++
Corticospinal tract			++	++	+	+	+	+
Forceps minor	+++	+++	++	++	+++	+++	+++	+++
Fasciculus uncinatus	+++	+++	++	++	++	++	+++	+++
Inferior fronto-occipital fasciculus	++	++	++	++	++	++	++	++
Anterior corona radiata			++	++	++	++	++	++
Superior corona radiata			++	++	++	++	++	++
Nucleus accumbens			+++	+++	++	++	++	++
Genu corporis callosum	+++	+++	++	++	++	++	+++	+++
Inferior cerebellar peduncle			++	++				
Brainstem			++	++	+	++	+	++
Anterior cingulum	+++	+++					++	++
Anterior limb of internal capsule			+++	+++				
Posterior limb of internal capsule	++	++					++	++
External capsule					++	++	++	++
Subgeniulate cortex (SGC)					+++	+++	+++	+++
Superior longitudinal fasciculus				++				
Inferior longitudinal fasciculus						++	++	++
Stratum sagittale						++	++	++
Periaqueductal gray matter			+	+	+	+	+	+

Likelihood of connectivity 1–<5% = +; probability 5–<10% = ++; probability 10–100% = +++.

component of such a polysynaptic circuit originating in the VTA of the brainstem and involved in the regulation of reward and mood. It is noteworthy that lesions placed in the AC in the past have been located in the most inferior part of the ALIC (Hurwitz *et al*, 2006). In a postoperative effort to demonstrate degenerating brain regions with T1-weighted MRI after anterior capsulotomies, two affected neuronal systems in depressed patients were identified. One was clearly the well-established anterior thalamic radiations. A second less well-recognized system was related to the more lateral AC, especially the frontopontine tracts to the midbrain. According to our current understanding, this second degenerating system prominently includes the sLMFB, which then conveys information rostrally, toward ventral striatal and medial frontal directions.

ACT has clinically been the least effective lesion site from the four targets studied in our anatomical reconstructions. ACT involves stereotactic placement of bilateral lesions in the cingulate cortex and cingulum. The cingulate gyrus is a component of limbic circuitry that initially motivated targeting this area for ablation in the surgical treatment of psychiatric illness, and since then has been implicated in the higher elaboration of negative affect characterized by separation distress and sadness grief (Panksepp, 1998). ACT connectivities traced by our study reveal involvement of the bilateral cingulate gyrus, bilateral frontal and thalamic connections, ipsilateral connections to the amygdalo-hippocampal complex, and bilateral involvement of

the ALIC. ACT is used to treat refractory depression and OCD. The mechanism of therapeutic action remains uncertain, but it is commonly assumed to be due to disruption of one or more components of associated limbic-emotional circuitry (Abosch and Cosgrove, 2008; Cho *et al*, 2008). More recently, studies evaluating the efficacy of ACT in major depression, drug dependence, and pain patients (Steele *et al*, 2008) suggest that the effects of ACT may be explained on the basis of disconnection of afferent fibers from the midline thalamic nuclei, the function of which is to impart the emotional coloring to perceptions (LeDoux, 1995), especially negative emotions (MacLean, 1990).

SCT emerged out of attempts to minimize the size of lobotomy lesions. In SCT bilateral lesions are placed, among other areas, in the substantia innominata of the basal forebrain immediately ventral to the head of the caudate (Knight, 1969). SCT has been used for many decades to treat refractory affective and anxiety disorders, including major depression and OCDs.

Our tractography study demonstrated bilateral frontal pole connectivities tracking via forceps minor and the anterior thalamic radiation, as well as white matter connecting to the subcallosal cortex. The connectivity is made via anterior thalamic radiations. Additional connections were demonstrated to mesial temporal lobe structures, the brainstem, and periaqueductal gray matter. Fibers connecting to the brainstem appear to parallel the frontopontine tract containing fibers of the sLMFB that

connect VTA with NAcc, which, via modulation (eg, perhaps release of function) of the reward circuitry, could promote anti-dysphoria effects. There is also a direct involvement of the lower medial part of ALIC, where the anterior thalamic radiation is located adjacent and medial to the sLMFB. Similar to AC, SCT may be producing clinical benefit by reducing inhibitory effects onto the reward-appetitive functions of the MFB. Given its location, SCT may also work by directly disrupting the functioning of Cg25. Haber and co-workers (Haber and Knutson, 2010) provide a synergistic possibility based on their primate neuroanatomy. According to them, bundles of fibers that connect midbrain dopaminergic neurons (VTA) connect to the NAcc, ventral striatum, hypothalamus, and bed nucleus of the stria terminals that travel ventral (inferior) to the ALIC.

LL is essentially a combination of bilateral ACT and SCT, although some variations have been described in surgical approaches, lesion sizes, and precise locations. LL most likely was the most effective treatment for depression during the lesion era. The method, introduced in 1973 by Kelly and Richardson (Mitchell-Heggs *et al.*, 1976; Kelly *et al.*, 1973), was based on the possibility that a dual lesion technique should produce better functional results compared with either single-lesion method alone. Our connectivity analysis demarcated the influenced tracts to the medial frontal, orbitofrontal, frontal polar, and subcallosal cortex.

AC and SCT share more areas in common—bilateral thalami, temporal lobe, and brainstem—than AC with ACT. AC/SCT overlap covers almost 80% of each single connectivity map. ACT connectivity has a noticeably wider pattern of frontal lobe connectivity extending to the frontobasal and frontomedial regions. Such differences can potentially be explained by collateral damage to the corpus callosum fibers, which are not directly connected with the targeted limbic pathways.

As all of the studied lesion sites are effective in the treatment of both depression and OCD, such benefit may depend on the disruption of shared connectivities and may point to a single common pathway involved in mood regulation. Alternatively, benefits may arise from the disruption of distinct and separate affect-regulating pathways, but nothing in the current data allows us to postulate such widely distributed independent limbic networks.

Perhaps the most parsimonious view is that the shared connectivities—pointing to a common mood pathway—project to the most mediobasal aspects of bilateral frontal lobe regions that include fibers of the forceps minor, and the anterior thalamic radiations, which make contact with the subgenual cingulate region—area Cg25 (Johansen-Berg *et al.*, 2008; Drevets *et al.*, 2008; Mayberg *et al.*, 2005). According to the present data, access to these shared brain regions is most readily explained via the sLMFB, which emerged as the most clear-cut convergence site of the historical lesions we analyzed (Table 2). The MFB is classically regarded as a structure of the reward-seeking circuitry and is a key structure of the mesolimbic dopamine system, a system related to affective disorders, drug addiction, and appetitive learning (Panksepp, 1998). However, there are alternative possibilities including nearby direct connections between the cerebellum and the septal region, which course through the MFB (Paul *et al.*, 1973).

The fuller extent of the MFB has only recently been characterized in humans (Coenen *et al.*, 2009). Originating in the VTA, the MFB subdivides into two distinct branches. The main inferomedial branch (imMFB) connects the VTA with the lateral hypothalamus. A second superolateral branch (sLMFB), also originating out of the VTA, separates from the main trunk and, via ventral aspects of the ALIC, connects to NAcc. The sLMFB runs parallel and lateral to the anterior thalamic radiation. The anterior thalamic radiation is a fiber pathway identified by tractography in all three historical lesion sites. We suggest that the observed involvement of the anterior thalamic radiation in all three historical lesion sites also includes fibers of the sLMFB. Due to a lack of description in currently used atlases, this bundle yet could not be identified as a separate structure.

The MFB, especially its superolateral branch, thus emerges from our analysis as a potential target especially for DBS, or possibly ablation if it inhibits positive affective functions of the brain, in the treatment of refractory mood disorders. There is some clinical evidence to support such possibilities. Current DBS studies in depression target Cg25 (Hamani *et al.*, 2009; Johansen-Berg *et al.*, 2008; Lozano *et al.*, 2008; Mayberg, 2009), ALIC, or NAcc (Schlaepfer *et al.*, 2008). Stimulation parameters are similar to those used in the treatment of Parkinson's disease, where the subthalamic nucleus is targeted—90 μ s square impulses at frequencies of 130 Hz (Mayberg *et al.*, 2005) and 145 Hz (Schlaepfer *et al.*, 2008). However, at times even high voltages, up to 4–5 V (Schlaepfer *et al.*, 2008; Hamani *et al.*, 2009; Lozano *et al.*, 2008; McNeely *et al.*, 2008), are needed to obtain treatment effects, raising the possibility that nearby structures are also affected. One such nearby structure is the sLMFB (Coenen *et al.*, 2009). If so, we hypothesize that a key affect modulating pathway could be the sLMFB, which could have widespread effects on the affective restructuring of the brain. Recent technical developments provide new insights into the mechanisms of DBS and its effects on fiber pathways in the vicinity of targeted brain regions. These studies point toward an activation and modulation of small afferent fiber tracts, as opposed to other possible effects such as inhibition of nuclear structures (Gradinaru *et al.*, 2009; Hamani *et al.*, 2010a,b). In this respect, excitatory modulation and not inactivation of the sLMFB would be postulated as the mechanism of action. This possibility is consistent with an abundance of pre-clinical evidence collected during the past half-century indicating a large number of emotion-regulating pathways, including dopamine circuits that course through the MFB (Panksepp, 1998).

Limitations

The research participants in this work consisted of healthy volunteers. The work is premised on the assumption that there is no difference in fiber architecture between healthy subjects and patients with depression. Although our subjects had normal BDI scores, they were not screened by a psychiatrist for ongoing or past psychiatric illness. This could have some indeterminate impact on our results.

Lesion simulations with a diameter of 10 mm are clearly smaller than the lesion sizes obtained after maturation of actual brain lesions produced by the above types of

neurosurgery. However, the volume of interests (VOIs) of 10 mm diameter are in agreement with typical VOI sizes in the literature (Gutmann *et al*, 2009). The evaluation of the presented tracking results might—in the light of the above—be prone to an underestimation of fiber connections involved in real lesion reconstructions. The presented method of ‘lesion generation/simulation’ based on high-resolution T1-weighted MRI has to be more accurate than individual lesion generation in patients that is based on bony landmarks, pneumo-encephalography, the intrinsic variabilities of stereotactic methods, and other factors. Simulated lesions, however, are smaller in size. However, the simulated lesions better represent an effective size that would result from the ‘Venn diagram’ of overlap regions of the larger (and sometimes multiple and repeated) historical lesions placed in populations of real patients.

Another problem is the fact that historical lesions that were the focus of the present work were only partly effective in treatment-resistant depression. This raises the possibility that our analysis of such lesions is susceptible to yielding false positives, by including brain regions that would have had no therapeutic effect. Obviously, we have no way of evaluating this possibility, but it should be equally evident that the modest effectiveness of some of the historical lesioning procedures may be explained by lack of consistency for accurate lesion placements. We think our selection of modest seed sizes, based on selecting likely overlap regions of lesions employed, can help minimize the role of such biases.

Ambiguous clinical outcome assessments in past lesion trials also compromise cross-study data comparisons. We have no way to account for such issues. Finally, probabilistic tracking also has several methodological limitations. DTI is unable to distinguish between afferent and efferent pathways such that the directionality of observed connections cannot be inferred, nor can their role in controlling excitatory and inhibitory processes. There are no empirically validated guidelines on what represents a functionally significant connection or how one determines such parameters. Nonetheless, the reproducibility of the DTI method is well established and the results generally match those of invasive tracing in primates or human post-mortem analyses (Schmahmann *et al*, 2007).

Also, the validity of such analyses must, obviously, be based on the fertility and accuracy of the predictions made for future interventions. In our estimation, the most interesting possibility emerging from this work is that direct facilitation of the reward-seeking effects of arousal of the MFB may be of therapeutic value in the treatment of medication-resistant depressions.

CONCLUSIONS

DTI probabilistic connectivity analysis is a useful tool to explore and to simulate the structural and functional impact of past stereotactic lesion surgery approaches for treating psychiatric disorders. Our study shows overlapping fiber tracts from four classical historical lesion sites for treating depression. The most prominent shared tract revealed by the present work was the sMFB. This structure has some appeal as a new site that could be of interest for DBS in

major depression, especially considering the historically established role of this brain reward-seeking network in regulating positive affective states.

ACKNOWLEDGEMENTS

J-CS-B was supported by the Deutsche Forschungsgemeinschaft (DFG) as part of the German transregional research cluster on temporal lobe epilepsy (SFB TR3, projects A1, A6, and A8). JP was supported by a grant from Hope for Depression Research Foundation. BW was supported by the Deutsche Forschungsgemeinschaft (DFG) with a Heisenberg grant (WE 4427/3-1). We thank Peter Trautner for help with image processing and Jennifer Faber, Beate Newport, and Silke Schiller for their help with MRI scans and study organization.

DISCLOSURE

VAC received honoraries for lecturing and consulting from Medtronic, USA and Medtronic, Europe. The authors declare no conflict of interest.

REFERENCES

- Abosch A, Cosgrove GR Biological basis for the surgical treatment of depression. *Neurosurg Focus* 2008 25: E2.
- Alcaro A, Huber R, Panksepp J Behavioral functions of the mesolimbic dopaminergic system: an affective neuroethological perspective. *Brain Res Rev* 2007 56: 283–321.
- Bailey H, Downling J, Davies E Studies in depression, III*the control of affective illness by cingulotomectomy: a review of 150 cases. *Med J Aust* 1973 2: 366–371.
- Behrens TE, Johansen-Berg H, Woolrich MW, Smith SM, Wheeler-Kingshott CA, Boulby PA *et al* (2003). Non-invasive mapping of connections between human thalamus and cortex using diffusion imaging. *Nat Neurosci* 6: 750–757.
- Beck AT, Ward CH, Mendelson M, Mock J, Erbaugh J (1961). An inventory for measuring depression. *Arch Gen Psychiatry* 4: 561–571.
- Behrens TE, Berg HJ, Jbabdi S, Rushworth MF, Woolrich MW (2007). Probabilistic diffusion tractography with multiple fibre orientations: What can we gain? *Neuroimage* 34: 144–155.
- Bridges PK, Bartlett JR, Hale AS, Poynton AM, Malizia AL, Hodgkiss AD (1994). Psychosurgery: stereotactic subcaudate tractomy. An indispensable treatment. *Br J Psychiatry* 165: 599–611, discussion 2–3.
- Burckhard G (1891). Über Rindenexcisionen, als Beitrag zur operativen Therapie der Psychosen. *Z Psychiatrie* 463–548.
- Cho DY, Lee WY, Chen CC (2008). Limbic leukotomy for intractable major affective disorders: a 7-year follow-up study using nine comprehensive psychiatric test evaluations. *J Clin Neurosci* 15: 138–142.
- Christensen DD, Laitinen LV, Schmidt LJ, Hariz MI (2002). Anterior capsulotomy for treatment of refractory obsessive-compulsive disorder: results in a young and an old patient. *Stereotact Funct Neurosurg* 79: 234–244.
- Coenen VA, Honey CR (2009). Ablative procedures for depression. In: Lozano AM, Gildenberg PL, Tasker RR (eds). *Textbook of Stereotactic and Functional Neurosurgery*, 2nd edn, pp 2941–2955.
- Coenen VA, Honey CR, Hurwitz T, Rahman AA, McMaster J, Burgel U *et al* (2009). Medial forebrain bundle stimulation as a pathophysiological mechanism for hypomania in subthalamic nucleus deep brain stimulation for Parkinson’s disease. *Neurosurgery* 64: 1106–1114, discussion 14–5.

- Cohen MX, Schoene-Bake JC, Elger CE, Weber B (2009). Connectivity-based segregation of the human striatum predicts personality characteristics. *Nat Neurosci* 12: 32–34.
- Cosgrove GR, Rauch SL (2003). Stereotactic cingulotomy. *Neurosurg Clin N Am* 14: 225–235.
- Delgado MR (2007). Reward-related responses in the human striatum. *Ann N Y Acad Sci* 1104: 70–88.
- Diering SL, Bell WO (1991). Functional neurosurgery for psychiatric disorders: a historical perspective. *Stereotact Funct Neurosurg* 57: 175–194.
- Drevets WC, Savitz J, Trimble M (2008). The subgenual anterior cingulate cortex in mood disorders. *CNS Spectr* 13: 663–681.
- Gradinaru V, Mogri M, Thompson KR, Henderson JM, Deisseroth K (2009). Optical deconstruction of parkinsonian neural circuitry. *Science* 324: 354–359.
- Greenberg PE, Stiglin LE, Finkelstein SN, Berndt ER (1993). The economic burden of depression in. *J Clin Psychiatry* 54: 405–418.
- Greenberg BD, Price LH, Rauch SL, Friehs G, Noren G, Malone D et al (2003). Neurosurgery for intractable obsessive-compulsive disorder and depression: critical issues. *Neurosurg Clin N Am* 14: 199–212.
- Gutmann DA, Holtzheimer PE, Behrens TE, Johansen-Berg H, Mayberg HS (2009). A tractography analysis of two deep brain stimulation white matter targets for depression. *Biol Psychiatry* 65: 276–282.
- Haber SN, Knutson B (2010). The reward circuit: linking primate anatomy and human imaging. *Neuropsychopharmacology* 35: 4–26.
- Hamani C, Mayberg H, Snyder B, Giacobbe P, Kennedy S, Lozano AM (2009). Deep brain stimulation of the subcallosal cingulate gyrus for depression: anatomical location of active contacts in clinical responders and a suggested guideline for targeting. *J Neurosurg* 111: 1209–1215.
- Hamani C, Diwan M, Isabella S, Lozano AM, Nobrega JN (2010). Effects of different stimulation parameters on the antidepressant-like response of medial prefrontal cortex deep brain stimulation in rats. *J Psychiatr Res* 44: 683–687.
- Hamani C, Diwan M, Macedo CE, Brandao ML, Shumake J, Gonzalez-Lima F et al (2010). Antidepressant-like effects of medial prefrontal cortex deep brain stimulation in rats. *Biol Psychiatry* 67: 117–124.
- Hodgkiss AD, Malizia AL, Bartlett JR, Bridges PK (1995). Outcome after the psychosurgical operation of stereotactic subcaudate tractotomy, 1979–1991. *J Neuropsychiatry Clin Neurosci* 7: 230–234.
- Hurwitz TA, Mandat T, Forster B, Honey C (2006). Tract identification by novel MRI signal changes following stereotactic anterior capsulotomy. *Stereotact Funct Neurosurg* 84: 228–235.
- Jenkinson M, Smith S (2001). A global optimisation method for robust affine registration of brain images. *Med Image Anal* 5: 143–156.
- Johansen-Berg H, Behrens TE, Sillery E, Ciccarelli O, Thompson AJ, Smith SM et al (2005). Functional-anatomical validation and individual variation of diffusion tractography-based segmentation of the human thalamus. *Cereb Cortex* 15: 31–39.
- Johansen-Berg H, Gutman DA, Behrens TE, Matthews PM, Rushworth MF, Katz E et al (2008). Anatomical connectivity of the subgenual cingulate region targeted with deep brain stimulation for treatment-resistant depression. *Cereb Cortex* 18: 1374–1383.
- Kelly D, Richardson A, Mitchell-Heggs N, Greenup J, Chen C, Hafner RJ (1973). Stereotactic limbic leucotomy: a preliminary report on forty patients. *Br J Psychiatry* 123: 141–148.
- Kessler RC, Berglund P, Demler O, Jin R, Koretz D, Merikangas KR et al (2003). The epidemiology of major depressive disorder: results from the National Comorbidity Survey Replication (NCS-R). *JAMA* 289: 3095–3105.
- Kim MC, Lee TK, Choi CR (2002). Review of long-term results of stereotactic psychosurgery. *Neurol Med Chir (Tokyo)* 42: 365–371.
- Knight GC (1969). Bi-frontal stereotactic tractotomy: an atraumatic operation of value in the treatment of intractable psychoneurosis. *Br J Psychiatry* 115: 257–266.
- Kotowicz Z (2005). Gottlieb Burckhardt and Egas Moniz—two beginnings of psychosurgery. *Gesnerus* 62: 77–101.
- LeDoux JE (1995). Emotion: clues from the brain. *Annu Rev Psychol* 46: 209–235.
- Lozano AM, Mayberg HS, Giacobbe P, Hamani C, Craddock RC, Kennedy SH (2008). Subcallosal cingulate gyrus deep brain stimulation for treatment-resistant depression. *Biol Psychiatry* 64: 461–467.
- MacLean P (1990). *The Triune Brain in Evolution. Role in Paleocerebral Function*. Plenum Press: New York.
- Malykhin N, Concha L, Seres P, Beaulieu C, Coupland NJ (2008). Diffusion tensor imaging tractography and reliability analysis for limbic and paralimbic white matter tracts. *Psychiatry Res* 164: 132–142.
- Mayberg HS (2009). Targeted electrode-based modulation of neural circuits for depression. *J Clin Invest* 119: 717–725.
- Mayberg HS, Lozano AM, Voon V, McNeely HE, Seminowicz D, Hamani C et al (2005). Deep brain stimulation for treatment-resistant depression. *Neuron* 45: 651–660.
- Mazziotta J, Toga A, Evans A, Fox P, Lancaster J, Zilles K et al (2001). A probabilistic atlas and reference system for the human brain: International Consortium for Brain Mapping (ICBM). *Philos Trans R Soc Lond B Biol Sci* 356: 1293–1322.
- McNeely HE, Mayberg HS, Lozano AM, Kennedy SH (2008). Neuropsychological impact of Cg25 deep brain stimulation for treatment-resistant depression: preliminary results over 12 months. *J Nerv Ment Dis* 196: 405–410.
- Meyerson B, Mindus P (1988). The role of anterior internal capsulotomy in psychiatric surgery. In: Lunsford L (ed.). *Modern stereotactic Neurosurgery*. Martinus Nijhoff Publishing: Boston. pp 353–364.
- Mitchell-Heggs N, Kelly D, Richardson A (1976). Stereotactic limbic leucotomy—a follow-up at 16 months. *Br J Psychiatry* 128: 226–240.
- Moniz E. (1937). Prefrontal leucotomy in the treatment of mental disorders. *Am J Psychiatry* 93: 1379–1385.
- Montoya A, Weiss AP, Price BH, Cassem EH, Dougherty DD, Nierenberg AA et al (2002). Magnetic resonance imaging-guided stereotactic limbic leucotomy for treatment of intractable psychiatric disease. *Neurosurgery* 50: 1043–1049; discussion 1049–1052.
- Mori S, Oishi K, Jiang H, Jiang L, Li X, Akhter K et al (2008). Stereotactic white matter atlas based on diffusion tensor imaging in an ICBM template. *Neuroimage* 40: 570–582.
- Northoff G (2010). Humans, brains, and their environment: marriage between neuroscience and anthropology? *Neuron* 65: 748–751.
- Northoff G, Heinzel A, de Greck M, Bempohl F, Dobrowolny H, Panksepp J (2006). Self-referential processing in our brain—a meta-analysis of imaging studies on the self. *Neuroimage* 31: 440–457.
- Panksepp J (1998). *Affective Neuroscience—The Foundation of Human and Animal Emotions*. Oxford University Press: New York.
- Papez JW (1995). A proposed mechanism of emotion 1937. *J Neuropsychiatry Clin Neurosci* 7: 103–112.
- Paul SM, Heath RG, Ellison JP (1973). Histochemical demonstration of a direct pathway from the fastigial nucleus to the septal region. *Exp Neurol* 40: 798–805.
- Richardson A (1973). Stereotactic limbic leucotomy: surgical technique. *Postgrad Med J* 49: 860–864.
- Rorden C, Bonilha L, Nichols TE (2007). Rank-order versus mean based statistics for neuroimaging. *Neuroimage* 35: 1531–1537.
- Schlaepfer TE, Cohen MX, Frick C, Kosel M, Brodessaer D, Axmacher N et al (2008). Deep brain stimulation to reward circuitry alleviates anhedonia in refractory major depression. *Neuropsychopharmacology* 33: 368–377.

- Schmahmann JD, Pandya DN, Wang R, Dai G, D'Arceuil HE, de Crespigny AJ *et al* (2007). Association fibre pathways of the brain: parallel observations from diffusion spectrum imaging and autoradiography. *Brain* **130**(Part 3): 630–653.
- Shelton RC, Osuntokun O, Heinloth AN, Corya SA (2010). Therapeutic options for treatment-resistant depression. *CNS Drugs* **24**: 131–161.
- Spiegel EA, Wycis HT, Marks M, Lee AJ (1947). Stereotaxic apparatus for operations on the human brain. *Science* **106**: 349–350.
- Steele JD, Christmas D, Eljamel MS, Matthews K (2008). Anterior cingulotomy for major depression: clinical outcome and relationship to lesion characteristics. *Biol Psychiatry* **63**: 670–677.
- Talairach J, Hecaen H, David M (1949). Lobotomie prefrontale limitee par electrocoagulation des fibres thalamo-frontalis leur emergence du bras anterior de la capsule interne. In Proceedings of the 4th Congress Neurologique Internationale, Paris, Masson, p 141.