

Endoscopic transpapillary gallbladder drainage with replacement of a covered self-expandable metal stent

Kazumichi Kawakubo, Hiroyuki Isayama, Naoki Sasahira, Yousuke Nakai, Hirofumi Kogure, Takashi Sasaki, Kenji Hirano, Minoru Tada, Kazuhiko Koike

Kazumichi Kawakubo, Hiroyuki Isayama, Naoki Sasahira, Yousuke Nakai, Hirofumi Kogure, Takashi Sasaki, Kenji Hirano, Minoru Tada, Kazuhiko Koike, Department of Gastroenterology, Graduate School of Medicine, The University of Tokyo, Tokyo 113-8655, Japan

Author contributions: Kawakubo K, Isayama H, Sasahira N, Kogure H and Nakai Y designed the research; Sasaki T, Hirano K and Tada M criticized the paper for important intellectual content; Koike K finally approved the paper; Kawakubo K wrote the article.

Correspondence to: Hiroyuki Isayama, MD, Department of Gastroenterology, Graduate School of Medicine, The University of Tokyo, 7-3-1, Hongo, Bunkyo-ku, Tokyo 113-8655, Japan. isayama-2im@h.u-tokyo.ac.jp

Telephone: +81-3-38155411 Fax: +81-3-38140021

Received: September 1, 2010 Revised: October 26, 2010

Accepted: November 2, 2010

Published online: February 16, 2011

© 2010 Baishideng. All rights reserved.

Key words: Self-expandable metal stent; Cholecystitis; Endoscopic transpapillary gallbladder drainage

Peer reviewers: Viktor Ernst Eysselein, MD, Professor of Medicine, Division of Gastroenterology, Harbor-UCLA Medical Center, Torrance, CA 90509, United States; Jong Ho Moon, MD, PhD, Professor of Medicine, Soon Chun Hyang University School of Medicine; Digestive Disease Center, Soon Chun Hyang University Bucheon Hospital, Bucheon 420-767, South Korea

Kawakubo K, Isayama H, Sasahira N, Nakai Y, Kogure H, Sasaki T, Hirano K, Tada M, Koike K. Endoscopic transpapillary gallbladder drainage with replacement of a covered self-expandable metal stent. *World J Gastrointest Endosc* 2011; 3(2): 46-48 Available from: URL: <http://www.wjgnet.com/1948-5190/full/v3/i2/46.htm> DOI: <http://dx.doi.org/10.4253/wjge.v3.i2.46>

Abstract

Endoscopic self-expandable metal stent (SEMS) placement has become a standard palliative therapy for patients with malignant biliary obstruction. Acute cholecystitis after SEMS placement is a serious complication. We report a patient with an acute cholecystitis after covered SEMS placement, who was managed successfully with endoscopic transpapillary gallbladder drainage (ETGBD) and replacement of the covered SEMS. An 85-year-old man with pancreatic cancer suffered from acute cholecystitis after covered SEMS placement. It was impossible to perform percutaneous transhepatic gallbladder drainage. After removal of the covered SEMS with a snare, a 7Fr double pigtail stent was placed between the gallbladder and duodenum, subsequently followed by another covered SEMS insertion into the common bile duct beside the gallbladder stent. The cholecystitis improved immediately after ETGBD. ETGBD with replacement of the covered SEMS thus proved to be effective for treatment of patients with acute cholecystitis after covered SEMS placement.

INTRODUCTION

Endoscopic self-expandable metal stent (SEMS) placement has become a standard palliative therapy for patients with malignant biliary obstruction^[1]. There is, however, a need to prevent and manage stent-related complications. Acute cholecystitis after SEMS placement is a serious complication, and tumor involvement at the orifice of the cystic duct (CD) is a risk factor^[2,3]. Some patients with cholecystitis improve with conservative therapy, while others require percutaneous drainage. We report a patient with acute cholecystitis after covered SEMS placement, who was managed successfully with endoscopic transpapillary gallbladder stenting and replacement of the covered SEMS.

CASE REPORT

An 85-year-old man with malignant biliary obstruction

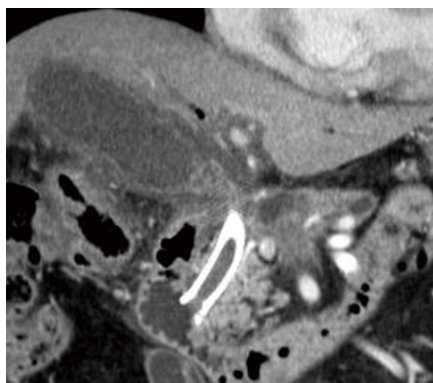


Figure 1 Computed tomography of the abdomen shows swelling of the gallbladder, wall thickening, and the previously placed covered metal stent.

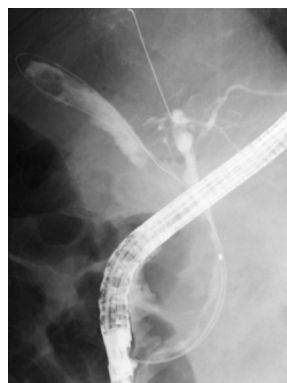


Figure 3 Cholangiogram showing the guidewire being placed in the gallbladder and intrahepatic duct.

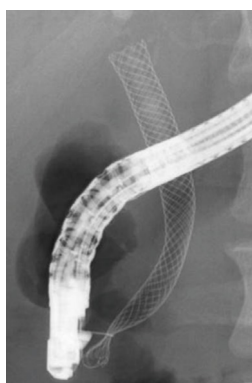


Figure 2 Fluoroscopic image showing the covered self-expandable metal stent grasped with a snare.

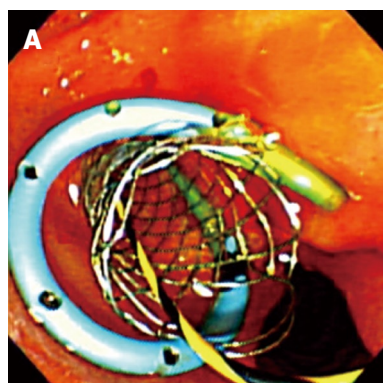
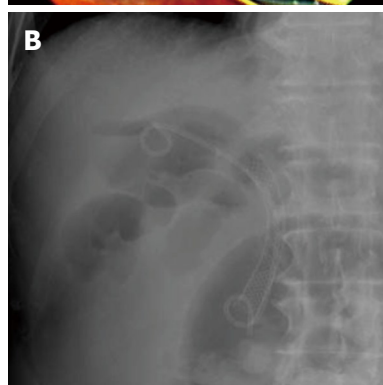


Figure 4 The transpapillary gallbladder stent and covered metal stent. A: Endoscopic image; B: Fluoroscopic image.



due to pancreatic cancer underwent endoscopic covered SEMS (diameter 10 mm, length 8 cm, partially covered Wallflex, Boston Scientific, Natick, MA, USA) placement. There was a tumor at the orifice of the CD, as demonstrated by cholangiography and intraductal ultrasound. After successful biliary drainage, he was given gemcitabine chemotherapy as an outpatient. 25 d after SEMS placement, he presented to the emergency unit with a fever and right upper abdominal pain. Computed tomography revealed acute cholecystitis, which did not resolve with conservative therapy (Figure 1). Due to the lack of a window for percutaneous transhepatic gallbladder drainage, endoscopic drainage was performed.

The orifice of the CD overlapped the previously placed covered SEMS, so we needed to remove the covered SEMS to gain access to the gallbladder. First, a duodenoscope was passed into the duodenum, and the covered SEMS was removed with a snare through the duodenoscope (Figure 2). Then, the orifice of the CD was negotiated with a sphincterotome (Clevercut; Olympus, Tokyo, Japan) and a 0.035-inch \times 260-cm hydrophilic guidewire (Radifocus; Terumo, Tokyo, Japan). Following the approach to the gallbladder, the hydrophilic guidewire was replaced with a 0.035-inch \times 460-cm stiff guidewire (Revowave; Piolax Medical Devices, Kanagawa, Japan; Figure 3). After withdrawing the sphincterotome, a 7Fr double pigtail stent (Zimmon Biliary Stent; Wilson-Cook Medical, Winston-Salem, NC, USA) was placed between the gallbladder and duodenum. Finally, another covered SEMS (diameter 10 mm, length 6 cm, partially covered WallFlex; Boston Scientific, Natick, MA, USA) was inserted into the common bile duct beside the gallbladder stent

(Figure 4). Immediately after the endoscopic gallbladder drainage, the cholecystitis improved. At follow-up, the cholecystitis had not recurred and the patient resumed chemotherapy. Both gallbladder stent and SEMS were patent until death.

DISCUSSION

Acute cholecystitis is a serious complication following SEMS insertion, with a reported incidence of 4.3%-9.7%. Tumor involvement at the orifice of the CD, as in our case, is a risk factor for cholecystitis^[2,3]. In patients in whom the cholecystitis does not resolve with conservative therapy, percutaneous cholecystostomy may be necessary^[5]. In our patient, however, there was no window for percutaneous transhepatic drainage. Furthermore, percutaneous transhepatic drainage is contraindicated in patients with coagulopathy, anticoagulants, or abundant ascites. Endoscopic transpapillary gallbladder drainage has been recognized as an effective procedure^[4]. To our knowledge,

there is no report of post-SEMS acute cholecystitis having been managed successfully by endoscopic transpapillary gallbladder stenting, with replacement of the covered SEMS. It is difficult to negotiate the orifice of the CD after removing a covered SEMS in patients with malignant biliary obstruction, because most of them have tumor involvement at the orifice of the CD. Intraductal ultrasonography or per-oral cholangioscopy may be useful for detecting the orifice of the CD in such patients. Removability is one of the important features of covered SEMS compared with uncovered SEMS^[5]. For patients with acute cholecystitis after uncovered SEMS placement, in whom transhepatic puncture is not anatomically possible, endoscopic ultrasonography-guided transmural gallbladder stenting is a reasonable alternative to percutaneous cholecystostomy^[6].

Endoscopic transpapillary gallbladder stenting with replacement of the covered SEMS has thus been proved to be safe and effective for treating patients with acute cholecystitis after covered SEMS placement, especially in patients with contraindications for percutaneous gallbladder drainage.

REFERENCES

- 1 **Knyrim K**, Wagner HJ, Pausch J, Vakil N. A prospective, randomized, controlled trial of metal stents for malignant obstruction of the common bile duct. *Endoscopy* 1993; **25**: 207-212
- 2 **Nakai Y**, Isayama H, Tsujino T, Kawabe T, Yashima Y, Yagioka H, Kogure H, Sasaki T, Togawa O, Arizumi T, Ito Y, Matsubara S, Hirano K, Sasahira N, Tada M, Omata M. Intraductal US in the assessment of tumor involvement to the orifice of the cystic duct by malignant biliary obstruction. *Gastrointest Endosc* 2008; **68**: 78-83
- 3 **Isayama H**, Kawabe T, Nakai Y, Tsujino T, Sasahira N, Yamamoto N, Arizumi T, Togawa O, Matsubara S, Ito Y, Sasaki T, Hirano K, Toda N, Komatsu Y, Tada M, Yoshida H, Omata M. Cholecystitis after metallic stent placement in patients with malignant distal biliary obstruction. *Clin Gastroenterol Hepatol* 2006; **4**: 1148-1153
- 4 **Itoi T**, Coelho-Prabhu N, Baron TH. Endoscopic gallbladder drainage for management of acute cholecystitis. *Gastrointest Endosc* 2010; **71**: 1038-1045
- 5 **Kahaleh M**, Tokar J, Le T, Yeaton P. Removal of self-expandable metallic Wallstents. *Gastrointest Endosc* 2004; **60**: 640-644
- 6 **Song TJ**, Park do H, Eum JB, Moon SH, Lee SS, Seo DW, Lee SK, Kim MH. EUS-guided cholecystoenterostomy with single-step placement of a 7F double-pigtail plastic stent in patients who are unsuitable for cholecystectomy: a pilot study (with video). *Gastrointest Endosc* 2010; **71**: 634-640

S- Editor Zhang HN **L- Editor** Herholdt A **E- Editor** Liu N