

Published in final edited form as:

J Med Microbiol. 2007 August ; 56(Pt 8): 1118–1121. doi:10.1099/jmm.0.47222-0.

Diagnosis of a *Trypanosoma lewisi*-like (*Herpetosoma*) infection in a sick infant from Thailand

Nachai Sarataphan¹, Montakan Vongpakorn¹, Bandit Nuansrichay¹, Nonglux Autarkool¹,
Tiemjan Keowkarnkah², Pranee Rodtian³, Roger W. Stich⁴, and Sathaporn Jittapalapong⁵

¹National Institute of Animal Health, Kaset Klang, Chatuchak, Bangkok 10900, Thailand

²Lampang Hospital, Muang, Lampang 52000, Thailand ³Fifth Bureau of Animal Hygiene and

Sanitation, Huaykaew, Chiangmai 50300, Thailand ⁴Department of Veterinary Pathobiology,

University of Missouri, Columbia, MO 65211, USA ⁵Department of Parasitology, Faculty of

Veterinary Medicine, Kasetsart University, Bangkok 10900, Thailand

Abstract

Trypanosomes were observed in a peripheral blood smear from a 45-day-old Thai infant displaying fever, anaemia, cough and anorexia. Human trypanosomiasis is not endemic to Thailand, so parasite identification was undertaken to determine likely sources of the infection. Several morphological parameters of the trypanosomes were similar to those of *Trypanosoma evansi* and statistically different from those of *Trypanosoma lewisi*-like parasites from a naturally infected indigenous rat. However, duplicate PCR assays with primers flanking trypanosome rRNA internal transcribed spacer 1 (ITS1) resulted in amplicons of ~623 bp that corresponded to the expected size for *T. lewisi*-like parasites. The ITS1 sequence from the infant's blood was 98 and 49% identical to *T. lewisi* and *T. evansi* sequences, respectively. Based on molecular results, it was concluded that the infant was infected with a *T. lewisi*-like (*Herpetosoma*) species.

Introduction

Trypanosomes are flagellated protozoan parasites, some of which can cause distinct zoonoses. The genus *Trypanosoma* is divided into two major groups that infect vertebrates, the salivaria and the stercoraria (Hoare, 1964). Although both *Trypanosoma* groups are enzootic to Thailand, human trypanosomiasis has not been reported to date in this country, and reports of human infections with the *Trypanosoma* species enzootic to Thailand are extremely rare worldwide (Johnson, 1933; Joshi *et al.*, 2005; Shrivastava & Shrivastava, 1974). Diagnosis of trypanosomiasis often involves examination of stained blood smears, and identification of *Trypanosoma* species is often based on parasite morphology; however, molecular diagnostic tests to distinguish *Trypanosoma* species are advantageous because morphological biometry can be problematic. A PCR assay has been developed to detect *Trypanosoma lewisi* and *Trypanosoma vivax* in rats (Desquesnes *et al.*, 2002). This assay utilizes primers conserved to 18S and 5.8S rRNA genes (rDNA) that flank the relatively polymorphic internal transcribed spacer 1 (ITS1). Thus, this assay can generate amplicons

© 2007 SGM

Correspondence Sathaporn Jittapalapong, fvetspj@yahoo.com.

The GenBank/EMBL/DDBJ accession no. for the 560 bp ITS1 sequence of the *T. lewisi*-like trypanosome is DQ345394.

A table showing a multiple sequence alignment of ITS1 sequences is available with the online version of this paper.

from divergent *Trypanosoma* species and allow parasite identification through ITS1 sequence analysis.

Case Report

Patient history

On August 28 2005, a 45-day-old male infant was admitted to Lampang Provincial Hospital in northern Thailand (approx. 500 km from Bangkok, Thailand) with coughing, fever, anorexia and depression. The patient was preliminarily diagnosed with dengue based on the high fever, and anti-pyrexia treatment was prescribed. The patient was readmitted on September 4 2005 due to continued fever, anorexia and depression. Blood was collected for a complete haemogram during the second visit, and trypanosomes were observed in a peripheral blood smear. The patient's haemogram indicated 15 100 leukocytes μL^{-1} (45% polymorphonuclear cells, 8% band forms, 40% lymphocytes and 7% monocytes), 11.5 g dl^{-1} haemoglobin and a haematocrit of 31 %. The patient was treated with 25 mg gentamicin in 30 ml sterile water in an intravenous drip for 1 h. Supportive treatment included 5% glucose, vitamins and amino acids. The patient recovered after antibiotic treatment, and parasite identification was undertaken to determine likely sources of this infection. Trypanocidal drugs were avoided due to their toxicity and the patient's positive response to treatment.

Trypanosome biometry

Two trypomastigote morphology types were observed: (1) a slender form with tapered ends, a distinct subterminal kinetoplast, a thin, straight posterior end and a nucleus at the anterior end, and (2) a broad trypomastigote with a large, granular body. Eight morphological parameters of the slender forms were measured to compare with other trypanosomes enzootic to Thailand (Fig. 1). Morphological features were compared to values reported for *T. lewisi*-like and *Trypanosoma evansi* parasites in naturally infected indigenous rats and pigs, respectively (Table 1) (Sarataphan *et al.*, 1986; Natheewattana *et al.*, 1973). One-way analysis of variance and the Tukey posthoc procedure were used to compare the above parameters. Average values for PK, KN and TL differed between trypanosomes in the infant's blood and those in the rat infection. These same values did not differ from those of *T. evansi*. Conversely, the nuclear index (NI) values were 1.4, 1.4 and 0.9, respectively, for trypomastigotes from the infant, rat (*Herpetosoma*) and pigs (*T. evansi*) from Thailand. However, statistical analysis of the kinetoplast index (KI) and NI was not performed due to unavailability of data for these measurements in earlier reports. PN for the infant infection was different from that of *T. evansi*, but this value was not available for *T. lewisi*-like parasites in the Thai rat. No differences were observed for W or F among the three trypanosomes.

Molecular diagnostics

Trypomastigote biometry suggested that these parasites were different from the *T. lewisi*-like parasites described in a naturally infected Thai rat, and there was no morphological evidence of differences between the trypanosomes found in the Thai infant and *T. evansi* enzootic to Thailand. However, the small sample sizes of these reports compelled us to confirm this observation; thus, PCR was used to amplify the region containing the ITS1 sequence between the 18S and 5.8S rRNA genes. This assay facilitates subgenus identification by amplicon size and species identification with ITS1 sequence homology. Heparinized blood from the patient was frozen and stored at $-20\text{ }^{\circ}\text{C}$ prior to DNA isolation with a commercial kit (FlexiGene, Qiagen) according to the manufacturer's protocol. PCR was carried out with primers TRYP1S (CGTCCCTGCCATTTGTACACAC) and TRYP1R (GGAAGCCAAGTCATCCATCG) for amplification of the ITS1 fragment (Desquesnes *et*

al., 2002). The reactions consisted of 50 µl volumes containing 10 mM Tris/HCl, pH 8.3, 50 mM KCl, 1.5 mM MgCl₂, 200 µM each dNTP, 1 µM each primer, 0.25 U *Taq* polymerase (Qiagen), 5% (v/v) DMSO and 5 µl DNA template. Amplicons were purified and directly sequenced in both directions with the same primers used to amplify the DNA template. Sequences were determined and used for multiple-sequence alignment with ITS1 sequences reported for *T. lewisi* in an experimentally infected rat (Desquesnes *et al.*, 2002) and *T. evansi* from Taiwan (GenBank accession no. D89527).

The PCR assay of the infant's blood resulted in amplicons of ~623 bp, which was consistent with the size reported for the stercorarian *T. lewisi* (Fig. 2). Controls included two salivarians, *T. evansi* and *Trypanosoma brucei rhodesiense*, which produced smaller amplicons of ~520 bp. Lengths of the ITS1 sequences were 416, 420 and 340 bp from the Thai infant infection, *T. lewisi* and *T. evansi*, respectively. The ITS1 sequence from the Thai infant was 98% identical to *T. lewisi*, which was due to deletion of 4 bases and mismatches between 5 bases of the respective ITS1 sequences. Conversely, the amplicon generated from the infant's blood was 49% identical to corresponding sequences reported for *T. evansi* from Taiwan. According to a BLAST search of the National Center for Biotechnology Information (NCBI) database, sequences from *T. lewisi*, *Trypanosoma otospermophili* (accession nos AB175625 and AB190228), *Trypanosoma grosi* (accession nos AB175622–AB175624) and an unclassified *Trypanosoma* species (accession no. AB175626) were the closest matches to ITS1 from this patient's blood.

Discussion

Parasite morphology alone suggested that these trypanosomes were indistinguishable from *T. evansi* and dissimilar to a *T. lewisi*-like species, both of which are enzootic to Thailand. However, *T. lewisi*-like trypomastigotes have only been described from a single naturally infected rat (Natheewattana *et al.*, 1973); thus, it is plausible that the rat trypanosome infection was a different species from the one described in this report. Amplicon size and ITS1 sequence analysis both suggested that the infection was *T. lewisi* or a closely related species of the stercorarian subgenus *Herpetosoma*. Thus, these results indicated that the patient was infected with a trypanosome that utilizes fleas and rodents as natural hosts, which was corroborated by the identification of *Ctenocephalides felis* fleas in the infant's dwelling. Although *Herpetosoma* species are thought to be specific to a single vertebrate host genus, they are reported to infect a relatively broad range of flea vectors (Hoare, 1972; Linardi & Botelho, 2002; Molyneux, 1969). Fleas are often opportunistic parasites of available mammalian hosts, thus the patient described in this report could have been exposed to infective fleas from a rodent reservoir other than rats.

The case reported here is similar to a report of human trypanosomiasis associated with a diagnosed *T. lewisi* infection of a 4-month-old Malaysian infant with a 3-week history of lassitude and loss of appetite and a 10-day history of fever (Johnson, 1933). Notably, the infant described in the present report was also found to be feverish and anaemic with a heavy trypanosome infection upon admission. Interestingly, attempts to culture or to infect rats with trypanosomes from the Malaysian child's blood were unsuccessful, suggesting that the infection might not have been *T. lewisi sensu stricto*. *T. lewisi* has since become the type species for *Herpetosoma*, a homogeneous subgenus of several dozen named species that are morphologically indistinguishable, but with various host specificities (Hoare, 1964). Another group has reported a serendipitous diagnosis of '*T. lewisi*-like' (i.e. *Herpetosoma*) infections in a febrile married couple during the Indian malaria eradication program (Shrivastava & Shrivastava, 1974). Taken together, these case reports suggest that these three '*T. lewisi* (-like)' human infections were likely due to unidentified *Herpetosoma*.

In conclusion, to our knowledge, this is the first report of human trypanosomiasis in Thailand. Although an identification based on biometry was inconclusive, due to the limited morphological data for trypanosomes enzootic to Thailand, molecular diagnostics were indicative of a *T. lewisi*-like infection in this baby. Thus, rodents and fleas appear to be environmental risks for exposure to the parasites described in this report, rather than the presence of livestock and biting flies associated with exposure to *T. evansi*, such as in a case recently reported from India (Joshi *et al.*, 2005). Further work is warranted to survey potential vertebrate and invertebrate hosts of both *Trypanosoma* subgenera in Thailand.

Abbreviations

ITS1	internal transcribed spacer 1
KI	kinetoplast index
NI	nuclear index.

Acknowledgments

The authors gratefully acknowledge the generous assistance of staff members from Lampang Hospital and The Fifth Bureau of Animal Hygiene and Sanitation, Huaykaew, Chiangmai, for providing records and essential information. We also thank Professor Ikuo Igarashi, Director of the National Research Center for Protozoan Disease, Obihiro University of Agriculture and Veterinary Medicine, Japan, who kindly provided control DNA samples from *T. evansi* (Tansui, Taiwan isolate, D89527) and *T. brucei rhodesiense* (IL1501). This report was supported by Kasetsart University Research Development Institution (S. J.) and National Institutes of Health AI47932 (R. W. S.).

References

- Desquesnes M, Ravel S, Cuny G. PCR identification of *Trypanosoma lewisi*, a common parasite of laboratory rats. *Kinetoplastid Biol Dis.* 2002; 1:2. [PubMed: 12234387]
- Hoare CA. Morphologic and taxonomic studies on mammalian trypanosomes. X. Revision of the systematics. *J Protozool.* 1964; 11:200–207. [PubMed: 14179743]
- Hoare, CA. *The Trypanosomes of Mammals. A Zoological Monograph.* Oxford and Edinburgh: Blackwell Scientific Publications; 1972.
- Johnson PD. A case of infection by *Trypanosoma lewisi* in a child. *Trans R Soc Trop Med Hyg.* 1933; 26:467.
- Joshi PP, Shegokar VR, Powar RM, Herder S, Katti R, Salkar HR, Dani VS, Bhargava A, Jannin J, Truc P. Human trypanosomiasis caused by *Trypanosoma evansi* in India: the first case report. *Am J Trop Med Hyg.* 2005; 73:491–495. [PubMed: 16172469]
- Linardi PM, Botelho JR. Prevalence of *Trypanosoma lewisi* in *Rattus norvegicus* from Belo Horizonte, State of Minas Gerais, Brazil. *Mem Inst Oswaldo Cruz.* 2002; 97:411–414. [PubMed: 12048574]
- Molyneux DH. Intracellular stages of *Trypanosoma lewisi* in fleas and attempts to find such stages in other trypanosome species. *Parasitology.* 1969; 59:737–744.
- Natheewattana N, Hongsbhanich L, Khamboonruang C, Thitasut P. Preliminary study of a *Trypanosoma lewisi*-like parasite of rats in Chiang Mai, Thailand. *Southeast Asian J Trop Med Public Health.* 1973; 4:322–323. [PubMed: 4588621]
- Sarataphan, N.; Siriwan, C.; Punyahotra, R.; Mekamol, C.; Meephuch, Y.; Assavamahasakda, C. Trypanosomiasis in pigs; The Sixth Annual Conference of Thailand Livestock Development; Bangkok, Thailand: Ministry of Agriculture; 1986.
- Shrivastava KK, Shrivastava GP. Two cases of *Trypanosoma* species infection of man in India. *Trans R Soc Trop Med Hyg.* 1974; 68:3–4. [PubMed: 4818660]

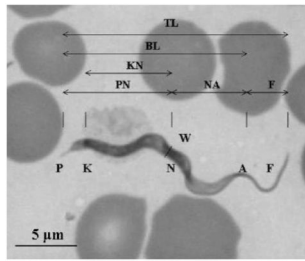
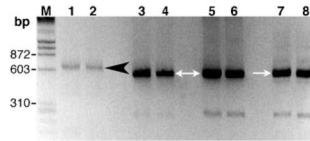


Fig. 1. Morphological parameters of trypanosomes from a Thai infant

Locations of different features and organelles are indicated by letters. Distances measured were: PN, posterior end to nucleus centre; NA, nucleus centre to the anterior end; PK, posterior end to kinetoplast centre; KN, kinetoplast centre to nucleus centre; W, parasite maximum width; F, free flagellum length; BL, posterior to anterior end; TL, total parasite length. These values were also used to calculate the NI ($NI = PN/NA$) and KI ($KI = PN/KN$). Bar, 5 μ m.

**Fig. 2. PCR of trypanosomes in the patient's blood**

Amplicons that included ITS1 of trypanosome-specific rDNA were generated with primers TRYP1S and TRYP1R and visualized on an agarose gel stained with ethidium bromide. The molecular size standard (M) was λ phage DNA digested with *Hind*III and ϕ X DNA digested with *Hae*III. Lanes: 1–2, blood sample from the Thai infant in duplicate assays; 3–4, *T. evansi* (Thailand); 5–6, *T. evansi* (Taiwan); 7–8, *T. brucei rhodesiense* (IL1501). The 520 and 623 bp amplicons are indicated by white arrows and a black arrowhead, respectively.

Table 1

Known morphological parameters of trypanosomes enzootic to Thailand

Infection	Morphological parameter measurements (mean±SD)*									
	PN (µm)	NA (µm)	PK (µm)	KN (µm)	W (µm)	F (µm)	TL (µm)	BL (µm)	NI	KI
Infant (n=20)	10.0±1.3 [‡]	7.5±2.0 [‡]	2.3±0.9 [‡]	7.8±1.3 [‡]	1.9±1.3	6.4±0.7 [‡]	23.9±1.4 [‡]	17.5±2.0	1.4	1.3
Rat (n=11)	NR [‡]	9.7±2.9 [§]	4.2±2.8 [§]	9.5±2.8 [§]	2.7±3.4	7.8±4.5 ^{‡§}	31.8±6.4 [§]	NR	1.4	1.4
<i>T. evansi</i> (n=60)	8.0±0.3 [§]	9.2±0.6 ^{‡§}	1.9±0.3 [‡]	6.1±0.1 [‡]	1.5±0.3	4.2±1.1 [§]	21.0±0.6 [‡]	16.7±0.6	0.9	1.3

* Parameters correspond to those described in Fig. 1.

^{‡,§}For each parameter, values marked with different symbols differ ($P<0.05$) according to Tukey posthoc analysis.

[‡]Not reported (Natheewattana *et al.*, 1973).