

Single-Incision Laparoscopic-Assisted Right Colon Resection for Cancer

David J. O'Connor, MD, Elyssa Feinberg, MD, Jinsuk Jang, BS,
Pratibha Vemulapalli, MD, Diego Camacho, MD

ABSTRACT

Introduction: We present an approach to laparoscopic right colon resection utilizing a single port placed through the umbilicus. The technique described is performed through a single small umbilical incision with a virtually scar-free result.

Methods: A 77-year-old woman with a tubulovillous adenoma in her cecum underwent a laparoscopic right colectomy using a single port placed through the umbilicus. Straight and reticulating laparoscopic instruments were utilized.

Results: The total operative time was 112 minutes. No intraoperative or postoperative complications occurred. The patient was discharged home on day 5 postoperatively with normal bowel function and tolerance of a solid diet.

Conclusions: Laparoscopic right colectomy can be safely performed through a single incision through the umbilicus with an excellent cosmetic result.

Key Words: Laparoscopy, Single-site surgery, Transumbilical colectomy, Single laparoscopic incision transabdominal surgery.

INTRODUCTION

Several reports have shown advantages of laparoscopic colon resection compared with conventional open surgery, including less scarring, decreased narcotic use, quicker return of bowel function, and fewer wound complications.¹⁻⁴ Recent research has focused on further limiting surgical incisions in laparoscopic surgery. Several reports have examined use of a single incision through the umbilicus for appendectomy, cholecystectomy, urologic procedures, and splenectomy.⁵⁻⁸ This approach yields an essentially scar-free procedure through the umbilicus with the use of conventional laparoscopic techniques. Recently, colon resection has been performed through this technique with excellent initial results.⁹⁻¹²

We report a case of a single-incision, single-port laparoscopic right colectomy for cancer using straight and articulated laparoscopic instruments.

METHODS

We report our initial experience of laparoscopic single-port access right colectomy in a 77-year-old woman with a tubulovillous adenoma in the cecum diagnosed by routine colonoscopy. The adenoma measured 1.5cm in diameter, and endoscopic removal was unsuccessful. After risks, benefits, and potential complications were explained, the patient agreed to the procedure. Successful single-incision laparoscopic surgery (SILS) was performed.

Surgical Technique

After general anesthesia was administered to the patient, and the abdomen was prepped and draped in standard surgical fashion. A 3-cm incision was created through the umbilicus. The fascia was opened in the region of the incision, and a single SILS port (Covidien, Mansfield, MA) was inserted into the opening. Pneumoperitoneum was created to a pressure of 15mm Hg. A 5-mm, 30-degree laparoscope (Stryker, Kalamazoo, MI) with both straight and reticulating laparoscopic instruments (Covidien, Mansfield, MA) were used. The terminal ileum, cecum, and ascending colon were mobilized from the line of Toldt to the midline by using electrocautery. Small bleed-

Department of Surgery, Montefiore Medical Center, Albert Einstein College of Medicine, Bronx, New York, USA (all authors).

Address correspondence to: David J. O'Connor, MD, 3400 Bainbridge Avenue, Bronx, NY 10467, USA. Telephone: (718) 920-4800, Fax: 718-231-4823, E-mail: daoconno@montefiore.org

DOI: 10.4293/108680810X12924466008367

© 2010 by JSLS, Journal of the Society of Laparoendoscopic Surgeons. Published by the Society of Laparoendoscopic Surgeons, Inc.

ers encountered were cauterized. The right ureter was identified and preserved.

Once mobilization was complete, the single port was removed and the incision was extended to 5cm total in length to facilitate exteriorization of the specimen (**Figure 1**). The terminal ileum, cecum, and ascending colon were then brought outside the abdomen. A GIA 3.5-mm stapler (Covidien, Mansfield, MA) was used to divide the terminal ileum and the ascending colon. The mesentery was then clamped, divided, and suture ligated by using 2-0 silk. Two enterotomies were created, one on the colon side and the other on the ileum, to facilitate a side-to-side stapled anastomosis. A GIA 3.5-mm stapler (Covidien, Mansfield, MA) was used to create the new lumen. Following this, the enterotomy was closed with a 3.5-mm TA-60 (Covidien, Mansfield, MA) stapling device. We closed the mesentery by using 2-0 silk figure-of-eight sutures. The anastomosis was then pushed back into the abdomen without signs of bleeding. The fascia was closed with running PDS, and the skin was reapproximated with 4-0 Monocryl (**Figure 2**).

RESULTS

Total operative time was 112 minutes. The surgical specimen contained moderately differentiated adenocarcinoma of the cecum with negative margins and contained 14 lymph nodes without cancer involvement, with specimen length of 16cm. Blood loss was minimal, and no intraoperative or postoperative complications occurred. The patient was discharged home on day 5 postoperatively with normal bowel function and tolerance of a solid diet.

DISCUSSION

Single-incision laparoscopic surgery offers the benefits of minimal scarring and pain but conventional laparoscopic techniques are still used. Single-port laparoscopic surgery is increasingly being utilized for a variety of surgical techniques including appendectomy, cholecystectomy, nephrectomy, splenectomy, and colon resections with recovery and complication rates similar to rates of standard laparoscopic techniques.^{5-8,13}

Our case demonstrates a technique for laparoscopic-assisted colon resection using conventional laparoscopic techniques through a single incision. Using the umbilicus for insertion of the single port allows for a concealed scar. A single multi-channel port with curved instruments allowed us to perform enough mobilization of the right

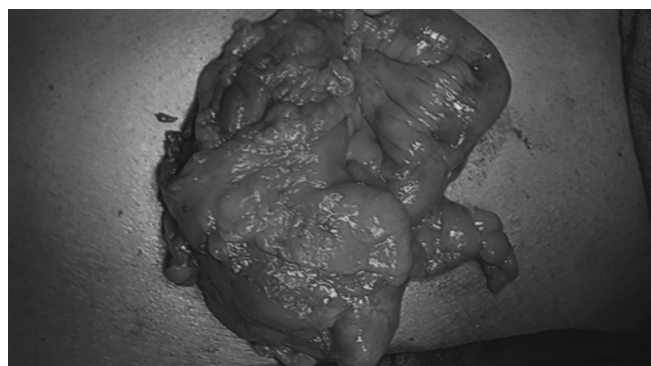


Figure 1. The right colon is exteriorized after removal of the umbilical port in preparation for resection and anastomosis.

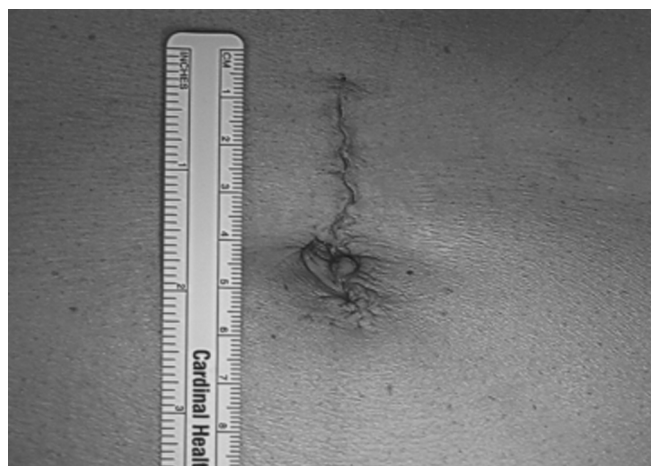

Figure 2. Surgical incision after completion of the procedure.

colon to facilitate exteriorization of the right colon and terminal ileum to facilitate extracorporeal mesenteric ligation and stapled colonic anastomosis. This technique facilitated a safe oncologic practice, with the removal of 14 lymph nodes and a 16-cm length of colon.

Remzi et al¹⁰ and Bucher et al⁹ have also reported single-incision laparoscopic right colon resection. Their techniques have also utilized a single multi-channel port inserted via the umbilicus with subsequent mobilization of the right colon and extracorporeal anastomosis. The report by Remzi and his colleagues described right colon removal for a cecal polyp. Their technique included endoscopic ligation of the ileocolic artery using a LigaSure device (Covidien Ltd., Norwalk, CT).¹⁰ This report, however, did not comment on the number of lymph nodes removed or the final pathology of the polyp. Bucher performed a single-incision laparoscopic colectomy for a 5-cm ascending colon polyp. The ileocolic pedicle was ligated using an extracorporeal knot; however, an addi-

tional transparietal suture was required to retract the colon for adequate exposure.⁹ They also reported safe oncologic results, removing 33 lymph nodes and 38cm of colonic specimen.⁹

Recent reports^{9–12} have shown favorable results with transumbilical SILS applied to colonic resections. Laparoscopic mobilization with extracorporeal anastomosis is feasible technically with acceptable operative times. The mesenteric vasculature can be controlled using endoscopic or extracorporeal ligation. The benefits of single-incision surgery are both functional and cosmetic. The risk involved with Veress needle or Hassan trocar insertion is eliminated as well by making an initially larger fascial opening with direct insertion of a single soft port. The use of fewer trocars also potentially reduces the risk of future incisional hernias because fewer incisions are created.¹⁴

CONCLUSION

Oncologic principles can be maintained with this technique, along with fast patient recovery and low morbidity. With the developments of single multi-port trocars and articulating instruments, transumbilical colon surgery has become more feasible and provides a safe alternative to standard laparoscopic colon surgery.

References:

1. Rosman AS, Melis M, Fichera A. Metaanalysis of trials comparing laparoscopic and open surgery for Crohn's disease. *Surg Endosc.* 2005;19:1549–1555.
2. Tong D, Law W. Laparoscopic versus open right colectomy for carcinoma of the colon. *JLS.* 2007;11:76–80.

3. Guller U, Jain N, Harvey S, Purves H, Pietrobon R. Laparoscopic versus open colectomy: Outcomes comparison based on large nationwide databases. *Arch Surg.* 2003;138:1178–1186.
4. Klarenbeek B, Veenhof A, de Lange E, et al. The Sigma-trial protocol: a prospective double-blind multicentre comparison of laparoscopic versus open elective sigmoid resection in patients with symptomatic diverticulitis. *BMC Surg.* 2007;3:16.
5. Piskun G, Rajpal S. Transumbilical laparoscopic cholecystectomy utilizes no incisions outside the umbilicus. *J Laparoendosc Adv Surg Tech A.* 1999;9:361–364.
6. Rispoli G, Armellino MF, Esposito C. One-trocar appendectomy. *Surg Endosc.* 2002;16:833–835.
7. Kaouk JH, Haber GP, Goel RK, et al. Single-port laparoscopic surgery in urology: initial experience. *Urology.* 2008;71:3–6.
8. Barbaros U, Dincag A. Single incision laparoscopic splenectomy: the first two cases. *J Gastrointest Surg.* 2009;8:1520–1523.
9. Bucher P, Pugin F, Morel P. Single port access laparoscopic right hemicolectomy. *Int J Colorectal Dis.* 2008;23:1013–1016.
10. Remzi F, Firat H, Kaouk J, Geisler D. Single-port laparoscopy in colorectal surgery. *Colorectal Dis.* 2008;10:823–826.
11. Bucher P, Pugin F, Morel P. Single port laparoscopic colectomy. *Colorectal Dis.* 2009;11:101.
12. Bucher P, Pugin F, Morel P. Transumbilical single incision laparoscopic sigmoidectomy for benign disease. *Colorectal Dis* 2009;12:61–65.
13. Marescaux J, Dallemagne B, Wattiez A, et al. Surgery without scars: report of transluminal cholecystectomy in a human being. *Arch Surg.* 2007;142:823–826.
14. Bhojru S, Payne J, Steffes B, Swanstrom L, Way L. A randomized prospective study of radially expanding trocars in laparoscopic surgery. *J Gastrointest Surg.* 2000;4:392–397.