

# Body contouring following massive weight loss

Vijay Langer, Amitabh Singh<sup>1</sup>, Al S. Aly<sup>2</sup>, Albert E. Cram<sup>3</sup>

Department of Surgery and Plastic Surgery, Armed Forces Medical College, Pune, Maharashtra, <sup>1</sup>Department of Plastic Surgery, Fortis Hospital, Vasant Kunj, New Delhi, India, <sup>2</sup>Department of Plastic Surgery, University of California Irvine, Aesthetic and Plastic Surgery Institute, Orange, California, <sup>3</sup>Dept of Plastic Surgery, Iowa City Plastic Surgery, Iowa City, Iowa, USA.

**Address for correspondence:** Dr. Vijay Langer, Department of Surgery and Plastic Surgery, Armed Forces Medical College, Pune, Maharashtra - 411 040, India. E-mail: vlangz@gmail.com

## ABSTRACT

Obesity is a global disease with epidemic proportions. Bariatric surgery or modified lifestyles go a long way in mitigating the vast weight gain. Patients following these interventions usually undergo massive weight loss. This results in redundant tissues in various parts of the body. Loose skin causes increased morbidity and psychological trauma. This demands various body contouring procedures that are usually excisional. These procedures are complex and part of a painstaking process that needs a committed patient and an industrious plastic surgeon. As complications in these patients can be quite frequent, both the patient and the surgeon need to be aware and willing to deal with them.

## KEY WORDS

Breast reshaping; brachioplasty; body contouring; belt lipectomy; medial thigh lift; morbid obesity; massive weight loss; upper body lift

## UNDERSTANDING THE PROBLEM

India is at the crossroads of many diseases. On one hand, we have not been able to conquer the communicable diseases. On the other, medical problems of the affluent have fast caught up with us. Obesity is a worldwide epidemic affecting over 1.1 billion people.<sup>[1]</sup> Of the Indian population 5% is morbidly obese. With a flood of “fast-food joints” drowning our society and the common urban man not having time for a healthy life-style, we are staring down the barrel.

What is more worrying is the rapid increase in childhood obesity. Apart from that, since surgical procedures in general are more economical in India, many obese patients have started thronging to the medical tourism capital of the world.

Obesity, defined as a body mass index (BMI) equal to or greater than 30, is associated with a high risk of morbidity and mortality. Fortunately bariatric surgery often leads to massive weight loss (MWL) that is considered as 100 pounds (approximately 45.45 kg) or more. Shermak *et al.* defined MWL as 50% or greater loss of excess weight.<sup>[2]</sup> This often results in redundant tissues of the lower trunk, upper back, breasts, arms, and thighs. Loose skin often causes intertrigo, difficulty in walking, urinating, or performing sexual activity, and consequent low self-esteem. This necessitates various body contouring procedures, usually excisional, in these patients [Figures 1–8]. The weight loss occurs over

Access this article online	
Quick Response Code: 	Website: <a href="http://www.ijps.org">www.ijps.org</a>
	DOI: 10.4103/0970-0358.81439

1–3 years after intervention and therefore, body contouring procedures are undertaken once the weight has stabilized. This usually takes 12–24 months. Owing to the above, this article attempts to unveil the mystery that shrouds body-contouring procedures and prepare the Indian plastic surgeon to undertake these daunting procedures in patients fraught with complications.

## APPROACH TO THE MASSIVE WEIGHT LOSS PATIENT

These patients are often not well educated about obesity and the body-contouring procedures that they can undergo; many request liposuction when in reality most should undergo excisional procedures. Liposuction may be included at surgery, but as a sole modality of treatment, it often fails. Bariatric surgeons and endocrinologists have a different emphasis from that of plastic surgeons when treating the obese and they may neglect to inform patients about body changes after MWL. So the plastic surgeon has to take the added role of educator. All the details of body-contouring procedures including possible complications are discussed with the patient. They are made to understand that most, if not all, of these procedures are major life events and not to be taken casually. They are also told about the probability of undergoing multiple procedures, as it is not safe to tackle all of these areas in a single operative event. After belt lipectomy surgery, a circumferential excisional procedure of the lower trunk, most patients require a minimum of 4 weeks to return to work on a limited basis and resume normal physical activity in 6 to 8 weeks. As many of these patients have psychiatric problems, counseling, especially in the peri-operative period is of immense value. Surgery should be desisted in patients who are medically or psychiatrically

unstable. Patients with significant cardiopulmonary disease and active smokers should be excluded. If smokers are chosen for surgery, they should stop smoking 2 weeks prior to up to 4 weeks after surgery to minimize wound-healing complications. The patient prior to surgery signs a comprehensive consent form including consent for photography and is asked to stop any anti-platelet drugs 1 week prior to surgery.

MWL patients are quite variable in their presentation despite having multiple problems in common. There are three factors that play a role in this diversity; namely their BMI at presentation, their fat deposition pattern, and the quality of skin-fat envelope. MWL patients stabilize at a particular BMI after weight loss which may differ from patient to patient. It is wise for the plastic surgeon to consult with the bariatric surgeon before considering body-contouring surgery to determine whether or not the patient has reached the final plateau. All humans pose genetically controlled fat deposition patterns as well as fat loss patterns. Males generally deposit more visceral fat as they gain weight while females tend to deposit more extra-peritoneal fat. Asking the patient to lie supine can help the plastic surgeon identify the extent of intra-abdominal or visceral fat; if the abdomen is scaphoid in the supine position, it is likely that abdominal wall plication will be successful in flattening the belly contour. Conversely, if the abdomen is convex in the supine position, it is unlikely that abdominal wall plication will be effective. In general, the lower the BMI at presentation, the better the result of body contouring. The quality of the skin-fat envelope of the MWL patients also affects their presentation and treatment. Patients with large BMI drops exhibit more redundancy and laxity than those with small BMI drops. Patients with thick fat layers after MWL have a nonpliable

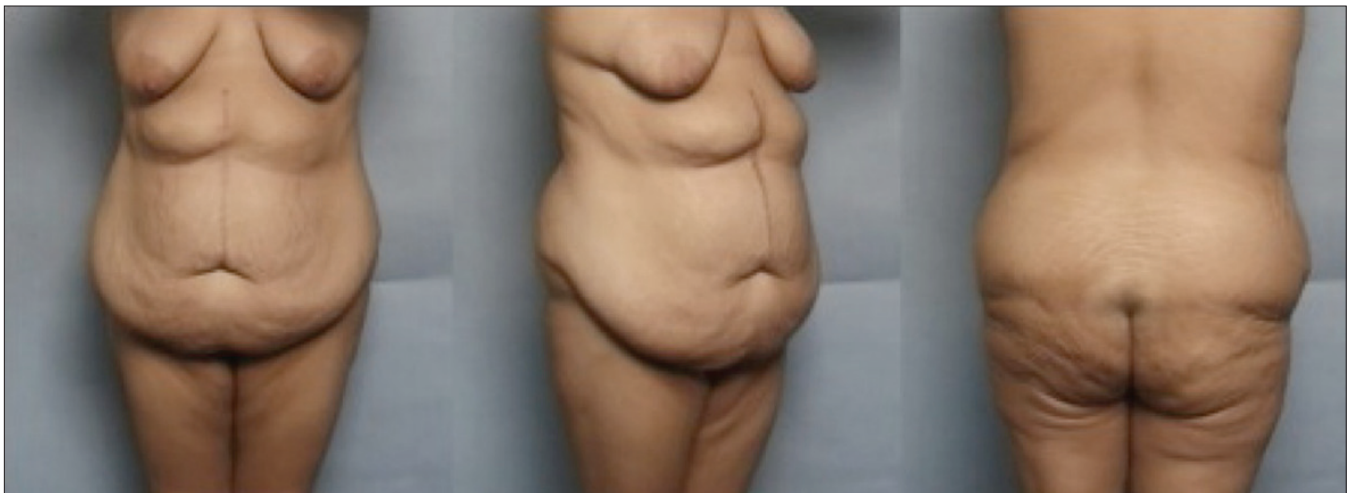

Figure 1: A patient following massive weight loss with typical lower truncal deformities

envelope while a thin layer of subcutaneous fat allows freer movement of the overlying skin. As a general rule, large BMI drops are associated with more excess skin and thinner subcutaneous fat at presentation, and small BMI drops are associated with less excess skin and thicker subcutaneous fat at presentation. Generally, the more skin that is resected during dermatolipectomies, the better the contour that can be created. The effect of resection in any part of the body on soft tissue structures located at a distance from the line of resection is referred to as “translation of pull,” which is helpful in predicting the results of excisional body-contouring procedures. This is especially applicable in the lower trunk.

## **BODY-CONTOURING PROCEDURES**

For purpose of description of most types of body-contouring procedures following MWL, they have been divided into lower body lift/belt lipectomy, thigh lift, brachioplasty, upper body lift, and breast reshaping. Panniculectomy or abdominoplasty may be good procedures to tackle intertrigo but do little to improve body contour in the MWL patient and therefore will not be discussed in this article. This is despite high lateral tension abdominoplasty<sup>[3]</sup> improving the contour of the waist, buttocks, and thighs. The superficial fascial system (SFS) devised by Lockwood is the key to all modern excisional lifts in these patients.<sup>[4]</sup> While he advocated nonabsorbable sutures for better rejuvenation, most workers today use long-standing absorbable sutures such as polydioxanone. In patients undergoing procedures on the trunk and the lower body, an epidural catheter is invaluable in post-operative pain management and may also reduce the incidence of deep venous thrombosis (DVT) and its sequelae. The operative time should preferably be kept under 6 hours or below to minimize complications. If vectors of pull at surgery are in opposite directions, such as in an upper body lift and a belt lipectomy/lower body lift, these procedures should be performed separately for obvious reasons. Hernias should be repaired at the same time of lower truncal body-contouring procedures in most instances. Scars of previous surgical procedures, especially chevron cholecystectomy scars, present potential problems with body-contouring procedures that involve the abdomen. Caution and special adjustments should be made when dealing with these scars.

## **LOWER BODY LIFT**

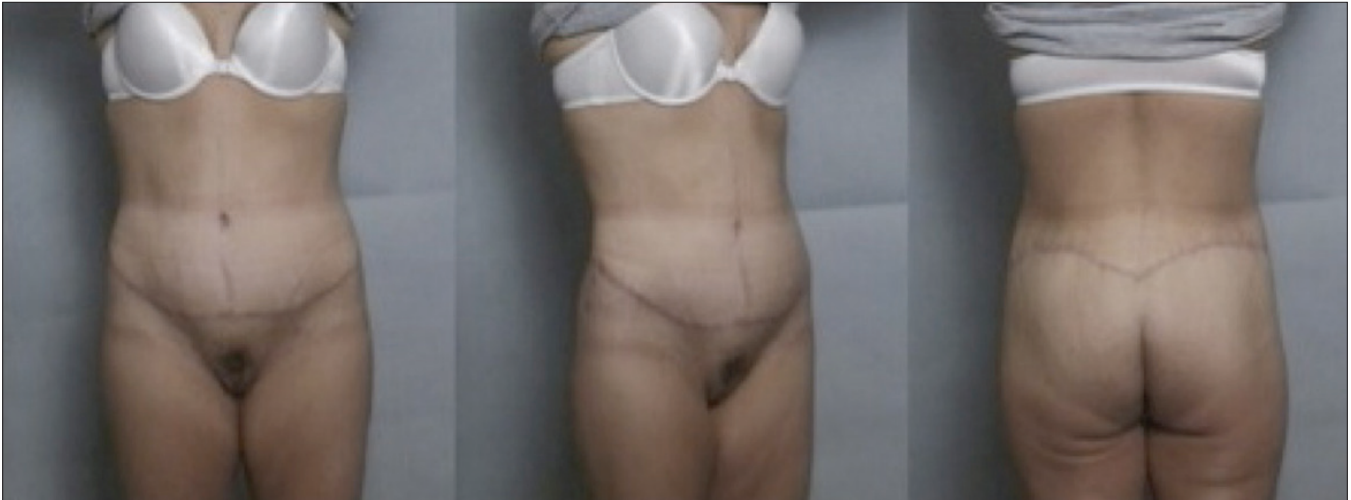A lower body lift treats the lower truncal subunit and the thigh as one unit. The position of the wedge to be excised is

more inferiorly located in a lower body lift when compared to the wedge excised in a belt lipectomy. With the lower body lift, tissues from knee level up must be lifted, thus the soft tissues of the thighs circumferentially must be loosened from the underlying musculoskeletal structure. To accomplish this, the thighs are circumferentially suctioned and the zones of adherence at the junction of the lateral thigh and the hip fat deposits are intentionally destroyed, along with the inguinal fascial attachments lateral to the femoral triangle. Since the zones of adherence act to prevent tissue movement in either a superior or inferior direction, the destruction of the fascia elements allows the thigh tissues to be lifted from the knee level. This allows the final scar to drift lower onto the lateral and posterior trunk, and is located about a third of the way down onto the buttocks proper, which is below the level of the widest aspect of the bony pelvic rim. A lower body lift is an excellent procedure in improving thigh contour but may lead to blunting of the waist rather than accentuation.

## **BELT LIPECTOMY**

The circumferential excisional wedge is located more superiorly, as compared with a lower body lift. The lower truncal subunit is specifically accentuated along with elevation of the lateral thighs and buttocks. However, there is no attempt to lift the tissues all the way from the knee unless the patient presents with an excellent translation of pull. As the zones of adherence are not intentionally and completely destroyed in a belt lipectomy, scar position at a superior level can be maintained. The intended final scar position is at the natural junction between the buttocks and lower back. The scar is located just above the widest aspect of the pelvic rim and this translates into cinching at the waist and improving the ptotic buttock contour [Figures 1 and 2].

Preoperative evaluation includes all aspects included in the section on approach to the MWL patient. In addition, preoperative markings are of utmost importance for maximizing outcome. This is a complex process and has a learning curve to it. Obviously a circumferential excisional procedure is going to require multiple position changes in the operating room. Many position sequences can be utilized. It is important that the individual surgeon is comfortable with their chosen sequence and that it leads to the desired body contour in a safe and efficient manner. One possible sequence preferred by the author is to perform the anterior resection first with the patient supine position, followed by lateral decubitus on one side followed by the other.



**Figure 2:** The same patient as in Figure 1 following belt lipectomy. The marked improvement in the contour of the abdomen, waist, buttocks, and also the thighs is evident

## MEDIAL THIGH LIFT

The trunk is the foundation of the thighs and they are both linked aesthetically. MWL patients who have normal thigh contour and only a minor anterior thigh descent can be treated by belt lipectomy/body lift alone. Liposuction alone usually does not work in these patients. In many patients, anteromedial thigh laxity is caused by a descent of relaxed lower abdominal and inguinal tissues after MWL. Usually, the trunk along with the lateral thigh is addressed initially by the lower body lift/belt lipectomy, which may reduce the amount of subsequent thigh surgery. This is then followed by the excisional thigh lift. Lockwood revolutionized medial thigh lift by anchoring it to the Colles' fascia.<sup>[5]</sup> However, in the MWL patient, the large amount of tissue movement and anchoring that must occur can lead to spreading of the labia, a very difficult complication to treat, despite properly anchored tissues. Thus the authors prefer to limit their excision to a vertical resection, avoiding any potential for labial spreading [Figures 3 and 4]. Should the surgeon choose to combine a vertical and horizontal resection, it is best to create most of the tension on the vertical closure. Despite all preventive measures being taken, the patient should be warned about the possibility of labial spreading. For some patients who, despite MWL, still have inflated thighs, it is preferable to deflate the thighs by circumferential liposuction and then undertake an excisional procedure 6 months later. After the liposuction, the patient must be prepared for worsening of the contour till the excision is undertaken.

## BRACHIOPLASTY

Upper arm excess in an MWL patient is a frequent source

of dissatisfaction and embarrassment. The “bat wings” of hanging tissue, both vertical and horizontal excess, get caught in clothing and may cause rashes. Consequently, these patients avoid short-sleeved clothing. The traditional T-shaped brachioplasty pattern is the most frequently chosen option for brachioplasty. However, most MWL patients present with significant excess of the upper arms that is contiguous with lateral chest wall excess. This type of deformity will not be adequately eliminated with the T-type approach. Examination reveals that the excess tissue is actually in line with the posterior axillary fold and this excess crosses into the axilla.<sup>[6]</sup> It follows, therefore, that the excision of the excess skin-fat envelope should be centered along the posterior axillary fold and it extends into the axilla as well as onto the lateral chest wall, helping in incorporation of the upper body lift incisions if required [Figures 5 and 6]. Like in the medial thigh lift, the excision is marked using a two-ellipse technique with the outer ellipse based on the patient's presenting anatomy and the inner ellipse being an adjustment to allow for safe closure.<sup>[7]</sup>

## UPPER BODY LIFT

The process of MWL often significantly alters the thoracic region, or upper truncal subunit. Excess skin combined with stretched and ptotic tissues may cause drooping breasts, lateral inframammary crease (IMC) descent, lateral breast and back rolls, and both anterior and posterior inverted-V deformities. Frequently, the MWL patient, after satisfactory correction of lower truncal contour deformity, will seek improvement in the upper trunk as well. A variety of surgical options are available, ranging from total upper body lift for more extensive deformities to brachioplasty

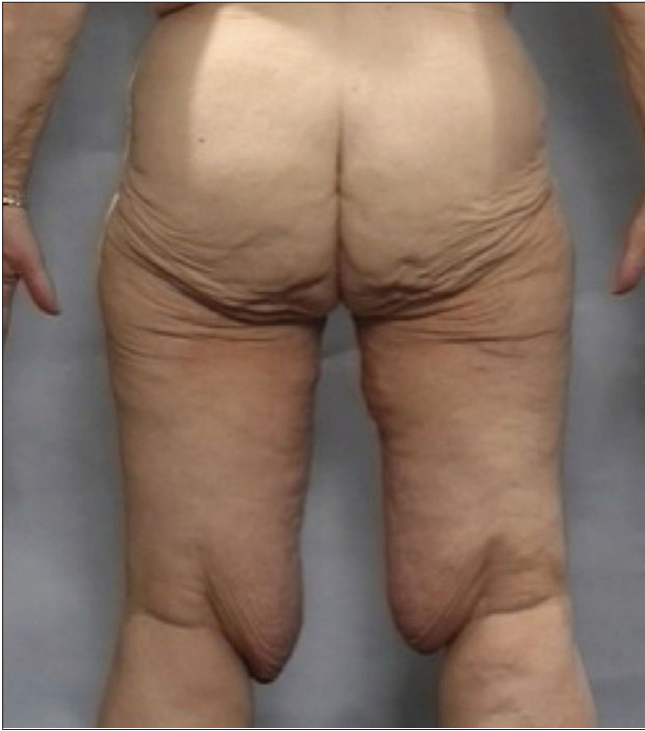

Figure 3: An MWL patient prior to a medial thigh lift

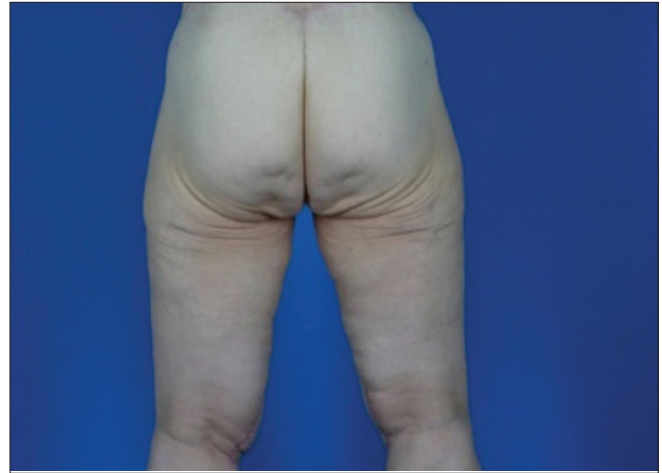

Figure 4: The same patient as in Figure 3 following medial thigh lift. The lower part of the operative scar is seen on the medial aspect of the popliteal crease bilaterally

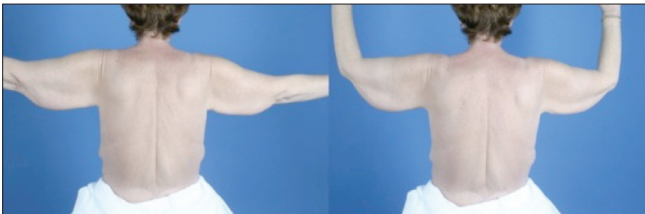

Figure 5: A patient with the typical "bat-wing" deformity bilaterally

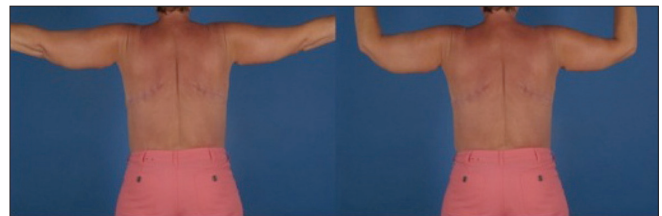

Figure 6: The same patient as in Figure 5 following brachioplasty with improvement in contour. The infrascapular scars bilaterally are those of concomitant back-roll excisions

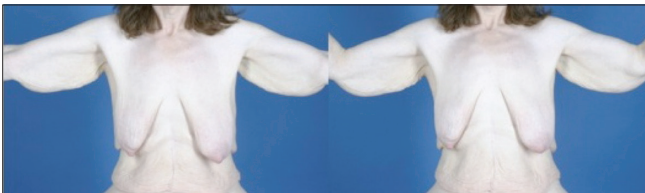

Figure 7: Another patient seen with the typical upper truncal deformities

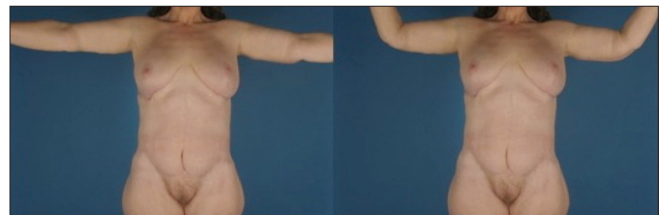


Figure 8: The same patient as in Figure 7 following upper body lift including bilateral mastopexy for breast reshaping. The lower abdominal scar is that of an earlier belt lipectomy

and/or breast surgery as individual procedures for more limited problems. The excess is horizontal as well as vertical. With women, a discussion of the desired breast size and shape after correction is essential to guide the surgeon in selecting the appropriate surgical approach. It is often helpful to show photographs of other patients who have had similar procedures to ensure that the patient has a realistic expectation of what can be accomplished. The key factor in determining whether an upper body lift is to be used in its entirety is the position of the lateral IMC. If it is properly positioned, isolated procedures such as a brachioplasty and

breast reshaping surgeries can be performed. If the lateral crease position is lower than it should be, an upper body lift is appropriate. For the upper body lift, three areas need to be addressed. First, the upper arm excess is eliminated using a brachioplasty technique, which includes a vertical wedge excision of the lateral thoracic wall. Next, the lateral breast-upper back roll excision eliminates vertical excess and upper back redundancy while lifting the lateral IMC. Third, the IMC elevation provides an accurate base for planning breast-contouring procedures that are dependent on the patient's sex and wishes [Figures 7 and 8]. For men, a breast reduction is required, while females may require breast reduction, breast augmentation, mastopexy, or augmentation mastopexy.

## BREAST RESHAPING

An MWL patient is different from the typical breast-reshaping candidate and represents a greater challenge. Severe volume deflation with shape distortion and inelastic skin and parenchyma makes the deformities difficult to correct. Short scar approaches usually do not adequately correct the inherent skin deformities of the MWL patient.<sup>[8]</sup> The technique used must allow for precise and symmetrical NAC positioning, exquisite control of parenchymal breast shape and contour, possible autoaugmentation in volume-deficient patients, and precise control of the remaining skin envelope. Total parenchymal reshaping and dermal suspension technique is one such technique that offers use of a lateral axillary roll deformity to augment breast volume.<sup>[8]</sup> Other techniques of breast reduction, mastopexy and augmentation with implants may be offered to the MWL patient in an individualized manner. If extra volume in the breast is desired, skin and fat from the axillary roll and mid-back region can be transferred to the breast as a flap based on the intercostal artery perforators, namely spiral or intercostal artery perforator (ICAP) flap.<sup>[9,10]</sup> This technique has the added advantage of removal of the undesirable excess tissue under the arm.

## COMPLICATIONS

MWL patients have a significantly higher complication rate than other patients undergoing body-contouring procedures. The frequency of occurrence is far greater for patients with elevated BMI. Obesity is a well-documented risk factor for DVT and pulmonary embolism, necessitating a sound protocol for prophylaxis.

Wound dehiscence after belt lipectomy/body lifts can occur either early (i.e., immediately after surgery) or later in the postoperative period. Early dehiscence is typically seen with patient movement by either the staff or the patient him- or herself. Dehiscence later in the healing process can be secondary to motion but is most often due to an underlying seroma, which will manifest as an open wound with drainage. Wound dehiscence from inappropriate movement can be minimized in MWL patients through sound education of the patient and the nursing care team. It can also be minimized by appropriate marking and not trying to overdo the resection so that the resultant suture line does not come under tension.

The incidence of seroma in the MWL patient undergoing belt lipectomy/body lift is high. Almost all patients with a

BMI above 35 may develop seromas.<sup>[11]</sup> Seromas may result in large cavities that can lead to dehiscence and chronic wounds. There are some interventions that can reduce the incidence of seroma. Three-point sutures secure the SFS to the deep fascia. This helps to obliterate dead space and reduce the incidence of seroma. Progressive tension sutures obliterate the dead space and may minimize seroma formation. Adequate drainage is imperative to minimize the development of seroma. Most body-contouring techniques in the lower body incorporate at least two posterior and two anterior drains. Preservation of a thin layer of fat on the deep fascia may also help diminish the risk of seroma.

Placement of long-lasting absorbable or permanent sutures can result in suture extrusion over time. It is imperative that these types of sutures be placed in the deeper layers, if at all. Most experienced surgeons in this area of surgery utilize long-lasting non-permanent, monofilament sutures.

Excess tension at the thigh/perineal crease can result in vulvar distortion. Excessive tension on the mons can displace it superiorly. In patients with both horizontal and vertical mons excess, a two-stage approach is recommended to help prevent permanent lymphedema.

## SAFETY ISSUES

Preoperatively, smoking and anti-platelet drugs should stop as described earlier in the article. Some authors have carefully included patients only with American Society of Anaesthesiologists (ASA) class I or II<sup>[12]</sup> for improving patient safety. However, it is important to stress the need for extensive monitoring in the early postoperative period regardless of the setting.

To minimize the incidence of DVT and pulmonary thromboembolism, calf or even foot pneumatic compression devices are worn during surgery<sup>[12]</sup> and postoperatively until the patient is fully ambulatory. Some authors advocate the use of low-molecular-weight heparin as prophylaxis. The appropriate dosage for chemoprophylaxis has not been determined. Other investigators have found that the use of postoperative epidural analgesia helps reduce the rate of DVT/PE.

All circumferential procedures are performed under general anesthesia. If patient is to be placed in the lateral decubitus position, an axillary roll should be placed on the ipsilateral side to prevent a brachial plexus injury. Tumescence infiltration is used for liposuction. An indwelling

Foley's catheter monitors urine output. The patient is kept warm with a blanket and the core temperature monitored throughout surgery. A temperature of 35°C is the point that triggers more aggressive warming of the patient.

Epidural analgesia, as mentioned above, is very effective in reducing postoperative pain. Although this is an extremely effective method of controlling pain, it requires the cooperation of the anesthesia team, which may or may not be well equipped for it. Pain is also managed with narcotics, and the duration of their use varies, depending on the procedure and the patient's individual pain tolerance.

As with other surgical procedures, the healthier the patient and the fewer the procedures performed, the lower the complication rate. Three or four procedures performed in one operative stage can be more demanding on the patient and the surgeon, and tend to lengthen the recovery time. As a general recommendation it is critical to gain more experience before attempting multiple procedures in one stage and to never attempt to treat all areas involved in a single procedure.

## CONCLUSION

MWL patients present a tough challenge to the plastic surgeon for body-contouring procedures. These patients harbor numerous problems. They often battle psychological instability, may have intertrigo and other skin conditions, and are prone to significantly higher complication rate than the rest of the population. They invariably need excisional procedures. Body contouring of MWL patients is a process and not just a single procedure. However, with care of a committed and dedicated team that keeps management safe yet aggressive enough to chisel a normal contour, these

patients achieve their goal of getting rid of their "obesity stigmata."

## REFERENCES

1. Marema RT, Buffington CK, Perez MA. Surgical treatment of morbid obesity. In: Aly AS, editor. Body contouring following massive weight loss. 1<sup>st</sup> ed. St Louis (Missouri): Quality Medical Publishing, Inc; 2006. p. 19-47.
2. Shermak MA, Chang D, Magnuson TH, Schweitzer MA. An outcomes analysis of patients undergoing body contouring surgery after massive weight loss. *Plast Reconstr Surg* 2006;118:1026-31.
3. Lockwood T. High lateral tension abdominoplasty with superficial fascial suspension. *Plast Reconstr Surg* 1995;96:603-15.
4. Lockwood T. Superficial fascial system (SFS) of the trunk and extremities: A new concept. *Plast Reconstr Surg* 1991;87:1019-27.
5. Lockwood T. Fascial anchoring in medial thigh lifts. *Plast Reconstr Surg* 1988;82:299-304.
6. Aly AS, Cram AE. Brachioplasty. In: Aly AS, editor. Body Contouring after massive weight loss. 1<sup>st</sup> ed. St Louis (Missouri): Quality Medical Publishing, Inc; 2006. p. 303-33.
7. Aly AS. Brachioplasty in the patient with massive weight loss. *Aesthetic Surg J* 2006;26:76-84.
8. Rubin JP, Agha-Mohammadi S, O'Toole JP. Breast reshaping after massive weight loss. In: Aly AS, editor. Body Contouring after massive weight loss. 1<sup>st</sup> ed. St Louis (Missouri): Quality Medical Publishing, Inc; 2006. p. 361-78.
9. Hurwitz DJ, Agha-Mohammadi S. Postbariatric surgery breast reshaping: The spiral flap. *Ann Plast Surg* 2006;56:481-6.
10. Kwei S, Borud LJ, Lee BT. Mastopexy with autologous augmentation after massive weight loss: The intercostal artery perforator (ICAP) flap. *Ann Plast Surg* 2006;57:361-5.
11. Aly AS. Belt lipectomy. In: Aly AS, editor. Body Contouring after massive weight loss. 1<sup>st</sup> ed. St Louis (Missouri): Quality Medical Publishing, Inc; 2006. p. 71-145.
12. Rohrich RJ, Gosman AA, Conrad MH, Coleman J. Simplifying circumferential body contouring: the central body lift evolution. *Plast Reconstr Surg* 2006;118:525-35.

**Source of Support:** Nil, **Conflict of Interest:** None declared.

## Announcement

David M. Freshwater has prepared a Catalogue raisonné of D. Ralph Millard's publications. It has hypertext links to those items indexed in PubMed, and it can be accessed via this link [http://calder.med.miami.edu/Ralph\\_Millard/bibliography.html](http://calder.med.miami.edu/Ralph_Millard/bibliography.html)

Through the kind offices of the Millard family, access to digital copies of D. Ralph Millard's Cleft Craft volumes 1-3 and A Rhinoplasty Tetralogy can be freely obtained via this link [http://calder.med.miami.edu/Ralph\\_Millard/ebooks.html](http://calder.med.miami.edu/Ralph_Millard/ebooks.html)