

This is an Open Access article licensed under the terms of the Creative Commons Attribution-NonCommercial-NoDerivs 3.0 License (www.karger.com/OA-license), applicable to the online version of the article only. Distribution for non-commercial purposes only.

Solitary Internal Mammary Lymph Node Metastases Detected by ^{18}F -FDG-PET/CT in Ovarian Cancer

Alessandra Bernardi^a Paolo Castellucci^b
Andrea Angelo Martoni^a

Units of ^aMedical Oncology and ^bNuclear Medicine, S. Orsola-Malpighi University Hospital, Bologna, Italy

Key Words

Recurrent ovarian cancer · ^{18}F -FDG-PET · Internal mammary lymph node metastases

Abstract

Internal mammary lymph nodes as solitary site of recurrent ovarian cancer have not been previously described. In this case report, 3 cases of late and very late isolated recurrence in internal mammary lymph nodes are presented. ^{18}F -FDG-PET/CT allowed the diagnosis which was suspected by the increase of the serum CA-125 level in 2 out of 3 cases. Local treatment, consisting of surgery (in 2 patients) and radiation therapy (in 1 patient), permitted an optimal long-term disease control.

Introduction

Recurrent epithelial ovarian carcinoma has a poor prognosis and is almost always fatal [1, 2]. The most frequent relapse site involves the peritoneal cavity and the infradiaphragmatic lymph nodes. Outside the abdomen, the most frequent metastatic sites are the pleura and the mediastinal lymph nodes [3, 4]. Although nodal metastases are well known in the course of epithelial ovarian carcinoma, solitary lymph node relapses are rarely described. The cervical, supraclavicular, groin and axillary areas are unusual sites of isolated lymph node involvement [5]. In a retrospective study evaluating 640 ovarian cancer patients, the incidence of isolated lymph node relapses was 4.2%. Prognosis of isolated lymph node relapse seems better than that of metastatic recurrence at other sites and in the event of an asymptomatic relapse, immediate or delayed therapy should be assessed [6].

Recurrence of ovarian carcinoma is commonly suspected when there is a progressive increase of the serum CA-125 level, but it does not allow differentiation between localized

and diffuse tumor spread. CT scan is the imaging technique of choice, but its capability to detect residual tumor is limited in case of small metastases, such as peritoneal, mesenteric and omental recurrences. CT has also limitations in differentiating residual malignant lesions from benign postoperative changes. ^{18}F -FDG-PET can detect residual tumor with a higher accuracy than CT and even with a higher sensitivity than the tumor markers CA-125 [7, 8]. Recently, we have observed internal mammary lymph node metastases diagnosed by ^{18}F -FDG-PET/CT as a solitary recurrence site in 3 ovarian cancer patients.

Case Reports

Case 1

A 65-year-old woman had been treated by total abdominal hysterectomy, bilateral salpingo-oophorectomy, pelvic lymphadenectomy and omentectomy followed by chemotherapy (carboplatin and cyclophosphamide) for ovarian papillary serous adenocarcinoma stage IC in 1997. At her annual follow-up, 9 years later (May 2006), the serum CA-125 level was increased (83 U/ml, normal value <35 U/ml). A PET/CT scan showed increased ^{18}F -FDG uptakes in the bilateral internal mammary lymph nodes (fig. 1a, b), with suspected infiltration of the right side of the sternum (fig. 1c) as the unique pathological finding. A CT scan confirmed an abnormal left internal mammary lymph node of 1.7 cm in size and a thickening of the right parasternal tissue. She was treated with 7 courses of chemotherapy (carboplatin plus gemcitabine). At the end of the treatment, the serum CA-125 level was stable (75 U/ml) and a CT scan confirmed stable disease. External radiation therapy was administered to the bilateral internal mammary lymph node chains at a total dose of 4,680 cGy. One month later, there was a complete normalization of the CA-125 value. PET/TC was performed 4 months after the end of the radiation therapy and showed a reduction of the ^{18}F -FDG uptake in the right internal mammary lymph node (SUV max. 6 vs. 11) and a complete normalization in the contralateral lymph node.

In November 2007, she was retreated with chemotherapy (6 courses of carboplatin) for disease progression in the internal mammary lymph nodes and the sternum. In July 2008, she developed 2 subcentimetric brain metastases that were treated with stereotaxic radiosurgery, obtaining a complete remission. In September 2008, an increase of the serum CA-125 level occurred (265 U/ml) and the ^{18}F -FDG-PET/CT scan showed multiple pathological uptakes in the supradiaphragmatic lymph nodes (bilateral supraclavicular, internal mammary chains and mediastinal). She was treated with 6 courses of carboplatin + paclitaxel and the serum CA-125 level was normalized. During 2010, disease progression was further documented and monochemotherapy with pegylated doxorubicin was started. On December 31, 2010, she was still on treatment.

Case 2

A 47-year-old woman had been treated by total abdominal hysterectomy, bilateral salpingo-oophorectomy and lombo-aortic lymphadenectomy followed by chemotherapy (cisplatin and cyclophosphamide) for ovarian papillary serous carcinoma stage III in 1991. Subsequently, she first received anterior sigmoid resection for pelvic relapse and adjuvant carboplatin (1996), and secondly, chemotherapy with cisplatin + paclitaxel, followed by liver dissections for liver metastases and carboplatin + topotecan chemotherapy (1998). During these treatments, there was no evidence of disease. In 2001, at a follow-up examination, a right supraclavicular lymph node was palpable. In absence of other signs of localizations, she was treated with gemcitabine + vinorelbine over a 4-month period. The patient experienced partial remission and subsequently, she was submitted for dissection of the right supraclavicular lymph node. The histological examination showed a poorly differentiated adenocarcinoma. Radiation therapy was delivered postoperatively. In December 2002, a PET/CT carried out during a follow-up examination, showed an increased ^{18}F -FDG uptake in a left internal mammary lymph node (fig. 2); the serum CA-125 level had a normal value. She was operated on and a lymph node metastasis was removed and histologically confirmed (poorly differentiated adenocarcinoma). No postoperative treatment was administered. In January 2006, a PET/CT showed an increased ^{18}F -FDG uptake in 3 supradiaphragmatic nodules located in the right anterior costophrenic sinus. She was

treated with supradiaphragmatic lymphadenectomy and partial diaphragm resection; 3 out of 14 lymph nodes were massively infiltrated by a poorly differentiated adenocarcinoma of ovarian origin. At the last follow-up examination (December 2010), almost 5 years later, the patient was well and showed no evidence of disease.

Case 3

A 51-year-old woman had been treated by total abdominal hysterectomy, bilateral salpingo-oophorectomy and omentectomy, followed by chemotherapy (carboplatin and paclitaxel) for ovarian papillary serous carcinoma stage IIIB in 2002. At her annual follow-up, 6 years later, the serum CA-125 level showed an increase above the normal level (>35 U/ml). A PET/CT scan revealed an increased ^{18}F -FDG uptake in the right internal mammary lymph nodes and the cardiophrenic nodule. She was treated with a cardiophrenic nodule excision. The nodule showed infiltration by a papillary adenocarcinoma of ovarian origin. Thus, 1 month later, she was submitted for right internal mammary lymphadenectomy; the histological examination confirmed a papillary adenocarcinoma. From April to July 2009, she was treated with 6 courses of carboplatin and paclitaxel. The serum CA-125 level was within the normal range. At the last follow-up visit, in September 2010, she was well and showed no signs of recurrent disease.

Conclusion

We have been unsuccessful in finding reports on internal mammary lymph nodes metastases from ovarian cancer in the recent literature. In this case report, we have presented 3 cases of recurrent ovarian cancer in which PET/CT detected internal mammary lymph node metastases as unique site of disease, 6, 9 and 11 years after the primary surgical operation, respectively. In the first and third case, PET/CT confirmed the recurrence suspected by the increase of the serum CA-125 level; in the second case, PET/CT was carried out as a follow-up examination in absence of symptoms or increased serum CA-125 levels. In these 3 patients, the PET/CT scan has enabled a local therapeutic approach: a surgical treatment in two patients and radiation therapy in 1 patient, permitting a local control of the disease. At, respectively, 4.5, 8 and 2 years after the diagnosis of internal mammary lymph node metastases our patients are still alive. Two cases have no evidence of disease and 1 case shows persistence of disease.

To our knowledge, this is the first report on internal mammary lymph nodes as a site of late and very late solitary ovarian cancer recurrence and on the determining role of PET/CT scan for the diagnosis of isolated tumor involvement and therapeutic decision-making. Surgical dissection or radical radiotherapy have allowed to obtain optimal disease control in all 3 patients.

Conflicts of Interest

All authors declare no actual or potential conflict of interest.

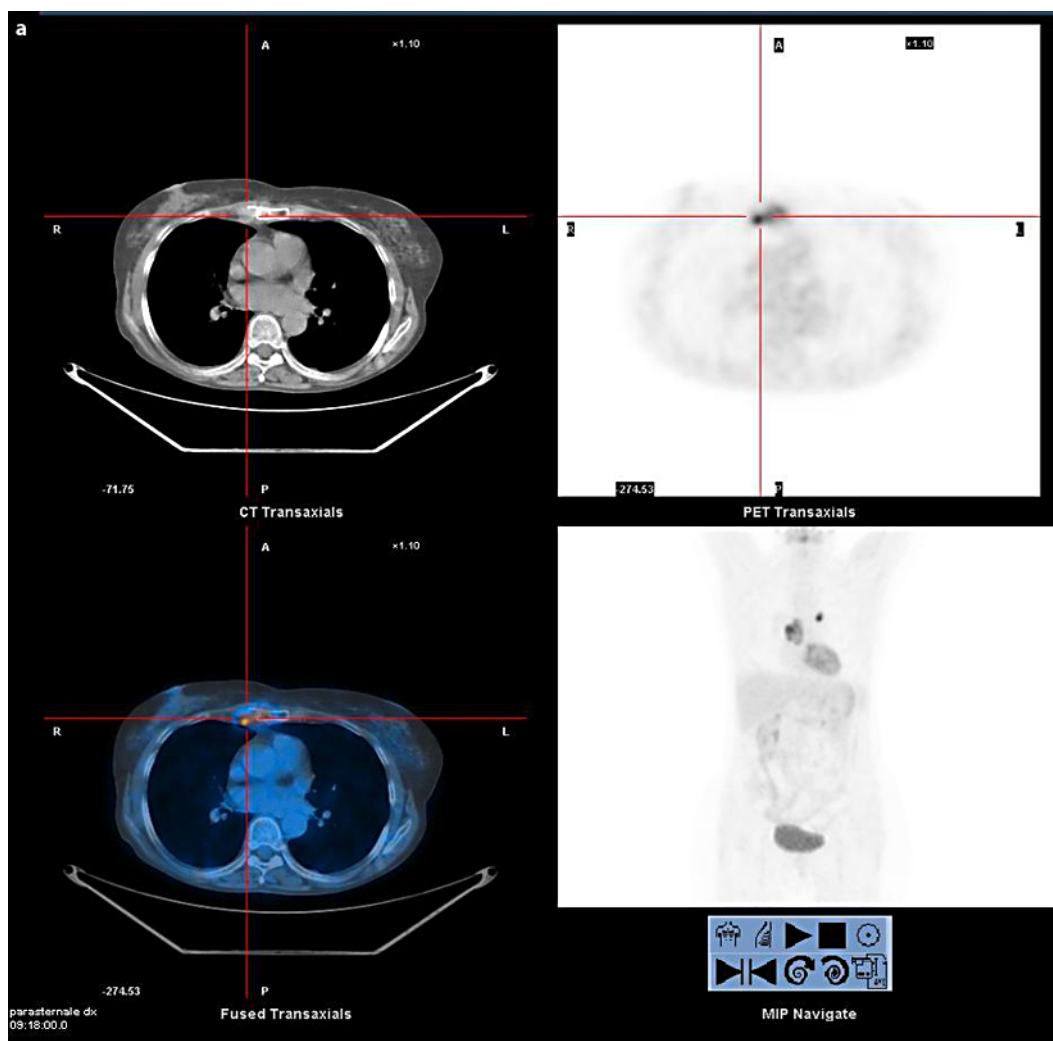
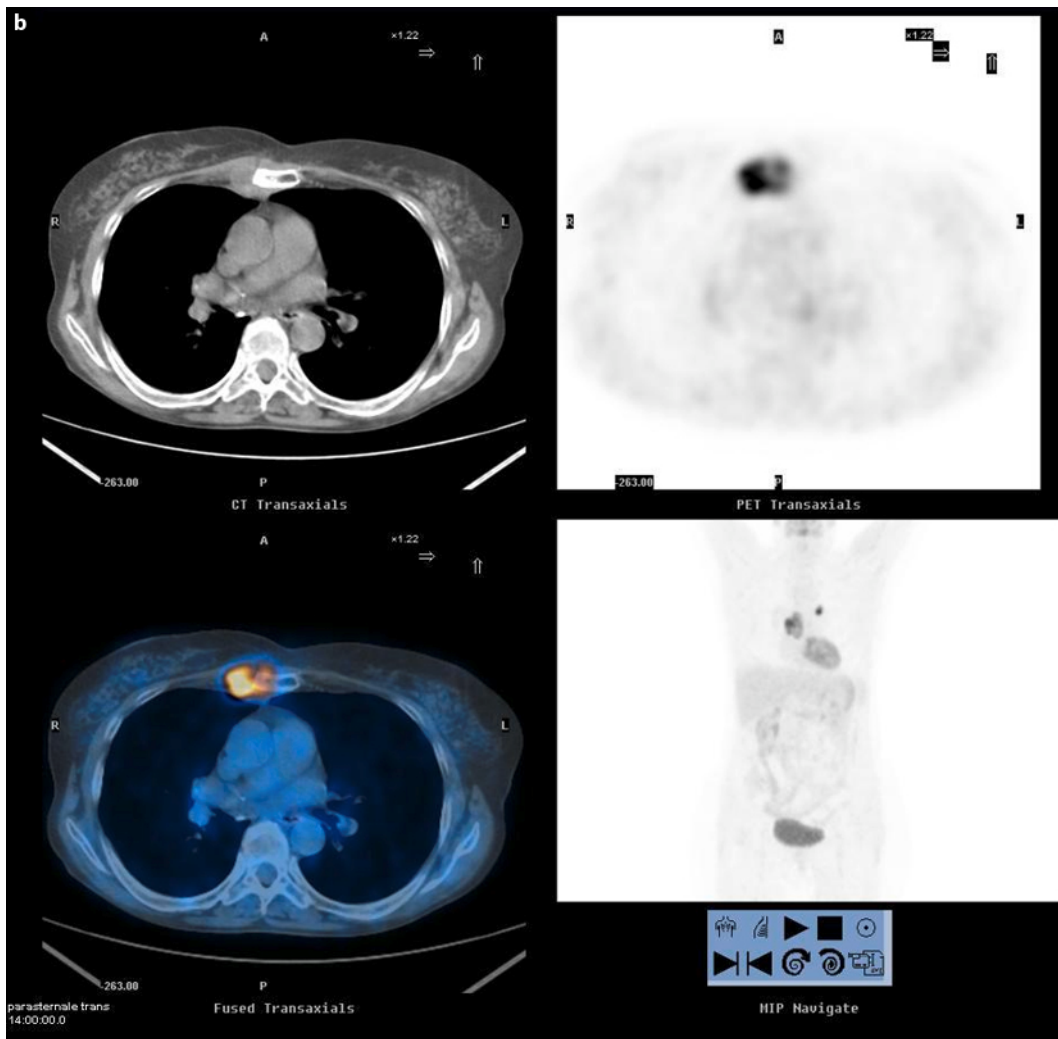
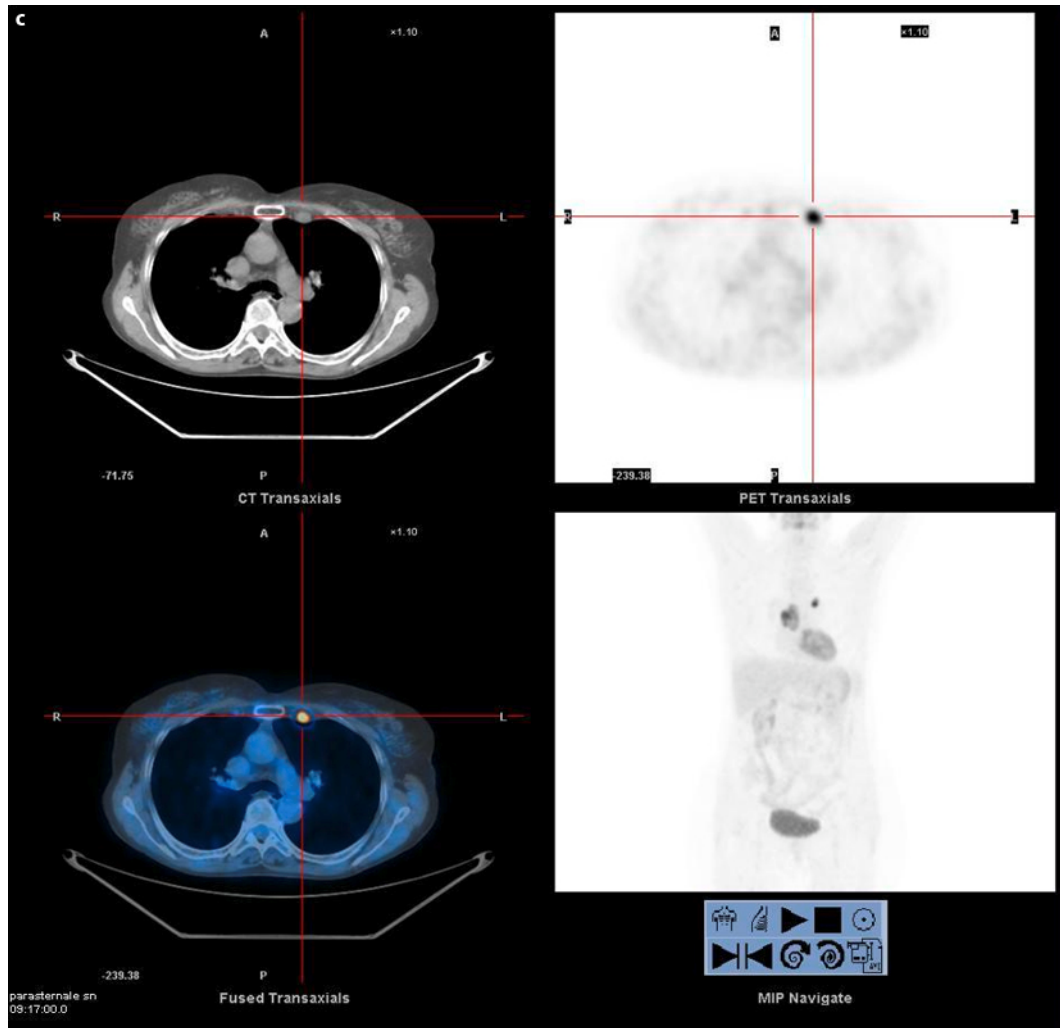


Fig. 1. Case 1. FDG-PET/CT scan shows increased uptakes in bilateral internal mammary lymph nodes (a and b) with involvement of right side of the sternum (c).





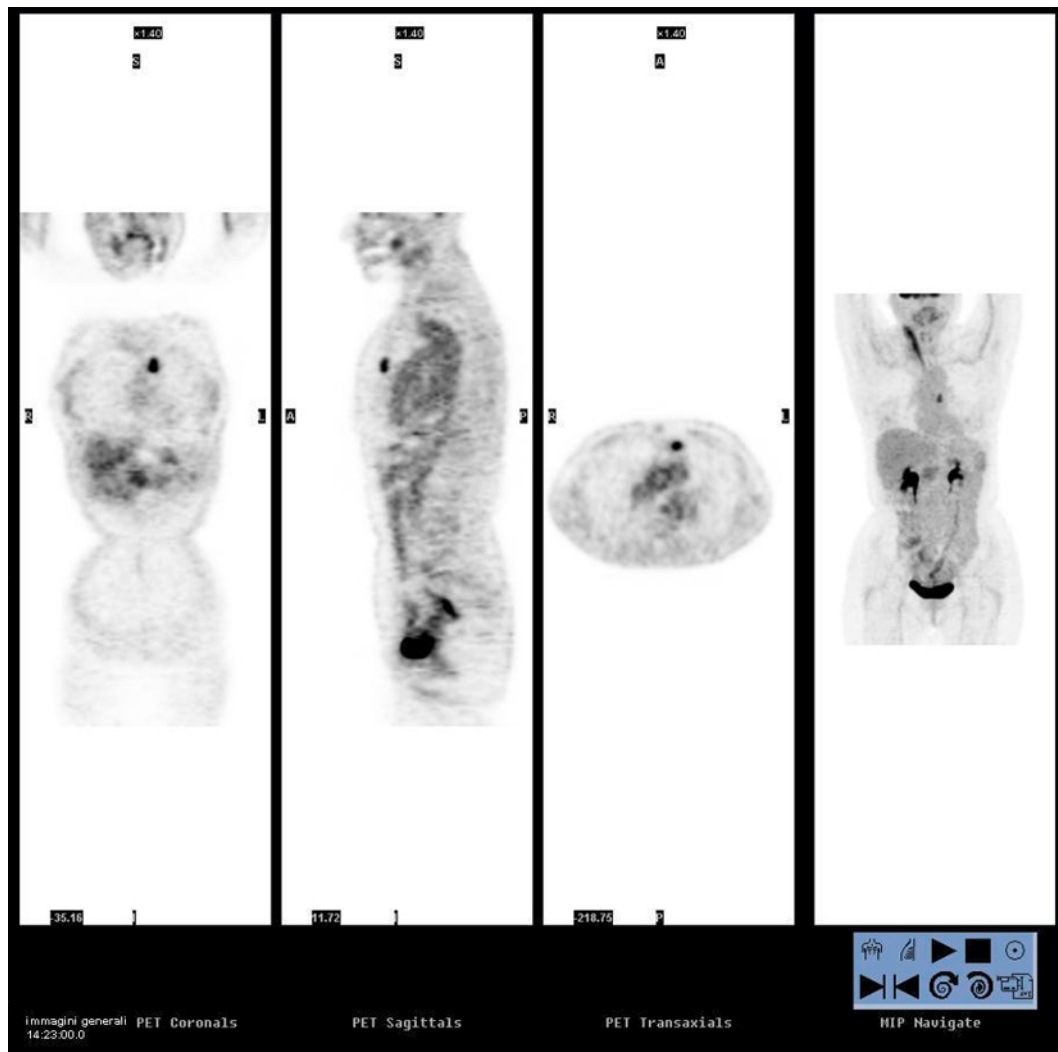


Fig. 2. Case 2. FDG-PET/CT scan shows pathological uptake in left internal mammary lymph nodes.

References

- 1 Cannistra SA: Cancer of the ovary. *N Engl J Med* 2004;351:2519–2529.
- 2 Ozols RF: Recurrent ovarian cancer: evidence-based treatment. *J Clin Oncol* 2002;20:1161–1163.
- 3 Dauplat J, Hacker NF, Nieberg RK, Berek JS, Rose TP, Sagae S: Distant metastases in epithelial ovarian carcinoma. *Cancer* 1987;60:1561–1566.
- 4 Cormio G, Rossi C, Cazzolla A, et al: Distant metastases in ovarian carcinoma. *Int J Gynecol Cancer* 2003;13:125–129.
- 5 Patel SV, Spencer JA, Wilkinson N, Perren TJ: Supradiaphragmatic manifestations of papillary serous adenocarcinoma of the ovary. *Clin Radiol* 1999;54:748–754.
- 6 Blanchard P, Plantade A, Pages C, Afchain P, Louvet C, Tournigand C, De Gramont A: Isolated lymph node relapse of epithelial ovarian carcinoma: outcomes and prognostic factors. *Gynecol Oncol* 2007;104:41–45.
- 7 Zimny M, Siggelkow W, Schroder W, et al: 2-Fluorine-18-fluoro-2-deoxy-D-glucose positron emission tomography in the diagnosis of recurrent ovarian cancer. *Gynecol Oncol* 2001;83:310–315.
- 8 Torizuka T, Nobezawa S, Kanno T, et al: Ovarian cancer recurrence: role of whole-body positron emission tomography using 2-[fluorine-18]-fluoro-2-deoxy-D-glucose. *Eur J Nucl Med* 2002;29:797–803.