

CASE REPORT

Warty Dyskeratoma Involving Two Adjoining Follicles

Eun Joo Jang, M.D., Ji Yeoun Lee, M.D., Mi Kyeong Kim, M.D.¹, Tae Young Yoon, M.D.

Departments of Dermatology and ¹Internal Medicine, School of Medicine and Medical Research Institute, Chungbuk National University, Cheongju, Korea

Warty dyskeratoma (WD) is a rare epidermal tumor that frequently arises as a papule or nodule on the head or neck of middle-aged or older persons. Histologically, it shows a cup-shaped keratin-filled invagination of an acanthotic epidermis, suprabasilar clefting with villi projecting into the clefts and acantholytic dyskeratotic cells are also present. The changes almost always involve a single hair follicle. We describe a distinctive case of WD that showed involvement of two adjoining follicles within a solitary lesion. (**Ann Dermatol 23(1) 98~100, 2011**)

-Keywords-

Multiple follicles, Warty dyskeratoma

INTRODUCTION

Graham and Helwig¹ first described warty dyskeratoma (WD) as isolated Darier's disease in 1954 and this malady was more properly called warty dyskeratoma by Szymanski² in 1957. WD is a rare tumor that is characterized by a solitary papule or nodule that is most commonly found on the scalp, face or neck. A cup-shaped invagination filled with a keratotic plug is the most histological common pattern. The invagination contains acantholytic dyskeratotic cells in the upper portion. In the lower portion of the invagination, there are numerous villi covered by a single layer of cells. The invagination has been interpreted as being a greatly dilated hair follicle. The changes almost always involve a single hair follicle.

Received April 14, 2010, Revised April 28, 2010, Accepted for publication May 4, 2010

Corresponding author: Tae Young Yoon, M.D., Department of Dermatology, School of Medicine and Medical Research Institute, Chungbuk National University, 410 Sungbong-ro, Heungdeok-gu, Cheongju 361-763, Korea. Tel: 82-43-269-6369, Fax: 82-43-266-1698, E-mail: tyoon@chungbuk.ac.kr

Tanay and Mehregan³ described that solitary lesion could exceptionally involve two to four close follicles. In Korea, only one case that revealed involvement of two adjoining follicles was reported by Chon et al.⁴.

We report here on an additional peculiar case of WD that involved two adjoining follicles.

CASE REPORT

A 47-year-old man visited our clinic with a 4 to 5-year history of a nodule on the scalp. The lesion was small and asymptomatic at first, but it had begun to increase in size and this was recently accompanied by tenderness. The patient pinched the lesion several times and he found that some whitish material was expressed through the pore. The patient was otherwise in good health.

The dermatologic examination revealed a 1.2×1.0 cm sized, erythematous, hairless nodule with a yellowish hyperkeratotic plug on the left parietal scalp (Fig. 1). On histologic examination, there were two large cup-shaped

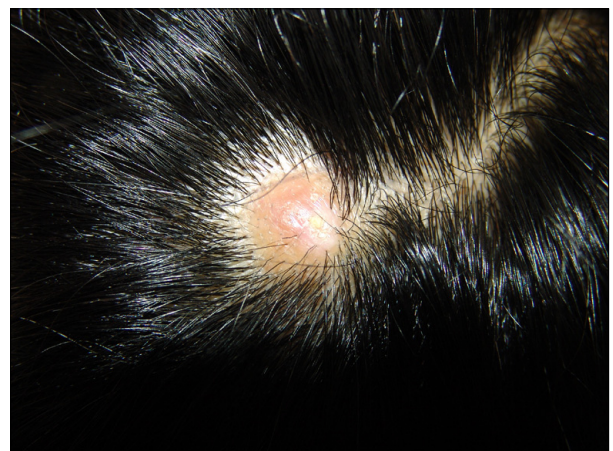

Fig. 1. A solitary, well-defined, erythematous, hairless nodule with a hyperkeratotic plug on the left parietal scalp.

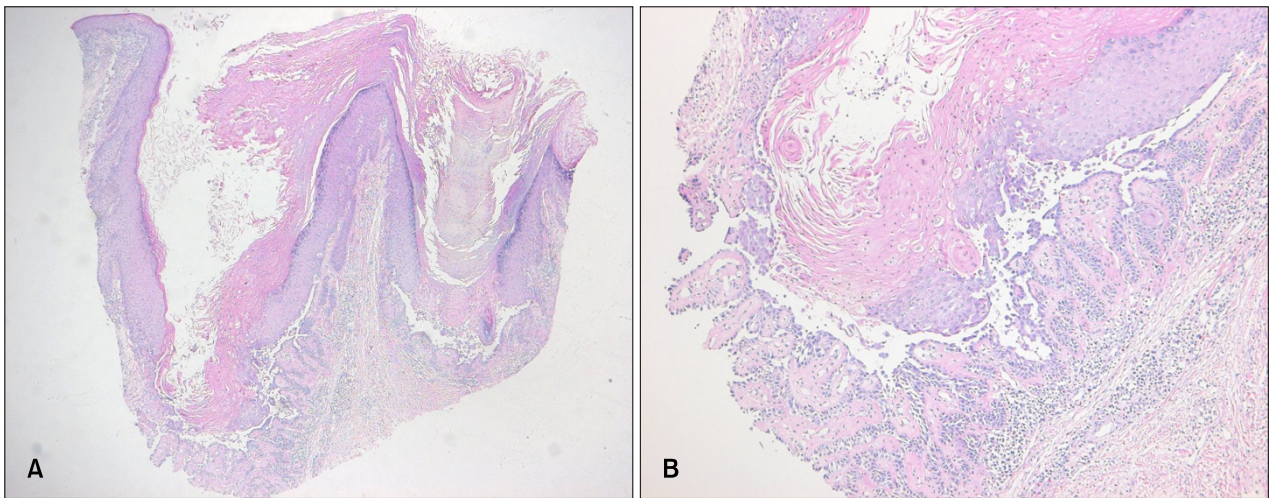


Fig. 2. (A) Two large cup-shaped invaginations containing keratinous material (H&E, $\times 40$). (B) The lower portion of each invagination shows suprabasal clefts and villi with acantholytic dyskeratotic cells. Typical corps ronds in the granular layer and a moderate inflammatory infiltrate consisting of lymphocytes and histiocytes in the dermis are observed (H&E, $\times 100$).

epidermal invaginations filled with keratinous material (Fig. 2A). The lower portion of each invagination showed suprabasal clefts and villi lined by a single layer of basaloid cells. There were typical corps ronds in the thickened granular layer and many acantholytic dyskeratotic cells above the villi. A moderate inflammatory infiltrate consisting of lymphocytes and histiocytes was observed in the dermis (Fig. 2B). On the basis of these clinical and histological findings, a diagnosis of WD was made. The lesion was completely removed by excisional biopsy. There were no signs of recurrence during the 7 month follow-up period.

DISCUSSION

Isolated lesions with the histologic features of focal acantholytic dyskeratosis were first given special standing by Graham and Helwig¹ as isolated dyskeratosis follicularis. Szymanski² first introduced the name warty dyskeratoma in his review of seven new cases.

WD frequently arises as a single lesion with a central keratotic plug on the skin of the head or neck of middle-aged or older persons. Yet multiple lesions^{5,6} and involvement of the oral⁷ and genital⁸ mucosa have occasionally been reported. The patient frequently states symptoms of pruritus and they may complain of recurrent foul-smelling cheesy drainage from the lesions. There may be central bleeding associated with trauma to the lesion.

Histologically, a cup-shaped invagination filled with a keratotic plug is observed. The lesion almost always involves a single hair follicle. Although it is very rare, adjoining follicles within a solitary lesion can be involv-

ed^{3,4,9}. The invagination contains numerous acantholytic dyskeratotic cells and typical corps ronds can be seen at the entrance to the invagination.

In the lower portion of the invagination, there are many villi that are often covered by a single layer of basaloid cells and these villi protrude upward. In our case, two adjoining follicles were involved and each showed the typical histologic features of WD. Besides the most common cup-shaped type, Kaddu et al.¹⁰ reported two additional patterns of WD, that is, the cystic and nodular patterns. The cystic lesions have shown large, well-defined, cystic structures in the dermis, which were lined by epithelial cells and filled with masses of keratin material. The nodular lesions showed small, well circumscribed, solid aggregations of epithelial cells in the dermis. They were connected to the epidermis and the epidermis showed hyperplasia.

Focal acantholytic dyskeratosis is not a histologic hallmark of WD. It is also observed in Darier's disease or transient acantholytic dermatosis; some neoplasms such as acantholytic squamous cell carcinoma, actinic keratosis and basal cell carcinoma may present with similar histologic feature. In our case, the clinical appearance of WD was so distinctive that Darier's disease and transient acantholytic dermatosis could be easily excluded. The lack of cellular atypia and specific morphological features did not support the diagnosis of squamous cell carcinoma, actinic keratosis or basal cell carcinoma.

The etiology of WD is unclear, but a viral infection, smoking, autoimmunity, and ultraviolet light have been postulated to play a role. Szymanski² showed the presence of viral DNA and RNA in the epithelial cells lining the villi

and he proposed that viral infection was the cause of WD. But there has been no further evidence to support this hypothesis. The idea that chronic actinic damage was responsible for the development of WD was contradicted by its occurrence in areas unexposed to sunlight. Many authors^{3,10,11} have suggested a follicular origin for WD, but mucosal lesions that lack follicle could not be explained by their proposal. For this reason, some authors have insisted that oral WD may represent another entity rather than true WDs.

The treatment of choice of WD is surgical excision. Curettement with electro-desiccation and irradiation with X-ray had been tried, but these were followed by recurrence³. A case of successful treatment with tazarotenic acid gel¹² has been reported. In our patient, there was no evidence of recurrence after excisional biopsy.

In conclusion, we describe here a peculiar case of WD that involved two adjoining hair follicles within a solitary lesion.

REFERENCES

1. Graham JH, Helwig EB. Isolated dyskeratosis follicularis. *AMA Arch Derm* 1958;77:377-389.
2. Szymanski FJ. Warty dyskeratoma; a benign cutaneous tumor resembling Darier's disease microscopically. *AMA Arch Derm* 1957;75:567-572.
3. Tanay A, Mehregan AH. Warty dyskeratoma. *Dermatologica* 1969;138:155-164.
4. Chon HJ, Hong SJ, Kang H, Son SJ. A case of warty dyskeratoma. *Korean J Dermatol* 1999;37:694-696.
5. Griffiths TW, Hashimoto K, Sharata HH, Ellis CN. Multiple warty dyskeratomas of the scalp. *Clin Exp Dermatol* 1997; 22:189-191.
6. Koç M, Kavala M, Kocatürk E, Mete O, Can B, Zindancı I, et al. Multiple warty dyskeratomas on the scalp. *Dermatol Online J* 2009;15:8.
7. Gorlin RJ, Peterson WC Jr. Warty dyskeratoma. A note concerning its occurrence on the oral mucosa. *Arch Dermatol* 1967;95:292-293.
8. Duray PH, Merino MJ, Axiotis C. Warty dyskeratoma of the vulva. *Int J Gynecol Pathol* 1983;2:286-293.
9. Lee IJ, Hur W, Ahn SK, Lee WS, Kim SC, Lee SH. Three cases of warty dyskeratoma. *Korean J Dermatol* 1992;30: 564-568.
10. Kaddu S, Dong H, Mayer G, Kerl H, Cerroni L. Warty dyskeratoma—"follicular dyskeratoma": analysis of clinicopathologic features of a distinctive follicular adnexal neoplasm. *J Am Acad Dermatol* 2002;47:423-428.
11. Azuma Y, Matsukawa A. Warty dyskeratoma with multiple lesions. *J Dermatol* 1993;20:374-377.
12. Abramovits W, Abdelmalek N. Treatment of warty dyskeratoma with tazarotenic acid. *J Am Acad Dermatol* 2002; 46:S4.