

Mucormycosis Caused by Unusual Mucormycetes, Non-*Rhizopus*, -*Mucor*, and -*Lichtheimia* Species

Marisa Z. R. Gomes,^{1,2} Russell E. Lewis,^{1,3} and Dimitrios P. Kontoyiannis^{1*}

Department of Infectious Diseases, Infection Control and Employee Health, The University of Texas M. D. Anderson Cancer Center, Houston, Texas 77030¹; Nosocomial Infection Research Laboratory, Instituto Oswaldo Cruz, Fundação Oswaldo Cruz, Rio de Janeiro, Brazil²; and University of Houston College of Pharmacy, Houston, Texas³

INTRODUCTION	412
TAXONOMIC ORGANIZATION OF UNUSUAL MUCORALES ORGANISMS	412
LITERATURE SEARCH AND CRITERIA	413
<i>Cunninghamella bertholletiae</i>	414
Taxonomy	414
Reported cases	414
Epidemiology and risk factors	415
Pathogenesis	416
Clinical presentation	417
(i) Disseminated infection	417
(ii) Pulmonary infection	418
(iii) Cardiovascular involvement	418
(iv) Rhino-orbito-cerebral infection	418
(v) Soft tissue infection	419
(vi) Peritonitis	419
(vii) Breakthrough <i>C. bertholletiae</i> infection	419
(viii) <i>C. bertholletiae</i> infection in pediatric patients	419
(ix) Chronic infection	419
Diagnosis	419
Management	420
<i>Rhizomucor pusillus</i>	421
Taxonomy	421
Reported cases	422
Epidemiology	422
Pathogenesis	423
Clinical presentation	423
(i) Pulmonary infection	423
(ii) Disseminated infection	423
(iii) Soft tissue infections and osteomyelitis	423
(iv) Rhino-orbito-cerebral infection	424
(v) Cerebral infection	424
(vi) Intra-abdominal infection	424
(vii) Chronic and recurrent infections	424
(viii) Breakthrough infections	424
Diagnosis	424
Management and prognosis	424
<i>Apophysomyces elegans</i> Complex	425
Taxonomy	425
Reported cases and epidemiology	425
Pathogenesis	425
Clinical presentation	426
(i) Soft tissue infection and osteomyelitis	426
(ii) Rhino-orbito-cerebral infection	426
(iii) Disseminated infection	426
(iv) Renal infection	427
(v) Intra-abdominal infection	427
(vi) Subacute or chronic infection	427

* Corresponding author. Mailing address: Department of Infectious Diseases, Infection Control and Employee Health, Unit 1460, The University of Texas M. D. Anderson Cancer Center, 1515 Holcombe Boulevard, Houston, TX 77030. Phone: (713) 792-6237. Fax: (713) 745-6839. E-mail: dkontoyi@mdanderson.org.

Diagnosis.....	427
Management.....	427
Prognosis.....	428
<i>Saksenaea vasiformis</i> complex.....	428
Taxonomy and reported cases.....	428
Epidemiology.....	428
Pathogenesis.....	428
Clinical presentation.....	428
(i) Soft tissue infection.....	428
(ii) Chronic soft tissue infection and osteomyelitis.....	429
(iii) Rhino-orbito-cerebral infection.....	429
(iv) Disseminated infection.....	429
(v) Renal infection.....	429
Diagnosis.....	429
Management.....	430
Prognosis.....	430
<i>Syncephalastrum racemosum</i>	430
Taxonomy and reported cases.....	430
Epidemiology.....	430
Pathogenesis and clinical presentation.....	430
Diagnosis.....	431
Management.....	431
<i>Cokeromyces recurvatus</i>	432
Taxonomy and reported cases.....	432
Epidemiology.....	432
Pathogenesis.....	432
Diagnosis.....	432
<i>Actinomucor elegans</i>	433
Taxonomy.....	433
Reported cases, epidemiology, and clinical presentation.....	433
Diagnosis and outcome.....	433
DISCUSSION.....	433
Epidemiology.....	433
Pathogenesis.....	434
Clinical Presentation.....	435
Diagnosis.....	435
Management and Prognosis.....	436
Prevention.....	437
CONCLUSIONS.....	438
ACKNOWLEDGMENTS.....	438
REFERENCES.....	438

INTRODUCTION

The prevalence and incidence of opportunistic mycoses have increased owing to several factors, including longer survival of immunosuppressed individuals and advances in laboratory-based diagnosis of these diseases. Mucormycosis is the second most frequent mold infection in immunocompromised patients and can progress rapidly in both immunocompromised and immunocompetent individuals (167). Unfortunately, diagnosis of mucormycosis in both the clinic and the laboratory remains difficult, leading to unsatisfactory treatment and high mortality rates. Early diagnosis, surgical debridement, systemic antifungal therapy, and control of underlying conditions are the key elements in the successful management of this infection.

Rhizopus is the most common genus causing human Mucormycetes (formerly Zygomycetes) infections in most case series, followed by genera such as *Mucor* and *Lichtheimia*, accounting for 70 to 80% of all mucormycosis cases (13, 287, 292). Reviews describing the less common Mucormycetes (Fig. 1) causing the remaining 20 to 30% of mucormycosis cases are lacking. Table 1 shows the compiled distribution of unusual Mucormycetes in

global and regional studies (13, 53, 54, 59, 287, 292; B. J. Park et al., submitted for publication). Increased knowledge of the epidemiology, clinical presentation, diagnosis, treatment of, and prognosis for these unusual infections could improve their early recognition and treatment.

TAXONOMIC ORGANIZATION OF UNUSUAL MUCORALES ORGANISMS

Recent advances in molecular techniques have contributed to the accuracy of identifying and classifying organisms (220) and to opportunities for genomic analysis of fungi (13, 133, 325, 351, 350, 361). Such techniques ushered in a revolution in Mucorales phylogeny, taxonomy, and nomenclature. Evolutionary distances and new species of Mucormycetes have been defined over the past decade (7, 13, 325, 349, 361). The results of distance and parsimony analyses strongly support the existence of several monophyletic clades that deviate from the morphological classification of mucoralean fungi (325, 352, 361). Thus, studies of the molecular phylogeny of Mucorales placed *Apophysomyces elegans* near *Saksenaea vasiformis* but

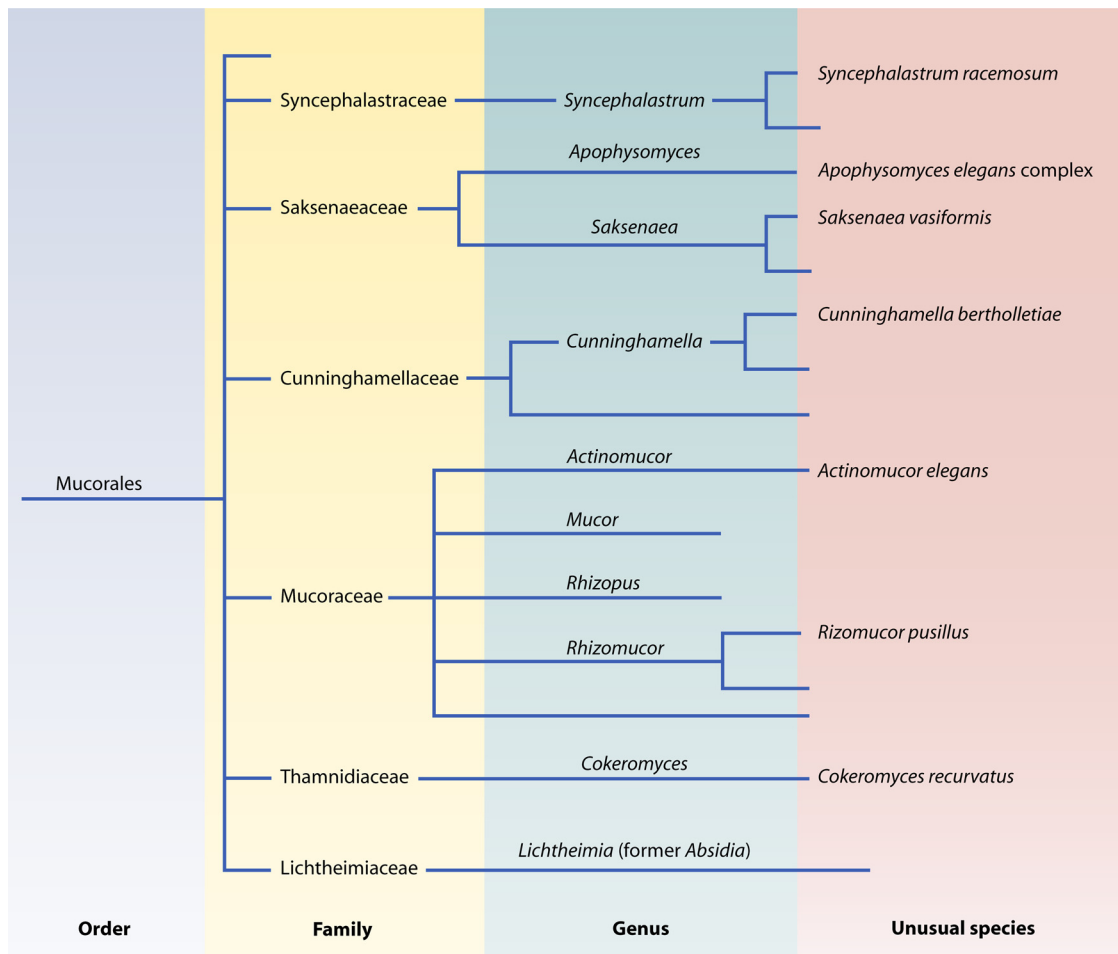


FIG. 1. Taxonomic scheme of human-pathogenic Mucormycetes of the order Mucorales.

far from *Mucor* and *Rhizopus* species, in a separate clade (351, 352; <http://Zygomycetes.org/index.php?id=49>). *Rhizomucor variabilis* var. *regularior* was considered a synonym of *Mucor circinelloides*, and together with *R. variabilis* var. *variabilis* in the phylogenetic tree, these species have been placed far from *Rhizomucor pusillus* and in the *Mucor* clade (13, 351). Figure 1 shows the current taxonomic organization of the human-pathogenic Mucormycetes of the order Mucorales and highlights the unusual species described herein.

LITERATURE SEARCH AND CRITERIA

We performed a Medline search of specific genera and species, as well as the terms “zygomycosis,” “phycomycosis,” “mucormycosis,” “Mucorales,” and “Zygomycetes.” We included all English and Spanish articles in our search. We considered only reported cases with sufficient clinical, epidemiological, and laboratory information to identify an organism as the cause of the mucormycosis. We further investigated the search results for single case reports or case series as well as articles with compiled data for ascertainment of additional cases.

Cases were included in this review if they were proven cases of mucormycosis with histopathological evidence of tissue invasion by hyphae and detection of the agent by culture isola-

tion and/or PCR analysis of samples from the infection site and/or sterile sites. Infections with *Cokeromyces recurvatus* were included if cultures from the site of infection were positive and histological examination exhibited yeast-like cells in tissue. Probable cases of mucormycosis with only cultures positive for the organism (without histopathological evidence of infection) were included if the organism was isolated from the infection site and/or sterile sites or repeatedly isolated from nonsterile sites (e.g., sputum) and there was clinical-laboratory evidence of response to antifungal treatment. Only cases with identification of Mucormycetes at the species level were considered for tabulation or comparative observations in the text.

Immunocompromised patients were defined as those with underlying conditions (e.g., hematological malignancies, solid tumors, transplantation, diabetes mellitus, AIDS, chronic alcoholism, cirrhosis, renal failure, burns, pregnancy, intravenous [i.v.] drug abuse, or being a premature neonate) or who received treatment (e.g., radiation, cytotoxic chemotherapy, antirejection medications, or corticosteroids) that causes immune depression. All patients described as previously healthy were considered to be nonimmunocompromised.

Predisposing factors classified as being health care associated were factors related to medical procedures, regardless of

TABLE 1. Frequencies (%) of unusual Mucormycetes species in global and regional publications^a

Region or country of study, study period (no. of cases/specimens)	Frequency (%) of species							% of cases with no data on species
	<i>Cunninghamella bertholletiae</i>	<i>Apophysomyces elegans</i> complex	<i>Saksenaia vasiformis</i>	<i>Rhizomucor pusillus</i>	<i>Syncephalastrum racemosum</i>	<i>Cokeromyces recurvatus</i>	<i>Actinomyces elegans</i>	
Global, ^b 1885–2005 (929 cases)	4	3	2	2	0.1	0.3	0	50
Italy, ^{c,d} 1987–2001 (59 cases)	3	0	0	0	0	0	0	48
India, ^d 1990–2007 (382 cases)	0	8	0.5	1	0.3	0	0	63
United States, ^{e,i} 2001–2006 (104 cases)	9	1	0	7	0	0	0	10
United States, ^f 2001–2007 (189 specimens)	3	0	0	4	0	0	0	7 ⁱ
Europe, ^g 2005–2007 (230 cases)	2	1	0.4	2	0	0	0	26
Central Europe and Asia, ^h 2006–2009 (41 cases)	2	2	0	5	0	0	0	29

^a Percentages are underestimations of the true frequencies, as not all cases were microbiologically documented or specific information about the Mucormycetes genus was provided for culture (or PCR)-positive cases.

^b From reference 287.

^c From reference 243.

^d From references 53, 54, and 59.

^e From Park et al., submitted.

^f From reference 13.

^g From reference 314.

^h From reference 292.

ⁱ Only the genus was identified.

whether they were performed during hospitalization (137). Cases of mucormycosis detected during nosocomial outbreaks were also classified as health care associated. A predisposing factor was classified as occupational exposure if it was the only risk condition described (e.g., if the patient experienced trauma during an occupational activity, it was classified as trauma rather than occupational exposure).

Clinical presentation of mucormycosis was classified as follows. (i) Rhino-orbito-cerebral infections were those where one or more of the following sites were affected: sinus, orbit, mastoid, cranium, and face. Isolated infection of the brain without evidence of infection in adjacent areas or other organs was described separately, as cerebral infection. (ii) Soft tissue infection was classified as an infection confined to cutaneous and/or subcutaneous tissues, muscles, or tendons. Osteomyelitis, arthritis, and onychomycosis were described separately. (iii) Pulmonary infection included disease affecting the lungs, pleura, or both. (iv) Sinopulmonary infection was defined as disease affecting the lungs and rhino-orbito-cerebral sites. (v) Cardiopulmonary infection was defined as disease affecting the lungs and heart. (vi) Disseminated infection was classified as involvement of two or more noncontiguous organs or tissues. (vii) Intra-abdominal infection included infection in an intraperitoneal or retroperitoneal space. (viii) Gastrointestinal and gynecological infections were infections restricted to these sites. (ix) Other single-organ infections were described separately when, for example, only the kidneys or heart was affected.

Collected patient data included age, sex, immune status, underlying condition(s), predisposing factors, clinical and radiological presentation, and presence of tissue necrosis. Surgical procedures were subcategorized into debridement, resection, amputation, and drainage. Hyperbaric oxygen therapy was included if it was described in the report as part of infection management. Outcomes included recovery and death

caused by Mucormycetes infection or other causes. Information on clinical sequelae following recovery from infection were also collected from published cases when available. Data concerning antifungal therapy, including prior antifungal therapy, were included in case summaries when available.

Cunninghamella bertholletiae

Taxonomy. Although *C. bertholletiae* is known to be the only clinically relevant species in the Cunninghamellaceae family (164, 186, 279), other species were recently reported to be human pathogens (13, 186). *Cunninghamella echinulata* was linked to human infections in studies using molecular sequencing of isolates (13, 186); however, clinical details of the cases were not provided. Similarly, *Cunninghamella elegans* is generally considered to be nonpathogenic in humans (279), yet a case of probable infection with this species was reported for a 52-year-old Japanese man with acute lymphocytic leukemia (ALL) having repeated *C. elegans*-positive sputum cultures (216). Several cases of misidentification of Cunninghamellaceae have been reported (13, 167, 279). For example, two *C. elegans* infections (140, 176) were later reclassified as *C. bertholletiae* infections (207). Also, a 20% rate of discordance in Mucorales identification was reported by Kontoyiannis et al. for a comparison of identification of clinical isolates to the species level by use of ribosomal internal transcribed spacer (ITS) sequencing with classical morphological identification techniques (168).

Reported cases. Although it was first isolated from Brazilian soil samples by Stadel in 1911 (299), *C. bertholletiae* was recently recognized as a cosmopolitan soil organism (279, 299). The first case of *C. bertholletiae* infection was described in 1958 for a patient with lymphosarcoma and profound immunosuppressive therapy (140). Forty-two subsequent cases reported in the literature met the criteria of this review for proven or

TABLE 2. Epidemiological data on reported cases of unusual Mucormycetes infection

Patient parameter	Value						
	<i>Apophysomyces elegans</i>	<i>Cunninghamella bertholletiae</i>	<i>Saksenaeva vasiformis</i>	<i>Rhizomucor pusillus</i>	<i>Syncephalastrum racemosum</i>	<i>Cokeromyces recurvatus</i>	<i>Actinomucor elegans</i>
No. of cases	74	43	42	22	4	3	1
Mean (median) age (or age of each patient) (yr)	40 (43)	45 (51)	42 (47)	41 (41)	4, 8, 23, 45	9, 66, 72	30
Age range (yr)	6–70	3–70	3 mo–84	21 mo–77	4–45	9–72	30
No. (%) of male patients	55 (74)	34 (79)	26 (62)	14 (64)	4 (100)	3 (100)	1 (100)
No. (%) of immunocompromised patients	20 (27)	42 (98)	8 (19)	20 (91)	0	1 (100)	0
No. (%) of patients with underlying condition							
No underlying conditions	49 (66)	1 (2)	30 (71)	0	4 (100)	0	1 (100)
Hematological malignancy and/or transplantation	3 (4)	31 (72)	1 (2)	16 (73)	0	1 (33)	0
Other hematological disease	1 (1)	5 (12)	1 (2)	1 (5)	0	0	0
Diabetes mellitus ^a	12 (16)	1 (2)	4 (10)	1 (5)	0	0	0
Other conditions	6 (8)	5 (12)	5 (12)	3 (14)	0	2 (67)	0
No. (%) of patients with other predisposing factor							
Unknown or undescribed factor	12 (16)	33 (77)	15 (36)	13 (59)	0	2 (67)	0
Trauma	30 (41)	3 (7)	12 (29)	0	4 (100)	0	1 (100)
Health care-associated infection	12 (16)	5 (12)	5 (12)	9 (41)	0	1 (33)	0
Other types of trauma ^b	6 (8)	0	9 (21)	0	0	0	0
Occupational exposure	2 (3)	1 (2)	1 (2)	0	0	0	0
No other predisposing factors	12 (16)	1 (2)	0	0	0	0	0
No. of references	50 ^c	40 ^d	39 ^e	19 ^f	3 ^g	3 ^h	1 ⁱ

^a Diabetes mellitus only or as main condition.

^b Animal bites or stings (insect, spider, scorpion, or magpie), burns, or tattoos.

^c References 8, 19, 36, 43, 44, 47, 50, 55-58, 64, 70, 86, 88, 97, 99, 103, 116, 117a, 134, 139, 144, 156, 158, 170, 178, 184, 187, 190, 204, 205, 208, 212, 221, 223, 234, 246, 268, 275, 291, 298, 304, 307, 315, 318, 322, 327, 355, 358, and 367.

^d References (18, 344), 40, (42, 98), 67, 69, 102, 105, 122, 140, 154, 160, 161, 164, 172, 176, 201, 206, 207, 209, 211, 217, 218, 222, 224, 227, 236, 251, 255, 262, 267, 276, 278, 282, 283, 286, 296, 370, and 371 (references in parenthesis refer to the same cases).

^e References 1, (4, 81), 9, 26-29, 37, 48, 51, 58, 64, 90, 104, 107, 110, 113, 127, 134, 150, 162, 171, 185, 199, 230, 240, 241, 250, 253, 261, 266, 316, 319, 326, 329, 334, 343, 365, and 366.

^f References 35, 45, (83, 120), 87, 92, 106, 115, 143, 157, 173, 195, 197, 200, 213, 294, 308, 320, 347, and 362.

^g References 256, 271, and 301.

^h References 23, 270, and 293.

ⁱ Reference 336.

probable *C. bertholletiae* infection (Table 2). In three other cases, *Cunninghamella* organisms were identified at the genus level only (66, 79, 145). Additionally, nine other cases met only the European Organization for Research and Treatment of Cancer/Mycoses Study Group criteria for probable pulmonary or sinopulmonary *C. bertholletiae* (34, 85, 124, 164, 282, 313, 369) or *Cunninghamella* (333) infection; all of these patients died. These nine patients were not included in the present review.

Epidemiology and risk factors. *C. bertholletiae* remains a rare cause of mucormycosis and has been described almost exclusively (98%) for immunosuppressed hosts (Table 2). The predominant mode of acquisition of *C. bertholletiae* infections is presumed to be via the respiratory tract. Indeed, pulmonary and/or sinus (42, 224, 283) involvement was reported in 74% (32/43 infections) of proven *C. bertholletiae* infections (Table 3). *Cunninghamella* species have been isolated from air samples collected in hospital wards in London (228, 279) and in buildings in the United States (310). The small size of sporangiospores allows them to remain airborne for prolonged periods, which can increase the exposure risk (142, 279, 280). Isolation of *Cunninghamella* organisms from indoor air can vary from one geographical area to another and in different seasons in the United States (310). Similarly, a cluster of four *C. bertholletiae* infections in a single German hospital under-

going construction was reported over a 2-year period (282).

Percutaneous inoculation of *C. bertholletiae*, although less common, has been described from the inpatient (218, 251), outpatient (262), and community (122, 267) settings, following pleural taps (218), peritoneal dialysis (262), use of blood glucose self-monitoring equipment (122), and insulin injections (267). Several adhesive products used in hospitals have been linked with the development of Mucormycetes wound infections (40, 279, 280), including *C. bertholletiae* infections (218). A unique case report by Passos et al. (251) described persistent *C. bertholletiae* fungemia detected in three sets of blood cultures obtained every 4 days from a patient with uncontrolled diabetes mellitus following several invasive procedures during intensive care unit and ward stays (251). However, in view of a lack of histological evidence of mucormycosis, one cannot rule out the possibility of pseudofungemia rather than true invasive infection with *C. bertholletiae*. Traumatic injuries have been associated with *C. bertholletiae* infections, including motor vehicle accidents (40, 279), abrasions occurring while fishing in a patient with leukemia (164), and nondescript trauma in a human immunodeficiency virus-positive patient (217).

The most common underlying conditions described for patients with *C. bertholletiae* infections are leukemia (51%), diabetes mellitus (19%), nonmalignant hematological diseases (16%), deferoxamine-based therapy (12%), organ transplanta-

TABLE 3. Clinical syndromes in reported cases of unusual Mucormycetes infection

Species (n)	% of reported cases or no. of cases					
	Soft tissue infection (osteomyelitis or arthritis) ^a	Pulmonary infection (sinopulmonary/ cardiopulmonary infection)	Disseminated infection	Rhino-orbito-cerebral infection (otogenic infection) ^a	Renal infection ^b	Intra-abdominal infection (gastrointestinal infection)
<i>Apophysomyces elegans</i> complex (74)	52.7 (5.4)	0	10.8	25.7 (2.7)	6.8	4.0
<i>Cunninghamella bertholletiae</i> (43)	9.3 (2.3)	30.2 (2.3/2.3)	48.8	4.7	0	2.3
<i>Saksenaia vasiformis</i> (42)	73.8 (9.5)	0	9.5	14.3	2.4	0
<i>Rhizomucor pusillus</i> (22)	13.6 (4.5)	22.7 (4.5/4.5)	40.9	9.0	0	4.5
<i>Syncephalastrum racemosum</i> (4)	75.0 (1 case of onychomycosis)	0	0	0	0	1 case
<i>Cokeromyces recurvatus</i> (3)	0	1 case	0	0	1 case	1 case
<i>Actinomyces elegans</i> (1)	0	0	1 case	0	0	0
Total (189)	42.3	12.2	22.8	15.3	3.7	3.7

^a The cases in parentheses are also included in the total numbers of soft tissue or rhino-orbito-cerebral infections.

^b Kidney and/or urinary tract infection.

tion (9%), asplenia (7%), hepatic cirrhosis (2%), AIDS and i.v. drug abuse (2%), and chronic pharmacological immunosuppression for treatment of autoimmune disease (2%) (Table 2). Only two descriptions of *C. bertholletiae* or *Cunninghamella* species infection have been reported for seemingly immunocompetent patients (145, 370). The first case was a 61-year-old man with a history of alcoholic binges who had chronic progressive pleural-pulmonary disease caused by amphotericin B (AmB)-resistant *C. bertholletiae* leading to his death (370). The second case was a 42-year-old male farmer who had microcytic hypochromic anemia and a history of seven episodes of malaria within the previous 10 years; he survived a 3-month progression of rhinofacial mucormycosis caused by *Cunninghamella* spp. (145). *Plasmodium falciparum* malaria can cause immunosuppression sufficient to allow development of opportunistic mold infections during the malaria recovery phase (71, 364). The availability of free iron as a sequela of hemolysis and occurrence of acidosis via interaction of the parasite with the microcirculation may contribute to Mucormycetes infections (71).

Pathogenesis. Airborne fungal spores are ubiquitous and can be found on human surfaces that come in contact with air, especially on the upper and lower airway mucosa (177, 280). Implantation of spores in the oral and nasal mucosa with subsequent extension to the rhinocerebral region is one of the probable modes of Mucormycetes infection (155, 283). Hence, dental extraction sites are cited as the portals of entry for Mucormycetes organisms (145, 155).

Because *C. bertholletiae* has been found in a wide variety of nuts, seeds, and plants, ingestion of sporangioles is possible (279). Acquisition of infection through the gastrointestinal tract was also postulated in cases of disseminated *C. bertholletiae* infection with gastrointestinal involvement (140, 161, 203, 206, 371). However, all of these patients had lung involvement, and one clearly had initial symptoms of pneumonia (203).

Fungi can be cultured from nasal mucus and are considered normal contents of nasal secretions (177). However, members of the order Mucorales were found very rarely in nasal mucus for 210 patients suffering from chronic rhinosinusitis and 23 healthy individuals in Austria (1 of 233 patients) (46), suggesting that fungal spores in the mucus of the airway mucosa are cleared efficiently by mucociliary transport (46, 280). Alterna-

tively, the level of airborne contamination by Mucormycetes was low in the studied region (280). Moreover, the occurrence of rhino-orbito-cerebral infection caused by *C. bertholletiae* is lower than that of pneumonia (Table 3), suggesting that the organism more efficiently penetrates the lower respiratory tract and alveolar space of immunocompromised patients.

Animal models have highlighted some of the key pathogenic features of *C. bertholletiae* infection (61, 135, 148, 263). Histological examination of infected lung tissues in experimental mouse models showed similarities with human infection, namely, early angioinvasion and thrombosis, resulting in alveolar hemorrhage and consolidation (135). *C. bertholletiae* hyphae invaded the lung when leukocytopenia continued for more than 1 week in mice given cyclophosphamide (135). Angioinvasion caused by Mucormycetes was more extensive in neutropenic than nonneutropenic patients (30). However, unlike the case for aspergillosis, paradoxical hyperinflammatory responses were not observed in the lungs of nonneutropenic patients with cancer who had mucormycosis (30). In a less immunocompromised patient population, neutrophilic infiltrates and granulomatous inflammation were observed in 100% and 50% of cases, respectively (100).

Few available studies have suggested that *Cunninghamella* spp. are more virulent than *Rhizopus* spp. In a fly model of infection, *C. bertholletiae* exhibited the highest degree of pathogenicity compared with infection by *Rhizopus* and *Mucor* species (61). In another study using polymorphonuclear leukocytes (PMNs) obtained from healthy volunteers, *C. bertholletiae* exhibited greater resistance to human PMN-induced damage, with or without the use of antifungal agents, than did *Rhizopus* spp. (310). However, neutrophils at high concentrations were similarly effective at damaging *C. bertholletiae* and *Rhizopus* spp., obviating the differences between these species (311). The fact that Mucormycetes spores are much larger than *Aspergillus fumigatus* spores may provide a mechanistic explanation for the differences in the rates of phagocytosis and virulence of these fungi reported in a *Drosophila melanogaster* model of mucormycosis (61).

In addition, *C. bertholletiae* has been shown to be more capable of suppressing interleukin-8 (IL-8) release and increasing tumor necrosis factor alpha (TNF- α) release from

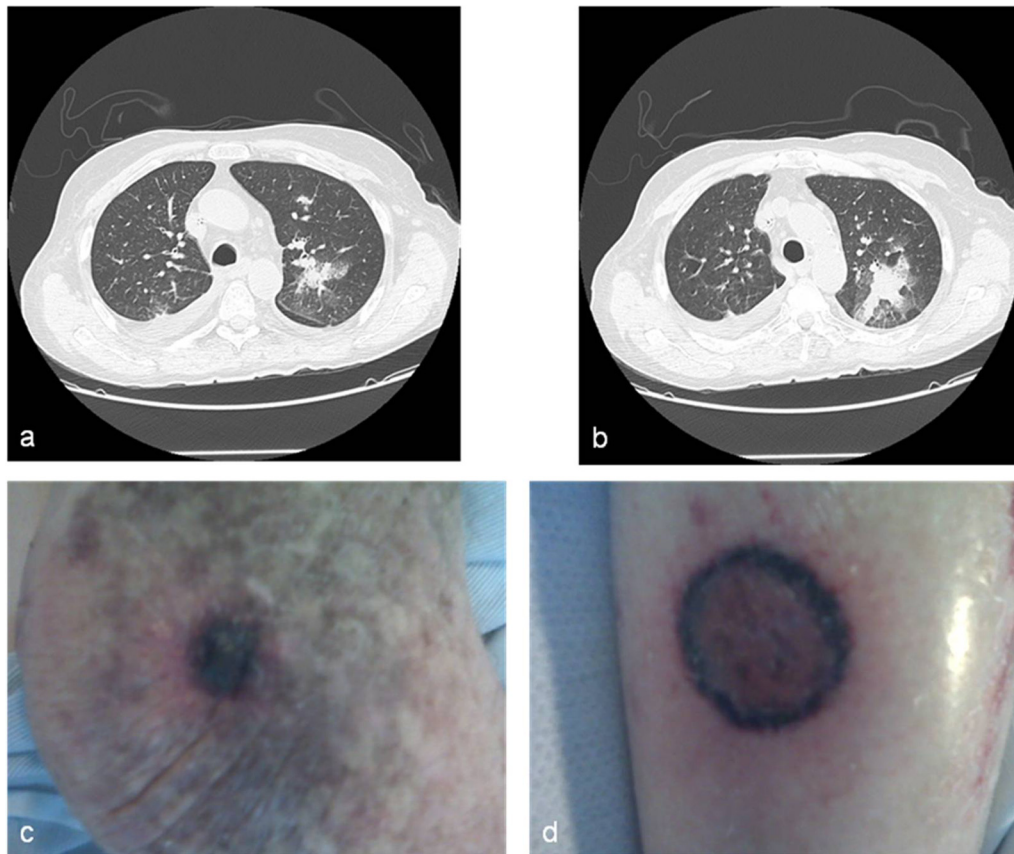


FIG. 2. Disseminated *C. bertholletiae* infection. The images are contrast-enhanced CT images of the chest revealing progression of pulmonary lesions in the left side (a and b) and pictures of necrotic skin lesions in the left elbow (c) and right leg (d) of a 76-year-old man with acute lymphoblastic leukemia (unpublished case).

human neutrophils than *Rhizopus* spp. (311). Because IL-8 is a potent chemotactic factor, the consequences of decreased IL-8 production may include diminished chemotactic signals and reduced recruitment of satisfactory numbers of neutrophils to sufficiently damage hyphae (311). In addition, enhanced production of TNF- α by neutrophils exposed to *C. bertholletiae* compared with those exposed to *Rhizopus* spp. may generate a complex network of immunosuppressive mechanisms that give an advantage to the fungus for further tissue spread (311). Additionally, increasing fungal biomass was recently demonstrated to be a key factor influencing PMN damage of filamentous fungi (20). Attenuation of PMN-mediated damage required 22 h of incubation for *Aspergillus terreus* but only 6 h for *C. bertholletiae* (20).

Finally, *C. bertholletiae* displays greater *in vitro* resistance to the iron chelator deferasirox than do *Rhizopus* spp. (189), suggesting that the former has an enhanced capacity for iron extraction from the environment or host, which may contribute to its enhanced pathogenesis *in vivo*.

Collectively, the differences in the host immune responses to *C. bertholletiae* observed *ex vivo* and *in vivo* may explain the relatively poorer prognoses for *C. bertholletiae* infections than those for infections with more common molds, such as *Aspergillus* and *Rhizopus* species (20, 61, 189).

Clinical presentation. As seen with other Mucormycetes, the clinical presentations of infections caused by *C. bertholletiae* are not unique. Infections with this opportunistic pathogen present in many clinical forms, including pulmonary, disseminated, cutaneous-articular, rhino-orbito-cerebral, endocardio-vascular, and peritoneal forms (Table 3).

(i) Disseminated infection. Disseminated infection ($n = 18$) with pulmonary involvement ($n = 15$) was the most common presentation among reported cases of *C. bertholletiae* infection (Fig. 2). We identified three additional patients in whom dissemination was likely (164, 211, 286). All but one of the patients with disseminated infection caused by *C. bertholletiae* died of the infection (296). The majority (14/21 infections [67%]) of these infections were diagnosed postmortem (18, 79, 122, 140, 160, 161, 164, 206, 209, 227, 236, 344, 371). Hematological disease was reported as the underlying condition in most of the disseminated infection cases (16/21 cases [76%]). Kidney and liver transplantation, diabetes mellitus, and hepatic disease were other common underlying conditions.

Accounting for all 21 cases of disseminated *C. bertholletiae* infection, including cases diagnosed by autopsy results, the organs and tissues affected were the lungs (81%), heart (62%), spleen (57%), brain (48%), kidneys (38%), liver (29%), gastrointestinal tract (24%), skin (24%), thyroid gland (19%),

lymph nodes (10%), mediastinum (5%), larynx (5%), thymus (5%), chest wall (5%), muscle (5%), and pancreas (5%). Disseminated *C. bertholletiae* infections originated most frequently from primary pulmonary or cutaneous sites of inoculation (122, 164, 279). Bloodstream dissemination may occur early in the course of *C. bertholletiae* pneumonia. Kobayashi et al. (160) documented *C. bertholletiae* DNAemia that occurred 2 days prior to the appearance of lung infiltrates in a patient with *C. bertholletiae* pneumonia.

A variety of signs, symptoms, and laboratory abnormalities have been reported for patients with disseminated *C. bertholletiae* infections, including fever (15/20 cases [75%]) (18, 122, 140, 160, 161, 164, 203, 206, 209, 211, 222, 227, 286, 344), rigor (122, 203), fatigue (122), progressive decline in performance status (140), myalgia (209), arthralgia (209, 296), metabolic acidosis (140), respiratory alkalosis (18, 164, 344), vomitus (140), uremia (140), respiratory distress (161, 203, 209), loss of consciousness or change in mental status (18, 122, 161, 164, 203, 206, 209, 286, 344, 371), and even signs of septicemia (67), hypotension (203, 206), and multiorgan failure (164, 206, 211).

(ii) Pulmonary infection. Pulmonary infection ($n = 13$) was the main localized site of *C. bertholletiae* infection in reported cases (Table 3) (69, 102, 105, 154, 172, 176, 207, 255, 276, 278, 282). With the exception of two patients (172, 278), all reported cases with pulmonary infection had an underlying hematological malignancy. Additionally, two patients had cardiopulmonary (370) or rhino-orbito-cerebral and pulmonary (283) infections. Only six patients (19%) with lung involvement (including those with disseminated infection) survived (69, 172, 207, 255, 282, 296).

Hemoptysis or bloody sputum was described for five patients (33%) with pulmonary *C. bertholletiae* infection (69, 172, 207, 282). This sign may be associated with early recognition and treatment of the infection, as three of these patients survived (172, 207, 282). In contrast, hemoptysis was reported for only two patients with disseminated infection and pulmonary involvement (12%); these cases were diagnosed postmortem only (160, 209).

(iii) Cardiovascular involvement. Although rarely diagnosed antemortem, invasion of the heart and/or pericardium is common in reported cases of disseminated *C. bertholletiae* infection, and it occurred in 62% of infections ($n = 13$). After the lungs, the heart was the most common organ involved in disseminated infection (67, 122, 140, 161, 206, 209, 211, 222, 227, 236, 286, 371). Among the patients with heart involvement, the lungs were also affected in 79% of cases (11/14 patients) (Table 3). Unusual patterns of cardiovascular involvement have also been described, including a mycotic pulmonary mass penetrating the endocardium (222) and a cutaneous infection that disseminated to involve the coronary arteries (122). These features support the hypothesis that the heart can be affected by either contiguous spread (from the lungs) or hematogenous dissemination of this infection.

Occasionally, young immunocompromised adults ($n = 4$) with disseminated *C. bertholletiae* infections presented with symptoms mimicking myocardial infarction (161, 211, 222, 236). All of these patients experienced chest pain and ischemic changes in electrocardiograms (161, 211, 222, 236), with (222, 236) or without elevations in cardiac enzyme levels. Fever and the appearance of pulmonary infiltrates on chest X-rays were

described in three cases and were important clues indicating concomitant lung infection (161, 222, 236). Also, evidence of congestive heart failure was observed in a subset of patients ($n = 3$) (161, 211, 222). Echocardiography revealed vegetative endocarditis (211), and an echodense ventricular mass originating from the lung was observed on magnetic resonance imaging (MRI) scans in one case (222). However, a lack of vegetation or pericardial effusion does not rule out a heart infection (161). Mycotic mural myocarditis with disseminated infection to several organs and pulmonary involvement occurred in three of these patients who underwent necropsy (161, 222, 236). Myocarditis was associated with multiple embolic brain lesions shown on head computed tomography (CT) scans and with recurrent vegetations in the aorta, mitral perforation, and progressive heart and multiple organ failure before death (211). Consequently, disseminated infection with an angiotropic mold such as *C. bertholletiae* should be considered for immunocompromised patients who experience acute vascular events such as ischemic myocardial infarctions.

(iv) Rhino-orbito-cerebral infection. Although 50% of all reported mucormycosis cases are rhinocerebral (145, 287), only 13% (6/46 cases) of *C. bertholletiae* infections (3 cases) or *Cunninghamella* spp. infections (3 cases) reported in the literature occurred in this form (42, 66, 98, 145, 224, 283), including one case classified as sinopulmonary (283).

The clinical course of rhino-orbito-cerebral mucormycosis caused by *C. bertholletiae* varies considerably depending on the underlying immunosuppression. At one end of the spectrum, indolent rhinofacial *Cunninghamella* infection was diagnosed in an immunocompetent host following tooth extraction and was successfully treated with AmB deoxycholate (145). Microscopic analysis of affected tissue showed granulomatous inflammation, suppuration, and well-circumscribed necrosis but limited angioinvasion, which was suggestive of a relatively preserved immune reaction (145). A similar indolent course of sinusitis was described for a 70-year-old man with non-insulin-dependent diabetes mellitus and a myelodysplastic disorder that was successfully treated with a combination of AmB and rifampin without sinus surgery (224). Also, a 68-year-old woman with diabetes mellitus and pansinusitis recovered after treatment with AmB plus 5-flucytosine but had to undergo ethmoidectomy, sphenoidectomy, and septal resection (66). On the other end of the spectrum, a fatal rhino-cerebral *C. bertholletiae* infection was described for a 70-year-old man with diabetes mellitus, thalassemia minor, and transfusion-associated hemosiderosis who received deferoxamine-based therapy; AmB-based therapy and repeated surgical resections were not effective (42, 98). Similarly, a 41-year-old male patient with leukemia who had a persistent rhino-orbito-cerebral *C. bertholletiae* infection and pulmonary involvement also died despite undergoing antifungal-based and surgical treatment (283), emphasizing the poor prognosis for infection with this pathogen in the setting of persistent neutropenia (245) or iron overload. Histological examination of tissue and autopsy analysis showed abundant necrosis and characteristic angioinvasion as the hallmarks of *C. bertholletiae* infection (283). These cases suggest that the more immunocompromised the patient is, the greater risk he or she has of severe rhino-orbito-cerebral *C. bertholletiae* infection.

(v) **Soft tissue infection.** Primary cutaneous (40, 267) and cutaneo-articular (217) cases of mucormycosis caused by *C. bertholletiae* were reported following percutaneous inoculation or trauma in patients with diabetes mellitus, renal transplant recipients, and an i.v. drug abuser with AIDS (40, 217, 267). Cutaneous *C. bertholletiae* infection was also described for a patient with leukemia who died 18 days after development of a necrotic skin lesion following the use of elastic adhesive tape surrounding a pleural effusion damage site (218). Cutaneous *C. bertholletiae* infections typically appear as necrotic lesions (40, 267), with occasional creamy white exudates and granules (217). Among patients with soft tissue *C. bertholletiae* infections ($n = 3$), two patients recovered after resection of skin lesions and systemic treatment with AmB, although one patient needed a leg amputation (40). In addition, soft tissue infections have been associated with death when the infection perforates a vital tissue plane such as the femoral artery (217).

Secondary disseminated *C. bertholletiae* infection can also result from primary cutaneous infection. Hampson et al. (122) described a 68-year-old man with myelodysplasia and diabetes mellitus who had received desferrioxamine-based therapy. An ultimately fatal (within 8 days after the initial symptoms) disseminated *C. bertholletiae* infection developed in this patient following a primary skin infection associated with the use of a blood glucose self-monitoring device.

(vi) **Peritonitis.** Only one case of *C. bertholletiae* peritonitis has been reported. This infection occurred secondary to use of a Tenckhoff catheter for continuous ambulatory peritoneal dialysis (262). The patient, a 39-year-old aboriginal diabetic woman with end-stage renal failure, recovered after catheter removal (262).

(vii) **Breakthrough *C. bertholletiae* infection.** *C. bertholletiae* infection may present as a breakthrough infection following antifungal-based prophylaxis with voriconazole (102, 206), fluconazole (236, 283), or itraconazole (282). Breakthrough mucormycosis can occur after use of all prophylactic azoles that are not active against Mucormycetes (242, 244). In experimental models, preexposure of Mucormycetes to voriconazole selectively enhanced their virulence in fly and murine infection models (179). Voriconazole-associated mucormycosis appears to have a poor outcome, perhaps reflecting the advanced immunosuppressive state of infected patients along with delayed diagnosis of the infection (264).

Breakthrough *C. bertholletiae* infection in patients on antifungal therapy is almost uniformly fatal due to infection or other causes (102, 206, 236, 283), despite the use of antifungal drugs (AmB or a lipid formulation in sequential therapy with other antifungals) and surgical procedures performed in two patients (102, 283).

(viii) ***C. bertholletiae* infection in pediatric patients.** We found six cases of *C. bertholletiae* infection in pediatric patients (age range, 3 to 16 years) with hematological malignancies ($n = 5$) or hepatic cirrhosis ($n = 1$) (69, 102, 140, 207, 209). The infections occurred as pneumonia ($n = 4$) (69, 102, 207) or disseminated disease ($n = 2$) (140, 209) in these patients. Three patients who survived (69, 207) or died of causes other than infection (102) had localized pulmonary infections and underwent lobectomies (69, 207) or resection of the entire pulmonary nodule and surrounding lung parenchyma (102) plus systemic antifungal-based therapy.

(ix) **Chronic infection.** Although *C. bertholletiae* infections are typically acute in onset and evolution, chronic forms lasting 1 (224), 2 (172, 296), and 4 (209) months have been described, even with disseminated infections (296). The patients with chronic infections ($n = 4$) were all adults, including patients with preleukemic syndrome (209) or myelodysplasia with diabetes mellitus (224), a patient with another nonmalignant hematological disease who underwent splenectomy and received deferoxamine (296), and a patient with autoimmune diseases and renal failure who received glucocorticoid-based therapy that was stopped 1 year before *C. bertholletiae* infection (172). Patients who died either did not receive treatment because of misinterpretation of the agent detected (considered a contaminant) in three specimens during a 4-week period (209) or had an AmB-resistant *C. bertholletiae* infection (370). Therefore, *C. bertholletiae* infections may have chronic courses in patients who are relatively less immunocompromised or immunocompetent individuals, leading to relatively better outcomes (survival rate, 67%).

Diagnosis. *Cunninghamella* spp. can be found in laboratory specimens as environmental contaminants (279). However, an isolate of *C. bertholletiae* from any clinical material should be analyzed carefully, as it is not an ordinary contaminant. In at least two cases, misinterpretation of mycological laboratory findings caused fatal delay or lack of treatment (209, 370). *C. bertholletiae* is a fast-growing mold that can grow at room temperature and at 30°C to 45°C in 24 to 48 h (276, 279, 283). *C. bertholletiae* grows at temperatures above 40°C, which distinguishes it from *C. elegans* (279, 359). The microscopic morphology of *C. bertholletiae* in culture varies depending on the culture medium (279). The species appears as branched sporangiophores terminating at a swollen, terminal vesicle with spherical, ovoidal, or ellipsoidal sporangioles (Fig. 3) (34, 181, 262, 279, 283).

Isolation of molds from blood cultures is much more difficult than that of yeast-like fungi (160). PCR-based detection of *Cunninghamella* nucleic acid in serum may be possible in some cases of *C. bertholletiae* infection, even when blood cultures are negative (160). Kasai et al. analyzed the sensitivity and specificity of a real-time quantitative PCR (qPCR)-based assay for detection of pulmonary and disseminated *Cunninghamella* infections in an experimental neutropenic rabbit model (149). They found that the qPCR assay was more sensitive than culture analysis for detection of *Cunninghamella* spp. in bronchoalveolar lavage fluid (100% versus 67%) and could detect *Cunninghamella* DNA in 18 of 31 (58%) serial plasma specimens as early as day 1 after inoculation of the agent (149). Hata et al. used similar PCR-based approaches for detection of *Lichtheimia* (formerly *Absidia*), *Apophysomyces*, *Cunninghamella*, *Mucor*, *Rhizomucor*, *Rhizopus*, and *Saksenaia* species in culture and in fresh and fixed tissue specimens, which produced results at the genus level in as little as 4 h (125). Under these highly controlled conditions, this assay demonstrated high levels of sensitivity (100%) and specificity (92%) compared with the gold standard culture-based methods (125). Also, with formalin-fixed, paraffin-embedded tissue, the sensitivity of the assay was 56%, and the specificity was 100% (125). However, relatively few data on the performance of these assays for patients with *C. bertholletiae* infection are available (160).

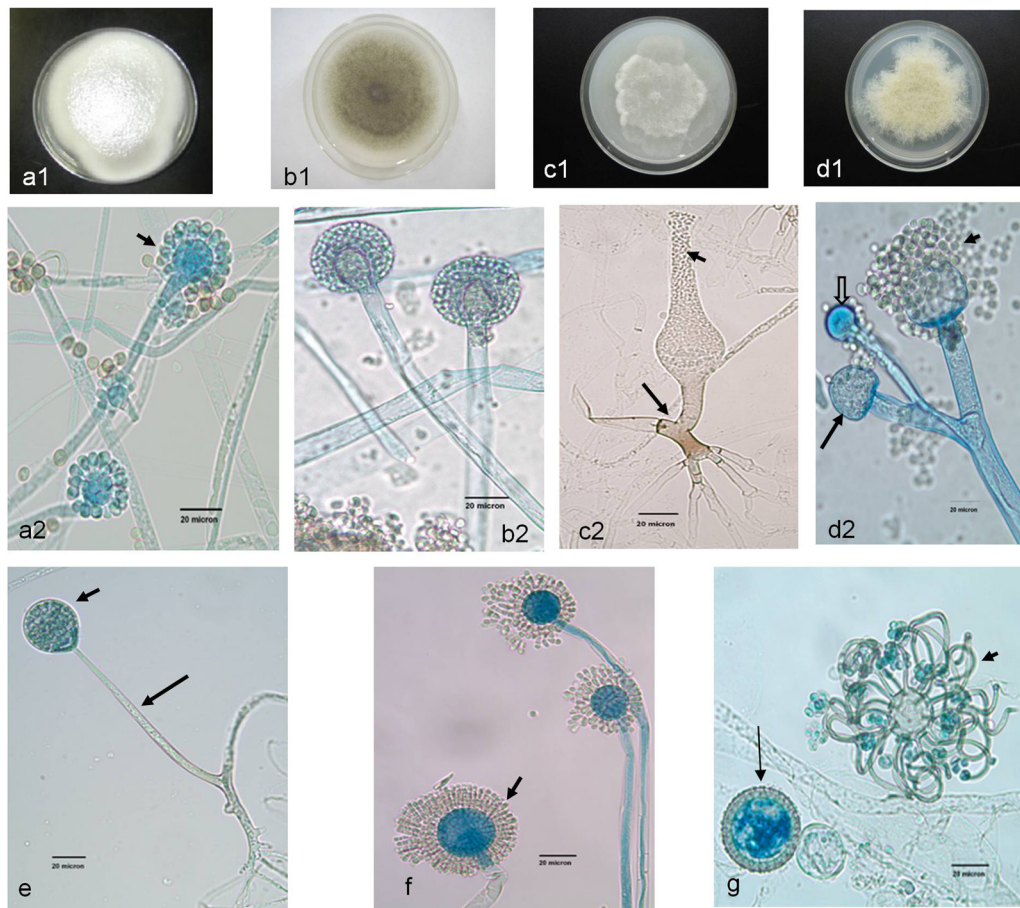


FIG. 3. Unusual Mucormycetes. (a2, b2, c2, d2, and e to g) Lactophenol cotton blue mount preparations. (a1, b1, c1, and d1) Potato dextrose agar (PDA) medium plates. (a1) *C. bertholletiae* colony surface on a PDA medium plate. (a2) *C. bertholletiae* sporangioophores in terminal swellings called vesicles, with sporangioles (short arrow). (b1) Colony surface of *R. pusillus* on a PDA medium plate incubated at 30°C for 96 h. (b2) *R. pusillus* sporangioophores with globose sporangia. (c1) *S. vasiformis* colony surface on a PDA medium plate incubated at 30°C (48 h). (c2) *S. vasiformis* sporangioophore arising from a “foot cell”-like hyphal element (long arrow), flask-shaped sporangium, and liberated sporangiospores (short arrow). (d1) *Actinomucor elegans* colony surface on a PDA medium plate incubated at 30°C (96 h). (d2) *Actinomucor elegans* branched sporangioophores, sporangium (long arrow), columella (block arrow), and various sporangiospores (short arrow). (e) Unbranched *Apophysomyces elegans* sporangioophore (long arrow) with a pyriform sporangium (short arrow). (f) *S. racemosum* sporangioophores with merosporangia (short arrow). (g) *C. recurvatus* sporangiolating vesicle (short arrow) and zygosporangia (long arrow). Bars, 20 µm. (All photomicrographs except panel a1 courtesy of Deanna A. Sutton, reproduced with permission.)

Management. Early diagnosis of and prompt intervention in Mucormycetes infection are essential for a favorable outcome (62). Infection with *C. bertholletiae* carries the poorest prognosis among all Mucormycetes infections, including those caused by unusual species (Table 4). Surgical resection of infected lesions in many of the reported *C. bertholletiae* infections was limited by (i) thrombocytopenia associated with the patient’s underlying malignancy, (ii) disseminated infection or multilobular lung involvement at the time of diagnosis, or (iii) very late diagnosis in a clinically unstable patient. In addition, immunosuppression threatens healing after surgical intervention.

Traditionally, the gold standard of antifungal-based therapy for *C. bertholletiae* infections is conventional AmB deoxycholate. However, renal toxicity often limits the dose and duration of therapy (207, 282). Although the use of lipid preparations of AmB can delay the onset of nephrotoxicity, renal impairment is still common, possibly leading to treatment interruptions (38, 207, 282). Virtually nothing is known about the

optimal dose of AmB deoxycholate or lipid AmB formulations for *C. bertholletiae* infections, although many experts advocate the use of high dosages (7.5 to 10.0 mg/kg of body weight/day) in the initial treatment phase.

Importantly, clinically relevant MIC breakpoints for Mucormycetes are lacking (11, 25). Specifically, data concerning the susceptibility of *C. bertholletiae* to antifungals are available for fewer than 100 isolates (6, 10, 40, 60, 75, 76, 102, 105, 108, 112, 164, 207, 252, 258, 262, 282, 283, 299, 312, 321, 370). Collectively, specific studies have shown that the MICs of AmB, itraconazole, and posaconazole are often 2 to 4 dilutions higher for *C. bertholletiae* than for the more commonly encountered *Rhizopus* and *Mucor* spp. (6, 75, 76, 112, 299, 312). However, in two studies, a low MIC of posaconazole (0.5 µg/ml) was observed for all clinical isolates of *C. bertholletiae* tested ($n = 6$) (76, 252). Terbinafine had the lowest MIC in three studies that tested only 12 *C. bertholletiae* strains (6, 76, 252); unfortunately, its oral formulation and pharmacokinetics

TABLE 4. Frequencies of treatment and overall mortality rates among reported cases of unusual Mucormycetes infection

Parameter	Value						
	<i>Apophysomyces elegans</i> complex	<i>Cunninghamella bertholletiae</i>	<i>Saksenaia vasiformis</i>	<i>Rhizomucor pusillus</i>	<i>Syncephalastrum racemosum</i> (n = 4)	<i>Cokeromyces recurvatus</i> (n = 3)	<i>Actinomucor elegans</i> (n = 1)
No. of patients undergoing treatment/total no. of patients (%)							
Surgical procedures	68/69 (99)	14/43 (33)	35/41 (85)	10/21 (48)	2 cases	1 case	1 case
Antifungal therapy	63/69 (91)	33/43 (77)	30/41 (73)	18/22 (82)	3 cases	2 cases	1 case
AmB	36/62 (58)	16/33 (49)	24/33 (73)	4/18 (22)	0	0	0
L-AmB	9/62 (15)	3/33 (9)	3/33 (9)	3/18 (17)	1 case	0	0
Combined and/or sequential therapy ^a	13/62 (21)	10/33 (30)	2/33 (6)	6/18 (33)	0	1 case	0
Posaconazole ^b	3/62 (5)	2/33 (6)	3/33 (9)	3/18 (17)	0	0	0
Other antifungals ^c	1/62 (2)	2/33 (6)	1/31 (3)	2/18 (11)	3 cases	1 case	1 case
Overall mortality (no. of deaths/no. of patients [%])	21/69 (30)	33/43 (77)	17/42 (40)	10/22 (46)	0	1 case	1 case
Number of references ^d	50	40	39	19	3	3	1

^a Combined and/or sequential antifungal drugs, including AmB and/or L-AmB, without posaconazole.

^b Posaconazole in combination or as sequential therapy with AmB and/or L-AmB.

^c For example, echinocandins, azoles, allylamines, and nystatin.

^d References are listed in the footnotes to Table 2.

make its use problematic for systemic infections. Researchers have performed studies of combinations of antifungal agents for seven strains of *C. bertholletiae* (73, 111, 258). Antagonism was not seen (73) and synergism was seen between AmB and terbinafine (111) for one strain each (73, 111). In addition, synergistic (three strains) and indifferent (two strains) activities of AmB and posaconazole against five *C. bertholletiae* strains were observed (258). In neutropenic and diabetic murine models of disseminated *C. bertholletiae* infection, AmB and posaconazole reduced the fungal loads in organs, while itraconazole showed limited efficacy (252). A previous study, however, showed poor results of AmB for experimental *C. bertholletiae* infection (135).

In reported cases of proven *C. bertholletiae* infection, 33 patients (77%) received antifungal-based therapy (Table 4). AmB deoxycholate and/or lipid-based formulations of it were used in almost all of these patients alone (n = 19), sequentially (n = 8) (102, 164, 172, 207, 222, 255, 282, 283), or in combination with other antifungal drugs (n = 4) (105, 160, 203, 224). One patient with AmB-resistant *C. bertholletiae* peritonitis recovered with peritoneal catheter removal only (262). Sequential therapy with either AmB or L-AmB followed by posaconazole was given to two patients with proven *C. bertholletiae* infection who survived (255) or died of another cause (102). Overall, only 11 of the 33 patients (33%) who received antifungal drugs survived. These data are in agreement with the observation that *C. bertholletiae* is often refractory to systemic antifungals (262, 279). In addition to receiving antifungal drugs, 14 patients underwent various surgical procedures (40, 42, 69, 102, 105, 172, 207, 211, 217, 255, 267, 278, 283, 296), and 8 recovered (57%) (40, 69, 102, 172, 207, 255, 267, 296), whereas only 2 of 18 patients (11%) recovered after receiving antifungal-based therapy alone (224, 282). Survival rates are generally high for patients who undergo surgical resection of infected lesions in addition to systemic antifungal-based therapy (287). However, it is difficult to rule out a selection bias of less ill patients who preferentially receive surgical resection

because they are better candidates for recovery.

Although no specific laboratory studies exist for *C. bertholletiae*, gamma interferon and granulocyte-macrophage colony-stimulating factor (GM-CSF) augment the activity of PMNs against *Rhizopus* spp. and *Lichtheimia corymbifera* (109). Adjunctive therapy with GM-CSF was administered sporadically (n = 3) to patients with *C. bertholletiae* infections (105, 160, 282), only one of whom survived (282).

Rhizomucor pusillus

Taxonomy. In 1978, the genus *Rhizomucor* was described as a thermophilic *Mucor*-like fungus. In particular, the uncommon human pathogen *R. pusillus* was formerly known as *Mucor pusillus* (157) and also cited as *Rhizomucor parasiticus* (140, 279). *Rhizomucor* traditionally was thought to comprise three species: *Rhizomucor miehei*, *R. pusillus*, and *Rhizomucor tauricus* (300, 342). *R. miehei* is synonymous with *Mucor miehei*, but the former is the preferred designation (279). Additional *Rhizomucor* species have been described, such as *Rhizomucor nainitalensis* (<http://Zygomycetes.org/index.php?id=49>), *Rhizomucor pakistanicus* (214), *Rhizomucor endophyticus* (373), and *R. variabilis*, with two subspecies: *R. variabilis* var. *regularior* and *R. variabilis* var. *variabilis* (374, 375). *R. pusillus*, *R. miehei*, and both varieties of *R. variabilis* can cause mucormycosis in humans (279, 345, 372). *R. variabilis* was recently phylogenetically nested far from *R. pusillus*, but within the *Mucor* clade (13, 351). *R. pusillus* and *R. miehei* are thermophilic saprophytic Mucormycetes with a wide geographic distribution but have not been associated commonly with human disease (279). *R. miehei* is important from a biotechnological aspect for cheese production (341) and in the pharmaceutical industry for the production of antibiotics and antifungals (323). Both *R. pusillus* and *R. miehei* were found in cigarettes and cured tobacco leaves in Nigerian-made cigarettes (232). Also, concern about the health risk of these fungi has been expressed, as they can be zoonotic pathogens (232).

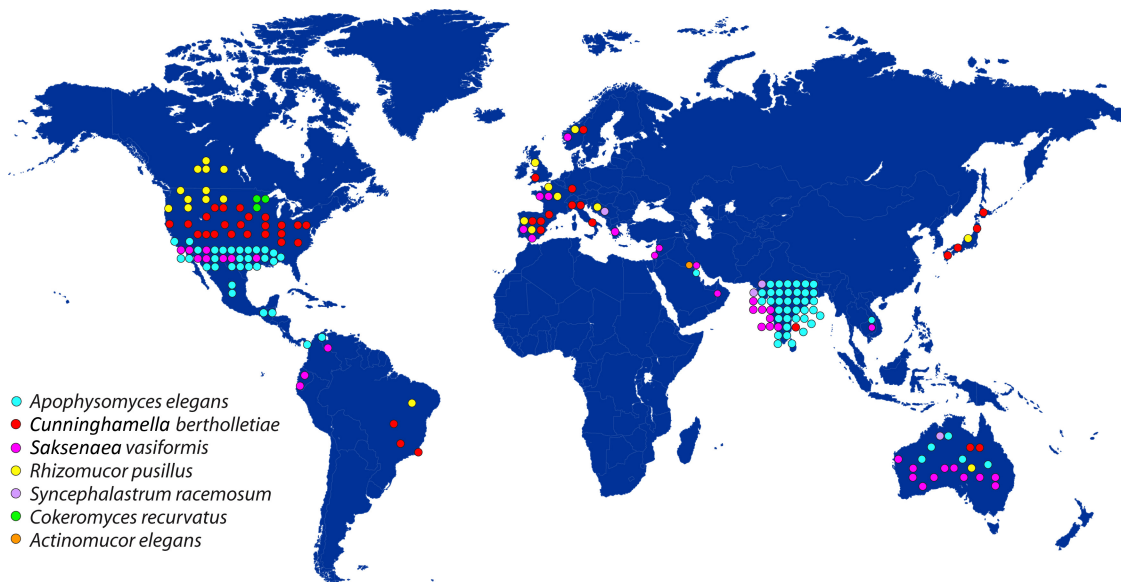


FIG. 4. Geographic distribution of reported cases of unusual mucormycosis. (Modified from a map that is freely available from psdGraphics.)

Reported cases. We found 22 cases of Mucormycetes infection with sufficient clinical information to identify *R. pusillus* as the definite infecting agent (Table 2). Postmortem diagnosis of the infection was accomplished in 23% of these cases (83, 92, 114, 173, 213, 362). Six other cases had a proven diagnosis of *Rhizomucor* species infection (16, 22, 32, 152, 248, 281), and two cases were probable *R. pusillus* infections (82, 225) according to European Organization for Research and Treatment of Cancer (EORTC) criteria (84). We found four other cases in which the etiology of the Mucormycetes species involved in mucormycosis resulted from the fact that these cases were epidemiologically related to other proven *R. pusillus* infection cases during nosocomial outbreaks (83, 106, 120). Several publications mention the potential for human *R. miehei* infection (130, 198, 279, 351), but we found only one case of invasive *R. miehei* infection, in a transplant recipient (244, 337); the researchers did not provide a clinical description of this case (337).

Epidemiology. Environmental isolates of *Rhizomucor* spp. can be found worldwide, with citations of their isolation in Eastern Europe, the British Isles, North America, Japan, Indonesia, India, and Africa (279). Human *R. pusillus* infections have been reported in the United States ($n = 7$), the European Union ($n = 8$), Canada ($n = 4$), Australia ($n = 1$), Brazil ($n = 1$), and Japan ($n = 1$) (Fig. 4). *Rhizomucor* spp. commonly contaminate air, soil, water, and organic matter, such as garden composting, municipal waste, cultivated mushroom beds, manure, leaf molds, grass, composted wheat straw, citrus waste composting, harvested wheat and sorghum dusts, dust from chicken stalls, guano, poultry droppings, and animal hair (2, 24, 231, 279, 302, 340, 349, 356). *R. pusillus* is a frequent cause of mucormycosis in mammals, leading to abortion and mastitis in cattle, cerebral mucormycosis in cats, and granulomatous lymphadenitis in steers (159, 235, 274, 279, 350). Also, *R. pusillus* has been found in foods such as grains, seeds, nuts, and beans (89, 279). This fungus has been used in retting of flax for manufacturing natural fibers in the United States and Europe

(129). Because of recently renewed interest in natural fibers, concerns have been raised about dust and fungal contaminants causing health problems in these industries (129).

Rhizomucor spores can easily become airborne and reach the alveoli because of their small size (3 to 5 μm) (279). They have been isolated from indoor air in hospitals in the United Kingdom (106, 228), Spain (83, 120), Canada (320), and Italy (290), as well as from household dust, including that on air conditioner filters, in Saudi Arabia (10). In addition, *Rhizomucor* spp. and other Mucormycetes were recovered from tap water and water from a main pipe that supply the pediatric bone marrow transplantation unit in Oslo, Norway (356). Three outbreaks or clusters of infections likely caused by *R. pusillus*, affecting patients with leukemia in hematology or oncology units in Spain (83, 120), Canada (320), and the United Kingdom (106), have been reported. In all of these occurrences, *Rhizomucor* spores were detected in the air (83, 106, 120, 320) and on surfaces close to the patients (83, 106). The outbreak was secondary to water damage in a linen store and a patient's shower room in a pediatric oncology unit (106). In other reports, outdoor refuse compactors located in the vicinity of clinical units were suspected to be the sources of *R. pusillus* (83, 320). In one of these studies, *R. pusillus* was also isolated from air samples obtained near the air intakes of the air conditioning units that cooled the hematology unit (83). Therefore, *R. pusillus* spores on decaying organic matter or water-damaged surfaces or in tap water in proximity to clinical units of hospitals may become airborne and be potential sources of infections in immunocompromised patients.

Nosocomial acquisition of *R. pusillus* was highly suspected in 36% (8/22 infections) of the reported infections (83, 106, 120, 157, 195, 294, 320). In another six cases, onset of infection occurred more than 1 week after hospital admission (87, 173, 213, 308) or 3 (115) or 7 (35) days after hospital discharge, which also implicates the hospital environment as a potential source of mold infections (237, 254). In another case, the infection was associated with a health care procedure (362).

Therefore, in 68% (15/22 cases) of the reported *R. pusillus* cases, the infections were or could be nosocomial or health care related. Considering that *R. pusillus* is ubiquitous and that humans undoubtedly repeatedly inhale airborne *R. pusillus* spores (157, 280), community-acquired cases of *R. pusillus* infection likely are underdiagnosed.

Like the case with *C. bertholletiae*, percutaneous introduction (152, 157, 195, 248, 294, 362) is the most common mechanism of cutaneous infections with *R. pusillus* (157, 195, 294, 362) or *Rhizomucor* spp. (152, 248). Continuous insulin infusion pump therapy (362), pleural drainage catheter insertions (157), venous catheter insertions (195, 294), and use of paper adhesive tape affixed to a plastic i.v. catheter (294) have all been implicated in *R. pusillus* infections. Similarly, bloodstream *Rhizomucor* infections have been described for patients receiving long-term parenteral nutrition via a Hickman line (152) and for an i.v. amphetamine abuser (248).

Hematological malignancy is a common underlying condition in patients with *R. pusillus* infections, representing 73% (16/22 cases) of the reported cases (Table 2). Twenty-seven percent of the cases occurred in the setting of hematopoietic stem cell (143, 320) or renal (347) transplantation or splenectomy (63, 92, 200). Diabetes mellitus (87, 195, 362) and other hematological (115) and autoimmune (362) diseases are among the most common nonmalignant conditions that have been associated with *R. pusillus* infection.

Pathogenesis. *R. pusillus* is considered a rare cause of human infection (279). Because of its ubiquitous nature and ability to cause disease in a variety of animals, frequent confusion of this agent with other genera or its detection as a culture contaminant may contribute to its low occurrence. Despite its lower pathogenicity than that of other Mucormycetes in human hosts, *R. pusillus* is still angioinvasive, resulting in thrombosis, hemorrhage, and tissue infarction (279). Reinhardt et al. (277) examined the ability of 33 Mucormycetes isolates to cause rhinocerebral disease following intranasal instillation of their spores into ketotic rabbits with alloxan-induced diabetes. They found marked differences in the abilities of the various Mucormycetes to cause infection. *R. pusillus* was less virulent than *Rhizopus* spp. In the same experiment, two thermotolerant *C. bertholletiae* strains, which were recovered from human lesions, did not cause either cerebral or pulmonary disease in the ketotic rabbits. The lungs and brain are among the most common sites of infection in reported cases of disseminated *C. bertholletiae* and *R. pusillus* infection. Therefore, these results should be extrapolated with caution to other immunosuppression backgrounds, in which pathogenesis may differ significantly from that in ketoacidotic animals.

Clinical presentation. (i) Pulmonary infection. Similar to the case with *C. bertholletiae* infection, the lungs were the most commonly affected organ (16/22 cases [73%]) in reported cases of *R. pusillus* infection. In 5 patients (23%), the infection was restricted to the lungs (35, 115, 197, 200, 320), whereas in the remaining 10 patients (11 infections), lung involvement was a feature of disseminated ($n = 9$), cardiopulmonary ($n = 1$) (92), or sinopulmonary ($n = 1$) (143) infection. Patients with isolated pulmonary infections had better prognoses than did patients with disseminated infections (survival rates of 80% and 22%, respectively).

(ii) Disseminated infection. Nine cases of disseminated *R. pusillus* infection have been reported in the literature (41% of cases) (106, 115, 173, 213, 308, 320, 347). The underlying diseases in these cases were acute leukemia ($n = 7$), non-Hodgkin's lymphoma with renal transplantation (347), and aplastic anemia ($n = 1$) (115). The most common affected sites during dissemination were the lungs (100%), brain (67%), kidney (67%), liver (56%), cardiovascular system (33%), spleen (33%), skin (33%), sinus (22%), thyroid (22%), gastrointestinal tract (22%), pancreas (11%), and bone marrow (11%). The origin of disseminated infection was judged to be a pulmonary (115, 213, 308, 320, 347) or cutaneous (106, 173) infection. All but two patients (106, 115) with disseminated *R. pusillus* infections died of their infections (mortality rate, 78%).

Similar to the case with *C. bertholletiae*, fever was the most common nonspecific sign of disseminated *R. pusillus* infection (89% of cases) (115, 173, 213, 308, 320, 347). Also, all of the patients with reported disseminated *R. pusillus* infection had abnormal chest X-rays. Hemoptysis is a relatively common (33%) clinical sign in disseminated infection with pulmonary involvement, ranging from blood-tinged sputum to massive fatal hemoptysis (308, 320). Typically, disseminated *R. pusillus* infection patients had other clinical signs or radiographic findings suggestive of disseminated infection, including cutaneous necrotic lesions (106, 173), indurated ecchymotic nodules (213), and abnormal head CT (320) or MRI (106) scans.

(iii) Soft tissue infections and osteomyelitis. Similar to other species, *R. pusillus* has caused severe health care-associated infections at needle insertion sites (362), catheter insertion sites (195), and areas of contact with paper adhesive tape used to secure i.v. catheters (294). Infections restricted to soft tissues (necrotizing fasciitis or cellulitis), both with (294) and without (195, 362) contiguous osteomyelitis, generally have an excellent prognosis (100% survival rate), provided that the underlying predisposing factor is controlled and the tissue is surgically debrided with administration of systemic antifungal therapy (195, 294, 362). However, cutaneous infections that resulted in disseminated infections, including those originating at the site of i.v. cannulation (106), have been fatal in patients with leukemia (106, 173). Therefore, *R. pusillus*, like other Mucormycetes, should be considered in the differential diagnosis of infections at catheter and injection sites in immunocompromised patients, especially if their infections are not responsive to antibacterials and quickly evolve to necrosis. Soft tissue infection also can result from other primary sources, such as lung infections that disseminate to the skin (213).

A chronic cutaneous infection caused by a *Rhizomucor* species within a 6-month period of progression after skin trauma was described for an immunocompromised patient who recovered after complete surgical excision of an infection-related lesion only (22). Chronic progression (3 months to 10 years) of cutaneous infection is characteristic of *R. variabilis* infection, which was described in eight reported cases in studies in China and Japan (196, 328, 372). In six of these cases, the infection occurred after trauma (196, 328). Because no authors have reported chronic cutaneous infections caused by *R. pusillus*, *Rhizomucor* infections described in some case reports from Spain may have been caused by one of the varieties of *R. variabilis* (22), which usually preferentially affects immunocom-

petent individuals (196, 372) but also affects immunocompromised hosts (3, 328).

(iv) Rhino-orbito-cerebral infection. Rhinofacial (83) and rhino-orbito-facial (87) *R. pusillus* infections were reported for an 11-year-old boy with acute leukemia (83) and a 38-year-old woman with diabetic ketoacidosis (87), respectively. The first patient recovered with the use of i.v. AmB alone (83), whereas the second recovered with extensive and repetitive surgical procedures, i.v. administration and local application of L-AmB, and strict control of diabetes (87). *R. pusillus* infection may also initially appear as a sino-orbital infection that rapidly invades the brain in patients with hematological malignancies. Iwen et al. (143) described a relentlessly progressive case of *R. pusillus* sino-orbital infection that was ultimately fatal despite repeated extensive surgical resection and i.v. and local use of AmB lipid complex and GM-CSF (143).

(v) Cerebral infection. Isolated cerebral mucormycosis is a rarely reported life-threatening infection (121, 123, 136, 346). It is linked primarily with i.v. drug abuse but has also been described for other immunocompromised individuals, such as those with diabetes mellitus, hematological malignancies, AIDS, liver cirrhosis, and autoimmune diseases treated with immunosuppressive drugs (121, 123, 136, 346). It was also reported in an apparently healthy patient without involvement of other organs at autopsy (346). Injection of contaminated amphetamine solutions was associated with infection in 4 of 25 patients in a case series of cerebral mucormycosis in i.v. drug abusers (136); basal ganglia were involved in the majority of these cases (136). *Rhizopus* and *Mucor* spp. were identified as infecting pathogens in seven and two of these cases, respectively (136). A *Rhizomucor* species was also identified in a nonimmunocompromised 24-year-old man who had a 2-day history of headache, confusion, and left hemiparesis caused by an ultimately fatal basal ganglion infection related to i.v. administration of a single dose of an amphetamine in the week before the initial symptoms of the infection and hospital admission (248). Hematogenous spread has been suggested as a route of infection because of initial infection of a deep cerebral site without a rhino-orbital focus (346). The presence of basal ganglion lesions in i.v. drug abusers, regardless of human immunodeficiency virus status, should suggest mucormycosis in the differential diagnosis (136).

(vi) Intra-abdominal infection. Busca et al. reported liver abscesses caused by *R. pusillus*, with extension of the infection to the stomach, duodenum, and diaphragm, in a 19-year-old boy with relapsed acute myeloid leukemia (45). The patient recovered after wide resection of all affected tissue and prolonged (136 days) treatment with L-AmB, posaconazole (45 days), and deferasirox (243 days), despite the fact that he subsequently underwent hematopoietic stem cell transplantation (HSCT) (45).

(vii) Chronic and recurrent infections. Although they are rare, chronic and recurrent *R. pusillus* infections have been reported. For example, a 76-year-old man with myelofibrosis and myeloid metaplasia who underwent a splenectomy presented with subacute endocarditis of the pulmonary valve and pneumonic process (possibly indicating pulmonary embolization) caused by *R. pusillus* infection, diagnosed postmortem only (92). Also, a 56-year-old man with aplastic anemia who underwent immunosuppressive therapy presented with a pul-

monary *R. pusillus* infection (115). His treatment consisted of lung lesion resection and AmB deoxycholate administration and, later, AmB lipid complex and G-CSF administration and cyclosporine discontinuation (115). About 2 months later, recurrent infection was detected in his kidneys, requiring retreatment with AmB. Although the patient recovered, he experienced renal failure because of prolonged AmB use (115).

(viii) Breakthrough infections. Like all Mucormycetes (168, 333), *R. pusillus* is inherently resistant to fluconazole and voriconazole. Breakthrough disseminated and pulmonary *R. pusillus* infections have been observed in patients with hematological malignancies and in recipients of solid organ transplants receiving voriconazole-based (347) or fluconazole-based (35) prophylaxis.

Diagnosis. Early diagnosis of *R. pusillus* infection often is feasible only in patients with accessible lesions who can tolerate a biopsy, which is required for histopathological identification and culture. Identification of *R. pusillus* is a challenge for clinical laboratories, as has been the case with other uncommon Mucormycetes infections (143, 279, 360). *R. pusillus* has a temperature growth range of 20°C to 60°C (Fig. 3) (279). Morphological (Fig. 3) and biochemical properties help to differentiate *R. pusillus* from other Mucormycetes (279). Mating studies were considered the best studies for morphological identification of Mucormycetes species (143, 279, 360), but they require maintaining a library of testing strains (143, 279, 360). Zygospore production is useful for differentiating *R. pusillus* from *R. miehei*, as the former produces heterothallic zygospores (279, 360). The higher tolerance of *R. miehei* to lovastatin can be useful for differentiation of it from other species (198), but its reliability in differentiating *Rhizomucor* from other genera is unknown (143). DNA sequencing to compare the sequence to those of known type strains in international databases is currently considered the best way to identify and classify Mucormycetes species (13, 68, 72, 78, 143, 341, 342, 351). PCR and restriction fragment length polymorphism or other molecular methods have been used for *R. pusillus* identification in culture and tissue (13, 45, 78, 125, 143, 149, 168, 351), and these techniques may be more rapid and reliable than standard mycological identification (25, 72).

In vitro susceptibility studies of Mucormycetes often do not include *Rhizomucor* spp. among the representative strains for testing or differentiate *Rhizomucor* beyond the genus level (11, 75, 76, 93–95, 118, 119, 183, 257, 258, 321, 330). Realizing that there are no established susceptibility breakpoints for Mucormycetes, among studies that tested clinical *R. pusillus* isolates ($n = 25$) (6, 82, 101, 111, 157, 163, 191, 312, 320, 331), relatively low MICs ($<1 \mu\text{g/ml}$) were reported for AmB (20 strains), terbinafine (7 strains), posaconazole (7 strains), nystatin (3 strains), fluvastatin (1 strain), and simvastatin (1 strain) (5, 35, 82, 101, 111, 157, 163, 312, 320, 331). Itraconazole had low MICs ($<1 \mu\text{g/ml}$) in 70% (14/20 strains) of tested strains (6, 35, 82, 111, 157, 163, 312, 320, 331). A synergistic *in vitro* effect of the combination of terbinafine and itraconazole on two strains was observed (111).

Management and prognosis. In published case reports, the overall mortality rate for *Rhizomucor* infections (46%) is significantly lower than that for *C. bertholletiae* infections (77%) (Table 4). Three patients did not receive any antifungal therapy because their infections were diagnosed postmortem only

(92, 173, 213). The small number and heterogeneity of treatment scenarios preclude generalization of optimal strategies for treating these infections. Among 18 patients with *R. pusillus* infection who received antifungal drugs, 11 (61%) survived (35, 45, 83, 87, 106, 115, 195, 197, 200, 294, 362). Nearly all of these patients received AmB and/or lipid formulations of it either alone or in sequence and/or combination with other antifungals ($n = 16$). With the caveats described above, surgical resection in combination with systemic antifungal therapy improved outcomes in six (35, 45, 87, 115, 195, 294) of nine patients (67%) whose infections were deemed suitable for such an aggressive approach (35, 45, 87, 115, 143, 195, 294, 320). Three of these six patients (50%) received G-CSF (35, 115) or granulocyte transfusions (294); another patient received deferasirox (45), and the remaining two patients had diabetes mellitus with cutaneous (195) and rhino-orbito-facial (87) infections. Four of five patients (80%) who received G-CSF or granulocyte transfusions in addition to antifungals (200) or antifungals plus surgery (35, 115, 143, 294) survived (35, 115, 200, 294). In contrast, among eight patients who received antifungals alone, only four (50%) survived (83, 106, 197, 362). Prolonged or suppressive use of antifungals may be necessary to prevent recurrent infection, especially in patients with neutropenia (45, 115, 200).

Apophysomyces elegans Complex

Taxonomy. As described recently, *Apophysomyces elegans* is considered part of a complex of species that includes three other newly proposed species—*Apophysomyces ossiformis*, *Apophysomyces trapeziformis*, and *Apophysomyces variabilis*—with genetic, physiological, and morphological differences (12). Thus, *Apophysomyces elegans* is actually split into four species that have been isolated from the environment or from human infections (12, 215, 279, 363). Therefore, in this review, *Apophysomyces elegans* is referred to as a complex of species. However, further molecular taxonomic studies are necessary to better understand the relative distribution of *Apophysomyces* species in human infections and whether they have subtle differences in epidemiology, clinical presentation, antifungal susceptibility, and prognosis.

Reported cases and epidemiology. *Apophysomyces elegans* was first isolated in 1979 from soil samples in a mango orchard in northern India (215). It has thermophilic characteristics (grows at temperatures above 37°C and grows rapidly at 42°C) (70, 158) and a widespread distribution in the soil in warm climates (103). Also, it was isolated from soil and air filter dust samples in Australia in association with human infections (70, 307). It is distributed in tropical and subtropical climates, with cases reported in India (49%), the United States (32%), Australia (7%), Mexico (3%), Sri Lanka (1%), Thailand (1%), Kuwait (1%), Central America (3%), and South America (3%) (Fig. 4).

The first case of human *Apophysomyces elegans* infection was reported in the United States, in Arizona, in 1985 (363). Over the past few decades, mucormycosis caused by *Apophysomyces elegans* has emerged as an important disease affecting primarily immunocompetent hosts, especially following trauma (Table 2). However, despite the fact that it is ubiquitous in the environment, *Apophysomyces elegans* is considered a rare patho-

gen. The largest case series of *Apophysomyces elegans* infections was reported from a single institution in India by Chakrabarti et al. (55). A lack of awareness about fungal infections in most centers in developing countries probably contributes to underestimation of its importance (55). The most common underlying immunosuppressive conditions predisposing patients to *Apophysomyces elegans* infections include diabetes mellitus (36, 55, 56, 64, 99, 116, 158, 187, 190, 221, 246, 275, 363), organ transplantation (8, 221), alcoholic cirrhosis (157, 355), and idiopathic myelofibrosis (56).

The recently described species *A. variabilis* was identified morphologically and molecularly as the infecting pathogen in five Indian patients with primary cutaneous mucormycosis, all of whom presented with necrotizing fasciitis or gangrene (64, 117a). This small series had a higher mortality rate (80%) than those in previous Indian case series for this infection (55, 117a).

Percutaneous inoculation of the pathogen after trauma is the most common mode of *Apophysomyces elegans* infection acquisition. Of 74 well-documented cases of *Apophysomyces elegans* infections, almost half (49%) developed secondary to trauma (Table 2), including motor vehicle accidents ($n = 15$ [50%]), contamination of burn wounds ($n = 2$), and inoculation via insect stings ($n = 2$) or a spider bite ($n = 1$) (Table 2). Soft tissue infections and necrotizing fasciitis caused by *Apophysomyces elegans* have also been described for immunocompetent victims of natural disasters, such as tsunamis (19, 315). Health care-associated *Apophysomyces elegans* infections were reported for 11 patients following surgery ($n = 4$) (8, 178, 205), intramuscular or subcutaneous injections ($n = 5$) (55, 58, 64), and skin tests using snapdragon flowers ($n = 2$) (36, 187). *Apophysomyces elegans* contamination of a plaster cast applied to a fractured arm was considered a source of cutaneous infection in one case (64).

The fungal inoculation source and predisposing condition for *Apophysomyces elegans* are occasionally unknown (Table 2) (55, 56, 144, 184, 327). Among cases with unknown or undescribed ($n = 12$) or no ($n = 12$) predisposing factors (Table 2), and excluding cases with underlying conditions ($n = 5$) (55, 56, 117a, 246, 307), 8 (40%) were rhino-orbital infections where the acquisition was likely related to spore inhalation (55, 304, 318, 322). Therefore, in 11 (15%) previously healthy patients who developed soft tissue infection ($n = 5$) (55, 144, 246), osteomyelitis and arthritis ($n = 1$) (212), or kidney ($n = 4$) (55, 184, 204, 327) or intra-abdominal infection with kidney involvement ($n = 1$) (55) caused by *Apophysomyces elegans*, no predisposing factor was detected. *Apophysomyces elegans* is believed to be incapable of penetrating intact skin (64), but trauma without visible breakage of skin integrity was deemed responsible for *Apophysomyces elegans* osteomyelitis of the sternum that appeared clinically 2 months later in a previously healthy individual (88). Thus, unnoticed trauma may predispose individuals to *Apophysomyces elegans* infections.

Pathogenesis. *Apophysomyces elegans* infections typically develop quickly after inoculation. Vascular invasion frequently causes thrombosis, leading to ischemic tissue necrosis; nerve invasion also occurs (50). *Apophysomyces elegans* infection rapidly progresses to necrosis, typically within days after inoculation, which may be explained by rapid growth of the organism in blood vessels (56). Tissue necrosis has been observed clini-

cally and/or histologically in a large percentage of all *Apophysomyces elegans* infections (60/74 infections [81%]), confirming the high pathogenicity of Mucorales species when they are inoculated.

No specific virulence factors have been identified for *Apophysomyces elegans* (279). However, one study indicated that a 250- to 2,300-fold lower inoculum of *Apophysomyces elegans* spores was required to cause equivalent mortality in animals compared to those for *Rhizopus microsporus* and *Lichtheimia corymbifera* (74, 77). *Apophysomyces elegans* sporangiospores are larger (4.0 to 5.7 $\mu\text{m} \times$ 5.4 to 8 μm) than those of other unusual Mucormycetes (279) but can easily impact the upper respiratory tract.

Clinical presentation. (i) **Soft tissue infection and osteomyelitis.** The most common sites of *Apophysomyces elegans* infections have included cutaneous and subcutaneous (53%) sites (Table 3) in both previously immunocompetent (25/51 infections [49%]) (19, 47, 58, 64, 86, 88, 139, 144, 170, 178, 205, 212, 223, 246, 291, 315, 358, 367) and immunocompromised (11/20 infections [55%]) (36, 50, 55, 64, 117a, 157, 158, 187, 221, 246, 275, 363) individuals. Local invasion resulting in necrotizing soft tissue infections has been a common feature (33/40 infections [83%]) (19, 36, 47, 50, 58, 64, 70, 86, 117a, 139, 144, 157, 158, 170, 178, 187, 205, 221, 223, 246, 275, 291, 298, 315, 358, 363), with progression to necrotizing fasciitis or gangrene occurring in a large proportion of these cases (26/33 infections [79%]) (36, 64, 117a, 246, 275, 298, 363). Contrary to common belief, only six patients (23%) with these severe manifestations of soft tissue *Apophysomyces elegans* infection (necrotizing fasciitis sometimes extending to muscles) had underlying immunocompromised states, such as diabetes mellitus or renal failure, or were pregnant (36, 50, 64, 117a, 275, 363). Rupture of the femoral artery as a complication of soft tissue *Apophysomyces elegans* infection was described for a previously healthy male patient who recovered after insertion of a Fogarty catheter and surgical repair of the artery (47). Osteomyelitis secondary to trauma or a contiguous soft tissue infection (excluding cases of rhino-orbito-cerebral infection) occurred in four previously immunocompetent patients (88, 139, 212, 358), and treatment without radical bone resection (88) or even limb amputation (212) was difficult in half of these cases. Primary cutaneous *Apophysomyces elegans* infections with dissemination to other organs and tissues have been reported (44, 55, 208, 234, 246, 355) and have been likely in other cases (158, 298).

Cutaneous infections caused by *Apophysomyces elegans* are characterized by pain, erythema, and swelling or induration, sometimes with vesicles, pus discharge from an abscess or the sinuses, and formation of an ulcer with various degrees of necrosis (58, 70, 187, 221, 275, 298, 358, 363). Fever has been described in several cases (70, 170, 187, 223, 358, 363). In some cases, cotton-like, fine white fluffy material with a woolly appearance or a white cottony filamentous structure covering a wound base has also been observed (47, 58, 170, 223, 291, 298, 355). Although *Apophysomyces elegans* infections may occur in any region of the body, the extremities, abdominal wall, and perineum are the most common sites (47, 70, 144, 221, 223, 291, 298, 363).

Excluding eight reported cases of *Apophysomyces elegans* infection without information on immune status or outcome,

unlike other rare Mucorales spp., the mortality rate for localized (mycutaneous or osseous) *Apophysomyces elegans* infections did not seem to differ in previously immunocompromised (4/11 infections [36%]) (50, 55, 64, 117a, 157, 158, 187, 221, 246, 275, 363) and immunocompetent (6/21 infections [29%]) (19, 36, 47, 55, 64, 86, 88, 139, 170, 178, 205, 212, 223, 246, 291, 358, 367) patients.

(ii) **Rhino-orbito-cerebral infection.** Unlike rhino-orbital-cerebral infections caused by the more common genera in the Mucoraceae family (*Rhizopus*, *Mucor*, and *Lichtheimia*) and *C. bertholletiae*, those caused by *Apophysomyces elegans* appear to occur primarily in immunocompetent patients. Nineteen cases of rhino-orbital or rhino-orbital-cerebral infection caused by *Apophysomyces elegans* in immunocompetent patients ($n = 16$) (43, 55, 97, 103, 268, 304, 307, 318, 322) or patients with (56, 116) or without (controlled diabetes mellitus) (99, 190) severe immunosuppression have been described. Four cases followed head trauma and were probably related to direct inoculation of the fungus via the resulting wounds (97, 99, 103, 268). Chronic sinusitis was likely a facilitating condition in some of these cases (43, 56, 190, 307). Therefore, *Apophysomyces elegans* should be suspected for any immunocompetent patients in whom a rhino-orbital infection develops, regardless of previous traumatic injuries or chronic sinusitis.

The clinical and radiological manifestations of rhino-orbital-cerebral infections caused by *Apophysomyces elegans* do not differ from those caused by other Mucormycetes (190), although the frequency of *Apophysomyces elegans* infection in patients with serious underlying disorders (e.g., myelofibrosis, diabetes mellitus, and chronic sinusitis) (56) or uncontrolled diabetes mellitus (116) has been comparatively low (2/19 infections [11%]). Nevertheless, the mortality rate for rhino-orbito-cerebral *Apophysomyces elegans* mucormycosis affecting more severely immunocompromised patients was reported to be 100% (56, 116); these patients' infections did not respond to AmB or aggressive surgical procedures (56, 116) such as orbital exenteration and extensive debridement (56). Additionally, although the mortality rate in hosts who were immunocompetent or relatively less immunosuppressed was comparatively low (2/17 cases [12%]) (304, 322), residual sequelae of the infection were often severe (14/15 cases [93%]) (55, 97, 99, 103, 190, 268, 307, 318, 322).

Oto-cervico-facial *Apophysomyces elegans* infection involving salivary glands and rhino-orbito-cerebral infection of otogenic origin were described for two patients. The first patient was diabetic and had a painful case of otitis externa after cleaning his left ear canal with a wooden matchstick that rapidly (10 days) progressed to an extensive, ultimately fatal infection (322). The second patient had an extensive infection after an insect that probably stung his auditory canal; he subsequently required extensive surgical debridement and resection followed by i.v. L-AmB to control the infection (116).

(iii) **Disseminated infection.** Disseminated *Apophysomyces elegans* infection has been reported for eight individuals (8, 44, 55, 184, 208, 234, 246, 355), 63% of whom died despite receiving aggressive treatment (8, 246, 355). Disseminated *Apophysomyces elegans* infections are somewhat unique in that almost all of the reported cases developed in patients following a primary cutaneous or subcutaneous infection resulting from trauma (44, 55, 208, 234, 246, 355). Also, Alexander and col-

leagues described a case of hematogenous spread of *Apophysomyces elegans* infection and direct extension of it from an infected renal allograft harvested from a victim in a motor vehicle accident who nearly drowned before death (8). Hematogenous dissemination typically involves the kidney (72%) (208, 234) and spleen (43%) (8, 44, 55), as well as other organs and tissues (8, 246, 355). Only three patients (38%) with disseminated *Apophysomyces elegans* infection have been reported to be immunocompromised, with one having diabetes mellitus (246), one having alcoholic cirrhosis (355), and one having a kidney transplant (8); all of these patients died.

(iv) Renal infection. Isolated renal mucormycosis caused by Mucormycetes has rarely been reported (54, 287). Isolated renal *Apophysomyces elegans* infections without any apparent predisposing factors were reported for three previously healthy individuals (55, 204, 327) and one patient with chronic alcoholism (55). The route of infection in renal tissue is not known, but ureter involvement was reported for two of these patients (204, 327), whereas contiguous spread from the abdomen was suspected in another case (55). These patients underwent successful treatment with AmB alone (204), nephrectomy (327), and/or drainage of the renal abscess guided by ultrasound (55).

Besides renal involvement via hematogenous or contiguous spread, involvement via an ascending route through the urinary tract was reported for an immunocompetent 56-year-old man by Lawrence et al. (184), in 1986. The infection had an acute onset, and pathological description revealed the presence of broad, nonseptate hyphae in a bladder lesion and septic embolic infarcts in the left kidney, suggesting the ascending route of infection. The patient received successful treatment with a left nephrectomy, repeated drainage of a left flank abscess, drainage of a tibial lytic lesion, and two courses of AmB (184).

(v) Intra-abdominal infection. Intra-abdominal *Apophysomyces elegans* infections are believed to develop via direct extension from soft tissue infections following trauma (such as a motor vehicle accident) to exposed intra-abdominal organs and tissues, including the kidneys, pancreas, and mesentery (157), or after transplantation of a likely infected organ (8). Also, a kidney and the retroperitoneal area were reported to be affected in a 70-year-old man with no underlying condition and unknown predisposing factors (55). Only one patient with intra-abdominal *Apophysomyces elegans* infection is reported to have survived (8).

(vi) Subacute or chronic infection. Although most *Apophysomyces elegans* infections have an acute onset and progression, subacute and chronic soft tissue, rhino-orbital-cerebral, and renal infections have been reported.

A chronic soft tissue *Apophysomyces elegans* infection was reported for a diabetic patient who was in an automobile accident but did not have a penetrating injury (275). A painful cutaneous ulcer subsequently developed in the patient. One month later, erythematous, indurated swelling occurred, resulting in a blister, a thick hemorrhagic crust, and surrounding necrotic tissue with regional lymphadenopathy. After excision of this lesion, the infection evolved into a necrotizing infection that extended to the quadriceps muscle, requiring radical debridement (275).

An ultimately fatal case of chronic rhino-orbital-cerebral *Apophysomyces elegans* infection was reported for a male 31-

year-old Indian farm laborer without other predisposing conditions. The infection started with right ocular discomfort and redness and occasional headaches 4 weeks before he sought medical attention (304). In another report, for three otherwise healthy individuals with rhino-orbital *Apophysomyces elegans* infection who underwent successful surgery and treatment with AmB, the duration of symptoms ranged from 1 to 2 months (318).

Chronic upper unilateral ($n = 1$) (327) and bilateral ($n = 3$) (55, 204) renal *Apophysomyces elegans* infections, sometimes also involving the ureter ($n = 2$) (204, 327), were reported in three previously healthy patients (55, 204, 327) and a chronically alcoholic patient (55) without any other predisposing conditions. Flank pain (55, 204, 327), dysuria (55), white flakes in urine or pyuria (55, 204, 327), high fever (204), and vomiting (204) were the symptoms and signs of these infections.

It seems that species in the *Apophysomyces elegans* complex may have some differences in virulence (117a) and pathogenicity (e.g., tropism for renal tissue). Furthermore, differences in outcome of acute versus subacute and chronic *Apophysomyces elegans* infections may be related to the mode of infection (open versus closed trauma) or inoculum load.

Diagnosis. *Apophysomyces elegans* should be considered the cause of soft tissue infections after any kind of trauma in otherwise healthy patients, especially for wound infections that are progressively necrotic despite antibacterial-based treatment and debridement.

Histopathological examination of the debrided tissue (including that of frozen sections, if available) or biopsy analysis of lesion edges is the most rapid method of early diagnosis of mucormycosis. It should be performed in addition to culture analysis to establish the etiology of the infection. *Apophysomyces elegans* usually grows quickly but does not sporulate easily on mycological primary isolation medium and subsequent subcultures (279). It requires low-nutrient stress conditions for promotion of sporulation, such as use of Czapek-Dox agar or water agar (239, 279). *Apophysomyces elegans* can be differentiated according to the morphology of its sporangia and the nature of sporangiophore formation (Fig. 3). Microscopically, *Apophysomyces elegans* shows similarities to *Lichtheimia* (formerly *Absidia*) species, as they all have prominent apophyses and pyriform (pear-shaped) sporangia (116, 158). The characteristic appearance of *Apophysomyces elegans* consists of unbranched, subhyaline, thin- and smooth-walled sporangiophores along with funnel- and/or bell-shaped apophyses (12, 70, 88, 116). Characteristic darkening and thickening of sporangiophore walls below apophyses that narrow sporangiophore lumina differentiate *Apophysomyces* from similar genera (64). DNA-based methods have been used to distinguish *Apophysomyces elegans* from other Mucormycetes (55). Exoantigen tests for identification of strains of *Apophysomyces elegans* and *S. vasiformis* (194) are no longer available and have been supplanted by DNA sequencing.

Management. As with other Mucormycetes infections, treatment of *Apophysomyces elegans* infections requires several simultaneous approaches. Surgical intervention, antifungal-based therapy, and correction of the underlying predisposing factors are some of the multipronged management modalities. Hyperbaric oxygen therapy also has been used as adjunct therapy, but evidence of its effectiveness remains limited considering that patients

also underwent surgical interventions (19, 103, 315, 332).

In vitro susceptibility tests of *Apophysomyces elegans* strains showed MICs of no more than 1 µg/ml for AmB and posaconazole for 83% (24/29 strains) and 70% (16/23 strains) of the tested strains, respectively (11, 12, 74, 75, 76, 321), although no breakpoints for susceptibility testing were defined. *Apophysomyces elegans* strains with a more resistant profile ($n = 18$) were recently described, as the MIC₅₀ and MIC₉₀ of AmB were 2 and 4 µg/ml, respectively; 100% of these strains had posaconazole MICs of ≤1 µg/ml (57). Importantly, clinical correlation was demonstrated in this retrospective study, as all patients with AmB MICs of <1 µg/ml recovered, whereas 43% of patients infected with more resistant strains (MICs of ≥1 µg/ml) died (57). Itraconazole ($n = 43$), isavuconazole ($n = 18$), and ravuconazole ($n = 16$) had variable activity *in vitro* (11, 12, 57, 74, 76, 321). Caspofungin, anidulafungin, and voriconazole were inactive against 34 tested strains of *Apophysomyces elegans* complex species (12, 57).

Prognosis. Excluding five patients whose outcomes were not described, the overall mortality rate for *Apophysomyces elegans* infections among reported cases appeared to be lower than that for *C. bertholletiae* infections (Table 4). However, almost half of the survivors of *Apophysomyces elegans* infections (23/48 patients [48%]) had considerable physical defects as a result of extensive debridement, amputation, or organ resection (44, 55, 70, 88, 97, 99, 103, 184, 190, 212, 223, 268, 307, 318, 322, 327, 363). Considering that most of these individuals were previously healthy, the burden caused by *Apophysomyces elegans* infection is considerable.

Saksenaia vasiformis complex

Taxonomy and reported cases. *Saksenaia vasiformis* is generally considered the only species in the family Saksenaaceae (279). Nevertheless, the *Apophysomyces elegans* complex was recently included in this family, with strong phylogenetic support (352; <http://Zygomycetes.org/index.php?id=49>) (Fig. 1). In addition, it has been demonstrated, based on molecular, morphological, and physiological characteristics, that *S. vasiformis* is a complex of species that include at least two new species: *Saksenaia oblongispora* and *Saksenaia erythrospora* (14). Therefore, *S. vasiformis* is referred to herein as a complex of species.

The number of reported infections caused by *S. vasiformis* has been small, but these infections probably have been underreported, as this species, like *Apophysomyces elegans*, does not sporulate well in routine mycological media (134, 279). Consequently, the number of *S. vasiformis* infection cases reported in the literature underrepresents the actual occurrence (Table 2) (279).

Epidemiology. *S. vasiformis* is an emerging Mucormycetes with worldwide distribution that is acquired via contact with soil. It was first isolated in 1953 from soil in India (295) and has been isolated from soil samples in Brazil, Honduras, Israel, Panama, and the United States (14, 90, 91, 134, 279). The ecology of *S. vasiformis* is not well known, and thus far, it has been found in soil and causing infection in human and veterinary patients (4, 91, 104, 132, 285). *S. vasiformis* and *Apophysomyces elegans* have been reported as causes of death in dolphins, and *S. vasiformis* caused

cranial mucormycosis in a cow (132, 285). Like the case for *Apophysomyces elegans*, human *S. vasiformis* infections occur primarily in tropical and subtropical climates (Fig. 4) (279).

S. vasiformis infections occur most often after trauma (Table 2), including motor vehicle accidents (4, 81, 100, 162), insect or spider bites, scorpion stings, bird pecks, tattoos, burns, and nosocomial exposures or health care-associated exposure via intramuscular injections, needle sticks, and vascular catheter and surgery sites (29, 58, 64, 110, 134, 185, 230, 240, 241, 250, 319, 334, 343). Similar to the case with *Apophysomyces elegans*, soil contamination of the trauma site is the probable cause of *S. vasiformis* infection in most patients (279). Water contamination via a cutaneous laceration while swimming is a potential source of *S. vasiformis* infection (319). Inhalation of spores into the sinuses and direct inoculation of contaminated soil into facial wounds or the sinuses are likely modes of infection (4, 81, 279). Primary pneumonia with bloodstream dissemination may also occur in patients with *S. vasiformis* infection (316). The size of *S. vasiformis* spores ranges from 1.2 to 1.4 by 2.8 to 4.2 µm (279), making them capable of reaching the alveoli when inhaled. Importantly, in a third of the cases reported thus far, no predisposing factors were identified (Table 2) (1, 26, 27, 29, 37, 48, 58, 90, 127, 134, 150, 266, 316, 329).

More than 80% of *S. vasiformis* infection cases have been reported for previously healthy or nonimmunocompromised individuals. In immunocompromised hosts, the most common underlying conditions are leukemia and other hematological diseases, solid neoplasms, splenectomy, uncontrolled diabetes, and treatment with adrenal corticosteroids (29, 48, 58, 90, 104, 326, 329). Therefore, *S. vasiformis*, like *Apophysomyces elegans*, is different from the typical opportunistic Mucormycetes because it affects mainly nonimmunocompromised patients (279).

Pathogenesis. As with other causes of mucormycosis, *S. vasiformis* infection usually is characterized by angioinvasion and tissue necrosis (37, 104, 279, 366).

Clinical presentation. Since it was first described as a cause of infection in humans by Ajello et al. (4), in 1976, *S. vasiformis* has increasingly been reported as a cause of localized cutaneous and subcutaneous infections, but only rarely as a cause of rhino-orbito-cerebral, disseminated, and renal infections (Table 3). Observing the clinical descriptions of *S. vasiformis* infection cases presented below, the spectrum of *S. vasiformis* infections apparently ranges from rapidly progressive localized infections and less frequent disseminated infections to a disease of slow onset and limited spread.

(i) Soft tissue infection. Necrotizing fasciitis or cellulitis (29, 37, 51, 58, 64, 107, 162, 171, 185, 230, 241, 253, 319, 366) extending rapidly to neighboring tissues (29, 37, 51, 58, 64, 107, 162, 185, 253, 319, 366) is the most common characteristic of soft tissue *S. vasiformis* infection. Abscess formation with fat necrosis has also been described (266, 326, 366), with histological evidence of satellite lesions in one of these cases (366). In most of the reported cases, the infection was localized and responded favorably to aggressive debridement and antifungal therapy (Tables 3 and 4) (29, 37, 58, 171, 185, 253, 266, 319, 326, 343, 366). However, amputation (51, 240, 366) and fatal progression despite treatment (with AmB alone or L-AmB and posaconazole) and extensive daily surgical debridement (162) have been described, occasionally associated with superim-

posed bacterial infections (64). Only three cases of *S. vasiformis* infections restricted to soft tissues have been reported in previously relatively immunocompromised patients, specifically, two individuals with diabetes mellitus (29, 58) and one who had thalassemia and underwent splenectomy (326).

(ii) Chronic soft tissue infection and osteomyelitis. Chronic primary cutaneous or subcutaneous infections caused by *S. vasiformis* have been reported as painless (9), painful (26, 240), and erythematous (9, 240), with swelling (240), papules (199) or nodules (9, 26), and small satellite lesions (9, 199, 240, 250), occasionally forming bullae (240), gradually increasing in size (9, 26, 199, 240), with induration (199, 240, 250), and finally rupturing and discharging a whitish purulent material (9, 26, 240) and forming ulcers (26, 240, 250). Necrosis (250), scars of old healed lesions (9), with (240) or without (9, 250) regional adenopathy, and low-grade fever (240) may occur. Progression to necrotizing fasciitis (26) and formation of a subcutaneous mass extending to muscle without ulceration, necrosis, or lymphadenopathy (199) have also been described. Without diagnosis, lesions caused by *S. vasiformis* infection have progressed over 3 (26), 8 (9, 199), 15 (250), and 18 (240) months.

The majority of chronic soft tissue *S. vasiformis* infections reported in the literature occurred in male patients with no significant past medical histories who began to complain of infection-related symptoms days to months after trauma resulting in sporangiospore inoculation (9, 199, 240). Resolution of the infection was achieved with cauterization of lesions (9), treatment with AmB (250), or slough debridement (26) or resection of all macroscopically involved tissue (199) with treatment with AmB (26, 199). However, one case required amputation (240).

Histopathological analysis of these chronic infections demonstrated mixed purulent (240, 250) and multiple granulomatous (240, 250) masses with central necrosis (240, 250) extending to the muscle (199, 250) and periosteum (240). Tuberculosis was the initial diagnosis in one of these cases, because of a granulomatous histology (240). Hyphal elements compatible with Mucormycetes in foci of suppurative necrosis, granulomas, or small abscesses (240, 250), including vascular invasion (240), were seen. Microscopic examinations of cultures revealed vase-shaped sporangia characteristic of the *S. vasiformis* complex (Fig. 3) in all of these cases (199, 240, 250), confirming the etiological diagnoses.

Chronic osteomyelitis and a soft tissue infection that progressed over 1 year were described for an oil worker with an open fracture of the tibia (261). After multiple radical debridements and treatment with 1.9 g of AmB, drainage of purulent material recurred and cultures from the site of infection continued to yield *S. vasiformis*. The patient recovered only after amputation of his leg below the knee (261).

(iii) Rhino-orbito-cerebral infection. Rhino-orbito-cerebral mucormycosis caused by *S. vasiformis* is clinically indistinguishable from similar infections caused by other Mucormycetes, even though the prognosis for rhino-orbito-cerebral *S. vasiformis* infection appears to be especially poor, with the majority of patients (83%) dying of the infection despite undergoing antifungal-based therapy and surgery (4, 27, 48, 81, 104, 113, 150). Nearly 50% of all reported patients with rhino-orbito-cerebral mucormycosis caused by *S. vasiformis* were diabetics (48, 104) or had a variety of malignancies, such as gastric

adenocarcinoma (104) and ALL (113), which may explain the relatively poorer outcomes for these patients than for those with other clinical forms of *S. vasiformis* infection.

(iv) Disseminated infection. Disseminated *S. vasiformis* infection was fatal in a majority (75%) of published report cases. It caused death in two apparently immunocompetent hosts (127, 316), and one immunocompromised host was diagnosed postmortem only (329). The respiratory tract was a likely route of infection, although cutaneous lesions were initially described for these patients (127, 316, 329). For one patient, infection was assumed to be a consequence of exposure to a heavy airborne inoculum while opal mining underground or orchid farming (316).

Although inhaled glucocorticoids are less likely to cause invasive fungal infections than systemic glucocorticoids (192), bilateral renal *S. vasiformis* infections have been reported for patients who received highly potent inhaled corticosteroids (1, 259, 316). Corticosteroids are known to impair the migration, ingestion, and phagolysosome fusion of bronchoalveolar macrophages, which are essential for clearing sporangiospores from the respiratory mucosa (167, 192).

Dissemination of an *S. vasiformis* infection from necrotizing primary cutaneous disease in the popliteal fossa to inguinal nodes was reported for a previously healthy 11-year-old boy who underwent successful treatment with serial surgical debridements, application of vacuum dressings, and 5 weeks of administration of AmB and then posaconazole (334).

(v) Renal infection. Acute bilateral renal *S. vasiformis* infection suggesting a disseminated route of infection, with extensive acute infarction and no evidence of lung involvement, was diagnosed in a 54-year-old woman who suffered from asthma and used inhaled corticosteroids (1). The patient presented with a 3-day history of fever and right flank pain before hospital admission. A CT scan revealed an enlarged kidney, and angiography showed renal artery occlusions and renal infarction. The patient underwent nephrectomy, which led to a diagnosis of *S. vasiformis* infection. She experienced recovery after treatment with lipid-based AmB and contralateral nephrectomy performed 6 weeks later (1).

Diagnosis. Although *S. vasiformis* usually grows easily in routinely used mycological media, it sporulates well only when it grows on a nutritionally deficient medium or Czapek-Dox agar (14, 26, 91, 279). The features and culture characteristics of *S. vasiformis* that help to differentiate it from the other Mucormycetes were described in detail and illustrated in the review by Ribes et al. (279). Alvarez et al. demonstrated the molecular and morphological characteristics of *S. oblongispora* and *S. erythrospora* that differ from those of *S. vasiformis* (14). In most of the reported cases, sporulation was successfully induced using a distilled water method, although this method may fail occasionally (29). Infection with *S. vasiformis* or *Apophysomyces elegans* should be suspected when a nonsporulating Mucormycetes organism is isolated from an infected lesion (37). In such situations, fungi should be cultured in Czapek-Dox agar or a similar agar to induce sporulation or identified using molecular tools (14, 37). Studies have generally agreed that growth of *S. vasiformis* is faster at 25°C to 37°C and that growth does not occur at 43°C and 50°C (14, 81, 279). This relatively poor thermotolerance of *S. vasiformis* may partially explain the relative rarity of this pathogen in humans.

Management. Because nonsporulating isolates of *S. vasiformis* are fragile, *in vitro* susceptibility testing of antifungal drugs of *S. vasiformis* is rare (162). The posaconazole MIC of 0.5 µg/ml for *S. vasiformis* suggests that this antifungal has clinical utility in patients with these infections (37). In studies examining the *in vitro* activity of various antifungal agents against 66 clinical Mucormycetes isolates, including 5 *S. vasiformis* isolates, *S. vasiformis* was the only species with MICs of posaconazole (4 strains) and itraconazole (5 strains) that were lower than those of AmB (4 strains) (112, 321). Similarly, posaconazole, itraconazole, and terbinafine showed MICs of ≤1 µg/ml for nine *Saksena* sp. strains in another study, while AmB, voriconazole, and echinocandins had poor activity (14). The MICs of AmB observed for *Saksena* spp. were higher than those for *Mucor* spp. (14). These data suggest the usefulness of identification of Mucormycetes to the species level in guiding management of infections (112, 321).

AmB has traditionally been the agent of choice for treatment of *S. vasiformis* infections (26, 27, 37, 319, 343, 366). As with treatment of other Mucormycetes infections, its significant nephrotoxicity often limits its duration and dosage when administered for severe infections (319, 334). Information on the efficacy of posaconazole in treating these infections is scant. Posaconazole has been used as an alternative to AmB in treatment of *S. vasiformis* infections because of the toxicity of AmB (319, 334) or in combination with other antifungals (Table 4) (162). Posaconazole's safety profile for children under the age of 13 years is limited (174, 334).

Prognosis. Not surprisingly, underlying immunosuppression is associated with poor prognosis for *S. vasiformis* infections. About one-third (6/17 patients [35%]) of patients who died of this infection in reported studies were immunocompromised (48, 58, 90, 104, 107, 113, 329), whereas only 12% (3/25 patients) of those who survived had underlying immunocompromised conditions (29, 37, 326). Except for one patient who had renal involvement that required bilateral nephrectomy (1) and another who had osteomyelitis that required amputation, all patients with nonlocalized soft tissue infections (disseminated or rhinocerebral) caused by *S. vasiformis* described thus far died of their infections (27, 48, 104, 113, 127, 150, 316, 329).

Syncephalastrum racemosum

Taxonomy and reported cases. *S. racemosum* is considered the only pathogenic species of the genus *Syncephalastrum*, although three additional taxa have been described (<http://Zygomycetes.org/index.php?id=49>). Until recently, it has been debated whether this fungus is a true pathogen (301) or merely a contaminant or transient colonizer of the human upper respiratory tract (272, 279). The first documented *Syncephalastrum* infection was described as a cutaneous infection that progressed to arteritis in the dermal vessels and contiguous osteomyelitis in a 50-year-old diabetic man who worked in a tea plantation in India, where *Syncephalastrum* spp. had been found in soil (147). The ability of *Syncephalastrum* species to cause ear infections and mycotic keratitis and isolation of these organisms in wound culture are not clear, as reports have not provided details about such cases (238, 324, 345). Also, researchers identified a cluster of eight patients with clinical specimens yielding *Syncephalastrum* isolates after natural di-

asters (272). All of these patients appeared to have transient colonization of *Syncephalastrum* spp. without evidence of infection, even those who were immunosuppressed (272). *S. racemosum* caused onychomycosis in a 45-year-old man who had injured the nail 7 months before (256) and intra-abdominal infection with a large abdominal wound in a previously healthy 23-year-old man who fell and was impaled on a steel reinforced rod (301). Additionally, two otherwise healthy boys in India were reported to have proven or probable chronic subcutaneous *S. racemosum* infections related to trauma that occurred while they were playing in their gardens (Table 2) (271).

Epidemiology. *S. racemosum* is widely distributed in the environment (2, 138, 233, 269, 279, 301). It can be found in both tropical and subtropical areas, particularly at sites rich in decaying organic matter (279). *Syncephalastrum* spp. have been isolated from outdoor air samples collected in Nigeria (233), indoor air samples collected in Austria (269) and England (228), and both outdoor and indoor air samples collected in the United States (273, 310). Like the case for *Cunninghamella* spp., regional and climatic factors have influenced the detection of *Syncephalastrum* species from air (310), and probably the risk of exposure to them. *Syncephalastrum* spp. were the only thermotolerant Mucormycetes detected in 47% of indoor air samples from heavily damaged houses and in none of the mildly damaged houses in the flooded areas of New Orleans after Hurricanes Katrina and Rita (272, 273). Workers in farm operations, particularly those who handle, harvest, and process food and feed after harvest, may be particularly predisposed to exposure to airborne *S. racemosum* (2). Specifically, *S. racemosum* was detected in sorghum dust and wheat hay sites at low frequencies (2) and in water of swimming pools (202) in Egypt and soil in India (147). It was also isolated from settled dust samples in houses free of water damage in the United States (138). Low levels of *S. racemosum* were isolated from air in a bone marrow transplant unit in Austria over a 6-month period (269). The low degree of fungal air contamination may be more important for the risk of infection in profoundly immunocompromised patients than in otherwise healthy individuals (280).

Despite the ubiquitous airborne characteristics of *S. racemosum*, percutaneous inoculation after trauma has been the only likely mode of infection in proven and probable reported cases of infection with this species (256, 271, 301). This suggests low pathogenicity of this fungus or erroneous interpretation of its isolation (considered a contaminant) or no report of cases. Figure 5 shows an unpublished case of rhino-orbital *S. racemosum* infection in a 64-year-old woman with relapsed ALL after allogeneic hematopoietic stem cell transplantation. This patient recovered with extensive debridement, L-AmB treatment, granulocyte transfusions, and G-CSF.

Pathogenesis and clinical presentation. Although *Syncephalastrum* appears to have low pathogenicity (279), it has been shown to colonize immunocompetent individuals after heavy exposure to mold and immunocompromised individuals with minimal or no history of mold exposure after hurricanes (272). Specifically, *S. racemosum* causes chronic infections (a few months to 3 years) following minor trauma (256, 271) and acute infection when inoculated after major trauma (301) in immunocompetent hosts.

Eight days after surgical repair of several visceral lacerations

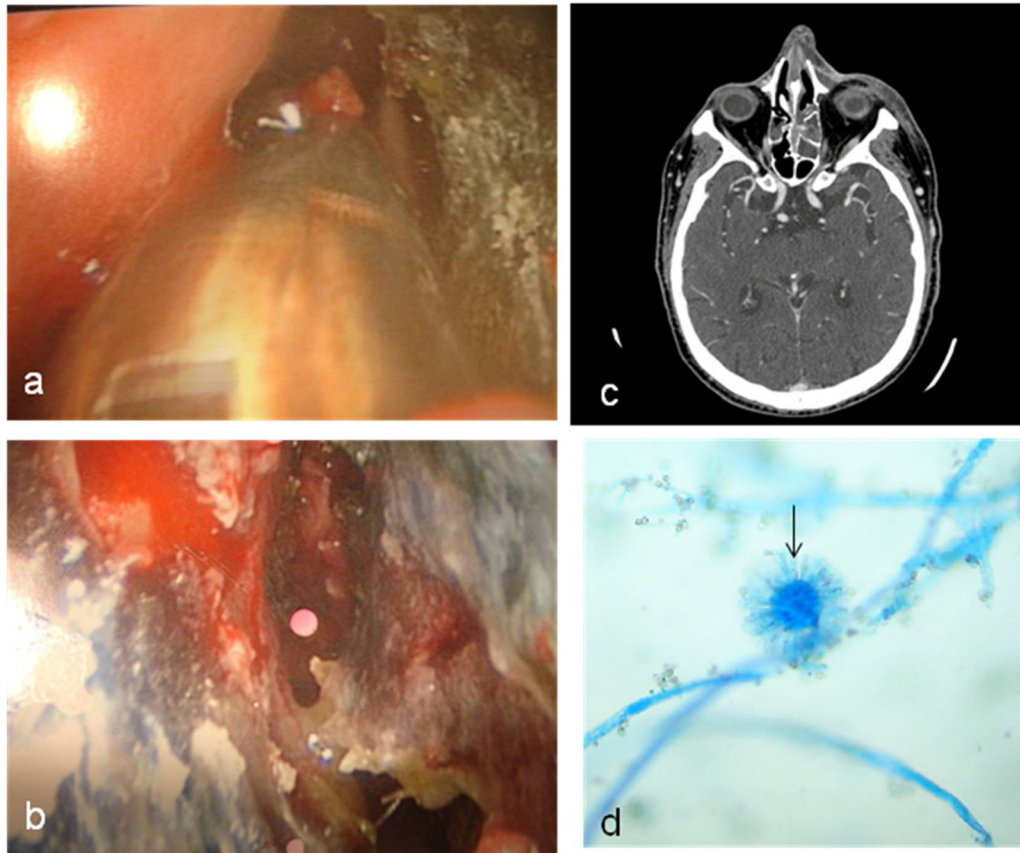


FIG. 5. Rhino-orbital infection caused by *Syncephalastrum racemosum* in a 64-year-old woman with relapsed acute lymphoblastic leukemia after allogeneic hematopoietic stem cell transplantation (unpublished case). (a and b) Nasal endoscopy showing hemorrhagic and necrotic lesions with white cottony growth. (c) Contrast-enhanced CT scan demonstrating ethmoid sinusitis. (d) Lactophenol cotton blue mount preparation showing cylindrical or finger-like projections (arrow) surrounding a swollen vesicle typical of merosporangia of *S. racemosum*. (Courtesy of George M. Viola, reproduced with permission.)

caused by trauma, splenectomy, and the use of temporary mesh interposed in the abdominal wall, the abdomen of a previously healthy 23-year-old man became distended and affected with necrotic skin (301). Later, *S. racemosum* was found to have invaded the abdominal wall, intra-abdominal fluids, and omental and retroperitoneal tissues (301). Histopathological stains of normal tissue sections also showed invasion of this organism (301).

Diagnosis. In culture, *S. racemosum* grows rapidly, and sporulation occurs readily on routine media at room temperature and temperatures above 37°C (279, 301). Regarding identification of *S. racemosum*, confusion with members of the genus *Aspergillus*, especially *Aspergillus niger*, is common (279). Specifically, fruiting bodies of *S. racemosum* and *A. niger* appear to be similar in direct KOH mounts, but the hyphal morphology (aseptate, ribbon-like mycelium) and merosporangial sack surrounding sporangiospores in *Syncephalastrum* cultures are crucial for distinguishing the two fungi (Fig. 3) (279). No molecular biology methods have been used for the diagnosis of *Syncephalastrum* species infections in reported cases (147, 256, 271, 272, 301), although a method based on PCR amplification and sequencing of the high-affinity iron permease 1 gene (*FTRI*) has been used for identification of the genus *Syncephalastrum* (229).

Management. Documented *S. racemosum* infection has been treated successfully using wide debridement of necrotic tissue in the abdominal wall, omentum, and retroperitoneum and with AmB lipid complex for 29 days, including 19 days after the last debridement and 15 days after the last identification of a specimen positive for *S. racemosum* (301). Repeated debridement may be necessary to remove necrotic tissue, and the duration of antifungal therapy depends on the clinical response of the infection (166, 301). The onychomycosis case responded to surgical extirpation and nystatin ointment applied twice daily (b.i.d.) to the exposed nail bed for 2 weeks (256). Chronic subcutaneous cases of *S. racemosum* infection have been treated with topical potassium iodide, and in one case, this was administered in combination with itraconazole (271).

MICs of AmB (four strains), itraconazole (three strains), and nystatin (three strains) have been relatively low ($\leq 1 \mu\text{g/ml}$) for *S. racemosum* (101, 238, 312). Resistance to azoles (posaconazole was not tested), except for itraconazole (three isolates) (238, 279, 312), as well as to caspofungin (two isolates), ciclopiroxolamine (two isolates), amorolfine (two isolates), and naftifine (one isolate) (238, 312), has been reported. The combination of posaconazole and AmB was indifferent to both conidia and hyphae of two clinical *S. racemosum* isolates in testing using a checkerboard method (258).

Cokeromyces recurvatus

Taxonomy and reported cases. *C. recurvatus* is a dimorphic Mucormycetes organism of the order Mucorales and family Thamniaceae that has been isolated only in North America (23, 293, 309), where it can be found in soils and the feces of lizards, certain rodents (23, 226, 279, 293), and occasionally humans (151, 284, 293). *C. recurvatus* has been recovered from peritoneal fluid after viscus perforation secondary to intestinal lymphosarcoma in a cat (226). Only eight cases of human *C. recurvatus* infection (293), probable (23, 270) or possible (15, 210, 219, 335) disease, or colonization (151, 284) have been reported in the literature. The species was first isolated by Shanor et al. (309) in 1950. This fungus has been isolated from vaginal secretions (151, 210, 284), stool (15, 335), urine (23), sputum (293), pleural and peritoneal fluids (219), and fluid from intra-abdominal abscesses (270). Also, yeast-like cells were observed in secretions from six of the patients with possible or probable infection or colonization (15, 23, 151, 270, 284, 335) and from tissue sections in three cases (15, 293, 335). However, histological evidence of *C. recurvatus* infection with invasion of lung tissue by yeast-like cells and pseudohyphae has been described in only one case (293).

One possible case of a *C. recurvatus* infection was in a 14-year-old girl suffering from vaginitis. Culture of the patient's vaginal secretions was concomitantly positive for *Chlamydia*, which was treated with erythromycin, but vaginal swabs obtained 1 and 2 months after initiation of therapy with miconazole continued to recover *C. recurvatus* (210). Follow-up cultures of vaginal secretions 1, 2, and 4 months after a 14-day course of terconazole cream were negative for the fungus, although no further information about the clinical resolution of the vaginitis was provided (210). Another possible case of a *C. recurvatus* infection, this one with a fatal outcome, was described by Munipalli et al. (219). The patient was a 64-year-old man with a history of peptic ulcers and alcohol abuse. The patient was hospitalized for severe abdominal pain and diagnosed with a ruptured duodenal ulcer. Peritoneal fluid obtained intraoperatively on two different occasions and pleural fluid obtained after bilateral pleural effusion developed contained *C. recurvatus* isolates. The patient received a cumulative AmB dose of 1.3 g and antibiotics but died of sepsis associated with multiorgan system failure without a proven bacterial etiology. Despite repeated isolation of the fungus from the fluid specimens, the authors were not able to demonstrate its presence in tissue. In a third possible *C. recurvatus* infection case, a patient experienced diarrhea that may have been caused by graft-versus-host disease, but *C. recurvatus* infection was implicated as the cause of diarrhea because of rapid resolution of the patient's symptoms and subsequent documentation of clearance of the fungus from stool and colonic mucosal biopsy specimens after oral nystatin-based therapy (15, 335).

Patients with probable *C. recurvatus* infections have had repeated fungal cultures positive for this species and responses to specific antifungal-based therapy in the absence of concurrent conditions that can cause similar clinical signs (23, 270). Specifically, a 72-year-old man with a 6-month history of chronic symptomatic hemorrhagic cystitis probably caused by *C. recurvatus* infection had a response to irrigation of the bladder with an antifungal drug (23). Also, a 9-year-old boy

with mixed bacterial peritonitis secondary to a ruptured Meckel diverticulum with cultures positive for *C. recurvatus* received antibiotics and fluconazole and underwent surgical procedures. This patient had recurrent abdominal pain 10 months later, with *C. recurvatus* growing in his peritoneal fluid; he had a recovery with surgery and use of antifungal drugs (AmB and L-AmB in sequential therapy) (270). Therefore, three cases (23, 270, 293) met the criteria of this review for *C. recurvatus* infection.

Epidemiology. Of eight reported cases of *C. recurvatus* infection/colonization, seven patients had an underlying condition that could have increased susceptibility to fungal infection/colonization, consisting of pregnancy (210), diabetes mellitus (151), malignant hematological disease (15, 293, 335), alcoholism with a perforated duodenal ulcer (219), a perforated Meckel diverticulum (270), and bladder diverticula removed via transurethral prostatic surgery in the year prior to symptoms of infection (23). Only one patient had *C. recurvatus* colonization with no described predisposing conditions (284).

The modes of transmission of *C. recurvatus* have yet to be determined, although in symptomatic cases, previous colonization of involved sites, specifically the gastrointestinal (219, 270) and genitourinary (23) tracts, was suspected. Similar to human cases (219, 270), the gastric and small intestinal mucosae of the cat likely were colonized with *C. recurvatus* and could have been the sources of peritoneal infection and/or colonization after viscus rupture (226). Previous disruption of the integrity of the gastrointestinal or genitourinary tract by a perforated Meckel diverticulum (270) or prostatic surgery (23) was implicated in *C. recurvatus* infection. In two asymptomatic cases, large, thick-walled cells bearing multiple buds were noted, and the fungus was also isolated from routine Papanicolaou smears (151, 284), which confirmed the potential for endocervical colonization. Therefore, the likely portals of entry of *C. recurvatus* are the gastrointestinal and genitourinary tracts. Furthermore, microaspiration of gastric contents or inhalation of spores (average sporangiospore size, 2.5 to 4.5 μm) (181) may result in entry of *C. recurvatus* into the lungs (293).

Pathogenesis. The pathogenic potential of *C. recurvatus* in humans has been debated (279, 293). Permissive *C. recurvatus* infection may be facilitated by the production of extracellular mycotoxins (279).

Histopathological lung examination for a 66-year-old hematopoietic stem cell transplant recipient who died of a bilateral *C. recurvatus* infection revealed profuse neutrophil infiltrates and areas of hemorrhage and necrosis but no blood vessel or perineural invasion (293).

Diagnosis. Dimorphism of *C. recurvatus* is dependent on the culture medium, incubation temperature, and degree of anaerobiosis (279). *C. recurvatus* grows as a filamentous fungus at room temperature (279). Figure 3 shows the characteristic morphological features of *C. recurvatus* in culture. The tissue form of *C. recurvatus* is morphologically similar to those of *Coccidioides immitis* and *Paracoccidioides brasiliensis*, and it may be misidentified as either of these organisms in cytological and histopathological specimens (293). For example, in three reported cases, including a veterinary case (226), *C. recurvatus* was initially misinterpreted as *P. brasiliensis* (151) and *C. immitis* (226, 293), highlighting the potential for confusion in identifying these dimorphic pathogenic fungi. The confusion

with *C. immitis* was based on histology and immunohistochemical staining, but immunoperoxidase staining helped to identify *C. recurvatus* (293). In all of these cases, the fungus was identified correctly after sending isolates to reference laboratories. Ramani et al. (270) developed a protocol for differentiating *C. recurvatus* from *P. brasiliensis* according to culture characteristics and microscopic morphology. In addition, yeast forms of *C. recurvatus* can be misinterpreted as *Mucor* spp., including *M. circinelloides* in particular (279, 284).

Limited data describing the susceptibility of *C. recurvatus* to AmB, fluconazole, itraconazole, ketoconazole, and nystatin are available (15, 270). One study found that *C. recurvatus* isolates recovered from stool specimens were susceptible to nystatin *in vitro*, and repeat stool cultures after nystatin-based therapy were negative for fungi (15).

Actinomucor elegans

Taxonomy. The genus *Actinomucor* was first described in 1898 by Schostakowitsch (303) and reevaluated in 1957 by Benjamin and Hesseltine (31, 153, 336). It currently includes one species with three varieties: *Actinomucor elegans* var. *elegans*, *Actinomucor elegans* var. *meitauzae*, and *Actinomucor elegans* var. *kuwaitiensis* (336).

Reported cases, epidemiology, and clinical presentation. *Actinomucor* organisms are known for their association with the production of soy-based products, providing flavor and texture to food (336). *Actinomucor elegans* was also isolated from soil samples after anaerobic incubation in Russia (175).

Only three cases of *Actinomucor elegans* infection/colonization have been reported. The first was described in 2001 for an immunocompetent 11-year-old girl diagnosed with maxillary sinusitis from which *Actinomucor elegans* was isolated (80). This patient underwent surgical cleaning and treatment with AmB. The second case was a diabetic patient who had *Actinomucor elegans* isolated from swabs of a foot ulcer containing necrotic material. The isolate was confirmed to be pathogenic in immunocompetent white mice, with a mortality rate of 100% (153). The third case was a previously healthy 30-year-old man injured by an improvised explosive device in Iraq, in whom a widespread necrotizing soft tissue and disseminated infection developed, requiring repeated debridement (336). *Actinomucor elegans* infection was diagnosed postmortem in this patient (Tables 2, 3, and 4).

Diagnosis and outcome. The first two cases described above had no invasive disease confirmed by histopathology, whereas in the third case the disease was confirmed histologically and was disseminated, with involvement of several organs (lungs, stomach, small and large bowels, liver, spleen, pancreas, adrenal glands, kidneys, prostate, and bladder) (336). Sequencing of the ITS and D1/D2 ribosomal DNA (rDNA) regions of *Actinomucor elegans* was used to confirm the conventional identification in two of these cases (153, 336).

The surface of an *Actinomucor elegans* colony exhibiting the whitish cottony growth typical of Mucormycetes is shown in Fig. 3. Microscopically, the *Actinomucor* species is differentiated from *Mucor* species by branched stolons that give rise to rhizoids and sporangiophores (336). Also, it is differentiated from the other two stoloniferous genera, *Rhizopus* and *Lich-*

theimia (formerly *Absidia*), by the limited growth of its stolons and the arrangement of the collumellae and sporangiophores (153, 336) (Fig. 3).

Antifungal susceptibility tests of a clinical isolate of *Actinomucor elegans* according to Clinical and Laboratory Standards Institute criteria showed MICs of 1 µg/ml for AmB, 0.25 µg/ml for posaconazole, 8 µg/ml for voriconazole, and >32 µg/ml for caspofungin (153).

DISCUSSION

This review demonstrates that the number of reports of infections with unusual members of the phylum Zygomycota, recently distributed among the phylum Glomeromycota and the subphylum Mucoromycotina (131), is increasing (Fig. 6) and that the spectrum of infections is wide (Table 3). These infections have both similarities and subtle differences in epidemiology, pathogenesis, manifestations, diagnosis, and potentially susceptibility to antifungal drugs compared with their most common counterparts (infections with *Rhizopus* and *Mucor* spp.). Classification of the Zygomycota is in continuous flux. The recent placement of *Apophysomyces elegans* in the Saksenaaceae family (Fig. 1) (352; <http://Zygomycetes.org/index.php?id=49>) agrees with the observation that the epidemiology and clinical and laboratory features of *Apophysomyces elegans* are similar to those of *S. vasiformis* but not to those of *C. bertholletiae*, *R. pusillus*, and some other members of the Mucoraceae family (Fig. 1).

Epidemiology

The cumulative evidence does not support easy generalizations of the knowledge on this diverse group of fungi. The environmental microbiological literature provides few clues about the ecological niches in which these unusual fungi are found (38, 280). Because we have an incomplete understanding of how and when individuals are exposed to Mucormycetes in general and to these unusual species in particular, we have no means of preventing these infections.

Our review supports the evidence that these Mucorales organisms are found in soil, water, air, and several organic substrates (202, 279, 319, 356). Infections can occur in the community as well as in hospital environments. Some species, such as those in the *Apophysomyces elegans* complex and the *S. vasiformis* complex, have unique geographic distributions, as infections occur mainly in tropical and subtropical regions in India, the southeastern United States, and Australia; in contrast, infections with *C. bertholletiae* and *R. pusillus* predominate in the United States and Europe and in Japan and Canada, respectively (Fig. 4). The predominance of infections in men (137/189 [73%]) among reported cases of unusual Mucormycetes infections (Table 2) may indicate environmental exposure or a genetic predisposition toward these infections in men.

Epidemiological differences among these unusual agents of mucormycoses are associated with differences in their clinical manifestations. Patients who have mucormycosis in the presence of underlying disease or immunosuppression often have infections caused by species for which spore inhalation is the predominant route of transmission (e.g., *C. bertholletiae* and *R.*

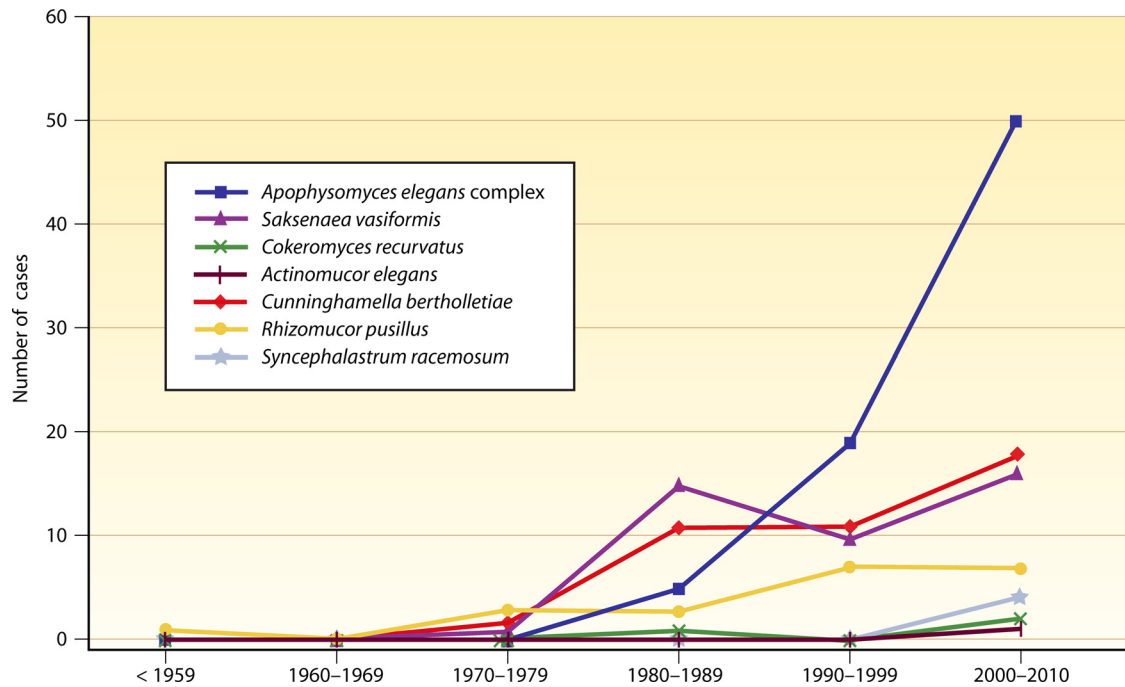


FIG. 6. Reported cases of unusual mucormycosis, according to Medline (searched on 23 December 2010).

pusillus). In these cases, pneumonia and rhino-orbital infections are the primary initial clinical forms. In contrast, immunocompetent individuals are afflicted primarily by Mucormycetes species for which the most common mode of infection is contact with contaminated soil (e.g., *Apophysomyces elegans* and *S. vasiformis*). Cutaneous and subcutaneous infections are the primary clinical forms in these cases.

Pathogenesis

As with the more common Mucormycetes species, almost all of the unusual species can afflict the paranasal sinuses and lungs. *C. bertholletiae* and *R. pusillus* spores may deposit preferentially in the lower respiratory tract and cause infections. In contrast, trauma is the major predisposing factor for *Apophysomyces elegans* complex and *S. vasiformis* infections, where traumatic implantation of fungal elements from contaminated soil is the cause.

The Mucoraceae are not common human colonizers (46, 83) and are believed to be incapable of penetrating intact skin (64). However, previous colonization of the upper respiratory, gastrointestinal, or genitourinary tract may be part of the pathogenic process in Mucormycetes infections. Unknown sources of soft tissue infections caused by *S. vasiformis* and the *Apophysomyces elegans* complex, as well as isolated renal infections caused by *Apophysomyces elegans*, may raise the hypothesis that these species as well as *C. recurvatus* can sporadically reside in the human microbiota before development of the infection. Sites of prior colonization could explain the sites of infection, although several organs may be affected in disseminated or contiguous spread. Associated bladder or ureter involvement (194, 204, 327) and the histopathology of the affected kidney (184) in cases of primary renal infections with

Apophysomyces elegans raise the possibility of an ascending route of infection. Organ tropism during rapid progression of bloodstream infections may explain cases of rapidly fatal isolated cerebral mucormycosis that occur after likely i.v. inoculation of Mucormycetes in i.v. drug abusers (136, 248, 346).

Published case reports and series of unusual Mucormycetes infections illustrate patterns of host specificity in which the rhino-orbital form occurs more frequently in patients who have poorly controlled diabetes and show that the pulmonary form predominates in patients who have malignant hematological diseases (167, 169). Also, Mucormycetes genus and species specificity contributes to subtle differences in the virulence, pathogenesis, and clinical features of mucormycosis. Sporangiospores released by the Mucorales range from 3 to 11 μm in diameter (279, 280). The different sizes of the sporangiospores may cause differences in their impact on the respiratory tract in humans (142). Spores larger than 5 μm (about 7 to 10 μm) have a greater chance of being trapped in the upper respiratory tract, whereas smaller spores (less than 5 μm) have a greater chance of reaching the lower respiratory tract (142, 167; <http://www.biology.ed.ac.uk/research/groups/jdeacon/microbes/airborne.htm>). This may contribute to differences in the frequency of clinical manifestations among Mucormycetes organisms. Although local and systemic immune host defense mechanisms are likely responsible for different frequencies of lower and upper respiratory tract infections among unusual Mucormycetes, the different sizes of *R. pusillus* (3 to 5 μm) and *Apophysomyces elegans* (4.0 to 5.7 \times 5.4 to 8 μm) spores, for example, may contribute to explain why *R. pusillus* causes infections predominantly in the lower respiratory tract, whereas *Apophysomyces elegans* has thus far caused primary infections only in the upper respiratory tract.

Differences in pathogenesis and virulence among Mucorales organisms as well as between Mucormycetes and other fila-

mentous fungi have been demonstrated (20, 61, 311). The rate of phagocytosis of Mucormycetes spores was significantly lower than that of *A. fumigatus* spores in a *D. melanogaster* model (61). The overall hyphal biomass of the organism is probably an important determinant in host-pathogen interactions (20, 61). PMN-induced hyphal damage decreased as the fungal biomass increased (20). This means that the number of PMNs that can cause significant damage to small hyphae of Mucormycetes in the early phases of fungal growth is not sufficient to inflict proportionally similar damage against the long, well-developed, branched hyphae observed later during Mucormycetes growth (20). This effect is genus dependent (20). These differences may help to explain the faster progression of and poorer prognosis for *C. bertholletiae* infections than other mold infections in immunocompromised hosts. Moreover, the virulence of *C. bertholletiae* (135) and its greater ability to succeed in the presence of innate host immunity than those of other Mucormycetes or even other filamentous fungi (20, 61, 311) explain the worst outcomes for mucormycosis caused by *C. bertholletiae*.

Clinical Presentation

Important differences in the clinical manifestations of infections caused by different Mucormycetes organisms are evident in published case reports, although almost all of the unusual species can cause cutaneous, pulmonary, disseminated, rhino-orbito-cerebral, and intra-abdominal infections (Table 3). In general, the fungi of the order Mucorales cause progressive infections with angioinvasion that evolve rapidly to thrombosis and infarction of surrounding tissues. The onset of symptoms is abrupt in most cases, with rapid evolution of the infection and patient death within a few days or weeks (96, 113, 116, 122, 246), especially if the diagnosis and treatment are delayed or when the infection develops in immunocompromised hosts. Although immune function, time of diagnosis, and treatment initiation (antifungal drugs and surgical procedures) are the major factors responsible for the pace of progression of mucormycosis, other factors related to the mode of acquisition, inoculum, strain virulence, and antifungal drug susceptibility may influence the outcome.

Tissue necrosis is a hallmark of mucormycosis (30), and *C. bertholletiae* is considered the most virulent and lethal pathogen. Because of this, *C. bertholletiae* and other uncommon Mucormycetes should not automatically be considered contaminants. Hematologists, oncologists, and transplant physicians should have a high index of suspicion for mucormycosis, as some Mucormycetes species (including *C. bertholletiae* and *R. pusillus*) are the cause of such infections. In addition, practitioners of other medical specialties, such as trauma specialists, should be aware of the signs and symptoms of mucormycosis, as Mucormycetes, including uncommon ones, may occur in healthy individuals (85/189 cases [45%]) or patients who are less immunosuppressed (Table 2) (39/189 cases [21%]).

Intraspecies or intragenus variation in the clinical presentation of infections with unusual Mucormycetes has also been evident. For example, mucormycosis with a chronic or subacute course has been reported for almost all unusual Mucormycetes, mostly in immunocompetent or slightly immunocompromised patients with relatively good prognoses. Soft tissue

infections caused by *S. vasiformis*, for instance, range from acute necrotizing fasciitis to chronic indurated granulomatous nodules and satellite lesions that may simulate entomophthoromycosis (265, 279). This observation agrees with a recent description of cutaneous mucormycosis by Chakrabarti (52). Several factors related to Mucormycetes species, inocula, host-pathogen interactions, and the degree of immune dysfunction may be responsible for the wide range in clinical manifestations.

Diagnosis

Increasing clinical and laboratory awareness of unusual Mucormycetes is essential considering their high mortality rates in immunocompromised patients and the relatively high frequency of infections with some species in immunocompetent individuals (Table 2). Motor vehicle accidents are common all over the world, and natural disasters and wars also increase the risk of exposure to contaminated soil. Because these pathogens reside in soil in tropical and subtropical areas of the world, and judging by the low frequency of reported cases of unusual mucormycosis, one could postulate that the burden of disease is underestimated. Thus, in cutaneous and subcutaneous infections that occur after accident-caused injuries or natural disasters in which contact with contaminated soil from tropical and subtropical areas of the world takes place, Mucormycetes organisms, especially the *Apophysomyces elegans* and *S. vasiformis* complexes, must be considered possible infecting pathogens.

The etiological agents in mucormycosis cases in many clinical reports were not identified at the species level (Table 1) (13, 168). In a comprehensive review of mucormycosis, a high percentage (50%) of the 929 cases reviewed lacked identification of the Mucormycetes species (287) (Table 1), and for most of these cases, the identification may have been doubtful (13). For this reason, the actual spectrum of Mucormycetes species and the incidence of infection with them in the clinic are not well known (13). Identification of fungi to the species level is desirable to better comprehend the natural histories and local differences in epidemiology of infecting Mucorales organisms (33, 283).

In cases with clinical suspicion of mucormycosis, culture of Mucormycetes with appropriate collections of specimens should be requested, because homogenization of tissue in the laboratory can result in fungal destruction (64, 244). In soft tissue infections, biopsy specimens should be obtained from the center of a lesion, especially a black eschar area, and should include subcutaneous fat, as Mucormycetes frequently invade blood vessels (52).

All Mucorales organisms grow rapidly (3 to 5 days) on most fungal media, such as Sabouraud and potato dextrose agar incubated at 25°C to 30°C (Fig. 3) (182, 279). A microaerophilic environment improves culture yield (165), although further validation of this approach is needed. Cultures positive for Mucormycetes species obtained from nonsterile specimens should be interpreted with caution and require correlation between the finding and the clinical situation (169, 182). Tissue swabs and sputum, sinus secretions, and bronchoalveolar lavage fluid cultures are usually nondiagnostic but may be important adjuvants for diagnosis of mucormycosis in immuno-

compromised patients (166, 193). Mucormycetes rarely grow in blood cultures (160, 182, 329), despite the angioinvasive nature of these pathogens. PCR techniques may be useful for early diagnosis of Mucormycetes infection, including for detection in blood. This is especially important for patients with hematological diseases in whom clinical conditions or coexistent thrombocytopenia precludes invasive diagnostic procedures. At this time, though, PCR techniques for detection of Mucormycetes remain investigational.

Apophysomyces elegans and *S. vasiformis* must be considered when Mucormycetes fail to sporulate on routinely used mycological culture media with antibiotics. Pathologists must be aware that *C. recurvatus*, in contrast with other Mucormycetes species, appears in yeast-like forms in histological sections, with sizes and morphologies similar to those of the yeast form of *P. brasiliensis* and spherules of *C. immitis*, creating the potential for cytological and histological misidentification of these agents (226, 293). This is especially important considering that, like these other two agents, *C. recurvatus* was recently shown to cause pulmonary infection (293).

Immunohistochemistry has been used to identify and discriminate Mucormycetes fungi from non-Mucormycetes fungi (32), but species identification of Mucormycetes was not achieved (33, 260). Carbon assimilation profiles are commonly used for yeast and bacterial species identification. This approach was shown to be in accordance with DNA-based phylogeny of Mucormycetes species and facilitated precise, accurate identification at the genus level (14, 306). It is also easy to perform, although it is less powerful than molecular approaches (14, 306).

The application of molecular biological methods, especially those based on amplification and analysis of DNA, has opened new horizons for diagnostic laboratories examining Mucormycetes. Different regions of DNA, including ribosomal DNA genes, have been used for molecular detection of Mucormycetes (69). Assays have often used the small-subunit (18S) or ITS rDNA gene region as targets because of the conserved nature and high copy number of these regions (149). However, other targets, such as the 28S rRNA gene and a conserved region of the Mucormycetes cytochrome, have been shown to be Mucormycetes species specific and are useful for differentiation of a variety of fungal pathogens from culture isolates (25, 55, 72, 125, 168, 201, 305, 351). Molecular techniques can also be important tools for recovery of Mucormycetes from fluids and tissues (25, 33, 78, 125, 128, 143, 149, 160, 185, 201, 281, 305), supporting histopathological diagnosis of mucormycosis (244). This is especially important for poorly sporulating Mucormycetes fungi (72, 185, 351). Ideally, the tissue specimens should be nonfixed, because formalin will damage DNA (72, 78). The possibility of false-positive results of molecular identification of Mucormycetes exists, especially when the clinical material used has come in contact with the environment, was obtained from a contaminated site, or was not collected aseptically (96, 117, 126). Further studies are needed to better standardize molecular techniques and to improve the sensitivity of identification of Mucormycetes in tissues (72).

Guidelines for fungal identification using DNA target sequencing were published by the CLSI (25, 68, 72), and the use of ITS sequencing as a first-line strategy for Mucormycetes identification has been proposed by the International Society

of Human and Animal Mycology (25, 72). However, the resolution of ITS sequence-based identification of some closely related Mucormycetes organisms is not optimal, and heterogeneity of the ITS sequence has been reported for members of the order Mucorales (25, 368). Additionally, because of difficulties in implementation and the cost of molecular techniques, they are restricted to research and reference laboratories (55). These techniques are important considering an increasing incidence of Mucormycetes infections and the scarcity of microbiologists trained in traditional mycology, which nullify precise species identification for guidance of management (25). Therefore, methods of DNA sequencing analysis to discriminate species of Mucorales should be used by large clinical microbiology or reference laboratories that are proficient in these molecular techniques. These laboratories often serve smaller laboratories as well, which would then also benefit from these services. Reference laboratories should receive at least clinically relevant or difficult-to-identify strains (368). These procedures would help clinicians to narrow therapeutic approaches (180), which is especially important as more antifungal drugs become available.

Management and Prognosis

The general approaches to management of infections caused by Mucormycetes species are similar. Unfortunately, the current antifungal armamentarium for treatment of infections with Mucormycetes remains limited, as Mucormycetes are inherently less susceptible to commonly used antifungal agents, including AmB, echinocandins, and triazoles. Species identification is important, as preclinical studies have suggested that pathogenic Mucormycetes species have different responses to antifungal drugs (11, 14, 180, 312).

Suspicion of mucormycosis in immunocompromised patients may lead to rapid introduction of broad-spectrum antifungal-based therapy and more rapid detection of the pathogen. Early suspicion and treatment are essential for improved prognoses for mucormycosis in immunocompromised as well as immunocompetent hosts (55, 62, 96, 317, 338). Successful treatment of mucormycosis can be achieved via extensive surgical debridement or resection of the infected focus in conjunction with antifungal-based therapy and control of the underlying disease when it is required and feasible. For example, rapid control of hyperglycemia, reversal of ketoacidosis, tapering of glucocorticoid-based therapy, and discontinuation of deferoxamine-based treatment are also critical to a positive outcome (96). Because tissue necrosis limits antifungal drug penetration, surgical procedures are vital to the management of mucormycosis. Intraoperative frozen sections are used to delineate the margins of infected tissues (317). The surgical area should be monitored closely, and at the first indication of disease progression, debridement should be repeated (52, 166).

The prognosis remains poor if the predisposing underlying disease cannot be ameliorated during the course of infection (96). Surgical interventions frequently are not feasible for immunocompromised patients, resulting in poor prognoses (96, 317). The use of AmB may be limited by adverse effects, especially renal impairment. Use of lipid formulations of AmB permits treatment with higher doses than those with conventional formulations of AmB without significantly increasing

toxicity (244). Use of higher dosages of L-AmB (i.e., 10 mg/kg/day) may achieve high concentrations of AmB in disease-targeted organs, such as the lung, earlier in the course of treatment (317). In a murine model of pulmonary *Rhizopus oryzae* mucormycosis, some differences in the pharmacodynamics of L-AmB and AmB lipid complex were observed; however, the survival rates for the two treatments were similar (188). The role of posaconazole is still unclear, as its use has been reported in few reported cases of unusual Mucormycetes infection (Table 4), and the precise efficacy of this drug is not known (297, 317). However, salvage posaconazole-based therapy or use of posaconazole in patients who are intolerant of conventional AmB treatment may be linked with improved outcomes of general mucormycosis in immunocompromised patients (339). Treatment with posaconazole has resulted in low survival rates and variable or no reductions in the fungal loads in the kidneys and brains of mice infected with *R. oryzae* strains with intermediate posaconazole MICs (288). In mice infected with a posaconazole-susceptible strain, the survival rate ranged from 30% to 40% (288). Comparable survival rates (33% and 31%, respectively) were seen following posaconazole monotherapy and in combination with G-CSF for the treatment of disseminated *Rhizopus microsporus* infection in neutropenic mice; significant reductions of the fungal burdens in the kidneys, but not in the lungs, brain, and liver, were observed (297). In another study using neutropenic and diabetic murine models of disseminated *C. bertholletiae* infection, posaconazole at a higher dosage (60 or 80 mg/kg/day) prolonged survival and reduced the fungal loads in target organs (252). *In vitro* susceptibility studies have indicated that different Mucormycetes species have various susceptibilities to posaconazole (6, 11, 297). Besides the differences in susceptibility to posaconazole *in vitro*, other factors, such as inoculum load, posaconazole dosage, differences in virulence that exist among Mucormycetes species and individual strains, and various degrees of immune suppression of the experimental host, may be responsible for the variable efficacy of posaconazole (252, 297). The proper role of combination antifungal therapy in primary treatment of mucormycosis is under debate (317, 354).

Hyperbaric oxygen therapy has been used as an adjuvant therapy for cutaneous or rhino-orbital infections, with unproven efficacy (146, 244, 317, 332). In neutropenic patients, use of G-CSF, GM-CSF, granulocyte transfusions, or recombinant gamma interferon is an anecdotally beneficial temporary approach to therapy until granulocyte recovery (245, 317).

Therefore, development of new antifungals with activity against Mucorales infections, especially those with activity against *C. bertholletiae*, is needed. Iron chelation with deferasirox has shown promising results, although the clinical experience is limited (45, 244). In addition, its potency *in vitro* is species specific against growing hyphae of Mucorales fungi (189); deferasirox was less active *in vitro* against *Cunninghamella* than against *Rhizopus* spp. (141, 189). Development of novel antifungals and continuing studies of the pharmacokinetics and pharmacodynamics of available drugs are basic to improving outcomes of mucormycosis.

Additionally, plastic surgery for correction of surgical sequelae of rhino-orbital or extensive soft tissue infections, re-

habilitation, and psychological support must be included systematically in management for survivors of mucormycosis.

Prevention

Reduction of environmental exposure to pathogens, although not easily feasible, remains the main prophylactic measure for Mucormycetes infections (243). Construction activity associated with dust generation, water-damaged environments, or decaying organic matter close to areas of immunocompromised patients have been associated with several outbreaks or clusters of infections caused by airborne molds (21, 353, 357), including those caused by unusual Mucormycetes species such as *R. pusillus* (83, 106, 320) and *C. bertholletiae* (282).

According to Weber et al., more than 60 outbreaks of health care-associated invasive aspergillosis have been described in the English literature (357). Information gained from outbreak investigations, especially control measures, formed the basis for current guidelines to prevent health care-associated aspergillosis (357). Among Mucormycetes infections, 15 hospital outbreaks or clusters of mucormycosis affecting mostly immunocompromised (patients with hematologic malignancies, other cancer patients, transplant recipients, neonates, burn patients, and patients in intensive care units [ICUs] or surgery (cardiac and orthopedic surgery) patients were reported in the United States, Europe, Canada, and China over a period of 1 month to 2 years between 1977 and 2010 (21, 65, 83, 106, 282, 320). The summary data presented here are derived from the excellent review of nosocomial outbreaks of mucormycosis from 1977 to 2008 provided by Antoniadou (21), with the inclusion of additional reports from 1977 to 2008 (83, 282, 320) and one outbreak from 2009 to 2010 (65). *Rhizopus* spp. were the cause of eight outbreaks (21, 65), *R. pusillus* was linked to three reports (83, 106, 320), and *C. bertholletiae* (282), *Mucor* sp., *L. corymbifera*, and a nonspecified Mucormycetes species (21) were each related to one outbreak or cluster of infection. The likely sources of infections were hospital indoor air (five outbreaks) (21, 83, 106, 320), ventilation systems (three outbreaks) (21, 83), water damage or nondamaged hospital surfaces near infected patients (two outbreaks) (83, 106), and several materials used in hospitals, such as elasticized adhesive bandages or tape (three outbreaks), wooden tongue depressors (two outbreaks), karaya (plant-derived adhesive) ostomy bags (one outbreak) (21), and cornstarch used in the manufacturing of allopurinol tablets and ready-to-eat food (65). Among unusual Mucormycetes species, *R. pusillus* was the only species isolated from patients and environmental sources during nosocomial outbreaks or clusters of cases (83, 106, 320). An outdoor refuse compactor located in the vicinity of a clinical unit or patients' rooms was associated with two *R. pusillus* reports (83, 320), while hospital reconstruction was associated with a cluster of *C. bertholletiae* cases (282). Molecular techniques were performed in two outbreaks caused by more common Mucormycetes species and were successful at showing genetic relatedness of *Rhizopus* spp. recovered from patients and sources (21, 65), although cutoff criteria for clonal characterization of the Mucormycetes must be determined (65).

Elimination of obvious sources of infections and other interventional measures, including the use of antifungal prophylaxis in an *R. pusillus* outbreak (106), have been described to

control outbreaks caused by Mucormycetes (21, 65, 106). Case numbers are usually low, ranging from two to six in the majority of outbreaks, including those caused by unusual Mucormycetes species (83, 106, 282, 320). The exception was an outbreak of intestinal *Rhizopus* sp. infection and colonization which was detected in 12 patients with hematological malignancies in a teaching hospital, and possibly in patients from other hospitals, in Hong Kong (65). Nevertheless, the average mortality rate in reported outbreaks of general mucormycosis was 42% (21, 65, 83, 106, 282, 320), while it was higher (69%) in infection outbreaks or clusters caused by unusual Mucormycetes species (83, 106, 282, 320). Therefore, whenever two or more cases of nosocomial acquisition of mucormycosis are suspected, especially in areas with immunocompromised patients, outbreak investigation and implementation of preventive and infection control measures, including relocating immunocompromised patients to a preventive environment when airborne transmission is suspected, are some of the approaches that have contributed to controlling mucormycosis outbreaks (21, 106).

The risk of mold infection depends on several factors related to the individual and the microorganism, including the route and magnitude of exposures, the immune status of the person exposed (28, 41, 142), and the virulence and pathogenicity of the microorganism. Studies to definitively measure the risk of infection that airborne mold exposures represent for immunocompromised patients are not available (41, 142). Studies assessing invasive mold infections following heavy airborne mold exposures after Hurricanes Katrina and Rita were not enough to establish the risk that these exposures represent to highly immunocompromised patients (28). However, a cluster of eight patients colonized in the respiratory tract with *Syncephalastrum* spp. was detected over a 5-month period after the hurricanes (272), at the same time that airborne *Syncephalastrum* species were the only Mucormycetes recovered in almost half (47%) of the heavily damaged houses sampled from flooded areas (272, 273). Also, very few reports of traumatic mucormycosis caused by unusual Mucormycetes species after natural disaster have been published (19, 313), but an epidemiological history of exposure to contaminated ground is a hallmark of traumatic mucormycosis caused by several unusual Mucormycetes species (Table 2). Besides geography and climate, other factors, such as temperature, light, air pollutants, and factors related to human activity, affect the risk of environmental mold contamination (5, 17, 39, 117, 142, 269, 289, 310), and probably the risk of infection (247, 348). Environmental studies specific for Mucormycetes species are also still scarce (5, 28, 289). Because of the limited information about the conditions in which Mucormycetes infections occur and considering the high mortality rates of mucormycosis in immunocompromised patients, any circumstance that is possible to prevent heavy exposure to molds is desirable. Therefore, detailed guidance in preventive measures, especially for airborne (e.g., avoid damp indoor spaces or mold cleanup, and seek the advice of a doctor in situations of mold-contaminated surfaces or during reconstruction activities in homes or buildings) and transcutaneous (e.g., avoid or take care with the use of elasticized or wooden material or plants in contact with skin, use aseptic technique for percutaneous injection, and avoid and report to health care provider any kind of trauma, especially

that with contact with contaminated soil or water) transmission of Mucormycetes, must be provided to immunocompromised patients.

CONCLUSIONS

Cases of unusual Mucormycetes infections may be overlooked, as Mucormycetes fungi are not always identified to the species level. Epidemiology, clinical presentations, and outcomes of unusual Mucormycetes infections vary according to the degree of immune function and the Mucormycetes species. The need remains for improved clinical and laboratory diagnoses of unusual Mucormycetes infections. In particular, new active antifungal drugs and treatment strategies for improving outcomes, especially for *C. bertholletiae* and *R. pusillus* infections, are urgently needed. Understanding the mechanisms of innate host responses to Mucormycetes infection is important, as the patient's immune status appears to be the most significant factor for a favorable prognosis for mucormycosis. More studies are necessary in order to develop preventive strategies for Mucormycetes infections.

ACKNOWLEDGMENTS

We thank Deanna A. Sutton, Department of Pathology and Fungus Testing Laboratory at The University of Texas Health Science Center at San Antonio, for providing the photomicrographs of Mucormycetes.

Marisa Z. R. Gomes has no conflicts of interest. Russell E. Lewis has conducted research for Merck & Co., Inc., and Astellas and has served in an advisory role for Merck & Co., Inc., and Astellas. Dimitrios P. Kontoyiannis has received research support from Merck & Co., Inc., Pfizer, Astellas, and Gilead, has served on the speakers bureau for Merck & Co., Inc., and Astellas, and has served on the advisory boards of Merck & Co., Inc., and Astellas.

REFERENCES

1. Aarset, H., K. Aasarod, U. Bergan, and A. Angelsen. 2001. Acute renal infarction in a woman with slight asthma. *Nephrol. Dial. Transplant.* **16**: 1711–1712.
2. Abdel-Hafez, S. I., A. H. Moubasher, A. A. Shoreit, and M. A. Ismail. 1990. Fungal flora associated with combine harvester wheat and sorghum dusts from Egypt. *J. Basic Microbiol.* **30**:467–479.
3. Abuali, M. M., et al. 2009. *Rhizomucor variabilis* var. *regularior* and *Hormographiella aspergillata* infections in a leukemic bone marrow transplant recipient with refractory neutropenia. *J. Clin. Microbiol.* **47**:4176–4179.
4. Ajello, L., D. F. Dean, and R. S. Irwin. 1976. The zygomycete *Saksenaia vasiformis* as a pathogen of humans with a critical review of the etiology of zygomycosis. *Mycologia* **68**:52–62.
5. Al-Ajam, M. R., A. R. Bizri, J. Mokhbat, J. Weedon, and L. Lutwick. 2006. Mucormycosis in the Eastern Mediterranean: a seasonal disease. *Epidemiol. Infect.* **134**:341–346.
6. Alastruey-Izquierdo, A., et al. 2009. Activity of posaconazole and other antifungal agents against *Mucorales* strains identified by sequencing of internal transcribed spacers. *Antimicrob. Agents Chemother.* **53**:1686–1689.
7. Alastruey-Izquierdo, A., et al. 2010. Species recognition and clinical relevance of the zygomycetous genus *Lichtheimia* (syn. *Absidia* pro parte, *Lichtheimia*). *J. Clin. Microbiol.* **48**:2154–2170.
8. Alexander, B. D., et al. 2010. Fatal *Apophysomyces elegans* infection transmitted by deceased donor renal allografts. *Am. J. Transplant.* **10**:2161–2167.
9. Al-Hedaithy, M. 1998. Cutaneous zygomycosis due to *Saksenaia vasiformis*: case report and literature review. *Ann. Saudi Med.* **18**:428–431.
10. Al-Humiany, A. A. 2010. Opportunistic pathogenic fungi of the house dust in Turubah, Kingdom of Saudi Arabia. *Aust. J. Basic Appl. Sci.* **4**:122–126.
11. Almyroudis, N. G., D. A. Sutton, A. W. Fothergill, M. G. Rinaldi, and S. Kusne. 2007. In vitro susceptibilities of 217 clinical isolates of Zygomycetes to conventional and new antifungal agents. *Antimicrob. Agents Chemother.* **51**:2587–2590.
12. Alvarez, E., et al. 2010. Molecular phylogenetic diversity of the emerging mucoralean fungus *Apophysomyces*: proposal of three new species. *Rev. Iberoam. Micol.* **27**:80–89.

13. Alvarez, E., et al. 2009. Spectrum of Zygomycetes species identified in clinically significant specimens in the United States. *J. Clin. Microbiol.* **47**:1650–1656.
14. Alvarez, E., et al. 2010. Molecular phylogeny and proposal of two new species of the emerging pathogenic fungus *Saksena*. *J. Clin. Microbiol.* **48**:4410–4416.
15. Alvarez, O. A., J. A. Maples, F. O. Tio, and M. Lee. 1995. Severe diarrhea due to *Cokeromyces recurvatus* in a bone marrow transplant recipient. *Am. J. Gastroenterol.* **90**:1350–1351.
16. Ameen, M., R. Arenas, E. Martínez-Luna, M. Reyes, and R. Zacarias. 2007. The emergence of mucormycosis as an important opportunistic fungal infection: five cases presenting to a tertiary referral center for mycology. *Int. J. Dermatol.* **46**:380–384.
17. Amend, A. S., K. A. Seifert, R. Samson, and T. D. Bruns. 2010. Indoor fungal composition is geographically patterned and more diverse in temperate zones than in the tropics. *Proc. Natl. Acad. Sci. U. S. A.* **107**:13748–13753.
18. Anaissie, E., et al. 1989. New spectrum of fungal infections in patients with cancer. *Rev. Infect. Dis.* **11**:369–378.
19. Andresen, D., et al. 2005. Multifocal cutaneous mucormycosis complicating polymicrobial wound infections in a tsunami survivor from Sri Lanka. *Lancet* **365**:876–878.
20. Antachopoulos, C., J. P. Demchok, E. Roilides, and T. J. Walsh. 2010. Fungal biomass is a key factor affecting polymorphonuclear leucocyte-induced hyphal damage of filamentous fungi. *Mycoses* **53**:321–328.
21. Antoniadou, A. 2009. Outbreaks of zygomycosis in hospitals. *Clin. Microbiol. Infect.* **15**(Suppl.):55–59.
22. Arnáiz-García, M. E., et al. 2009. Cutaneous mucormycosis: report of five cases and review of the literature. *J. Plast. Reconstr. Aesthet. Surg.* **62**:e434–e441.
23. Axelrod, P., K. J. Kwon-Chung, P. Frawley, and H. Rubin. 1987. Chronic cystitis due to *Cokeromyces recurvatus*: a case report. *J. Infect. Dis.* **155**:1062–1064.
24. Bagy, M. M., and A. Y. Abdel-Mallek. 1991. Thermophilic and thermotolerant fungi of animals' hair. *Acta Microbiol. Hung.* **38**:117–120.
25. Balajee, S. A., et al. 2009. Sequence-based identification of *Aspergillus*, *Fusarium*, and *Mucorales* species in the clinical mycology laboratory: where are we and where should we go from here? *J. Clin. Microbiol.* **47**:877–884.
26. Baradkar, V. P., and S. Kumar. 2009. Cutaneous zygomycosis due to *Saksena* *vasiformis* in an immunocompetent host. *Indian J. Dermatol.* **54**:382–384.
27. Baradkar, V. P., M. Mathur, S. Taklikar, M. Rath, and S. Kumar. 2008. Fatal rhino-orbito-cerebral infection caused by *Saksena* *vasiformis* in an immunocompetent individual: first case report from India. *Indian J. Med. Microbiol.* **26**:385–387.
28. Barbeau, D. N., L. F. Grimsley, L. E. White, J. M. El-Dahr, and M. Lichtveld. 2010. Mold exposure and health effects following hurricanes Katrina and Rita. *Annu. Rev. Public Health* **31**:165–178.
29. Bearer, E. A., P. R. Nelson, M. Y. Chowers, and C. E. Davis. 1994. Cutaneous zygomycosis caused by *Saksena* *vasiformis* in a diabetic patient. *J. Clin. Microbiol.* **32**:1823–1824.
30. Ben-Ami, R., M. Luna, R. E. Lewis, T. J. Walsh, and D. P. Kontoyiannis. 2009. A clinicopathological study of pulmonary mucormycosis in cancer patients: extensive angioinvasion but limited inflammatory response. *J. Infect.* **59**:134–138.
31. Benjamin, C. R., and C. W. Hesseltine. 1957. The genus *Actinomorcor*. *Mycologia* **49**:240–249.
32. Bethge, W. A., et al. 2005. Mucormycoses in patients with hematologic malignancies: an emerging fungal infection. *Haematologica* **90**(Suppl.): ECR22.
33. Bialek, R., et al. 2005. PCR based identification and discrimination of agents of mucormycosis and aspergillosis in paraffin wax embedded tissue. *J. Clin. Pathol.* **58**:1180–1184.
34. Bibashi, E., V. Sidi, M. Kotsiou, E. Makrigiannaki, and D. Kolioukas. 2008. Pulmonary zygomycosis caused by *Cunninghamella bertholletiae* in a child with acute lymphoblastic leukemia. *Hippokratia* **12**:43–45.
35. Björkholm, M., et al. 2001. Liposomal amphotericin B and surgery in the successful treatment of invasive pulmonary mucormycosis in a patient with acute T-lymphoblastic leukemia. *Scand. J. Infect. Dis.* **33**:316–319.
36. Blair, J. E., L. J. Fredrikson, B. A. Pockaj, and C. S. Lucaire. 2002. Locally invasive cutaneous *Apophysomyces elegans* infection acquired from snapdragon patch test. *Mayo Clin. Proc.* **77**:717–720.
37. Blanchet, D., et al. 2008. *Saksena* *vasiformis* infection, French Guiana. *Emerg. Infect. Dis.* **14**:342–344.
38. Bodhe, P. V., R. N. Kotwani, B. G. Kirodian, N. A. Kshirsagar, and S. K. Pandya. 2002. Open label, randomised, comparative phase III safety and efficacy study with conventional amphotericin B and liposomal amphotericin B in patients with systemic fungal infection. *J. Assoc. Physicians India* **50**:662–670.
39. Bonito, G., O. S. Isikhuemhen, and R. Vilgalys. 2010. Identification of fungi associated with municipal compost using DNA-based techniques. *Biore-sour. Technol.* **101**:1021–1027.
40. Boyce, J. M., L. A. Lawson, W. R. Lockwood, and J. L. Hughes. 1981. *Cunninghamella bertholletiae* wound infection of probable nosocomial origin. *South. Med. J.* **74**:1132–1135.
41. Brandt, M., et al. 2006. Mold prevention strategies and possible health effects in the aftermath of hurricanes and major floods. *MMWR Recomm. Rep.* **55**:1–27.
42. Brennan, R. O., B. J. Crain, A. M. Proctor, and D. T. Durack. 1983. *Cunninghamella*: a newly recognized cause of rhinocerebral mucormycosis. *Am. J. Clin. Pathol.* **80**:98–102.
43. Brown, S. R., I. A. Shah, and M. Grinstead. 1998. Rhinocerebral mucormycosis caused by *Apophysomyces elegans*. *Am. J. Rhinol.* **12**:289–292.
44. Burrell, S. R., D. J. Ostlie, M. Saubolle, M. Dimler, and S. D. Barbour. 1998. *Apophysomyces elegans* infection associated with cactus spine injury in an immunocompetent pediatric patient. *Pediatr. Infect. Dis. J.* **17**:663–664.
45. Busca, A., et al. 2010. Combined antifungal therapy, iron chelation and surgical resection as treatment of hepatic zygomycosis in a patient with haematological malignancy. *Mycoses* **53**:275–278.
46. Buzina, W., et al. 2003. Fungal biodiversity—as found in nasal mucus. *Med. Mycol.* **41**:149–161.
47. Cáceres, A. M., et al. 1997. *Apophysomyces elegans* limb infection with a favorable outcome: case report and review. *Clin. Infect. Dis.* **25**:331–332.
48. Campelo, C., S. Miguel, and A. del Palacio. 2005. Zygomycosis rhinocerebral causada por *Saksena* *vasiformis* en un paciente diabetico. *Enferm. Infecc. Microbiol. Clin.* **23**:77.
49. Reference deleted.
50. Carter, J. E., and O. Ulusarac. 2003. Widespread cutaneous involvement by invasive *Apophysomyces elegans* in a gravid patient following trauma. *Cutis* **72**:221–224, 227–228.
51. Cefai, C., T. S. Elliott, R. W. Nutton, A. E. Lockett, and J. Pooley. 1987. Zygomycetic gangrenous cellulitis. *Lancet* **ii**:1337–1338.
52. Chakrabarti, A. 2010. Cutaneous zygomycosis: major concerns. *Indian J. Med. Res.* **131**:739–741.
53. Chakrabarti, A., et al. 2006. The rising trend of invasive zygomycosis in patients with uncontrolled diabetes mellitus. *Med. Mycol.* **44**:335–342.
54. Chakrabarti, A., et al. 2001. Ten years' experience in zygomycosis at a tertiary care centre in India. *J. Infect.* **42**:261–266.
55. Chakrabarti, A., et al. 2003. *Apophysomyces elegans*: an emerging zygomycete in India. *J. Clin. Microbiol.* **41**:783–788.
56. Chakrabarti, A., et al. 1997. Craniofacial zygomycosis caused by *Apophysomyces elegans*. *Mycoses* **40**:419–421.
57. Chakrabarti, A., et al. 2010. *Apophysomyces elegans*: epidemiology, amplified fragment length polymorphism typing, and in vitro antifungal susceptibility pattern. *J. Clin. Microbiol.* **48**:4580–4585.
58. Chakrabarti, A., et al. 1997. Primary cutaneous zygomycosis due to *Saksena* *vasiformis* and *Apophysomyces elegans*. *Clin. Infect. Dis.* **24**:580–583.
59. Chakrabarti, A., et al. 2009. Invasive zygomycosis in India: experience in a tertiary care hospital. *Postgrad. Med. J.* **85**:573–581.
60. Chamilos, G., and D. P. Kontoyiannis. 2006. The rationale of combination antifungal therapy in severely immunocompromised patients: empiricism versus evidence-based medicine. *Curr. Opin. Infect. Dis.* **19**:380–385.
61. Chamilos, G., et al. 2008. *Drosophila melanogaster* as a model host to dissect the immunopathogenesis of zygomycosis. *Proc. Natl. Acad. Sci. U. S. A.* **105**:9367–9372.
62. Chamilos, G., R. E. Lewis, and D. P. Kontoyiannis. 2008. Delaying amphotericin B-based frontline therapy significantly increases mortality among patients with hematologic malignancy who have zygomycosis. *Clin. Infect. Dis.* **47**:503–509.
63. Chamilos, G., et al. 2006. Invasive fungal infections in patients with hematologic malignancies in a tertiary care cancer center: an autopsy study over a 15-year period (1989–2003). *Haematologica* **91**:986–989.
64. Chander, J., J. Kaur, A. Attri, and H. Mohan. 2010. Primary cutaneous zygomycosis from a tertiary care centre in north-west India. *Indian J. Med. Res.* **131**:765–770.
65. Cheng, V. C., et al. 2009. Outbreak of intestinal infection due to *Rhizopus microsporus*. *J. Clin. Microbiol.* **47**:2834–2843.
66. Chetchotisakd, P., P. Boonma, M. Sookpranee, and C. Pairouk. 1991. Rhinocerebral mucormycosis: a report of eleven cases. *Southeast Asian J. Trop. Med. Public Health* **22**:268–273.
67. Chiba, N., and R. Miki. 1990. Zygomycosis caused by *Cunninghamella bertholletiae*. *Rinsho Byori* **38**:1219–1225.
68. Clinical and Laboratory Standards Institute. 2008. Interpretive criteria for identification of bacteria and fungi by DNA target sequencing: guideline. CLSI, Wayne, PA.
69. Cohen-Abbo, A., P. M. Bozeman, and C. C. Patrick. 1993. *Cunninghamella* infections: review and report of two cases of *Cunninghamella* pneumonia in immunocompromised children. *Clin. Infect. Dis.* **17**:173–177.
70. Cooter, R. D., I. S. Lim, D. H. Ellis, and I. O. Leitch. 1990. Burn wound zygomycosis caused by *Apophysomyces elegans*. *J. Clin. Microbiol.* **28**:2151–2153.
71. Däbritz, J., M. Schneider, G. Just-Nübling, and A. H. Groll. 17 December 2009. Minireview: invasive fungal infection complicating acute *Plasmodium falciparum* malaria. *Mycoses* doi:10.1111/j.1439-0507.2009.01826.x.

72. **Dannaoui, E.** 2009. Molecular tools for identification of Zygomycetes and the diagnosis of zygomycosis. *Clin. Microbiol. Infect.* **15**(Suppl. 5):66–70.
73. **Dannaoui, E., J. Afeltra, J. F. Meis, and P. E. Verweij.** 2002. In vitro susceptibilities of Zygomycetes to combinations of antimicrobial agents. *Antimicrob. Agents Chemother.* **46**:2708–2711.
74. **Dannaoui, E., J. W. Mouton, J. F. Meis, P. E. Verweij, and Eurofung Network.** 2002. Efficacy of antifungal therapy in a nonneutropenic murine model of zygomycosis. *Antimicrob. Agents Chemother.* **44**:1953–1959.
75. **Dannaoui, E., J. F. Meis, J. W. Mouton, and P. E. Verweij.** 2002. In vitro susceptibilities of Zygomycota to polyenes. *J. Antimicrob. Chemother.* **49**:741–744.
76. **Dannaoui, E., J. Meletiadis, J. W. Mouton, J. F. Meis, and P. E. Verweij.** 2003. In vitro susceptibilities of Zygomycetes to conventional and new antifungals. *J. Antimicrob. Chemother.* **51**:45–52.
77. **Dannaoui, E., A. J. Rijs, and P. E. Verweij.** 2003. Invasive infections due to *Apophysomyces elegans*. *Mayo Clin. Proc.* **78**:252–253.
78. **Dannaoui, E., et al.** 2010. Molecular detection and identification of Zygomycetes species from paraffin-embedded tissues in a murine model of disseminated zygomycosis: a collaborative European Society of Clinical Microbiology and Infectious Diseases (ESCMID) Fungal Infection Study Group (EFISG) evaluation. *J. Clin. Microbiol.* **48**:2043–2046.
79. **Darrisaw, L., G. Hanson, D. H. Vesole, and S. C. Kehl.** 2000. *Cunninghamella* infection post bone marrow transplant: case report and review of the literature. *Bone Marrow Transplant.* **25**:1213–1216.
80. **Davel, G., et al.** 2001. Maxillary sinusitis caused by *Actinomyces elegans*. *J. Clin. Microbiol.* **39**:740–742.
81. **Dean, D. F., L. Ajello, R. S. Irwin, W. K. Woelk, and G. J. Skarulis.** 1977. Cranial zygomycosis caused by *Saksenaia vasiformis*. Case report. *J. Neurosurg.* **46**:97–103.
82. **del Palacio, A., et al.** 1999. Five cases of zygomycosis. *Rev. Iberoam. Micol.* **16**:50–56.
83. **del Palacio Hernanz, A., J. Fereres, S. Larregla Garraus, A. Rodriguez-Noriega, and F. Sanz Sanz.** 1983. Nosocomial infection by *Rhizomucor pusillus* in a clinical haematology unit. *J. Hosp. Infect.* **4**:45–49.
84. **De Pauw, B., et al.** 2008. Revised definitions of invasive fungal disease from the European Organization for Research and Treatment of Cancer/Invasive Fungal Infections Cooperative Group and the National Institute of Allergy and Infectious Diseases Mycoses Study Group (EORTC/MSG) Consensus Group. *Clin. Infect. Dis.* **46**:1813–1821.
85. **Dermoumi, H.** 1993. A rare zygomycosis due to *Cunninghamella bertholletiae*. *Mycoses* **36**:293–294.
86. **Devi, S. C., et al.** 2008. Favorable outcome of amphotericin B treatment of zygomycotic necrotizing fasciitis caused by *Apophysomyces elegans*. *Int. J. Dermatol.* **47**:407–409.
87. **Dökmets, H. S., et al.** 2002. Diabetic ketoacidosis and rhino-orbital mucormycosis. *Diabetes Res. Clin. Pract.* **57**:139–142.
88. **Eaton, M. E., A. A. Padhye, D. A. Schwartz, and J. P. Steinberg.** 1994. Osteomyelitis of the sternum caused by *Apophysomyces elegans*. *J. Clin. Microbiol.* **32**:2827–2828.
89. **el-Kady, I. A., and M. S. Youssef.** 1993. Survey of mycoflora and mycotoxins in Egyptian soybean seeds. *J. Basic Microbiol.* **33**:371–378.
90. **Ellis, D. H., and G. W. Kaminski.** 1985. Laboratory identification of *Saksenaia vasiformis*: a rare cause of zygomycosis in Australia. *Sabouraudia* **23**:137–140.
91. **Ellis, J. J., and C. W. Heseltine.** 1974. Two new families of *Mucorales*. *Mycologia* **66**:87–95.
92. **Erdos, M. S., K. Butt, and L. Weinstein.** 1972. Mucormycotic endocarditis of the pulmonary valve. *JAMA* **222**:951–953.
93. **Espinel-Ingroff, A., et al.** 2007. Multicenter evaluation of a new disk agar diffusion method for susceptibility testing of filamentous fungi with voriconazole, posaconazole, itraconazole, amphotericin B, and caspofungin. *J. Clin. Microbiol.* **45**:1811–1820.
94. **Espinel-Ingroff, A., and E. Canton.** 2008. Comparison of Neo-Sensitabs tablet diffusion assay with CLSI broth microdilution M38-A and disk diffusion methods for testing susceptibility of filamentous fungi with amphotericin B, caspofungin, itraconazole, posaconazole, and voriconazole. *J. Clin. Microbiol.* **46**:1793–1803.
95. **Espinel-Ingroff, A., E. Johnson, H. Hockey, and P. Troke.** 2008. Activities of voriconazole, itraconazole and amphotericin B in vitro against 590 moulds from 323 patients in the voriconazole phase III clinical studies. *J. Antimicrob. Chemother.* **61**:616–620.
96. **Eucker, J., O. Sezer, B. Graf, and K. Possinger.** 2001. Mucormycoses. *Mycoses* **44**:253–260.
97. **Fairley, C., T. J. Sullivan, P. Bartley, T. Allworth, and R. Lewandowski.** 2000. Survival after rhino-orbital-cerebral mucormycosis in an immunocompetent patient. *Ophthalmology* **107**:555–558.
98. **Ferguson, B. J., T. G. Mitchell, R. Moon, E. M. Camporesi, and J. Farmer.** 1988. Adjunctive hyperbaric oxygen for treatment of rhinocerebral mucormycosis. *Rev. Infect. Dis.* **10**:551–559.
99. **Ferguson, T. D., et al.** 2007. Posaconazole treatment for *Apophysomyces elegans* rhino-orbital zygomycosis following trauma for a male with well-controlled diabetes. *J. Clin. Microbiol.* **45**:1648–1651.
100. **Frater, J. L., G. S. Hall, and G. W. Procop.** 2001. Histologic features of zygomycosis: emphasis on perineural invasion and fungal morphology. *Arch. Pathol. Lab. Med.* **125**:375–378.
101. **Galgóczy, L., G. Lukács, I. Nyilasi, T. Papp, and C. Vágvölgyi.** 2010. Antifungal activity of statins and their interaction with amphotericin B against clinically important Zygomycetes. *Acta Biol. Hung.* **61**:356–365.
102. **Garbino, J., C. Myers, J. Ambrosioni, and F. Gummy-Pause.** 2010. Report of a successful treatment of pulmonary *Cunninghamella bertholletiae* infection with liposomal amphotericin and posaconazole in a child with GvHD and review of the literature. *J. Pediatr. Hematol. Oncol.* **32**:85–87.
103. **García-Covarrubias, L., R. Bartlett, D. M. Barratt, and R. J. Wassermann.** 2001. Rhino-orbitocerebral mucormycosis attributable to *Apophysomyces elegans* in an immunocompetent individual: case report and review of the literature. *J. Trauma* **50**:353–357.
104. **García-Martínez, J., F. López-Medrano, A. Alhambra, and A. del Palacio.** 2008. Rhinocerebral zygomycosis caused by *Saksenaia vasiformis* in a diabetic patient. *Mycoses* **51**:549–553.
105. **Garey, K. W., et al.** 2001. *Cunninghamella bertholletiae* infection in a bone marrow transplant patient: amphotericin lung penetration, MIC determinations, and review of the literature. *Pharmacotherapy* **21**:855–860.
106. **Garner, D., and K. Machin.** 2008. Investigation and management of an outbreak of mucormycosis in a paediatric oncology unit. *J. Hosp. Infect.* **70**:53–59.
107. **Gil, L. A., et al.** 2007. Zygomycosis cutanea en un paciente de 10 años. Primer caso pediátrico en Venezuela. Revisión de la literatura. *Arch. Venez. Pueric. Pediatr.* **70**:22–27.
108. **Gil-Lamaignere, C., et al.** 2005. Effect of media composition and in vitro activity of posaconazole, caspofungin and voriconazole against Zygomycetes. *J. Antimicrob. Chemother.* **55**:1016–1019.
109. **Gil-Lamaignere, C., et al.** 2005. Interferon-gamma and granulocyte-macrophage colony-stimulating factor augment the activity of polymorphonuclear leukocytes against medically important Zygomycetes. *J. Infect. Dis.* **191**:1180–1187.
110. **Goldschmied-Reouven, A., A. Shvoron, M. Topaz, and C. Block.** 1989. *Saksenaia vasiformis* infection in a burn wound. *J. Med. Vet. Mycol.* **27**:427–429.
111. **Gómez-López, A., M. Cuenca-Estrella, E. Mellado, and J. L. Rodríguez-Tudela.** 2003. In vitro evaluation of combination of terbinafine with itraconazole or amphotericin B against Zygomycota. *Diagn. Microbiol. Infect. Dis.* **45**:199–202.
112. **Gómez-López, A., M. Cuenca-Estrella, A. Monzón, and J. L. Rodríguez-Tudela.** 2001. In vitro susceptibility of clinical isolates of Zygomycota to amphotericin B, flucytosine, itraconazole and voriconazole. *J. Antimicrob. Chemother.* **48**:919–921.
113. **Gois, G., and M. Starr.** 1997. Fatal rhino-orbital mucormycosis caused by *Saksenaia vasiformis* in an immunocompromised child. *Pediatr. Infect. Dis. J.* **16**:714–716.
114. **González, A., et al.** 1996. Zygomycosis: review of 16 cases. *Enferm. Infecc. Microbiol. Clin.* **14**:233–239.
115. **González, C., E. D. R. Couriel, and T. J. Walsh.** 1997. Disseminated zygomycosis in a neutropenic patient: successful treatment with amphotericin B lipid complex and granulocyte colony-stimulating factor. *Clin. Infect. Dis.* **24**:192–196.
116. **Goyal, A., I. Tyagi, R. S. S. Marak, and J. Singh.** 2007. *Apophysomyces elegans* causing acute otogenic cervicofacial zygomycosis involving salivary glands. *Med. Mycol.* **45**:457–461.
117. **Grinn-Gofroñ, A., A. Strzelczak, and T. Wolski.** 2011. The relationships between air pollutants, meteorological parameters and concentration of airborne fungal spores. *Environ. Pollut.* **159**:602–608.
- 117a. **Guarro, J., et al.** 2011. *Apophysomyces variabilis* infections in humans. *Emerg. Infect. Dis.* **17**:134–135. <http://www.cdc.gov/eid/content/17/1/pdfs/134.pdf>.
118. **Guembe, M., J. Guinea, T. Peláez, M. Torres-Narbona, and E. Bouza.** 2007. Synergistic effect of posaconazole and caspofungin against clinical Zygomycetes. *Antimicrob. Agents Chemother.* **51**:3457–3458.
119. **Guinea, J., T. Peláez, S. Recio, M. Torres-Narbona, and E. Bouza.** 2008. In vitro antifungal activities of isavuconazole (BAL4815), voriconazole, and fluconazole against 1,007 isolates of Zygomycetes, *Candida*, *Aspergillus*, *Fusarium*, and *Scedosporium* species. *Antimicrob. Agents Chemother.* **52**:1396–1400.
120. **Gutiérrez Díaz, A., A. del Palacio Hernanz, S. Larregla, and A. Sanz Lopez.** 1981. Orbital phycomycosis. *Ophthalmologica* **182**:165–170.
121. **Hameroff, S. B., J. W. Eckholdt, and R. Lindenberg.** 1970. Cerebral phycomycosis in a heroin addict. *Neurology* **20**:261–265.
122. **Hampson, F. G., E. J. Ridgway, K. Feeley, and J. T. Reilly.** 2005. A fatal case of disseminated zygomycosis associated with the use of blood glucose self-monitoring equipment. *J. Infect.* **51**:e269–e272.
123. **Han, S. R., C. Y. Choi, M. Joo, and C. J. Whang.** 2007. Isolated cerebral mucormycosis. *J. Korean Neurosurg. Soc.* **42**:400–402.
124. **Hashiguchi, K., et al.** 1997. A case of pulmonary zygomycosis caused by *Cunninghamella bertholletiae*. *Kansenshogaku Zasshi* **71**:264–268.
125. **Hata, D. J., S. P. Buckwalter, B. S. Pritt, G. D. Roberts, and N. L. Wen-**

- genack. 2008. Real-time PCR method for detection of Zygomycetes. *J. Clin. Microbiol.* **46**:2353–2358.
126. Hay, R. J. 2005. Mucormycosis: an infectious complication of traumatic injury. *Lancet* **365**:830–831.
 127. Hay, R. J., C. K. Campbell, W. M. Marshall, B. I. Rees, and J. Pincott. 1983. Disseminated zygomycosis (mucormycosis) caused by *Saksenaia vasiformis*. *J. Infect.* **7**:162–165.
 128. Hayden, R. T., X. Qian, G. W. Procop, G. D. Roberts, and R. V. Lloyd. 2002. In situ hybridization for the identification of filamentous fungi in tissue section. *Diagn. Mol. Pathol.* **11**:119–126.
 129. Henriksson, G., et al. 1997. Identification and retting efficiencies of fungi isolated from dew-retted flax in the United States and Europe. *Appl. Environ. Microbiol.* **63**:3950–3956.
 130. Hessian, P. A., and J. M. Smith. 1982. Antigenic characterization of some potentially pathogenic mucoraceous fungi. *Sabouraudia* **20**:209–216.
 131. Hibbett, D. S., et al. 2007. A higher-level phylogenetic classification of the Fungi. *Mycol. Res.* **111**:509–547.
 132. Hill, B. D., P. F. Black, M. Kelly, D. Muir, and W. A. McDonald. 1992. Bovine cranial zygomycosis caused by *Saksenaia vasiformis*. *Aust. Vet. J.* **69**:173–174.
 133. Hoffmann, K., S. Discher, and K. Voigt. 2007. Revision of the genus *Absidia* (*Mucorales*, Zygomycetes) based on physiological, phylogenetic, and morphological characters; thermotolerant *Absidia* spp. form a coherent group, *Mycocladaceae* fam. nov. *Mycol. Res.* **111**:1169–1183.
 134. Holland, J. 1997. Emerging zygomycoses of humans: *Saksenaia vasiformis* and *Apophysomyces elegans*. *Curr. Top. Med. Mycol.* **8**:27–34.
 135. Honda, A., et al. 1998. A murine model of zygomycosis by *Cunninghamella bertholletiae*. *Mycopathologia* **144**:141–146.
 136. Hopkins, R. J., M. Rothman, A. Fiore, and S. E. Goldblum. 1994. Cerebral mucormycosis associated with intravenous drug use: three case reports and review. *Clin. Infect. Dis.* **19**:1133–1137.
 137. Horan, T. C., M. Andrus, and M. A. Dudeck. 2008. CDC/NHSN surveillance definition of health care-associated infection and criteria for specific types of infections in the acute care setting. *Am. J. Infect. Control* **36**:309–332.
 138. Horner, W. E., A. G. Worthan, and P. R. Morey. 2004. Air- and dustborne mycoflora in houses free of water damage and fungal growth. *Appl. Environ. Microbiol.* **70**:6394–6400.
 139. Huffnagle, K. E., P. M. Southern, Jr., L. T. Byrd, and R. M. Gander. 1992. *Apophysomyces elegans* as an agent of zygomycosis in a patient following trauma. *J. Med. Vet. Mycol.* **30**:83–86.
 140. Hutter, R. V. 1959. Phycomycetous infection (mucormycosis) in cancer patients: a complication of therapy. *Cancer* **12**:330–350.
 141. Ibrahim, A. S., B. Spellberg, and J. Edwards, Jr. 2008. Iron acquisition: a novel perspective on mucormycosis pathogenesis and treatment. *Curr. Opin. Infect. Dis.* **21**:620–625.
 142. Institute of Medicine of the National Academy of Sciences. 2004. Damp indoor spaces and health. National Academy of Sciences, Washington, DC.
 143. Iwen, P. C., A. G. Freifeld, L. Sigler, and S. R. Tarantolo. 2005. Molecular identification of *Rhizomucor pusillus* as a cause of sinus-orbital zygomycosis in a patient with acute myelogenous leukemia. *J. Clin. Microbiol.* **43**:5819–5821.
 144. Jain, D., et al. 2006. Zygomycotic necrotizing fasciitis in immunocompetent patients: a series of 18 cases. *Mod. Pathol.* **19**:1221–1226.
 145. Jayasuriya, N. S., W. M. Tilakaratne, E. A. Amaratunga, and M. K. Ekanayake. 2006. An unusual presentation of rhinofacial zygomycosis due to *Cunninghamella* sp. in an immunocompetent patient: a case report and literature review. *Oral Dis.* **12**:67–69.
 146. John, B. V., G. Chamilos, and D. P. Kontoyiannis. 2005. Hyperbaric oxygen as an adjunctive treatment for zygomycosis. *Clin. Microbiol. Infect.* **11**:515–517.
 147. Kamalam, A., and A. S. Thambiah. 1980. Cutaneous infection by *Syncephalastrum*. *Sabouraudia* **18**:19–20.
 148. Kamei, K. 2001. Animal models of zygomycosis—*Absidia*, *Rhizopus*, *Rhizomucor*, and *Cunninghamella*. *Mycopathologia* **152**:5–13.
 149. Kasai, M., et al. 2008. Detection of a molecular biomarker for Zygomycetes by quantitative PCR assays of plasma, bronchoalveolar lavage, and lung tissue in a rabbit model of experimental pulmonary zygomycosis. *J. Clin. Microbiol.* **46**:3690–3702.
 150. Kaufman, L., A. A. Padhye, and S. Parker. 1988. Rhinocerebral zygomycosis caused by *Saksenaia vasiformis*. *J. Med. Vet. Mycol.* **26**:237–241.
 151. Kemna, M. E., R. C. Neri, R. Ali, and I. F. Salkin. 1994. *Cokeromyces recurvatus*, a mucoraceous zygomycete rarely isolated in clinical laboratories. *J. Clin. Microbiol.* **32**:843–845.
 152. Kerr, O. A., C. Bong, C. Wallis, and M. J. Tidman. 2004. Primary cutaneous mucormycosis masquerading as pyoderma gangrenosum. *Br. J. Dermatol.* **150**:1212–1213.
 153. Khan, Z. U., et al. 2008. *Actinomucor elegans* var. *kuwaitiensis* isolated from the wound of a diabetic patient. *Infection* **36**:343–352.
 154. Kiehn, T. E., F. Edwards, D. Armstrong, P. P. Rosen, and I. Weitzman. 1979. Pneumonia caused by *Cunninghamella bertholletiae* complicating chronic lymphatic leukemia. *J. Clin. Microbiol.* **10**:374–379.
 155. Kim, J., J. K. Fortson, and H. E. Cook. 2001. A fatal outcome from rhinocerebral mucormycosis after dental extractions: a case report. *J. Oral Maxillofac. Surg.* **59**:693–697.
 156. Kimura, M., M. B. Smith, and M. R. McGinnis. 1999. Zygomycosis due to *Apophysomyces elegans*: report of 2 cases and review of the literature. *Arch. Pathol. Lab. Med.* **123**:386–390.
 157. Kimura, M., et al. 2009. Isolation and identification of *Rhizomucor pusillus* from pleural zygomycosis in an immunocompetent patient. *Med. Mycol.* **47**:869–873.
 158. Kindo, A. J., et al. 2007. Fatal cellulitis caused by *Apophysomyces elegans*. *Indian J. Med. Microbiol.* **25**:285–287.
 159. Knudtson, W. U., and C. A. Kirkbride. 1992. Fungi associated with bovine abortion in the northern plains states (U. S. A.). *J. Vet. Diagn. Invest.* **4**:181–185.
 160. Kobayashi, M., et al. 2004. Molecular polymerase chain reaction diagnosis of pulmonary mucormycosis caused by *Cunninghamella bertholletiae*. *Respirology* **9**:397–401.
 161. Kolbeck, P. C., R. G. Makhoul, R. R. Bollinger, and F. Sanfilippo. 1985. Widely disseminated *Cunninghamella* mucormycosis in an adult renal transplant patient: case report and review of the literature. *Am. J. Clin. Pathol.* **83**:747–753.
 162. Kompoti, M., et al. 14 June 2010. Fatal cutaneous *Saksenaia vasiformis* infection in a critically ill trauma patient. *Mycoses* doi:10.1111/j.1439-0507.2010.01902.x.
 163. Kondori, N., E. Svensson, and I. Mattsby-Baltzer. 14 June 2010. In vitro susceptibility of filamentous fungi to itraconazole, voriconazole and posaconazole by Clinical and Laboratory Standards Institute reference method and E-test. *Mycoses* doi:10.1111/j.1439-0507.2010.01913.x.
 164. Kontoyiannis, D. P., et al. 1994. Infections due to *Cunninghamella bertholletiae* in patients with cancer: report of three cases and review. *Clin. Infect. Dis.* **18**:925–928.
 165. Kontoyiannis, D. P., et al. 2007. Increased culture recovery of Zygomycetes under physiologic temperature conditions. *Am. J. Clin. Pathol.* **127**:208–212.
 166. Kontoyiannis, D. P., and R. E. Lewis. 2010. Agents of mucormycosis and entomophthoromycosis, p. 3257–3270. In G. L. Mandell, J. E. Bennett, and R. Dolin (ed.), Principles and practice of infectious diseases, 7th ed. Churchill Livingstone Elsevier, Philadelphia, PA.
 167. Kontoyiannis, D. P., and R. E. Lewis. 2006. Invasive zygomycosis: update on pathogenesis, clinical manifestations, and management. *Infect. Dis. Clin. North Am.* **20**:581–607.
 168. Kontoyiannis, D. P., et al. 2005. Zygomycosis in a tertiary-care cancer center in the era of *Aspergillus*-active antifungal therapy: a case-control observational study of 27 recent cases. *J. Infect. Dis.* **191**:1350–1360.
 169. Kontoyiannis, D. P., V. C. Wessel, G. P. Bodey, and K. V. Rolston. 2000. Zygomycosis in the 1990s in a tertiary-care cancer center. *Clin. Infect. Dis.* **30**:851–856.
 170. Kordy, F. N., et al. 2004. Successful treatment of a child with posttraumatic necrotizing fasciitis caused by *Apophysomyces elegans*: case report and review of literature. *Pediatr. Infect. Dis. J.* **23**:877–879.
 171. Koren, G., I. Polacheck, and H. Kaplan. 1986. Invasive mucormycosis in a non-immunocompromised patient. *J. Infect.* **12**:165–167.
 172. Koyama, N., M. Nagata, K. Hagiwara, and M. Kanazawa. 2008. Survival of a patient with pulmonary *Cunninghamella bertholletiae* infection without surgical intervention. *Respirology* **13**:309–311.
 173. Kramer, B. S., A. D. Hernandez, R. L. Reddick, and A. S. Levine. 1977. Cutaneous infarction. Manifestation of disseminated mucormycosis. *Arch. Dermatol.* **113**:1075–1076.
 174. Krishna, G., A. Sansone-Parsons, M. Martinho, B. Kantesaria, and L. Pedicone. 2007. Posaconazole plasma concentrations in juvenile patients with invasive fungal infection. *Antimicrob. Agents Chemother.* **51**:812–818.
 175. Kurakov, A. V., R. B. Lavrent'ev, T. Nechitailo, P. N. Golyshin, and D. G. Zviagintsev. 2008. Diversity of facultatively anaerobic microscopic mycelial fungi in soils. *Mikrobiologiya* **77**:103–112.
 176. Kwon-Chung, K. J., R. C. Young, and M. Orlando. 1975. Pulmonary mucormycosis caused by *Cunninghamella elegans* in a patient with chronic myelogenous leukemia. *Am. J. Clin. Pathol.* **64**:544–548.
 177. Lackner, A., et al. 2005. Fungi: a normal content of human nasal mucus. *Am. J. Rhinol.* **19**:125–129.
 178. Lakshmi, V., et al. 1993. Zygomycotic necrotizing fasciitis caused by *Apophysomyces elegans*. *J. Clin. Microbiol.* **31**:1368–1369.
 179. Lamaris, G. A., et al. 2009. Increased virulence of Zygomycetes organisms following exposure to voriconazole: a study involving fly and murine models of zygomycosis. *J. Infect. Dis.* **199**:1399–1406.
 180. Larché, J., et al. 2005. Diagnosis of cutaneous mucormycosis due to *Rhizopus microsporus* by an innovative PCR-restriction fragment-length polymorphism method. *Clin. Infect. Dis.* **41**:1362–1365.
 181. Larone, D. H. 2002. Medically important fungi. A guide to identification, 4th ed. ASM Press, Washington, DC.
 182. Lass-Flörl, C. 2009. Zygomycosis: conventional laboratory diagnosis. *Clin. Microbiol. Infect.* **15**(Suppl. 5):60–65.
 183. Lass-Flörl, C., et al. 2008. Activities of antifungal agents against yeasts and

- filamentous fungi: assessment according to the methodology of the European Committee on Antimicrobial Susceptibility Testing. *Antimicrob. Agents Chemother.* **52**:3637–3641.
184. Lawrence, R. M., et al. 1986. Systemic zygomycosis caused by *Apophysomyces elegans*. *J. Med. Vet. Mycol.* **24**:57–65.
 185. Lechevalier, P., et al. 2008. Molecular diagnosis of *Saksenaeva vasiformis* cutaneous infection after scorpion sting in an immunocompetent adolescent. *J. Clin. Microbiol.* **46**:3169–3172.
 186. Lemmer, K., et al. 2002. Molecular biological identification of *Cunninghamella* spec. *Mycoses* **45**(Suppl. 1):31–36.
 187. LeSueur, B. W., K. Warschaw, and L. Fredrikson. 2002. Necrotizing cellulitis caused by *Apophysomyces elegans* at a patch test site. *Am. J. Contact Dermat.* **13**:140–142.
 188. Lewis, R. E., et al. 2010. Comparative pharmacodynamics of amphotericin B lipid complex and liposomal amphotericin B in a murine model of pulmonary mucormycosis. *Antimicrob. Agents Chemother.* **54**:1298–1304.
 189. Lewis, R. E., et al. 18 October 2010. Activity of deferasirox in *Mucorales*: influence of species and exogenous iron. *Antimicrob. Agents Chemother.* doi:10.1128/AAC.00792-10.
 190. Liang, K. P., I. M. Tleyjeh, W. R. Wilson, G. D. Roberts, and Z. Temesgen. 2006. Rhino-orbito-cerebral mucormycosis caused by *Apophysomyces elegans*. *J. Clin. Microbiol.* **44**:892–898.
 191. Linares, M. J., et al. 2005. Susceptibility of filamentous fungi to voriconazole tested by two microdilution methods. *J. Clin. Microbiol.* **43**:250–253.
 192. Lionakis, M. S., and D. P. Kontoyiannis. 2003. Glucocorticoids and invasive fungal infections. *Lancet* **362**:1828–1838.
 193. Lionakis, M. S., and D. P. Kontoyiannis. 2004. The significance of isolation of saprophytic molds from the lower respiratory tract in patients with cancer. *Cancer* **100**:165–172.
 194. Lombardi, G., A. A. Padhye, P. G. Standard, L. Kaufman, and L. Ajello. 1989. Exoantigen tests for the rapid and specific identification of *Apophysomyces elegans* and *Saksenaeva vasiformis*. *J. Med. Vet. Mycol.* **27**:113–120.
 195. Lozano, F., E. Martín, P. Jiménez, E. Hidalgo, and A. Robles. 1999. Necrotizing cellulitis of the hand and forearm in a hospitalized diabetic patient. *Enferm. Infecc. Microbiol. Clin.* **17**:37–38.
 196. Lu, X. L., et al. 2009. Primary cutaneous zygomycosis caused by *Rhizomucor variabilis*: a new endemic zygomycosis? A case report and review of 6 cases reported from China. *Clin. Infect. Dis.* **49**:e39–e43.
 197. Lucet, A., and J. Constantin. 1901. Contributions à l'étude des mucorinées pathologiques. *Arch. Parasitol.* **4**:362–408.
 198. Lukács, G., T. Papp, I. Nyilasi, E. Nagy, and C. Vágvolgyi. 2004. Differentiation of *Rhizomucor* species on the basis of their different sensitivities to lovastatin. *J. Clin. Microbiol.* **42**:5400–5402.
 199. Lye, G. R., G. Wood, and G. Nimmo. 1996. Subcutaneous zygomycosis due to *Saksenaeva vasiformis*: rapid isolate identification using a modified sporulation technique. *Pathology* **28**:364–365.
 200. Ma, B., J. F. Seymour, H. Januszewicz, and M. A. Slavin. 2001. Cure of pulmonary *Rhizomucor pusillus* infection in a patient with hairy-cell leukemia: role of liposomal amphotericin B and GM-CSF. *Leuk. Lymphoma* **42**:1393–1399.
 201. Machouart, M., et al. 2006. Genetic identification of the main opportunistic *Mucorales* by PCR-restriction fragment length polymorphism. *J. Clin. Microbiol.* **44**:805–810.
 202. Maghazy, S. M., A. Y. Abdel-Mallek, and M. M. Bagy. 1989. Fungi in two swimming pools in Assiut town, Egypt. *Zentralbl. Mikrobiol.* **144**:213–216.
 203. Maloïsel, F., et al. 1991. *Cunninghamella bertholletiae*: an uncommon agent of opportunistic fungal infection. Case report and review. *Nouv. Rev. Fr. Hematol.* **33**:311–315.
 204. Marak, R. S., et al. 1 April 2010. Successful medical management of renal zygomycosis: a summary of two cases and a review of the Indian literature. *Med. Mycol.* doi:10.3109/13693781003753477.
 205. Mathews, M. S., A. Raman, and A. Nair. 1997. Nosocomial zygomycotic post-surgical necrotizing fasciitis in a healthy adult caused by *Apophysomyces elegans* in south India. *J. Med. Vet. Mycol.* **35**:61–63.
 206. Mayayo, E., C. Klock, and L. Goldani. 24 January 2009. Thyroid involvement in disseminated zygomycosis by *Cunninghamella bertholletiae*: 2 cases and literature review. *Int. J. Surg. Pathol.* doi:10.1177/1066896908329595.
 207. Mazade, M. A., J. F. Margolin, S. N. Rossmann, and M. S. Edwards. 1998. Survival from pulmonary infection with *Cunninghamella bertholletiae*: case report and review of the literature. *Pediatr. Infect. Dis. J.* **17**:835–839.
 208. McGinnis, M. R., J. Midez, L. Pasarell, and A. Haque. 1993. Necrotizing fasciitis caused by *Apophysomyces elegans*. *J. Mycol. Med.* **3**:175–179.
 209. McGinnis, M. R., D. H. Walker, I. E. Dominy, and W. Kaplan. 1982. Zygomycosis caused by *Cunninghamella bertholletiae*: clinical and pathologic aspects. *Arch. Pathol. Lab. Med.* **106**:282–286.
 210. McGough, D. A., A. W. Fothergill, and M. G. Rinaldi. 1990. *Cokeromyces recurvatus* Poitras, a distinctive zygomycete and potential pathogen: criteria for identification. *Clin. Microbiol. Newsl.* **12**:113–117.
 211. Mehta, N. N., J. Romanelli, and M. G. Sutton. 2004. Native aortic valve vegetative endocarditis with *Cunninghamella*. *Eur. J. Echocardiogr.* **5**:156–158.
 212. Meis, J. F., B. J. Kullberg, M. Pruszczyński, and R. P. Veth. 1994. Severe osteomyelitis due to the zygomycete *Apophysomyces elegans*. *J. Clin. Microbiol.* **32**:3078–3081.
 213. Meyer, R. D., M. H. Kaplan, M. Ong, and D. Armstrong. 1973. Cutaneous lesions in disseminated mucormycosis. *JAMA* **225**:737–738.
 214. Mirza, J. H., S. M. Khan, S. Begum, and S. Shaguffa. 1979. *Mucorales* of Pakistan. University of Agriculture, Faisalabad, Pakistan.
 215. Misra, P. C., K. J. Srivastva, and K. Lata. 1979. *Apophysomyces*, a new genus of the *Mucorales*. *Mycotaxon* **8**:377–382.
 216. Mori, T., et al. 2003. Zygomycosis: two case reports and review of reported cases in the literature in Japan. *Nippon Ishinkin Gakkai Zasshi* **44**:163–179.
 217. Mostaza, J. M., F. J. Barbado, J. Fernandez-Martin, J. Peña-Yañez, and J. J. Vazquez-Rodriguez. 1989. Cutaneous mucormycosis due to *Cunninghamella bertholletiae* in a patient with AIDS. *Rev. Infect. Dis.* **11**:316–318.
 218. Motohashi, K., et al. 2009. Cutaneous zygomycosis caused by *Cunninghamella bertholletiae* in a patient with chronic myelogenous leukemia in blast crisis. *Am. J. Hematol.* **84**:447–448.
 219. Munipalli, B., M. G. Rinaldi, and S. B. Greenberg. 1996. *Cokeromyces recurvatus* isolated from pleural and peritoneal fluid: case report. *J. Clin. Microbiol.* **34**:2601–2603.
 220. Murray, P. R., and F. G. Witesbsky. 2010. The clinician and the microbiology laboratory, p. 233–266. In G. L. Mandell, J. E. Bennett, and R. Dolin (ed.), *Principles and practice of infectious diseases*, 7th ed. Churchill Livingstone Elsevier, Philadelphia, PA.
 221. Naguib, M. T., et al. 1995. *Apophysomyces elegans* infection in a renal transplant recipient. *Am. J. Kidney Dis.* **26**:381–384.
 222. Naumann, R., M. L. Kerkmann, U. Schuler, W. G. Daniel, and G. Ehninger. 1999. *Cunninghamella bertholletiae* infection mimicking myocardial infarction. *Clin. Infect. Dis.* **29**:1580–1581.
 223. Newton, W. D., F. S. Cramer, and S. H. Norwood. 1987. Necrotizing fasciitis from invasive Phycomyces. *Crit. Care Med.* **15**:331–332.
 224. Ng, T. T., et al. 1994. Successful treatment of sinusitis caused by *Cunninghamella bertholletiae*. *Clin. Infect. Dis.* **19**:313–316.
 225. Nicod, J. L., C. Fleury, and J. Schlegel. 1952. Mixed micotic infection of the lungs with *Aspergillus fumigatus* Fres. and *Mucor pusillus* Lindt. *Schweiz. Z. Pathol. Bakteriell.* **15**:307–321.
 226. Nielsen, C., D. A. Sutton, I. Matise, N. Kirchhof, and M. C. Libal. 2005. Isolation of *Cokeromyces recurvatus*, initially misidentified as *Coccidioides immitis*, from peritoneal fluid in a cat with jejunal perforation. *J. Vet. Diagn. Invest.* **17**:372–378.
 227. Nimmo, G. R., R. F. Whiting, and R. W. Strong. 1988. Disseminated mucormycosis due to *Cunninghamella bertholletiae* in a liver transplant recipient. *Postgrad. Med. J.* **64**:82–84.
 228. Noble, W. C., and Y. M. Clayton. 1963. Fungi in the air of hospital wards. *J. Gen. Microbiol.* **32**:397–402.
 229. Nyilasi, L., et al. 2008. High-affinity iron permease (FTR1) gene sequence-based molecular identification of clinically important Zygomycetes. *Clin. Microbiol. Infect.* **14**:393–397.
 230. Oberle, A. D., and R. L. Penn. 1983. Nosocomial invasive *Saksenaeva vasiformis* infection. *Am. J. Clin. Pathol.* **80**:885–888.
 231. Ogundero, V. W. 1979. Thermophilic and thermotolerant fungi in poultry droppings in Nigeria. *J. Gen. Microbiol.* **115**:253–254.
 232. Ogundero, V. W., and J. O. Aina. 1989. Storage temperature and viability of sporangiospores of potentially human pathogenic species of *Rhizomucor* from Nigerian tobacco. *J. Basic Microbiol.* **29**:171–175.
 233. Ogunlana, E. O. 1975. Fungal air spora at Ibadan, Nigeria. *Appl. Microbiol.* **29**:458–463.
 234. Okhuysen, P. C., J. H. Rex, M. Kapusta, and C. Fife. 1994. Successful treatment of extensive posttraumatic soft-tissue and renal infections due to *Apophysomyces elegans*. *Clin. Infect. Dis.* **19**:329–331.
 235. Ortega, J., et al. 2010. Zygomycotic lymphadenitis in slaughtered feedlot cattle. *Vet. Pathol.* **47**:108–115.
 236. Ortin, X., et al. 2004. *Cunninghamella bertholletiae* infection (mucormycosis) in a patient with acute T-cell lymphoblastic leukemia. *Leuk. Lymphoma* **45**:617–620.
 237. Ostrosky-Zeichner, L., and J. H. Rex. 2004. Filamentous fungi, p. 705–708. In C. G. Mayhall (ed.), *Hospital epidemiology and infection control*, 3rd ed. Lippincott Williams & Wilkins, Philadelphia, PA.
 238. Otčenásek, M., and V. Buchta. 1994. In vitro susceptibility to 9 antifungal agents of 14 strains of Zygomycetes isolated from clinical specimens. *Mycopathologia* **128**:135–137.
 239. Padhye, A. A., and L. Ajello. 1988. Simple method of inducing sporulation by *Apophysomyces elegans* and *Saksenaeva vasiformis*. *J. Clin. Microbiol.* **26**:1861–1863.
 240. Padhye, A. A., et al. 1988. First case of subcutaneous zygomycosis caused by *Saksenaeva vasiformis* in India. *Diagn. Microbiol. Infect. Dis.* **9**:69–77.
 241. Padmaja, I. J., T. V. Ramani, and S. Kalyani. 2006. Cutaneous zygomycosis: necrotising fasciitis due to *Saksenaeva vasiformis*. *Indian J. Med. Microbiol.* **24**:58–60.
 242. Pagano, L., B. Gleissner, and L. Fianchi. 2005. Breakthrough zygomycosis and voriconazole. *J. Infect. Dis.* **192**:1496–1497.

243. Pagano, L., et al. 2004. Mucormycosis in hematologic patients. *Haematologica* 89:207–214.
244. Pagano, L., C. G. Valentini, M. Caira, and L. Fianchi. 2009. Zygomycosis: current approaches to management of patients with hematological malignancies. *Br. J. Haematol.* 146:597–606.
245. Pagano, L., C. G. Valentini, L. Fianchi, and M. Caira. 2009. The role of neutrophils in the development and outcome of zygomycosis in hematological patients. *Clin. Microbiol. Infect.* 15(Suppl. 5):33–36.
246. Page, R., D. J. Gardam, and C. H. Heath. 2001. Severe cutaneous mucormycosis (Zygomycosis) due to *Apophysomyces elegans*. *ANZ J. Surg.* 71:184–186.
247. Panackal, A. A., et al. 2010. Geoclimatic influences on invasive aspergillosis after hematopoietic stem cell transplantation. *Clin. Infect. Dis.* 50:1588–1597.
248. Pandian, J. D., J. S. McCarthy, T. Goldschlager, T. Robertson, and R. D. Henderson. 2007. Rhizomycosis infection in the basal ganglia. *Arch. Neurol.* 64:134–135.
249. Reference deleted.
250. Parker, C., G. Kaminski, and D. Hill. 1986. Zygomycosis in a tattoo, caused by *Saksenaia vasiformis*. *Australas. J. Dermatol.* 27:107–111.
251. Passos, X. S., et al. 2006. Nosocomial invasive infection caused by *Cunninghamella bertholletiae*: case report. *Mycopathologia* 161:33–35.
252. Pastor, F. J., et al. 19 August 2010. In vitro and in vivo antifungal susceptibilities of the mucoralean fungus *Cunninghamella*. *Antimicrob. Agents Chemother.* doi:10.1128/AAC.00786-10.
253. Patiño, J. F., R. Mora, M. A. Guzmán, and E. Rodríguez-Franco. 1984. Mucormycosis: a fatal case by *Saksenaia vasiformis*. *World J. Surg.* 8:419–422.
254. Patterson, J. E., A. Zidouh, P. Minitier, V. T. Andriole, and T. F. Patterson. 1997. Hospital epidemiologic surveillance for invasive aspergillosis: patient demographics and the utility of antigen detection. *Infect. Control Hosp. Epidemiol.* 18:104–108.
255. Paul, S., F. M. Marty, and Y. L. Colson. 2006. Treatment of cavitary pulmonary zygomycosis with surgical resection and posaconazole. *Ann. Thorac. Surg.* 82:338–340.
256. Pavlović, M. D., and N. Bulajić. 2006. Great toenail onychomycosis caused by *Syncephalastrum racemosum*. *Dermatol. Online J.* 12:17.
257. Perkhofer, S., V. Lechner, and C. Lass-Flörl. 2009. In vitro activity of isavuconazole against *Aspergillus* species and Zygomycetes according to the methodology of the European Committee on Antimicrobial Susceptibility Testing. *Antimicrob. Agents Chemother.* 53:1645–1647.
258. Perkhofer, S., et al. 2008. Posaconazole enhances the activity of amphotericin B against hyphae of Zygomycetes in vitro. *Antimicrob. Agents Chemother.* 52:2636–2638.
259. Peter, E., F. Bakri, D. M. Ball, R. T. Cheney, and B. H. Segal. 2002. Invasive pulmonary filamentous fungal infection in a patient receiving inhaled corticosteroid therapy. *Clin. Infect. Dis.* 35:e54–e56.
260. Piao, Y. S., Y. Zhang, X. Yang, C. Y. He, and H. G. Liu. 2008. The use of MUC5B antibody in identifying the fungal type of fungal sinusitis. *Hum. Pathol.* 39:650–656.
261. Pierce, P. F., et al. 1987. *Saksenaia vasiformis* osteomyelitis. *J. Clin. Microbiol.* 25:933–935.
262. Pimentel, J. D., G. Dreyer, and G. D. Lum. 2006. Peritonitis due to *Cunninghamella bertholletiae* in a patient undergoing continuous ambulatory peritoneal dialysis. *J. Med. Microbiol.* 55:115–118.
263. Pongas, G. N., R. Ben-Ami, R. E. Lewis, T. J. Walsh, and D. P. Kontoyiannis. 2009. Culture medium composition affects the lethality of *Cunninghamella bertholletiae* in a fly model of mucormycosis. *Antimicrob. Agents Chemother.* 53:4569.
264. Pongas, G. N., R. E. Lewis, G. Samonis, and D. P. Kontoyiannis. 2009. Voriconazole-associated zygomycosis: a significant consequence of evolving antifungal prophylaxis and immunosuppression practices? *Clin. Microbiol. Infect.* 15(Suppl. 5):93–97.
265. Prabhu, R. M., and R. Patel. 2004. Mucormycosis and entomophthoromycosis: a review of the clinical manifestations, diagnosis and treatment. *Clin. Microbiol. Infect.* 10(Suppl. 1):31–47.
266. Pritchard, R. C., D. B. Muir, K. H. Archer, and J. M. Beith. 1986. Subcutaneous zygomycosis due to *Saksenaia vasiformis* in an infant. *Med. J. Aust.* 145:630–631.
267. Quinio, D., et al. 2004. Zygomycosis caused by *Cunninghamella bertholletiae* in a kidney transplant recipient. *Med. Mycol.* 42:177–180.
268. Radner, A. B., M. D. Witt, and J. E. Edwards, Jr. 1995. Acute invasive rhinocerebral zygomycosis in an otherwise healthy patient: case report and review. *Clin. Infect. Dis.* 20:163–166.
269. Rainer, J., U. Peintner, and R. Pöder. 2001. Biodiversity and concentration of airborne fungi in a hospital environment. *Mycopathologia* 149:87–97.
270. Ramani, R., et al. 2000. *Cokeromyces recurvatus* as a human pathogenic fungus: case report and critical review of the published literature. *Pediatr. Infect. Dis. J.* 19:155–158.
271. Ramesh, V. M., et al. 25 February 2010. Subcutaneous zygomycosis: report of 10 cases from two institutions in North India. *J. Eur. Acad. Dermatol. Venereol.* doi:10.1111/j.1468-3083.2010.03606.x.
272. Rao, C. Y., et al. 2007. Implications of detecting the mold *Syncephalastrum* in clinical specimens of New Orleans residents after Hurricanes Katrina and Rita. *J. Occup. Environ. Med.* 49:411–416.
273. Rao, C. Y., et al. 2007. Characterization of airborne molds, endotoxins, and glucans in homes in New Orleans after Hurricanes Katrina and Rita. *Appl. Environ. Microbiol.* 73:1630–1634.
274. Ravise, P., H. Fromentin, P. Destombes, and F. Mariat. 1978. Cerebral mucormycosis in the cat caused by *Mucor pusillus*. *Sabouraudia* 16:291–298.
275. Reddy, I. S., N. R. Rao, V. M. Shankar Reddy, and R. Rao. 2008. Primary cutaneous mucormycosis (zygomycosis) caused by *Apophysomyces elegans*. *Indian J. Dermatol. Venereol. Leprol.* 74:367–370.
276. Reed, A. E., B. A. Body, M. B. Austin, and H. F. Frierson, Jr. 1988. *Cunninghamella bertholletiae* and *Pneumocystis carinii* pneumonia as a fatal complication of chronic lymphocytic leukemia. *Hum. Pathol.* 19:1470–1472.
277. Reinhardt, D. J., et al. 1981. Experimental cerebral zygomycosis in alloxan-diabetic rabbits: variation in virulence among Zygomycetes. *Sabouraudia* 19:245–256.
278. Rex, J. H., A. M. Ginsberg, L. F. Fries, H. I. Pass, and K. J. Kwon-Chung. 1988. *Cunninghamella bertholletiae* infection associated with deferroxamine therapy. *Rev. Infect. Dis.* 10:1187–1194.
279. Ribes, J. A., C. L. Vanover-Sams, and D. J. Baker. 2000. Zygomycetes in human disease. *Clin. Microbiol. Rev.* 13:236–301.
280. Richardson, M. 2009. The ecology of the Zygomycetes and its impact on environmental exposure. *Clin. Microbiol. Infect.* 15(Suppl. 5):2–9.
281. Rickerts, V., et al. 2006. Successful treatment of disseminated mucormycosis with a combination of liposomal amphotericin B and posaconazole in a patient with acute myeloid leukaemia. *Mycoses* 49(Suppl. 1):27–30.
282. Rickerts, V., et al. 2000. Cluster of pulmonary infections caused by *Cunninghamella bertholletiae* in immunocompromised patients. *Clin. Infect. Dis.* 31:910–913.
283. Righi, E., et al. 2008. A case of *Cunninghamella bertholletiae* rhino-cerebral infection in a leukaemic patient and review of recent published studies. *Mycopathologia* 165:407–410.
284. Rippon, J. W., and C. T. Dolan. 1979. Colonization of the vagina by fungi of the genus *Mucor*. *Clin. Microbiol. Newsl.* 1:4–5.
285. Robeck, T. R., and L. M. Dalton. 2002. *Saksenaia vasiformis* and *Apophysomyces elegans* zygomycotic infections in bottlenose dolphins (*Tursiops truncatus*), a killer whale (*Orcinus orca*), and Pacific white-sided dolphins (*Lagenorhynchus obliquidens*). *J. Zoo Wildl. Med.* 33:356–366.
286. Robinson, B. E., M. T. Stark, T. L. Pope, F. M. Stewart, and G. R. Donowitz. 1990. *Cunninghamella bertholletiae*: an unusual agent of zygomycosis. *South. Med. J.* 83:1088–1091.
287. Roden, M. M., et al. 2005. Epidemiology and outcome of mucormycosis: a review of 929 reported cases. *Clin. Infect. Dis.* 41:634–653.
288. Rodriguez, M. M., et al. 2010. Correlation between in vitro activity of posaconazole and in vivo efficacy against *Rhizopus oryzae* infection in mice. *Antimicrob. Agents Chemother.* 54:1665–1669.
289. Rodriguez-Romero, J., M. Hedtke, C. Kastner, S. Müller, and R. Fischer. 2010. Fungi, hidden in soil or up in the air: light makes a difference. *Annu. Rev. Microbiol.* 64:585–610.
290. Rolandi, L., L. Lodola, M. Guglielminetti, G. Caretta, and G. Azzaretti. 1998. Evaluation of airborne particulate and fungi in critical hospital care units. *Toxicol. Lett.* 95:226.
291. Ruiz, C. E., M. Arango, A. L. Correa, L. S. López, and A. Restrepo. 2004. Necrotizing fasciitis in an immunocompetent patient caused by *Apophysomyces elegans*. *Biomedica* 24:239–251.
292. Rüping, M. J., et al. 2010. Forty-one recent cases of invasive zygomycosis from a global clinical registry. *J. Antimicrob. Chemother.* 65:296–302.
293. Ryan, L. J., P. Ferrieri, R. Powell, S. Zeki, and S. Pambuccian. 14 January 2009. Fatal *Cokeromyces recurvatus* pneumonia: report of a case highlighting the potential for histopathologic misdiagnosis as *Coccidioides*. *Int. J. Surg. Pathol.* doi:10.1177/1066896908330483.
294. Ryan, M. E., D. Ochs, and J. Ochs. 1982. Primary cutaneous mucormycosis: superficial and gangrenous infections. *Pediatr. Infect. Dis.* 1:110–114.
295. Saksena, S. B. 1953. A new genus of the *Mucorales*. *Mycologia* 45:426–436.
296. Sands, J. M., A. M. Macher, T. J. Ley, and A. W. Nienuis. 1985. Disseminated infection caused by *Cunninghamella bertholletiae* in a patient with beta-thalassemia. Case report and review of the literature. *Ann. Intern. Med.* 102:59–63.
297. Saoulidis, S. M., et al. 29 October 2010. Antifungal activity of posaconazole and granulocyte colony-stimulating factor in the treatment of disseminated zygomycosis (mucormycosis) in a neutropenic murine model. *Mycoses* doi:10.1111/j.1439-0507.2010.01958.x.
298. Saravia-Flores, M., D. M. Guaran, and V. Argueta. 2010. Invasive cutaneous infection caused by *Apophysomyces elegans* associated with a spider bite. *Mycoses* 53:259–261.
299. Schell, W. A., M. G. Johnson, M. R. McGinnis, I. Weitzman, and M. Y. Crist. 1982. Zygomycosis caused by *Cunninghamella bertholletiae*: mycologic aspects. *Arch. Pathol. Lab. Med.* 106:287–291.
300. Schipper, M. A. A. 1978. On the genera *Rhizomucor* and *Parasitella*. *Stud. Mycol.* 17:52–71.
301. Schleich, S., and D. F. Look. 2005. Intra-abdominal zygomycosis caused

- by *Syncephalastrum racemosum* infection successfully treated with partial surgical debridement and high-dose amphotericin B lipid complex. *J. Clin. Microbiol.* **43**:5825–5827.
302. **Dhinger, A., and J. Schnürer.** 2006. Fungal survival during anaerobic digestion of organic household waste. *Waste Manag.* **26**:1205–1211.
303. **Schostakowitsch, W.** 1898. *Actinomyces repens* n. g. n. sp. *Ber. Dtsch. Bot. Ges.* **16**:155–158.
304. **Schütz, P., et al.** 2006. Fatal rhino-orbito-cerebral zygomycosis caused by *Apophysomyces elegans* in a healthy patient. *J. Oral Maxillofac. Surg.* **64**:1795–1802.
305. **Schwarz, P., et al.** 2006. Molecular identification of Zygomycetes from culture and experimentally infected tissues. *J. Clin. Microbiol.* **44**:340–349.
306. **Schwarz, P., O. Lortholary, F. Dromer, and E. Dannaoui.** 2007. Carbon assimilation profiles as a tool for identification of Zygomycetes. *J. Clin. Microbiol.* **45**:1433–1439.
307. **Sdralis, T., S. Krishnan, and J. Holland.** 1997. “Martini glass” mucormycosis-*Apophysomyces elegans* infection in an immune competent host. *Aust. J. Otolaryngol.* **2**:600–602.
308. **Severo, L. C., F. Job, and T. C. Mattos.** 1991. Systemic zygomycosis: nosocomial infection by *Rhizomucor pusillus*. *Mycopathologia* **113**:79–80.
309. **Shanor, L., A. W. Poitras, and R. K. Benjamin.** 1950. A new genus of the *Choanephoraceae*. *Mycologia* **42**:271–278.
310. **Shelton, B. G., K. H. Kirkland, W. D. Flanders, and G. K. Morris.** 2002. Profiles of airborne fungi in buildings and outdoor environments in the United States. *Appl. Environ. Microbiol.* **68**:1743–1753.
311. **Simitsopoulou, M., E. Georgiadou, T. J. Walsh, and E. Roilides.** 2010. *Cunninghamella bertholletiae* exhibits increased resistance to human neutrophils with or without antifungal agents as compared to *Rhizopus* spp. *Med. Mycol.* **48**:720–724.
312. **Singh, J., D. Rimek, and R. Kappe.** 2005. In vitro susceptibility of 15 strains of Zygomycetes to nine antifungal agents as determined by the NCCLS M38-A microdilution method. *Mycoses* **48**:246–250.
313. **Sivakumar, S., M. S. Mathews, and B. George.** 2005. *Cunninghamella* pneumonia in post-bone marrow transplant patient: first case report from India. *Mycoses* **48**:360–362.
314. **Skiaida, A. L., et al.** 2 January 2011. Zygomycosis in Europe: analysis of 230 cases accrued by the registry of the European Confederation of Medical Mycology (ECMM) Working Group on Zygomycosis between 2005 and 2007. *Clin. Microbiol. Infect.* doi:10.1111/j.1469-0691.2010.03456.x.
315. **Snell, B. J., and K. Tavakoli.** 2007. Necrotizing fasciitis caused by *Apophysomyces elegans* complicating soft-tissue and pelvic injuries in a tsunami survivor from Thailand. *Plast. Reconstr. Surg.* **119**:448–449.
316. **Solano, T., B. Atkins, E. Tambosis, S. Mann, and T. Gottlieb.** 2000. Disseminated mucormycosis due to *Saksenaia vasiformis* in an immunocompetent adult. *Clin. Infect. Dis.* **30**:942–943.
317. **Spellberg, B., T. J. Walsh, D. P. Kontoyiannis, J. Edwards, Jr., and A. S. Ibrahim.** 2009. Recent advances in the management of mucormycosis: from bench to bedside. *Clin. Infect. Dis.* **48**:1743–1751.
318. **Sridhara, S. R., G. Paragache, N. K. Panda, and A. Chakrabarti.** 2005. Mucormycosis in immunocompetent individuals: an increasing trend. *J. Otolaryngol.* **34**:402–406.
319. **Stewardson, A. J., N. E. Holmes, D. H. Ellis, and B. P. Howden.** 2009. Cutaneous zygomycosis caused by *Saksenaia vasiformis* following water-related wound in a 24-year-old immunocompetent woman. *Mycoses* **52**:547–549.
320. **St-Germain, G., A. Robert, M. Ishak, C. Tremblay, and S. Claveau.** 1993. Infection due to *Rhizomucor pusillus*: report of four cases in patients with leukemia and review. *Clin. Infect. Dis.* **16**:640–645.
321. **Sun, Q. N., A. W. Fothergill, D. I. McCarthy, M. G. Rinaldi, and J. R. Graybill.** 2002. In vitro activities of posaconazole, itraconazole, voriconazole, amphotericin B, and fluconazole against 37 clinical isolates of Zygomycetes. *Antimicrob. Agents Chemother.* **46**:1581–1582.
322. **Suryanarayan Rao, S., N. K. Panda, G. Pragache, A. Chakrabarti, and K. Saravanan.** 2006. Sinoorbital mucormycosis due to *Apophysomyces elegans* in immunocompetent individuals—an increasing trend. *Am. J. Otolaryngol.* **27**:366–369.
323. **Tajdini, F., M. A. Amini, N. Nafissi-Varcheh, and M. A. Faramarzi.** 2010. Production, physicochemical and antimicrobial properties of fungal chitosan from *Rhizomucor miehei* and *Mucor racemosus*. *Int. J. Biol. Macromol.* **47**:180–183.
324. **Talwar, P., et al.** 1988. Fungal infections of ear with special reference to chronic suppurative otitis media. *Mycopathologia* **104**:47–50.
325. **Tanabe, Y., M. Saikawa, M. M. Watanabe, and J. Sugiyama.** 2004. Molecular phylogeny of Zygomycota based on EF-1 α and RPB1 sequences: limitations and utility of alternative markers to rDNA. *Mol. Phylogenet. Evol.* **30**:438–449.
326. **Tanphaichitr, V. S., A. Chaiprasert, V. Suvatte, and P. Thasnakorn.** 1990. Subcutaneous mucormycosis caused by *Saksenaia vasiformis* in a thalassaemic child: first case report in Thailand. *Mycoses* **33**:303–309.
327. **Thomas, A. J., S. Shah, M. S. Mathews, and N. Chacko.** 2008. *Apophysomyces elegans*-renal mucormycosis in a healthy host: a case report from south India. *Indian J. Med. Microbiol.* **26**:269–271.
328. **Tomita, H. E., et al.** 10 November 2010. *Rhizomucor variabilis* infection in human cutaneous mucormycosis. *Clin. Exp. Dermatol.* doi:10.1111/j.1365-2230.2010.03956.x.
329. **Torell, J., B. H. Cooper, and N. G. Helgeson.** 1981. Disseminated *Saksenaia vasiformis* infection. *Am. J. Clin. Pathol.* **76**:116–121.
330. **Torres-Narbona, M., J. Guinea, J. Martínez-Alarcón, T. Peláez, and E. Bouza.** 2007. In vitro activities of amphotericin B, caspofungin, itraconazole, posaconazole, and voriconazole against 45 clinical isolates of Zygomycetes: comparison of CLSI M38-A, Sensititre YeastOne, and the Etest. *Antimicrob. Agents Chemother.* **51**:1126–1129.
331. **Tortorano, A. M., et al.** 2009. Molecular identification and in vitro antifungal susceptibilities of 28 Zygomycetes isolates: FIMUA-ECMM survey of zygomycosis in Italy. *J. Chemother.* **21**:363–364.
332. **Tragiannidis, A., and A. H. Groll.** 2009. Hyperbaric oxygen therapy and other adjunctive treatments for zygomycosis. *Clin. Microbiol. Infect.* **15**(Suppl. 5):82–86.
333. **Trifilio, S., et al.** 2007. Breakthrough fungal infections after allogeneic hematopoietic stem cell transplantation in patients on prophylactic voriconazole. *Bone Marrow Transplant.* **40**:451–456.
334. **Trotter, D. J., G. Gonis, E. Cottrill, and C. Coombs.** 2008. Disseminated *Saksenaia vasiformis* in an immunocompetent host. *Med. J. Aust.* **189**:519–520.
335. **Tsai, T. W., et al.** 1997. *Cokeromyces recurvatus* infection in a bone marrow transplant recipient. *Bone Marrow Transplant.* **19**:301–302.
336. **Tully, C. C., A. M. Romanelli, D. A. Sutton, B. L. Wickes, and D. R. Hospenthal.** 2009. Fatal *Actinomyces elegans* var. *kuwaitiensis* infection following combat trauma. *J. Clin. Microbiol.* **47**:3394–3399.
337. **Ullmann, A. J., et al.** 2007. Posaconazole or fluconazole for prophylaxis in severe graft-versus-host disease. *N. Engl. J. Med.* **356**:335–347.
338. **Valentini, C. G., et al.** 2010. Efficacy of combined surgery and antifungal therapies for the management of invasive zygomycoses in patients with haematological malignancies. *Mycoses* **53**:89–92.
339. **van Burik, J. A., R. S. Hare, H. F. Solomon, M. L. Corrado, and D. P. Kontoyiannis.** 2006. Posaconazole is effective as salvage therapy in zygomycosis: a retrospective summary of 91 cases. *Clin. Infect. Dis.* **42**:e61–e65.
340. **van Heerden, I., C. Cronjé, S. H. Swart, and J. M. Kotzé.** 2002. Microbial, chemical and physical aspects of citrus waste composting. *Bioresour. Technol.* **81**:71–76.
341. **Vastag, M., et al.** 2004. Cloning and sequence analysis of the glyceraldehyde-3-phosphate dehydrogenase gene from the Zygomycetes fungus *Rhizomucor miehei*. *Antonie Van Leeuwenhoek* **86**:111–119.
342. **Vastag, M., T. Papp, Z. Kasza, and C. Vágvölgyi.** 2000. Intraspecific variation in two species of *Rhizomucor* assessed by random amplified polymorphic DNA analysis. *J. Basic Microbiol.* **40**:269–277.
343. **Vega, W., M. Orellana, L. Zaror, J. Gené, and J. Guarro.** 2006. *Saksenaia vasiformis* infections: case report and literature review. *Mycopathologia* **162**:289–294.
344. **Ventura, G. J., H. M. Kantarjian, E. Anaissie, R. L. Hopfer, and V. Fainstein.** 1986. Pneumonia with *Cunninghamella* species in patients with hematologic malignancies. A case report and review of the literature. *Cancer* **58**:1534–1536.
345. **Venugopal, P. L., T. L. Venugopal, A. Gomathi, E. S. Ramakrishna, and S. Ilavarasi.** 1989. Mycotic keratitis in Madras. *Indian J. Pathol. Microbiol.* **32**:190–197.
346. **Verma, A., B. Brozman, and C. K. Petito.** 2006. Isolated cerebral mucormycosis: report of a case and review of the literature. *J. Neurol. Sci.* **240**:65–69.
347. **Vigouroux, S., et al.** 2005. Zygomycosis after prolonged use of voriconazole in immunocompromised patients with hematologic disease: attention required. *Clin. Infect. Dis.* **40**:e35–e37.
348. **Viscoli, C., and E. Castagnola.** 2010. Geoclimatic factors and invasive aspergillosis after allogeneic hematopoietic stem cell transplantation: new perspectives for patient management? *Clin. Infect. Dis.* **50**:1598–1600.
349. **Vissinon, T.** 1999. Fungal flora in chicken stalls and its etiopathogenic importance for humans and animals. *Berl. Munch. Tierarztl. Wochenschr.* **112**:104–107.
350. **Vitovec, J., P. Vladík, C. Proks, and P. Fragner.** 1975. Mucormycosis (*Mucor pusillus*) with asteroids in a young bull. *Acta Vet. Acad. Sci. Hung.* **25**:31–35.
351. **Voigt, K., E. Cigelnik, and K. O'Donnell.** 1999. Phylogeny and PCR identification of clinically important Zygomycetes based on nuclear ribosomal DNA sequence data. *J. Clin. Microbiol.* **37**:3957–3964.
352. **Voigt, K., and J. Wöstemeyer.** 2001. Phylogeny and origin of 82 Zygomycetes from all 54 genera of the *Mucorales* and *Mortierellales* based on combined analysis of actin and translation elongation factor EF-1 α genes. *Gene* **270**:113–120.
353. **Vonberg, R. P., and P. Gastmeier.** 2006. Nosocomial aspergillosis in out-break settings. *J. Hosp. Infect.* **63**:246–254.
354. **Walsh, T. J., and D. P. Kontoyiannis.** 2008. Editorial commentary: what is the role of combination therapy in management of zygomycosis? *Clin. Infect. Dis.* **47**:372–374.
355. **Wang, J., C. M. Harvey, J. H. Calhoun, L. Y. Yin, and J. T. Mader.** 2002.

- Systemic *Apophysomyces elegans* after trauma: case report and literature review. *Surg. Infect. (Larchmt)* **3**:283–289.
356. **Warris, A., et al.** 2001. Recovery of filamentous fungi from water in a paediatric bone marrow transplantation unit. *J. Hosp. Infect.* **47**:143–148.
357. **Weber, D. J., A. Peppercorn, M. B. Miller, E. Sickbert-Benett, and W. A. Rutala.** 2009. Preventing healthcare-associated *Aspergillus* infections: review of recent CDC/HICPAC recommendations. *Med. Mycol.* **47**(Suppl.): S199–S209.
358. **Weinberg, W. G., B. H. Wade, G. Cierny III, D. Stacy, and M. G. Rinaldi.** 1993. Invasive infection due to *Apophysomyces elegans* in immunocompetent hosts. *Clin. Infect. Dis.* **17**:881–884.
359. **Weitzman, I., and M. Y. Crist.** 1979. Studies with clinical isolates of *Cunninghamella*. I. Mating behavior. *Mycologia* **71**:1024–1033.
360. **Weitzman, I., S. Whittier, J. C. McKittrick, and P. Della-Latta.** 1995. Zygosporangia: the last word in identification of rare or atypical Zygomycetes isolated from clinical specimens. *J. Clin. Microbiol.* **33**:781–783.
361. **White, M. M., et al.** 2006. Phylogeny of the Zygomycota based on nuclear ribosomal sequence data. *Mycologia* **98**:872–884.
362. **Wickliffe, C. L., T. G. Cornitiu, and T. Butler.** 1989. Cellulitis caused by *Rhizomucor pusillus* in a diabetic patient receiving continuous insulin infusion pump therapy. *South. Med. J.* **82**:1432–1434.
363. **Wieden, M. A., K. K. Steinbronn, A. A. Padhye, L. Ajello, and F. W. Chandler.** 1985. Zygomycosis caused by *Apophysomyces elegans*. *J. Clin. Microbiol.* **22**:522–526.
364. **Wilson, A. P., S. Wright, and G. Bellingan.** 2000. Disseminated fungal infection following falciparum malaria. *J. Infect.* **40**:202–204.
365. **Wilson, M., J. Robson, C. M. Pyke, and J. G. McCormack.** 1998. *Saksenaea vasiformis* breast abscess related to gardening injury. *Aust. N. Z. J. Med.* **28**:845–846.
366. **Wilson, P. A.** 2008. Zygomycosis due to *Saksenaea vasiformis* caused by a magpie peck. *Med. J. Aust.* **189**:521–522.
367. **Winn, R. E., P. D. Ramsey, and E. D. J. Adams.** 1982. Traumatic mucormycosis secondary to *Apophysomyces elegans*, a new genus of the *Mucorales*. *Clin. Res.* **30**:382A.
368. **Woo, P. C., et al.** 2010. Internal transcribed spacer region sequence heterogeneity in *Rhizopus microsporus*: implications for molecular diagnosis in clinical microbiology laboratories. *J. Clin. Microbiol.* **48**:208–214.
369. **Yagi, S., et al.** 2008. Pulmonary mucormycosis (*Cunninghamella bertholletiae*) with cavitation diagnosed using ultra-thin fibre-optic bronchoscopy. *Respirology* **13**:312–314.
370. **Zeilender, S., D. Drenning, F. L. Glauser, and D. Bechard.** 1990. Fatal *Cunninghamella bertholletiae* infection in an immunocompetent patient. *Chest* **97**:1482–1483.
371. **Zhang, R., J. W. Zhang, and H. M. Szerlip.** 2002. Endocarditis and hemorrhagic stroke caused by *Cunninghamella bertholletiae* infection after kidney transplantation. *Am. J. Kidney Dis.* **40**:842–846.
372. **Zhao, Y., et al.** 2009. Primary cutaneous mucormycosis caused by *Rhizomucor variabilis* in an immunocompetent patient. *Mycopathologia* **168**:243–247.
373. **Zheng, R.-Y., and H. Jiang.** 1995. *Rhizomucor endophyticus* sp. nov., an endophytic Zygomycetes from higher plants. *Mycotaxon* **56**:455–466.
374. **Zheng, R.-Y., and G.-Q. Chen.** 1993. Another non-thermophilic *Rhizomucor* causing human primary cutaneous mucormycosis. *Mycosystema* **6**:1–11.
375. **Zheng, R.-Y., and G.-Q. Chen.** 1991. A non-thermophilic *Rhizomucor* causing human primary cutaneous mucormycosis. *Mycosystema* **4**:45–57.

Marisa Z. R. Gomes is Assistant Researcher in the Nosocomial Infection Research Laboratory at Instituto Oswaldo Cruz, Fundação Oswaldo Cruz (FIOCRUZ), Rio de Janeiro, Brazil, and Visiting Scientist in the Department of Infectious Diseases, Infection Control, and Employee Health at The University of Texas M. D. Anderson Cancer Center, Houston, TX. Dr. Gomes received her M.D., M.Sc., and Ph.D. in infectious diseases from The Federal University of Rio de Janeiro. Since 1991, she has been working in infectious disease specialized hospitals, and for the last 10 years, she has been working with nosocomial infection control in Brazilian federal hospitals. She has also been doing research on nosocomial infection and tutoring and teaching master's and doctoral students in the postgraduate program of FIOCRUZ.



Dimitrios Kontoyiannis is Professor of Medicine and Deputy Chairman in the Department of Infectious Diseases, Infection Control, and Employee Health at The University of Texas M. D. Anderson Cancer Center in Houston, TX. Dr. Kontoyiannis leads an internationally recognized multidisciplinary group focusing on the epidemiology, natural history, pathogenesis, prognosis, and management of virtually every common mycosis that afflicts immunocompromised patients with cancer. He has authored or coauthored more than 440 manuscripts, abstracts, and book chapters and is the recipient of several national awards.



Russell Lewis is Associate Professor in the Division of Clinical and Experimental Pharmacology at the University of Houston College of Pharmacy and Adjunct Associate Professor of Medicine and Clinical Pharmacy Specialist in the Section of Infectious Diseases at The University of Texas M. D. Anderson Cancer Center in Houston, TX. Dr. Lewis has authored over 150 papers and 15 book chapters on the topics of antifungal pharmacology and infections in neutropenic cancer patients. His research focuses on the pharmacology, resistance, and immunological effects of antifungal therapies.

