

Photo Quiz

(For answer and discussion, see page 2387 in this issue [doi:10.1128/JCM.r00075-11])

Cellulitis, Headache, and Fever following Tick Bites

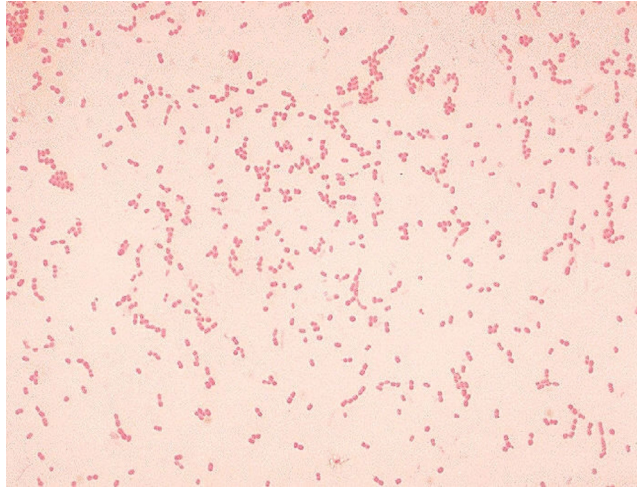


FIG. 1. Gram stain of colonies from chocolate agar plate.

A 53-year-old male resident of rural Kentucky presented to his primary care physician with a 2-day history of severe headache and fever to 104°F. Symptoms had developed 5 days following his removal of numerous ticks from his lower extremities. One tick was embedded and may not have been completely removed, leading to an area of redness on the left ankle that expanded over the ensuing days, eventually forming an abscess and cellulitis. Despite treatment with oral doxycycline, his symptoms worsened, and on the 8th day of illness, with erythema extending to the thigh, he was admitted to the hospital. The initial working diagnosis was probable staphylococcal cellulitis and sepsis, for which the patient was treated with vancomycin, clindamycin, and continuation of oral doxycycline.

Initial laboratory findings were unremarkable except for a C-reactive protein level of 64.7 mg/liter (normal, <5 mg/liter). Results of serological tests for Lyme disease, *Ehrlichia chaffeensis*, *Francisella tularensis*, and Rocky Mountain spotted fever antibodies were all negative. Cultures of blood (aerobic and anaerobic; Bactec 9240) and urine were negative. A Gram stain of a swab specimen collected from the left ankle revealed no organisms or white blood cells. Since the specimen arrived

in the laboratory late in the evening, culture plates were not examined until after 32 h of incubation. At that time, small, gray, moist colonies were present on the chocolate agar plate, with no growth on the sheep blood and MacConkey agar plates. The isolate was presumptively reported as representing a *Haemophilus* species. The isolate was subcultured to provide sufficient growth to inoculate identification panels but had not grown within 24 h. Gram staining was performed, revealing the organisms seen in Fig. 1.

Alan D. Junkins
Norton Healthcare
Louisville, Kentucky

James W. Snyder*
University of Louisville Hospital
Louisville, Kentucky

*Phone: (502) 852-1777
Fax: (502) 852-1771
E-mail: james.w.snyder@louisville.edu