

## Molecular Methods To Improve Diagnosis and Identification of Mucormycosis<sup>∇</sup>

Sarah P. Hammond,<sup>1,3,4\*</sup> Ralf Bialek,<sup>5</sup> Danny A. Milner,<sup>2,4</sup> Eva M. Petschnigg,<sup>1,†</sup>  
Lindsey R. Baden,<sup>1,3,4</sup> and Francisco M. Marty<sup>1,3,4</sup>

Division of Infectious Diseases<sup>1</sup> and Department of Pathology,<sup>2</sup> Brigham and Women's Hospital, Dana-Farber Cancer Institute,<sup>3</sup>  
and Harvard Medical School,<sup>4</sup> Boston, Massachusetts 02115, and Labor Dr. Krause & Kollegen MVZ, Kiel, Germany<sup>5</sup>

Received 4 February 2011/Returned for modification 15 March 2011/Accepted 12 April 2011

**Mucormycosis is difficult to diagnose. Samples from suspected cases often fail to grow Mucorales in microbiologic cultures. We identified all hematologic malignancy and stem cell transplant patients diagnosed with proven mucormycosis between 2001 and 2009 at Brigham and Women's Hospital/Dana-Farber Cancer Institute. Seminested PCR targeting Mucorales 18S ribosomal DNA and sequencing were performed on formalin-fixed paraffin-embedded tissue samples. Of 29 cases of mucormycosis, 27 had tissue samples available for PCR and sequencing. Mucorales PCR was positive in 22. Among 12 culture-positive cases, 10 were PCR positive and sequencing was concordant with culture results to the genus level in 9. Among 15 culture-negative cases, PCR was positive and sequencing allowed genus identification in 12. Mucorales PCR is useful for confirmation of the diagnosis of mucormycosis and for further characterization of the infection in cases where cultures are negative.**

The reported incidence of mucormycosis (previously referred to as zygomycosis) (6) has been increasing in the last 2 decades, particularly among immunocompromised patients (3, 11, 12). In a recent study of invasive fungal disease in hematopoietic stem cell transplant (HSCT) recipients, mucormycosis was the third most common infection, after candidiasis and aspergillosis (8).

Despite its increasing frequency, mucormycosis remains difficult to diagnose. Radiographically and clinically, mucormycosis is often indistinguishable from other common invasive mold infections, such as aspergillosis. Histopathology is the “gold standard” for diagnosis. However, histopathologic identification of Mucorales in tissue specimens requires significant pathological expertise and does not allow species identification. Organisms in tissue specimens with histopathologically identified mucormycosis often fail to grow in fungal cultures. In a review of 929 cases of mucormycosis reported between 1940 and 2003, only 50% were culture positive (11).

The inability to confirm histopathologically diagnosed mucormycosis and determine the species has important treatment implications. In comparison to *Aspergillus* species, which are typically susceptible to voriconazole, amphotericin B, and echinocandins, Mucorales are usually susceptible only to amphotericin B and less frequently to posaconazole (1). Furthermore, there is significant variability in susceptibility by genus; in a study of 217 clinical isolates of Mucorales, 100% of *Lichtheimia* spp. (syn. *Absidia* pro parte), *Rhizomucor* spp., and *Rhizopus* spp. were susceptible to amphotericin B, while only 63% of *Cunninghamella* sp. isolates were susceptible (1). Thus,

novel techniques to confirm the diagnosis of mucormycosis in tissue and identify the infecting species are needed.

Detection of fungal DNA in tissue samples by PCR is a novel non-culture-based method that may allow improved diagnosis of mucormycosis (2, 4, 7, 9, 10). In particular, PCR with sequencing of the 18S ribosomal DNA of Mucorales in order to diagnose mucormycosis and identify the infecting species in paraffin-embedded tissue samples in clinical cases of invasive fungal infection has been described (2, 9, 10). We assessed the performance of Mucorales 18S ribosomal DNA PCR and sequencing in a retrospective cohort of patients treated for hematological malignancies with histopathologically proven mucormycosis.

(This work was presented in abstract form at the 50th Interscience Conference on Antimicrobial Agents and Chemotherapy, Boston, MA, 12 September 2010, abstr. M-414.)

### MATERIALS AND METHODS

**Patients and definitions.** All adult patients with hematologic malignancy and HSCT recipients at Brigham and Women's Hospital/Dana-Farber Cancer Institute (BWH/DFCI) who developed proven mucormycosis between 1 January 2001 and 31 December 2009 were identified. Computerized medical records were reviewed for underlying hematologic diagnosis, stem cell transplant status, microbiologic results, pathological results (from tissue aspirates, biopsy specimens, or autopsy specimens), and radiographic results. This study was approved by the Partners Healthcare Human Research Committee.

The routine clinical approach to patients with suspected invasive mold infection in whom serum fungal antigens (galactomannan beginning in 2003 and 1→3-β-D-glucan beginning in 2004) do not suggest a diagnosis at BWH/DFCI includes surgical biopsy or computed tomography-guided collection of a fine-needle aspirate of the affected area. Proven mucormycosis was defined by use of the European Organization for Research and Treatment of Cancer/Mycosis Study Group criteria on the basis of pathological assessment of tissue samples at the time that the sample was collected (5). Mucormycosis was considered disseminated if there was radiographic evidence of infection in two or more noncontiguous sites.

**Histopathology.** Histopathologic analysis of biopsy specimens and cytopathologic analysis of fine-needle aspirate specimens were performed on formalin-fixed paraffin-embedded samples by an anatomic pathologist at the time that the tissue specimen was obtained. All tissue samples were fixed in 10% neutral-buffered formalin and processed per routine protocols to paraffin blocks. The cohort included all cases in which this initial pathological assessment suggested

\* Corresponding author. Mailing address: Division of Infectious Diseases, Brigham and Women's Hospital, 75 Francis St., PBB-A4, Boston, MA 02115. Phone: (617) 525-8418. Fax: (617) 732-6829. E-mail: shammond2@partners.org.

† Present address: Department of Medicine, Boston Medical Center, Boston University School of Medicine, Boston, MA 02118.

∇ Published ahead of print on 20 April 2011.

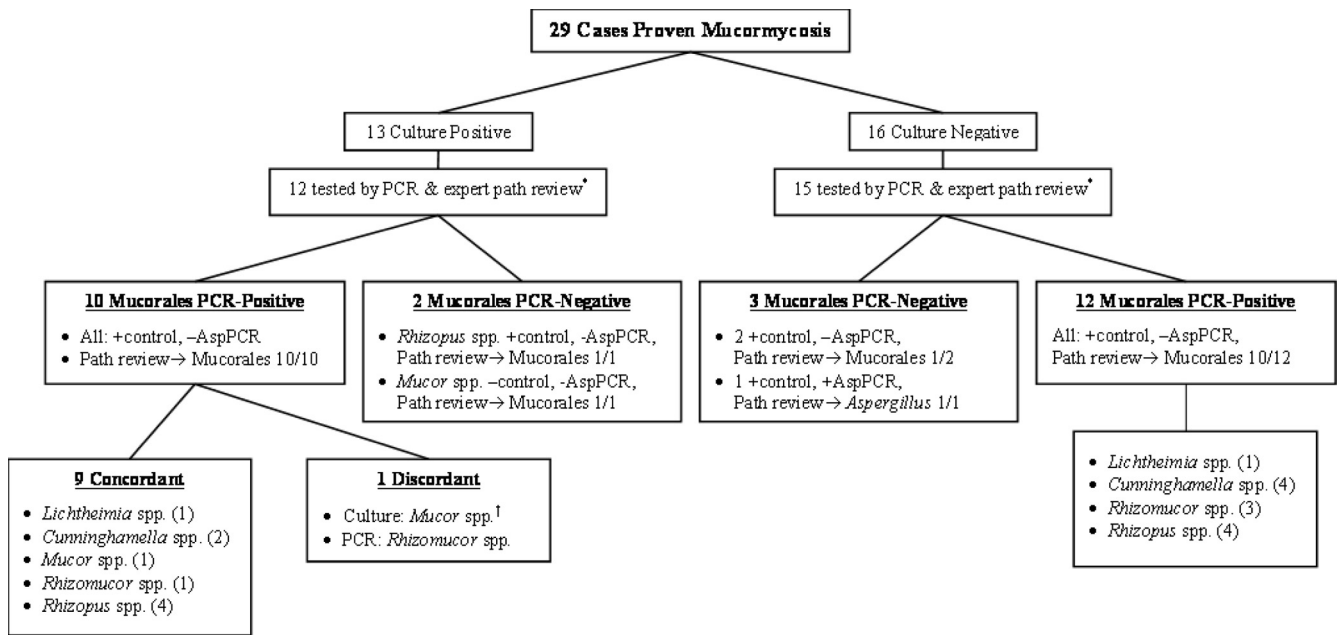


FIG. 1. Results of Mucorales and *Aspergillus* PCR and expert pathological review. path, pathological; AspPCR, *Aspergillus* PCR; \*, one tissue sample each from the culture-positive and culture-negative groups was not available for pathological review and PCR at the time that the study was undertaken; †, a cultured fungus was identified locally, but the species was not confirmed by the reference laboratory.

mucormycosis. All available samples were reviewed a second time by an infectious disease pathologist (D.A.M.) at the time that the study was completed for confirmation. The histological sections examined by the infectious disease pathologist were the same sections analyzed at initial diagnosis by the primary pathologist. The primary pathologists and the expert infectious disease pathologist were blinded to PCR results.

**Fungal culture.** Routine fungal cultures were performed on all biopsy, aspirate, and autopsy specimens. In cases where tissue culture yielded growth of a fungus, isolated pathogens were identified by standard phenotypic methods. Confirmatory species identification of most isolates was performed using phenotypic methods at a national reference laboratory (Fungus Testing Laboratory, University of Texas Health Science Center at San Antonio, San Antonio, TX).

**Molecular methods.** DNA extraction and seminested PCR targeting the 18S ribosomal DNA of Mucorales, the mitochondrial DNA of *Aspergillus* species, and the human beta-globulin gene (extraction control) were performed on formalin-fixed paraffin-embedded tissue specimens (including biopsy specimens and cell blocks from fine-needle aspirates) as previously described (2, 9). The primers are located within the V4 and V5 variable regions of the 18S ribosomal DNA. The outer primers ZM1 (5'-ATT ACC ATG AGC AAA TCA GA-3') and ZM2 (5'-TCC GTC AAT TCC TTT AAG TTT C-3') are complementary to nucleotide positions 711 to 730 and 1117 to 1096 (*Rhizopus arrhizus*, GenBank accession number AF113440), respectively. Products of the seminested reaction using primers ZM1 and ZM3 (5'-CAA TCC AAG AAT TTC ACC TCT AG-3') are 175 to 177 bp long and demonstrate enough variability to reliably identify genera but not enough to distinguish species unequivocally.

All PCR testing was performed retrospectively at the time that the study was completed. Tissue sections used for DNA extraction and PCR amplification were cut from the existing tissue block at the time that the study was initiated in 2010 (months to years after original collection) using a fresh sterile blade and sterile tubes for collection and transport to the molecular lab. For each tissue specimen, at least two extractions and PCRs were performed on each of the two 5-micrometer tissue slices. In cases where multiple tissue specimens were available from the same diagnostic procedure, up to four separate samples per case were assayed. Mucorales and *Aspergillus* PCR products were sequenced as previously described (2). Investigators who performed the PCR assays and sequencing were blinded to clinical information and tissue culture results.

**Analysis.** Concordance of pathological, microbiologic, and Mucorales PCR sequencing results were assessed to determine the order and genus in cases where cultures grew a mold of the order Mucorales. In cases where cultures did not grow, the ability of PCR to identify the infecting mold to the genus level was

assessed. The performance characteristics of Mucorales PCR and culture were compared by McNemar's test. Statistical analysis was performed using SAS (version 9.2) software (SAS Institute Incorporated, Cary, NC).

## RESULTS

During the study period, proven mucormycosis was diagnosed in 29 patients on the basis of initial pathological review at the time of the clinical illness. The cohort included 14 patients with hematologic malignancy and 15 HSCT recipients. Diagnosis was made by tissue biopsy in 21 patients, fine-needle tissue aspiration in 3 patients, and autopsy in 5 patients. There were 12 episodes of disseminated infection and 17 episodes of localized infection, including 9 sino-orbital infections, 6 pulmonary infections, and 2 cutaneous infections.

Fungal tissue cultures grew Mucorales in 13 of 29 cases, including *Rhizopus* spp. ( $n = 5$ ), *Mucor* spp. ( $n = 3$ ), *Cunninghamella* spp. ( $n = 2$ ), *Rhizomucor* spp. ( $n = 2$ ), and *Lichtheimia* spp. ( $n = 1$ ). One tissue sample from a patient with sino-orbital infection grew both *Mucor circinelloides* and *Curvularia clavata*.

Among the 13 cases where both cultures grew Mucorales and initial review of tissue pathology was consistent with mucormycosis, 12 specimens were available when the study was performed for PCR assays and expert pathological review (Fig. 1). Ten of 12 were Mucorales PCR positive, and sequencing results for 9 of these were concordant with culture results to the genus level. All 12 samples were *Aspergillus* PCR negative, and all 12 appeared to have infections consistent with mucormycosis on expert pathological review. One case was PCR positive for mucormycosis, but the sequencing result, *Rhizomucor* spp., was discordant at the genus level with the culture result, *Mucor* spp. The cultured fungus in this case was identified locally, but the isolated species was not sent to the ref-

erence laboratory for confirmation. Two of 12 cases in which cultures grew Mucorales were PCR negative, including 1 case that was also human beta-globulin PCR (control) negative.

Among the 16 cases where mucormycosis was diagnosed on the basis of initial review of tissue histopathology alone, 15 paraffin-embedded specimens were available at the time that the study was performed for PCR with sequencing and expert pathological review (Fig. 1). Twelve of 15 samples were Mucorales PCR positive, and the findings of expert pathological review were consistent with mucormycosis in 10 of these 12 samples. Sequencing identified the following Mucorales: *Rhizopus* spp. ( $n = 4$ ), *Cunninghamella* spp. ( $n = 4$ ), *Rhizomucor* spp. ( $n = 3$ ), and *Lichtheimia* spp. ( $n = 1$ ).

Three of 15 culture-negative cases were Mucorales PCR negative. Two of these three were *Aspergillus* PCR negative; expert pathological review of these two cases suggested mucormycosis in one case, and the infection could not be identified further than an invasive mold infection in the other. The third culture-negative Mucorales PCR-negative case was *Aspergillus* PCR positive, with *Aspergillus flavus* identified by sequencing. Blinded expert pathological review of this case also suggested invasive aspergillosis.

Among the five cases in which Mucorales PCR did not amplify, one sample each was from 2001, 2004, and 2005 and two samples were from 2009; thus, there was no relationship between the age of the sample and Mucorales PCR negativity.

Overall, Mucorales PCR was positive in 22 of 27 tissue specimens that were assessed. In comparison to tissue culture, Mucorales PCR was significantly more likely to confirm mucormycosis in pathologically defined cases ( $P = 0.008$ ).

## DISCUSSION

These data demonstrate that Mucorales PCR of formalin-fixed paraffin-embedded tissue can be a useful tool for confirmation of pathological diagnosis of mucormycosis. Among 27 tissue specimens with initial histologic evidence of mucormycosis, Mucorales PCR was positive in 22 specimens. Furthermore, we found a high rate of concordance among 12 specimens in which tissue culture grew Mucorales: PCR confirmed mucormycosis in 10 (83%), and the sequencing result was concordant with the culture result at the genus level in 9 specimens. Comparison of Mucorales PCR results to those of microbiologic culture strongly suggests the accuracy of this technique and allowed identification of the infecting mold in 12 culture-negative cases in this cohort. The present study confirms and extends findings from previous studies which assessed the performance of this technique in a limited number of cases of solely histopathologically identified mucormycosis (2, 9) and in culture-proven cases with non-formalin-fixed specimens (9, 10). Our data demonstrate that Mucorales PCR with sequencing offers a reliable way to confirm tissue diagnosis of mucormycosis and to identify the infecting species, thereby allowing targeted antifungal therapy.

Mucorales PCR was negative in 5 tissue specimens with initial histopathologic evidence of mucormycosis. These negative samples included one tissue specimen that was repeatedly *Aspergillus* PCR positive and that appeared to a blinded expert pathologist to have an infection consistent with invasive aspergillosis, suggesting that the initial pathological diagno-

sis of mucormycosis made at the time of infection may have been incorrect. Another negative specimen was both *Aspergillus* PCR negative and human beta-globulin (control) PCR negative, suggesting that the DNA in the specimen was destroyed in the process of fixation, sample storage, or DNA extraction. The remaining three Mucorales PCR-negative specimens were control PCR positive and *Aspergillus* PCR negative. On expert pathological review, the findings for one of these specimens, in which there was limited tissue, was not characteristic for mucormycosis or aspergillosis. These negative Mucorales PCR results may be due to technical factors, such as a limited amount of fungal DNA in small tissue specimens or degradation of fungal DNA, particularly in the older specimens in this retrospective study. In addition, the negative Mucorales PCR result in the case where the infection was not characteristic for mucormycosis or aspergillosis on expert pathological review suggests possible infection due to a less common other mold (e.g., *Fusarium* spp.).

In summary, Mucorales PCR of formalin-fixed paraffin-embedded tissue samples with sequencing had a high rate of concordance with tissue culture to the genus level and allowed diagnostic confirmation and species identification in 12 of 15 cases of mucormycosis diagnosed solely on the basis of histopathology. This is a useful tool that can improve tissue diagnosis of mucormycosis and characterization of culture-negative invasive mold infection, thus facilitating targeted antifungal therapy.

## ACKNOWLEDGMENTS

We declare no competing financial interests.

We acknowledge the excellent technical assistance of Veronika Lucht and Maria Hinz.

## REFERENCES

- Almyroudis, N. G., D. A. Sutton, A. W. Fothergill, M. G. Rinaldi, and S. Kusne. 2007. In vitro susceptibilities of 217 clinical isolates of zygomycetes to conventional and new antifungal agents. *Antimicrob. Agents Chemother.* **51**:2587–2590.
- Bialek, R., et al. 2005. PCR based identification and discrimination of agents of mucormycosis and aspergillosis in paraffin wax embedded tissue. *J. Clin. Pathol.* **58**:1180–1184.
- Bitar, D., et al. 2009. Increasing incidence of zygomycosis (mucormycosis), France, 1997–2006. *Emerg. Infect. Dis.* **15**:1395–1401.
- Dannaoui, E., et al. 2010. Molecular detection and identification of zygomycetes species from paraffin-embedded tissues in a murine model of disseminated zygomycosis: a collaborative European Society of Clinical Microbiology and Infectious Diseases (ESCMID) Fungal Infection Study Group (EFISG) evaluation. *J. Clin. Microbiol.* **48**:2043–2046.
- De Pauw, B., et al. 2008. Revised definitions of invasive fungal disease from the European Organization for Research and Treatment of Cancer/Invasive Fungal Infections Cooperative Group and the National Institute of Allergy and Infectious Diseases Mycoses Study Group (EORTC/MSG) Consensus Group. *Clin. Infect. Dis.* **46**:1813–1821.
- Hibbett, D. S., et al. 2007. A higher-level phylogenetic classification of the Fungi. *Mycol. Res.* **111**:509–547.
- Kasai, M., et al. 2008. Detection of a molecular biomarker for zygomycetes by quantitative PCR assays of plasma, bronchoalveolar lavage, and lung tissue in a rabbit model of experimental pulmonary zygomycosis. *J. Clin. Microbiol.* **46**:3690–3702.
- Kontoyannis, D. P., et al. 2010. Prospective surveillance for invasive fungal infections in hematopoietic stem cell transplant recipients, 2001–2006: overview of the Transplant-Associated Infection Surveillance Network (TRANSNET) Database. *Clin. Infect. Dis.* **50**:1091–1100.
- Rickerts, V., et al. 2006. Diagnosis of invasive aspergillosis and mucormycosis in immunocompromised patients by seminested PCR assay of tissue samples. *Eur. J. Clin. Microbiol. Infect. Dis.* **25**:8–13.
- Rickerts, V., et al. 2007. Comparison of histopathological analysis, culture, and polymerase chain reaction assays to detect invasive mold infections from biopsy specimens. *Clin. Infect. Dis.* **44**:1078–1083.
- Roden, M. M., et al. 2005. Epidemiology and outcome of zygomycosis: a review of 929 reported cases. *Clin. Infect. Dis.* **41**:634–653.
- Saegeman, V., et al. 2010. Increasing incidence of mucormycosis in university hospital, Belgium. *Emerg. Infect. Dis.* **16**:1456–1458.