

Subcutaneous Phaeohyphomycosis Caused by *Phaeoacremonium* Species in a Kidney Transplant Patient: The First Case in Korea

Jonghyeon Choi, M.D.¹, Yangsoon Lee, M.D.¹, Hae-Sun Chung, M.D.¹, Ja-Seung Koo, M.D.³, Dongeun Yong, M.D.¹,
Yu Sun Kim, M.D.², Kyungwon Lee, M.D.¹, and Yunsop Chong, Ph.D.¹

Departments of Laboratory Medicine and Research Institute of Bacterial Resistance¹, General Surgery², and Pathology³, Yonsei University College of Medicine, Seoul, Korea

Phaeohyphomycosis is a subcutaneous infection caused by dark pigmented fungi, including fungi of the species *Phaeoacremonium*, *Alternaria*, *Exophiala*, and *Pyrenochaeta*. In August 2005, a 54-yr-old man who had received a renal transplant 5 yr ago was admitted to our hospital with a subcutaneous mass on the third finger of the right hand; the mass had been present for several months. He had been receiving immunosuppressive agents for several years. He underwent excision of the mass, which was followed by aspiration of the wound for bacterial and fungal cultures. Many fungal hyphae were observed on the histology slide treated with periodic acid-Schiff stain. A few white waxy colonies with a woolly texture grew on the Sabouraud dextrose agar at 30°C and changed to dark brown in color. Nucleotide sequencing of internal transcribed spacer regions revealed 100% homology to the *Phaeoacremonium aleophilum* anamorph and *Togninia minima* teleomorph (514 bp/514 bp). The patient completely recovered after wide surgical excision. Here, we report the first case of phaeohyphomycosis caused by *Phaeoacremonium* species in a kidney transplant patient in Korea.

Key Words: Subcutaneous phaeohyphomycosis, *Phaeoacremonium* species, Renal transplantation, Immunosuppressive agents

INTRODUCTION

The fungal genus *Phaeoacremonium* was described by Crous et al. [1]. Fungi of this genus have been isolated from a wide range of hosts such as humans, woody plants, and the larvae of bark beetles, but only some species of this genus have been reported as pathogens of humans [2, 3]. Presently, the *Phaeoacremonium* genus, formerly known as *Phialophora*, includes more than 20 species [4, 5]. The occurrence of *Phaeoacremonium* species varies, with *Phaeoacremonium aleophilum* being the most frequently isolated spe-

cies in esca diseased grapevines [2].

The term phaeohyphomycosis was first introduced in 1974 to describe local infections caused by darkly pigmented molds (black mold) [6, 7]. However, only a few human phaeohyphomycosis cases have been reported in the literature worldwide [8]. We report the first case of primary phaeohyphomycosis by *Phaeoacremonium* species in a kidney transplant patient in Korea.

CASE REPORT

A 54-yr-old man with a large subcutaneous mass on the third finger of his right hand was admitted to our hospital in August 2005 (Fig. 1A). He had been working at a leather factory for 10 yr. He had chronic renal failure caused by diabetes mellitus, and therefore, he underwent kidney transplantation in October 2000. After the operation, he was prescribed immunosuppressive agents such as tacrolimus, deflazacort, and mycophenolate mofetil. He had no history of trauma, but had a small nodule on the third finger since 1995. The nodule grew gradually during several months prior to hospital admission. The patient also experienced

Received: December 13, 2010

Manuscript No: KJLM-10-169

Revision received: January 18, 2011

Accepted: March 4, 2011

Corresponding author: Dongeun Yong, M.D.

Department of Laboratory Medicine, Yonsei University College of Medicine,
250 Seongsan-ro, Seodaemun-gu, Seoul 120-752, Korea

Tel: +82-2-2228-2442, Fax: +82-2-313-0956, E-mail: deyong@yuhs.ac

ISSN 1598-6535 © The Korean Society for Laboratory Medicine.

This is an Open Access article distributed under the terms of the Creative Commons Attribution Non-Commercial License (<http://creativecommons.org/licenses/by-nc/3.0>) which permits unrestricted non-commercial use, distribution, and reproduction in any medium, provided the original work is properly cited.

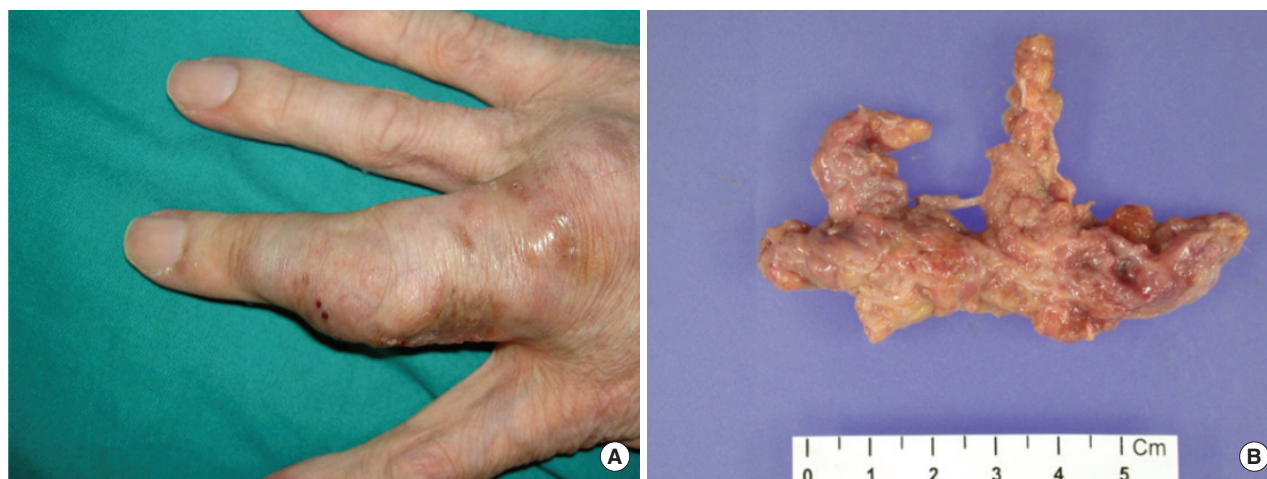

Fig. 1. (A) Subcutaneous lesion on the third finger of the right hand; (B) 6.5 × 3 × 1.2 cm-sized mass obtained after removal of the lesion.

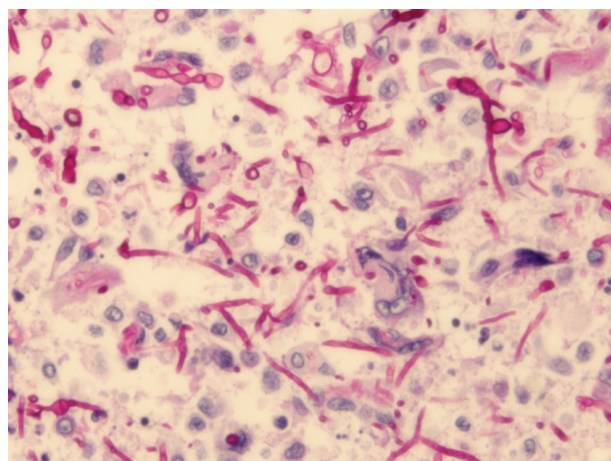


Fig. 2. Periodic acid-Schiff stain showed many fungal hyphae under the microscope (×400).

mild pain and pruritus around the lesion. The mass was removed by an orthopedic surgeon. The patient had high serum glucose levels of 341 mg/dL, which suggested post-transplant diabetic mellitus; his serum blood urea nitrogen/creatinine levels were 33.5/1.5 mg/dL. In complete blood count analysis, the white blood cell count and Hb and Hct levels were within reference ranges, although platelet count was slightly low at 117,000/ μ L. The patient underwent excision of the mass, which was followed by culture of the wound aspirate collected in the operating room. The mass was removed entirely and had dimensions of 6.5 × 3 × 1.2 cm (Fig. 1B). In the bacterial culture, no colonies formed on the blood agar, MacConkey agar, or thioglycolate broth after incubation for 48 hr at 35°C and ambient temperature. Periodic acid-Schiff staining performed on the histology slide showed many fungal hyphae (Fig. 2). Few white waxy

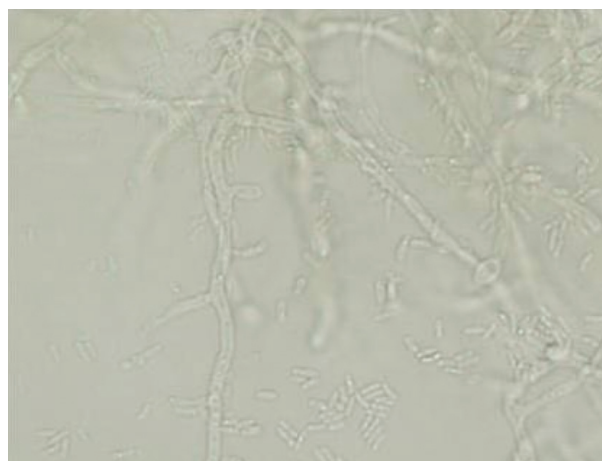


Fig. 3. On the slide culture of the specimen, many fungal hyphae were septate, and conidiophores were observed to be short and usually unbranched (×400).

colonies with a woolly texture were observed on Sabouraud dextrose agar at 30°C, and the colonies changed into a dark-brown color. When the fungal hyphae were separated on the slide culture, the conidiophores were observed to be short and frequently unbranched. Furthermore, the apical cell of the conidiophores mainly represented 1 phialide. The phialides appeared to be elongate-ampulliform and were long or subcylindrical. This morphology further supported the presence of the genus *Phaeoacremonium* (Fig. 3). PCR using ITS1 (5' TCC GTA GGT GAA CCT GCG G 3') and ITS4 (5' TCC TCC GCT TAT TGA TAT GC 3') primers was performed for species identification [9]. The β -tubulin and actin genes were detected according to CLSI guidelines, 2008 [10]. Even though β -tubulin and actin were not amplified, nucleotide sequencing of ITS1 and ITS4 revealed 100%

sequence homology to both *P. aleophilum* anamorph and *Togninia minima* teleomorph. As such, antifungal agents, including fluconazole and amphotericin B, were administered to the patient empirically for 2 days, and the patient recovered without any sequelae. Five years after the wide excision, the patient has had no further subcutaneous lesions.

DISCUSSION

Phaeohyphomycosis is the term used to describe a subcutaneous fungal infection caused by darkly pigmented molds (black mold), such as those from the species *Phaeoacremonium*, *Phialophora*, *Alternaria*, *Exophiala*, and *Pyrenochaeta* [6, 7]. This condition is rare in humans, but it can involve the skin, subcutis, paranasal sinuses, or the central nervous system [9]. The genus *Phaeoacremonium* has been isolated from patients who experience traumatic implantation of fungi from contaminated plant thorns or soil, and was usually known as a causal agent of grapevine diseases such as Petri disease and esca, which can cause leaf drop and wood discoloration [7, 11]. Recently, cases of phaeohyphomycosis caused by *Phaeoacremonium* species have been increasingly reported in humans [7, 8]. Notably, these diseases have been described in immunocompromised patients with renal transplantation [12]. In our case, the patient was in an immunosuppressed state. Although he lived in an urban area, he frequently climbed mountains as a hobby before the appearance of the subcutaneous mass. When we consider the natural ecological niches of the *Phaeoacremonium* species, the patient may have been exposed to this pathogen during his frequent mountain-climbing trips. It is difficult to explain how he acquired the infection because he did not report any injury. However, it is possible that microtraumas to the skin and immunosuppressive therapy may have played a role.

Morphologically, the genus *Phaeoacremonium* is an intermediate between the genera *Acremonium* and *Phialophora* [8, 13]. Organisms of the genus *Acremonium* usually produce delicate hyaline septate hyphae, which carry unbranched tapering conidiophores with elliptical-shaped unicellular conidia. The characteristic tapering phialides of these organisms are derived from septate hyphae with one-celled ellipsoidal conidia [14]. In contrast, organisms of genus *Phialophora* show melanized hyphae and slimy one-celled conidia at their apex with distinct collarettes [15]. *Phaeoacremonium* show medium brown hyphae, which become pale brown to hyaline and verruculose. The phialides have a funnel-shaped collarette and show a wide variety of diverse

forms, including ellipsoidal, obovate, cylindrical, or allantoid (sausage-like) [5]. The morphological distinctions from a number of other relatively similar *Phaeoacremonium* species have been summarized by Mostert et al. [5]. Although it is difficult to identify the species in our isolate on the basis of morphological criteria, it could be distinguished from species of brown colonies, such as *Phaeoacremonium parasiticum* and *Phaeoacremonium inflatipes*, by its short and usually unbranched conidiophores. However, molecular-based tools must be used in order to confirm the species. Although the additional PCRs for β -tubulin and actin were unsuccessfully repeated several times, sequence analysis of internal transcribed spacer (ITS) revealed 100% sequence homology to *P. aleophilum* and *T. minima*. *T. minima* is a teleomorph of *P. aleophilum* [11]. CLSI guidelines indicate that the ITS region in *Phaeoacremonium* only provides limited resolution for species identification [10]. Thus, we are able to conclude that the pathogen was of the genus *Phaeoacremonium*. Optimal treatment of phaeohyphomycosis usually involves surgical wound excision combined with antifungal agents for several months [16]. For this patient, empirical antifungal agents were administered for 2 days and the wound excision was successfully completed. Total excision of the nodule was important for uncomplicated healing in the patient. After 5 yr, no subcutaneous lesion has been recognized in the patient. Herein, we have reported the first case of phaeohyphomycosis caused by the *Phaeoacremonium* species in a kidney transplant patient in Korea.

Authors' Disclosures of Potential Conflicts of Interest

No potential conflict of interest relevant to this article was reported.

REFERENCES

1. Crous PW, Gams W, Wingfield MJ, Van Wyk PS. *Phaeoacremonium* gen. nov. associated with wilt and decline diseases of woody hosts and human infections. *Mycologia* 1996;88:786-96.
2. Aroca A, Raposo R, Lunello P. A biomarker for the identification of four *Phaeoacremonium* species using the beta-tubulin gene as the target sequence. *Appl Microbiol Biotechnol* 2008;80:1131-40.
3. Aguilar-Donis A, Torres-Guerrero E, Arenas-Guzman R, Hernandez-Hernandez F, Lopez-Garcia L, Criales-Vera S, et al. Mycetoma caused by *Phaeoacremonium parasiticum*- a case confirmed with B-tubulin sequence analysis. *Mycoses Epub* 2010 Aug 4. (<http://www.ncbi.nlm.nih.gov/pubmed/20701685>).
4. Essakhi S, Mugnai L, Crous PW, Groenewald JZ, Surico G. Molecular and phenotypic characterisation of novel *Phaeoacremonium* species isolated from esca diseased grapevines. *Persoonia* 2008;21:119-34.
5. Mostert L, Groenewald JZ, Summerbell RC, Robert V, Sutton DA,

- Padhye AA, et al. Species of *Phaeoacremonium* associated with infections in humans and environmental reservoirs in infected woody plants. *J Clin Microbiol* 2005;43:1752-67.
6. Naggie S, Perfect JR. Molds: hyalohyphomycosis, phaeohyphomycosis, and zygomycosis. *Clin Chest Med* 2009;30:337-53, vii-viii.
 7. Guarro J, Alves SH, Gene J, Graziotin NA, Mazzuco R, Dalmagro C, et al. Two cases of subcutaneous infection due to *Phaeoacremonium* spp. *J Clin Microbiol* 2003;41:1332-6.
 8. Baradkar VP, Mathur M, Kumar S. Phaeohyphomycosis of subcutaneous tissue caused by *Phaeoacremonium parasiticum*. *Indian J Med Microbiol* 2009;27:66-9.
 9. Kumar KK, Hallikeri K. Phaeohyphomycosis. *Indian J Pathol Microbiol* 2008;51:556-8.
 10. Clinical and Laboratory Standards Institute. Interpretive criteria for identification of bacteria and fungi by DNA target sequencing (MM18-A) 2008.
 11. Damm U, Mostert L, Crous PW, Fourie PH. Novel *Phaeoacremonium* species associated with necrotic wood of Prunus trees. *Per-sonia* 2008;20:87-102.
 12. Farina C, Gotti E, Mouniee D, Boiron P, Goglio A. *Phaeoacremonium parasiticum* subcutaneous infection in a kidney-transplanted patient successfully treated by surgery. *Transpl Infect Dis* 2007;9:253-5.
 13. Reblova M, Seifert KA. A new fungal genus, *Teracosphaeria*, with a phialophora-like anamorph (*Sordariomycetes*, *Ascomycota*). *Mycol Res* 2007;111:287-98.
 14. Das S, Saha R, Dar SA, Ramachandran VG. *Acremonium* species: a review of the etiological agents of emerging hyalohyphomycosis. *Mycopathologia* 2010;170:361-75.
 15. de Hoog GS, Maysen P, Haase G, Horre R, Horrevorts AM. A new species, *Phialophora europaea*, causing superficial infections in humans. *Mycoses* 2000;43:409-16.
 16. Larsen CG, Arendrup MC, Krarup E, Pedersen M, Thybo S, Larsen FG. Subcutaneous phaeohyphomycosis in a renal transplant recipient successfully treated with voriconazole. *Acta Derm Venereol* 2009;89:657-8.