

Laparoscopic 5-mm Trocar Site Herniation and Literature Review

Miya Yamamoto, MD, Laura Minikel, MD, Eve Zaritsky, MD

ABSTRACT

Objective: To evaluate the evidence for fascial closure of 5-mm laparoscopic trocar sites.

Methods: We conducted electronic database searches of PubMed and the Cochrane Library for articles published between November 2008 and December 2010. We used the keywords *trocar hernia*, *trocar-site hernia*, *laparoscopic hernia*, *trocar port-site hernia*, *laparoscopic port-site hernia*. Prospective and retrospective case series, randomized trials, literature reviews, and randomized animal studies of trocar hernias on abdominal wall defects from gynecologic, urologic, and general surgery literature were reviewed. The Cochrane Database was reviewed for pertinent studies. Metaanalysis was not possible due to the significant heterogeneity between studies and lack of randomized trials large enough to assess the incidence of this rare complication.

Results: Trocar-site hernias are a rare but known complication of laparoscopic surgery. Trocar size ≥ 10 mm is associated with an increased rate of hernia development. Currently, the accepted gynecologic surgical practice is closure of fascial incisions ≥ 10 mm, while incisions < 10 mm do not require closure. However, large prospective and retrospective case series reports from general surgery and urology literature support nonclosure of blunt or radially dilating trocars in paramedian sites. Expert opinion and small case reports suggest that in cases of prolonged manipulation of 5-mm trocar sites the surgeon should consider fascial closure, because extension of the initial incision may have occurred.

Conclusion: There is no evidence to recommend routine closure of 5-mm trocar incisions; the choice should continue to be left to the discretion of the individual surgeon.

Key Words: Trocar hernia, Trocar-site hernia, Laparo-

scopic hernia, Trocar port-site hernia, Laparoscopic port-site hernia, Trocar fascia closure.

INTRODUCTION

The case presented herein is of a 5-mm trocar-site incisional hernia. This is a rare complication, because most trocar-site hernias reported in the gynecologic, urology, and general surgery literature have developed at incisions ≥ 10 mm. The incidence of trocar hernias ranges from 0.2% to 3.1% in large case series and reviews (**Table 1**)¹⁻⁵ and has been correlated to trocar size.^{1,4,5} Trocar hernias at a 5-mm port site are infrequently reported in the literature. There have been 10 published case reports in adults of 5-mm trocar hernias (**Table 2**).⁶⁻⁹ The largest number of 5-mm cases was published by Nezhat² in 1997 for a total of 5 of 11 trocar-site hernias in a retrospective case review of approximately 5300 patients. Factors that may be involved in the development of hernias that were addressed in the literature include trocar size, location, trocar type, trocar manipulation, entry and closure techniques, and preexisting fascial defects. The objective of this review was to analyze the evidence for closure of 5-mm fascial incisions.

CASE REPORT

A 43-year-old gravida 2 para 2 woman underwent a laparoscopic hysterectomy with removal of a 20-week size fibroid uterus. An 11-mm umbilical radially expanding trocar was placed using the Veress needle, followed by 3 accessory 5-mm ports in the right, left, and suprapubic regions under direct visualization. The umbilical port site was expanded to 14-mm for morcellation, and the fascia was later closed with 2 interrupted 0 polygalactin suture using the Carter-Thomason. The 5-mm fascial incisions were not closed. The uterine weight was 1505g.

The patient's recovery was unremarkable. She did have nausea and vomiting in the immediate recovery period that resolved with medication and went home the evening of post-operative day one. On postoperative day 4, she developed nausea and vomiting and presented to

Kaiser Permanente Oakland, California, USA (all authors).

The authors wish to thank Dr. Misa Perron-Burdick and the Kaiser Permanente Oakland Library staff, Mare Gehrke and Angela Hudson, for their assistance.

Address correspondence to: Miya Yamamoto, MD, Kaiser Permanente Oakland, 280 W. MacArthur, Oakland, CA 94611, USA. E-mail: miya.yamamoto@gmail.com

DOI: 10.4293/108680811X13022985131697

© 2011 by JSLS, *Journal of the Society of Laparoendoscopic Surgeons*. Published by the Society of Laparoendoscopic Surgeons, Inc.

Table 1.

Author	Study Type	Fascial Closure Hernia Development	Non Closure Hernia Development	% Umbilical	% Extra-umbilical	Incidence, Size Related
Kadar ¹	Retrospective, 3560 operative gynecologic laparoscopies	5-mm 0/8771 10-mm 0/175 12-mm 3/136	5-mm 0/8771 10-mm 1/254 12-mm 2/25	0	100%	5-mm 0% 10-mm (1) 0.23% 12-mm (5) 3.1%
Nezhat ²	Retrospective, 5,300 gynecologic laparoscopies	10-mm 6 sites	5-mm 5 sites	All 10-mm	All 5-mm	0.2% overall
Azurin ³	Retrospective, 1,300 laparoscopic cholecystectomies	10/1,300	N/A	10/10, 10-mm	N/A	0.77% overall
Montz ⁴	Survey, 933 reported gynecologic cases (840 size known)	167/933	766/933	76%	24%	.021% overall estimated -86% ≥ 10-mm
Lajer ⁵	Literature review, 62 gynecologic cases (55 size known)	53/55	96% ≥ 10-mm	27%	73%	n/a

Table 2.

5-mm Trocar Hernia Case Reports

Author	Procedure	Location	Comments
Nezhat ²	Hysterectomy adhesiolysis	Left lower quadrant 5	Extensive manipulation at trocar sites where hernias developed
Plaus ⁶	Diagnostic for pelvic pain, biliary colic	Midline supra-pubic 2	Para-median sites may be preferred over midline
Reardon ⁷	Para-esophageal hernia repair	Left abdomen 1	Hernia developed at site of active manipulation with repetitive movements in long procedure
Matter ⁸	cholecystectomy	Right upper lateral 1	Reinsertion of cannula may widen initial fascial defect
Toub ⁹	Radical hysterectomy for cervical carcinoma	Left lower quadrant 1	Began chemotherapy postoperative day #3

the gynecology clinic having passed one bowel movement. Upon examination, she was found to be afebrile, have a soft, mildly distended abdomen with normal bowel sounds and tenderness over the right lower quadrant incision. The incisions were intact without drainage or erythema. She had a normal leukocyte count. Computed tomography of her abdomen and pelvis showed a spigelian hernia in the right lateral abdominal wall at the level of the iliac crest, with a herniated loop of small bowel (**Figure 1**). She was immediately taken to the operating room.

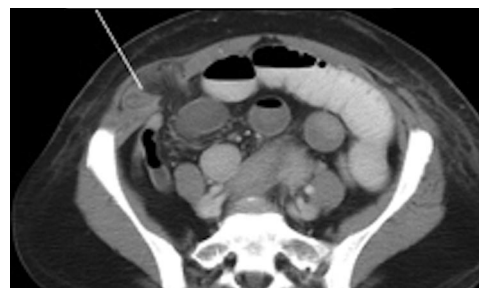


Figure 1. Herniated loop of small bowel through Spigelian fascia.

Intraoperatively, the herniated small bowel was found to be viable and was manually reduced into the abdomen. The peritoneum and fascia were closed with a 3-0-polygalactin running stitch. The patient did well and went home the next morning. This patient's hernia development may have been related to the extensive trocar manipulation that was required to operate on a 1505g myomatous uterus that resulted in expansion of the fascial incision.

METHODS

Prospective and retrospective case series, randomized trials, literature reviews, and randomized animal studies of trocar hernias on abdominal wall defects from gynecologic, urologic, and general surgery studies were reviewed. Metaanalysis was not possible due to the significant heterogeneity between studies and lack of randomized trials large enough to assess the incidence of this rare complication. The studies were organized by (1) incidence of incisional hernia development via large case series, (2) hernia development by trocar type and location, (3) animal studies on abdominal wall defects from trocar types, (4) pre-existing fascial defects, and (5) trocar manipulation.

RESULTS

Location

Para-median locations versus median locations (including the umbilicus) have been associated with conflicting rates of trocar hernias reported in the literature (**Table 1**).¹⁻⁵ The linea alba, including the umbilicus, lacks the muscle support in spontaneous fascial closure due to the lack of rectus muscle. Paramedian incisions have been shown in animal studies to be supported by muscle re-opposition after blunt trocars were used (**Table 3**).^{10,11} Para-median

incisions have also been shown in Level 2 general surgery studies not to require fascial closure when blunt trocars are used (**Table 4**).¹²⁻¹⁷ The arcuate line may also demarcate an inherent weakness of the abdominal fascia. It is the place where the fascia of the internal oblique and the transversus abdominus of the posterior rectus sheath migrate to join the anterior sheath, leaving only the transversalis fascia and peritoneum for closure support deep to the rectus muscle (**Figures 2 and 3**).

Trocar Type

Blunt (conical, pyramidal, radially dilating, nonbladed) have been shown to have the benefit of decreased length and surface area of fascial defects over bladed or cutting trocars in animal studies with muscle splitting instead of cutting (**Table 3**). This evidence supports nonclosure of 5-mm fascial defects made with blunt trocars.

Manipulation

Extensive manipulation of the trocar port site may widen a port-site incision beyond the initial length. Fascial and peritoneal stretching of the original incision may occur from several causes: specimen removal, multiple reinsertions of the sheath, advanced surgical difficulty requiring increased force and torque on the fascia, and prolonged operative time. Nezhat's review² reported that the substantial manipulation of the 5-mm operative port sites required for the surgeries resulted in trocar-site hernias. All 5 cases were associated with advanced surgical complications: extensive adhesions, severe endometriosis, large uterine leiomyomata.² All cases occurred in the left supra-pubic location where the bulk of manipulation was performed and no closure was performed.

Table 3.

Author	Study	Trocar type	Difference in Defect Surface Area	Comments
Tarnay ¹⁰	Randomized, observer blinded swine abdominal wall	Cutting Conical Pyramidal	Conical fascial defect 57-68% smaller than cutting Conical fascial defect 32-62% smaller than pyramidal	Conical split muscles, which later re-opposed with fascia
Bhojrul ¹¹	12 swine abdominal, not blinded	Cutting Blunt radially dilating	Radially dilating 52% narrower muscle defect than cutting	Muscles split rather than cut

Table 4.

Author	Study Type/Size	Trocar type, Location	Fascia Closed	Follow up Time	Hernia Incidence	Conclusion/Comments
Bhojrul ¹²	Randomized/244 general surgery procedures	Cutting & Blunt	≥10-mm cutting >10-mm blunt (3%)	6–18 months	Cutting 125 C 0% Blunt 119 NC: 0%	Radially expanding trocar sites do not require routine closure
Liu ¹³	Prospective/110 sites, general surgery procedures	Blunt, para-median	None	11 months	10-mm 0% 12-mm 0%	Closure not required with blunt trocars at para-median sites above arcuate line, residual fascial defect 6–8mm
Johnson ¹⁴	Retrospective/747 Roux-en-Y gastric bypass	Blunt, para-median	None	20 months	1494 12-mm 0% 2241 5-mm 0%	Para-median blunt (radially dilating) sites do not require closure
Shalhav ¹⁵	Retrospective/92 renal procedures	Blunt, para-median	62 closed, 28 non-closed	4.8 months	12-mm C: 0% 12-mm NC: 0%	Closure not required on para-median blunt trocars, NC excluded malnutrition, renal failure, chronic steroid use
Siqueira ¹⁶	Retrospective/350 sites, donor nephrectomies	Blunt, para median	None	36 months	140 12-mm 0% 210 5-mm 0%	Closure not required on para-median blunt trocars even at 12-mm
Mahmoud ¹⁷	Prospective/405 Nissen fundoplication	Cutting, para median, above arcuate line	None	1 month up to 6 years	810 10-mm 0%	Para-median trocar sites do not require closure

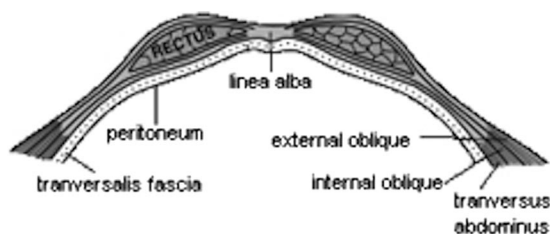


Figure 2. Abdominal fascia above the arcuate line. The posterior rectus sheath is made up of the internal oblique, transversus abdominus, and transversalis fascia. Image reprinted from Netter's, public domain courtesy of Wikipedia.com.

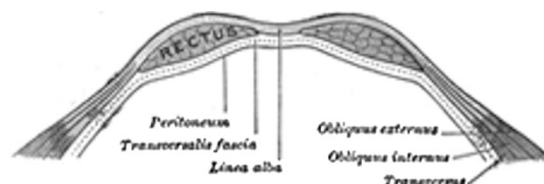


Figure 3. Abdominal fascia below the arcuate line. The posterior rectus sheath is made up of only the transversalis fascia. Image reprinted from Netter's, public domain courtesy of Wikipedia.com.

Pre-existing Fascial Defects

Ramachandran¹⁸ found an 18% incidence of pre-existing umbilical fascial defects in 2100 patients undergoing laparoscopic surgery for various gynecologic and general surgery indications. All identified defects were repaired, and a relationship was not found between the repaired pre-existing fascial defect and the development of a hernia.¹⁸ In contrast, in a report on 1300 laparoscopic cholecystectomies, Azurin³ reported 9 of 10 trocar hernias developed in patients who had been diagnosed with a pre-existing hernia preoperatively despite intraoperative repair. Trocar

incisions at sites of pre-existing hernias should be carefully evaluated to confirm adequate closure.

Insertion and Closure Techniques

A Cochrane review from 2008 that evaluated different entry techniques reported no advantage in using any single technique over another to prevent major complications.¹⁹ They did not report data relating to laparoscopic trocar hernias.

Only one randomized trial²⁰ conducted an intraoperative evaluation of laparoscopic closure techniques. Elashry et al²⁰ looked at closure of 95 twelve-mm trocar port sites in 32 patients and compared the Carter-

Thomason (CT-NP) needle point suture device (CooperSurgical, Inc, Trumbull, CT) with the Maciol suture needle set (Specialty Surgical Instrumentation, Nashville, TN), eXit disposable puncture closure device (Progressive Medical, St. Louis, MO), the Endoclose device (Covidien Surgical, Norwalk, CT), a 14-gauge angiocatheter, Lowsley retractor (CS Surgical Inc, Slidell, LA) with hand-sutured closure, and standard hand-sutured closure. They found that the CT-NP device was faster (mean time 2.5 minutes) and had secure closure confirmed digitally and endoscopically, but they did not follow their patients for hernia development.²⁰ This study was underpowered, so no definitive conclusions can be made about the benefit of one closure type over another in hernia development.

CONCLUSION

Trocar-site hernias are a known complication related to laparoscopic surgery. Trocar size is the primary measure by which most gynecologic surgeons decide to close fascial incisions; conventional practice is closure of 10-mm incisions and nonclosure of 5-mm incisions. Fascial closure does not prevent incisional hernia development. Paramedian location and blunt type trocars are 2 factors that have been extensively reported on in general surgery and urologic surgery Level II studies as measures by which fascial closure is not required 10-mm and 12-mm incisions. We would recommend surgeons consider fascial closure in 5-mm incisions where extensive, prolonged manipulation occurred that may have extended or widened the initial defect.

References:

1. Kadar. Incisional hernias after major laparoscopic gynecologic procedures. *Am J Obstet Gynecol*. 1993 May;168(5):1493–1495.
2. Nezhat C. Incisional hernias after operative laparoscopy. *J Laparoendosc Adv Surg Tech A*. 1997 Apr;7(2):111–115.
3. Azurin DJ. Trocar site herniation following laparoscopic cholecystectomy and the significance of an incidental preexisting umbilical hernia. *Am Surg*. 1995;8:718–20.
4. Montz FJ. Incisional hernia following laparoscopy: a survey of the American Association of Gynecologic Laparoscopists. *Obstet Gynecol*. 1994 Nov;84(5):881–884.
5. Lajer H. Hernias in trocar ports following abdominal laparoscopy, a review. *Acta Obstet Gynecol Scand*. 1997 May;76(5):389–393.
6. Plaus WJ. Laparoscopic trocar site hernias. *J Laparoendosc Surg*. 1993 Dec;3(6):567–570.
7. Reardon P. Hernia at 5-mm laparoscopic port site presenting as early postoperative small bowel obstruction. *J Laparoendosc & Adv Surg Tech A*. 1999 Dec;9(6):523–525.
8. Matter I. Incisional hernia via a lateral 5mm trocar port following laparoscopic cholecystectomy. *Isr J Med Sci*. 1996 Sep;32(9):790–791.
9. Toub D. Omental herniation through a 5-mm laparoscopic cannula site. *J Am Assoc Gynecol Laparosc*. 1994 Aug;1(4 Pt 1):413–414.
10. Tarnay CM. Incisional characteristics associated with six laparoscopic trocar-cannula systems: a randomized, observer-blinded comparison. *Obstet Gynecol*. 1999 Jul;94(1):89–93.
11. Bhojru S. Radially expanding dilatation. A superior method of laparoscopic trocar access. *Surg Endosc*. 1996 Jul;10(7):775–778.
12. Bhojru S, Payne J, Steffes B, Swanstrom L, Way LW. A randomized, prospective study of radially expanding trocars in laparoscopic surgery. *J Gastrointest Surg*. 2000 Jul-Aug;4(4):392–397.
13. Liu CD. Laparoscopic port sites do not require fascial closure when nonbladed trocars are used. *Am Surg*. 2000 Sep;66(9):853–854.
14. Johnson WH. VersaStep trocar hernia rate in unclosed fascial defects in bariatric patients. *Surg Endosc*. 2006 Oct;20(10):1584–1586.
15. Shalhav A. Transperitoneal laparoscopic renal surgery using blunt 12-mm trocar without fascial closure. *J Endourol*. 2002 Feb;16(1):43–46.
16. Siqueira T. The use of blunt-tipped 12-mm trocars without fascial closure in laparoscopic live donor nephrectomy. *JSL*. 2004 Jan-Mar;8(1):47–50.
17. Mahmoud Uslu HY. Cannula site insertion technique prevents incisional hernia in laparoscopic fundoplication. *Surg Laparosc Endosc Percut Tech*. 2007 Aug;17(4):267–270.
18. Ramachandran CS. Umbilical hernial defects encountered before and after abdominal laparoscopic procedures. *Int Surg*. 1998 Apr-Jun;83(2):171–173.
19. Ahmad G, Duffy JMN, Phillips K, Watson A. Laparoscopic entry techniques. *Cochrane Database Syst Rev* 2008, Issue 2. Art. No.: CD006583. DOI: 10.1002/14651858.CD006583.pub2.
20. Elashry OM. Comparative clinical study of port-closure techniques following laparoscopic surgery. *J Am Coll Surg*. 1996 Oct;183(4):335–344.