

Laparoscopic Repair of Incidentally Found Spigelian Hernia

Khanjan H. Nagarsheth, MD, Todd Nickloes, DO, Greg Mancini, MD, Julio A. Solla, MD

ABSTRACT

Background and Objectives: A Spigelian hernia is a rare type of hernia that occurs through a defect in the anterior abdominal wall adjacent to the linea semilunaris. Estimation of its incidence has been reported as 0.12% of all abdominal wall hernias. Traditionally, the method of repair has been an open approach. Herein, we discuss a series of laparoscopic repairs.

Methods: Case series and review of the literature.

Cases: Three patients are presented. All were evaluated and taken to surgery initially for a different disease process, and all were incidentally found to have a spigelian hernia. These patients underwent laparoscopic repair of their hernias; 2 were repaired intraperitoneally and one was repaired totally extraperitoneally. Two patients initially underwent a mesh repair, while the third had an attempted primary repair.

Conclusions: There is evidence that supports the use of laparoscopy for both diagnosis and repair of spigelian hernias. There are also reports of successful repairs both primarily and with mesh. In our experience with the preceding 3 patients, we found that laparoscopic repair of incidentally discovered spigelian hernias is a viable option, and we also found that implantation of mesh, when possible, resulted in satisfactory results and no recurrence.

Key Words: Spigelian, Hernia, Laparoscopic, Repair.

INTRODUCTION

Spigelian hernias are now defined as an anterior wall defect in the transversus abdominis close to the arcuate line of Douglas, lateral to the lateral border of the anterior rectus sheath along the semilunar line.¹ Klinkosh was the first to identify the presence of a hernia in this area, and it is now referred to as a spigelian hernia after Adrian van der Spieghel who first reported on the anatomy of the linea semilunaris in the rectus sheath.² Spigelian hernias are a rare type of hernia that occurs through a defect in the anterior abdominal wall adjacent to the linea semilunaris. Estimations of their incidence have been reported as 0.12% of all abdominal wall hernias.³ Usually these hernias are identified once there is pain or obstruction from incarceration of the hernia. Therefore, traditionally the method of repair has been an open approach. There have been several case reports and a few case series that discuss the effectiveness of using a laparoscopic approach to repair these hernias. Herein, we present 3 patients who were all incidentally found to have Spigelian hernias that were laparoscopically repaired.

CASE ONE

An 87-year-old woman presented to an outside facility with a syncopal episode and was diagnosed with a urinary tract infection and normocytic anemia. Her hemoglobin and hematocrit dropped from 10 and 29 to 6.8 and 19.5, respectively. She was transferred to our tertiary care center after passing a large clot per rectum. On physical examination after transfer, she was found to have a large, full thickness, rectal prolapse that was incarcerated and not reducible, but it was not ischemic or strangulated.

Gastroenterologists were brought in for a consult on this case due to the full-thickness rectal prolapse. They were unable to reduce the prolapse secondary to extreme pain felt by the patient on examination. The recommendation to call in a colorectal surgeon for further evaluation and suggestions for therapeutic options was made. On hospital day 4, after cardiology clearance was obtained, the patient was taken to surgery and underwent a perineal rectosigmoidectomy with levatorplasty to tent her incarcerated rectal prolapse. Perineal procedures for rectal prolapse have a higher recurrence rate than abdominal pro-

University of Tennessee Medical Center, Department of Surgery, Knoxville, Tennessee (all authors).

Address correspondence to: Khanjan Nagarsheth, MD, 4850 Briar Rock Lane, Knoxville, TN 37920, USA. Telephone: (732) 757-7618, E-mail: khanjan.nagarsheth@gmail.com

DOI: 10.4293/108680811X13022985131372

© 2011 by JSLS, *Journal of the Society of Laparoendoscopic Surgeons*. Published by the Society of Laparoendoscopic Surgeons, Inc.

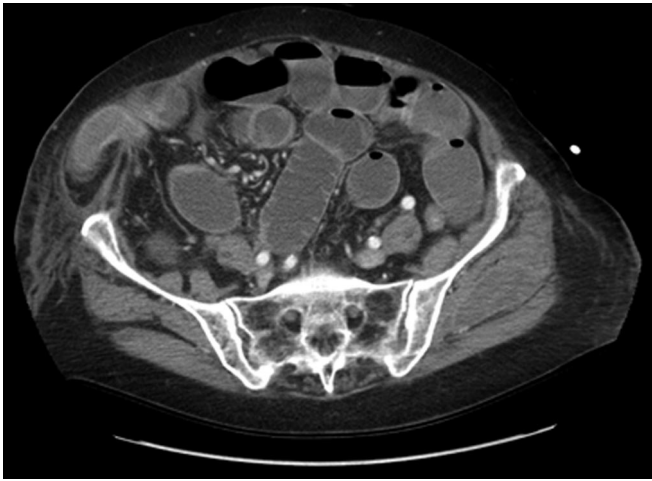

Figure 1. CT Scan image revealing right sided Spigelian hernia.

cedures but have a lower morbidity rate. Perineal procedure or Altermeier's⁴ procedures are often performed in elderly and high-risk populations.

Postoperatively, the patient was sent to the intensive care unit for close monitoring and management. In the ICU, this patient became more distended and began to have tenderness in her abdomen. She was obstipated after surgery and had not had a bowel movement since her day of transfer. It was felt that the patient had a postoperative ileus but with her worsening distention and then nausea and vomiting, a CT scan of the abdomen was obtained that revealed an enlarged Spigelian hernia with a portion of ileum that appeared kinked (**Figure 1**). On examination, she had an extremely tender right-sided ventral hernia with inflammatory changes to the overlying skin. The hernia was not reducible at bedside, so it was decided to take the patient emergently to the operating room for a laparoscopic Spigelian hernia repair with mesh.

Intraoperatively, we were able to reduce the hernia and the hernia sac (**Figure 2**). The portion of ileum in the hernia appeared viable, and peristalsis was visualized in this segment once it was reduced. A 12-cm x 12-cm round Parietex mesh was implanted against the hernia defect that was 4cm x 4cm in size. At the end of the procedure, the hernia defect was widely covered by the mesh.

Postoperatively, the patient began having flatus and a bowel movement on postoperative day 2, and her nausea and vomiting had resolved. She was transferred out of the ICU and to the floor and eventually was discharged to a skilled nursing facility for rehabilitation and physical therapy.




Figure 2. Laparoscopic view of Spigelian hernia defect.

CASE TWO

A 79-year-old female was admitted to our facility with a diagnosis of acute cholecystitis. She had recently had a cardiac pacemaker placed and was quite concerned about undergoing surgery and potentially getting an infection that would compromise her pacemaker. She was started on antibiotic coverage until the cardiology department was able to clear her for surgery. Radiographic and sonographic studies revealed gallbladder wall thickening, cholelithiasis, and pericholecystic fluid. Once the cardiology department cleared the patient for surgery, she was taken to the operating room for laparoscopic cholecystectomy. Once the abdomen was entered with the laparoscope, a survey revealed a Spigelian hernia in the usual location at the linea semilunaris in the right lower quadrant, and this defect contained herniated omental fat. The hernia was taken down laparoscopically, and the decision was made to try and close the defect primarily and not implant mesh, because the defect was only 2.5cm x 2cm, and there was an acutely infected gallbladder present. The hernia was closed primarily by way of transabdominally placed 2-0 Prolene sutures. The repair appeared to be good and attention was turned to the gallbladder, which was noted to be very edematous and tense. Bile was aspirated with only a little amount spilled and then suctioned. The gallbladder was removed in the standard fashion and a specimen was sent for analysis.

Postoperatively, the patient was sent to the floor where she began returning to normal function quickly and was discharged on postoperative day number 2 with minimal tenderness and tolerating a regular diet. She did suffer

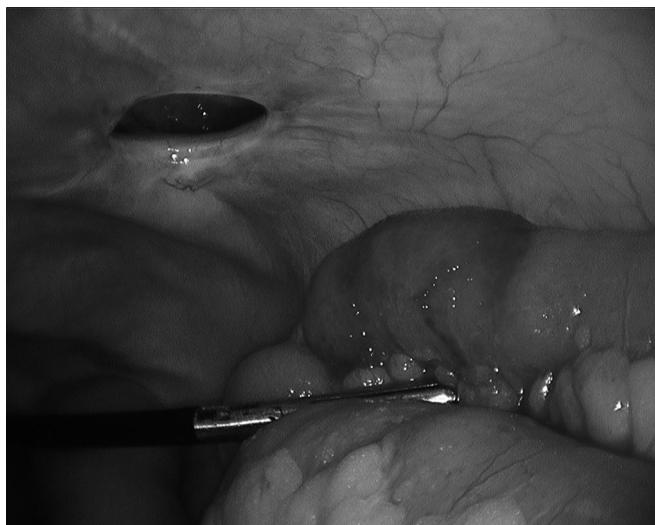

Figure 3. Laparoscopic view depicting Spigelian hernia and reduced bowel.

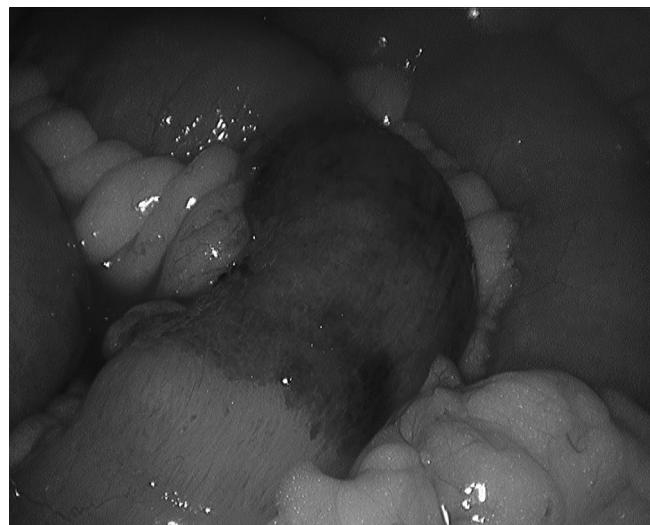

Figure 4. Laparoscopic view showing contused but viable small bowel, reduced from Spigelian hernia.

from some urinary retention and was therefore referred to the urology department for treatment. She was seen in the office approximately one week after discharge and was noted to be doing well.

However, this patient returned to the emergency department approximately 1 month after her office visit with complaints of nausea, vomiting, and crampy abdominal pain in the right lower quadrant. Physical examination revealed tenderness in this area, and as per the patient, she had not been able to have a bowel movement in several days. A CT scan revealed a recurrence of the Spigelian hernia now with a loop of small bowel stuck within it and a small bowel obstruction. The patient was taken to the operating room emergently for risk of ischemia to this segment of bowel.

The patient underwent a laparoscopic reduction and repair of her recurrent Spigelian hernia. It appeared that the prior primary closure of her hernia had broken down, and now the defect contained the terminal ileum. This loop of bowel was gently reduced, and although the bowel looked bruised, it did not look frankly ischemic or have a perforation (**Figures 3, 4**). At this point, the defect was noted to be about 3cm in diameter, and a closure was performed with a 15-cm Parietex mesh and the aid of transfascial sutures and absorbable tacks.

Again the patient tolerated this procedure well and was sent back to the floor in stable condition. She continued to do well and again recovered quickly. Her cardiac issues were being controlled by the internal medicine house

staff, and she was found fit for discharge a few days after surgery. She is currently doing well without any further issues from her hernia or the repair.

CASE THREE

A 67-year-old man arrived at ambulatory surgery to undergo laparoscopic repair of bilateral inguinal hernias. He had been suffering from the right-sided hernia for months. When he was evaluated in the surgeon's office, he was noted to have a left-sided hernia also. The patient was prepped for bilateral repair to be done laparoscopically.

During surgery, a periumbilical incision was made and the preperitoneal area was entered. Space was created using a balloon dissector. Two more 5-mm trocars were placed in the midline, and dissection commenced to reduce the bilateral inguinal hernias. On visualization of the left lateral wall, there was an abnormality noted that appeared to be another hernia at the linea semilunaris. On palpation of the abdominal wall, it was noted that there was a small, barely visible hernia on the left side. This Spigelian hernia was delineated in the preperitoneal space, and the sack was reduced into the abdomen. The defect was noted to be 3cm x 3cm.

At this point, our Parietex mesh was placed bilaterally to cover our direct hernia defects, and the left side was positioned such that the Spigelian hernia defect was also covered. Tacks were placed at the pubic tubercle and on Cooper's ligament as well as out laterally on the muscle wall.

The patient tolerated the procedure well and was released home that same day. On follow-up he was doing well, with no recurrence of his inguinal hernias and no pain at the Spigelian hernia site. This patient did very well with his laparoscopic repairs and tolerated repair of his incidentally found Spigelian hernia.

DISCUSSION

As mentioned previously, the incidence of Spigelian hernias is quite low, and part of that is likely the anomalous constellation of symptoms that can accompany it, such as a vague abdominal pain, nausea, and an area of swelling that may or may not be present.⁵ A reason that the swelling or mass of a Spigelian hernia is not always readily evident is because it protrudes through the transversus abdominis and is still covered by the external oblique aponeurosis. This additional layer masks the hernia and may prevent it from being palpable thus making the diagnosis difficult. In fact, it is reported that only 50% of all Spigelian hernias are diagnosed in the preoperative period.⁶ This makes it all the more important to determine whether repair of incidentally identified Spigelian hernias is justifiable and under what circumstances one should proceed with repair. It has additionally been noted that the fascial defect for Spigelian hernias is very often quite narrow. There are reports of incarceration and strangulation in as many as 24% of these hernias.^{7,8}

Moreno-Egea et al⁹ tackled the question of open versus laparoscopic repair in 2002 when they attempted a prospective randomized trial to analyze elective surgical treatment of Spigelian hernias. In their analysis of 22 patients (11 open repairs, 11 laparoscopic repairs), they found significantly less morbidity and shorter hospital length of stay in the laparoscopic repairs, all of which were repaired with the use of prosthetic mesh.⁹ The information that is not provided in their report is the characteristics of the hernias, the size of the hernia defects, and whether a primary repair with suture alone was attempted. Then Palanivelu et al¹⁰ showed that these hernias could be repaired laparoscopically by using a combination of primary suture repair followed by mesh reinforcement. He goes on to explain that this technique could lead to acceptable outcomes without recurrences.¹⁰ Others¹¹ showed that a simple intraperitoneal underlay of mesh yielded acceptable results. Bittner et al¹² reported in 2008 that based on their experiences and extensive review of the literature, mesh-free repair of small Spigelian hernias (≤ 2 cm) was a reasonable option and gave the benefits of laparoscopic localization, reduction, and closure without

the added morbidity and cost of foreign materials, namely mesh implantation.

All the patients in this series were seen or admitted for another surgical pathology, and either during their initial surgery or during their subsequent hospital course a Spigelian hernia was identified and repaired. Two of our 3 patients had no further recurrences or problems with their laparoscopic Spigelian hernia repairs, and we attribute this to the use of mesh for their repair. The one patient that did have some difficulty after repair had a primary laparoscopic repair without mesh, and did have a recurrence with subsequent incarceration and needed a mesh repair. We feel that placing mesh during the initial surgery could have potentially been problematic given the nature of the planned operation and risk of contamination and infection of a prosthetic mesh if it had been used. As stated before, very little information is available on these rare hernias, and nothing has been said about repairing them when operating on a patient for other pathology.

CONCLUSION

Given our experience with these limited situations, we do advocate laparoscopic repair of incidentally identified Spigelian hernias, but the caveat we add to this is that mesh should be utilized in the repair when possible, especially if the defect is noted to be over 2cm in diameter and there is no risk of contamination of the mesh with enteric or biliary contents. We also cite the need for larger series' to help identify the true benefit of repair of incidentally found Spigelian hernias.

References:

1. Spangen L. Spigelian hernia. *Acta Chirurgica Scandinavica*. 1976;462.
2. DeMatteo RP, Morris JB, Broderick G. Incidental laparoscopic repair of spigelian hernia. *Surgery*. 1997;115:521–522.
3. Mittal T, Kumar V, Khullar R, et al. Diagnosis and management of spigelian hernia: a review of the literature and our experience. *J Minimal Access Surg*. 2008;4:95–98.
4. Altomare DF, Binda G, Ganio E, De Nardi P, Giamundo P, Pescatori M. Long-term outcome of Altemeire's procedure for rectal prolapse. *Dis Colon Rectum*. 2009;52:698–703.
5. Leff DR, Hassell J, Sufi P, Heath D. Emergency and elective laparoscopic repair of spigelian hernias: two case reports and a review of the literature. *Surg Laparosc Endosc Percutan Tech*. 2009;19:e152–e155.

6. Olson RO, Davis WC. Spigelian hernia: rare or obscure? *Am J Surg*. 1968;116:842–846.
7. Baucom C, Nguyen QD, Hidalgo M, Slakey D. Minimally invasive spigelian hernia repair. *JLS*. 2009;13:263–268.
8. Spagen L. Spigelian Hernia. In: Bendavid R, ed. *Prostheses and Abdominal Wall Hernias*. Austin: RG Landes. 1994;563.
9. Moreno-Egea A, Carrasco L, Girela E, Martín JG, Aguayo JL, Canteras M. Open vs. laparoscopic repair of spigelian hernias: a prospective randomized trial. *Arch Surg*. 2002;137:1266–1268.
10. Palanivelu C, Vijaykumar M, Jani KV, Rajan PS, Maheshkumar GS, Rajapandian S. Laparoscopic transabdominal preperitoneal repair of spigelian hernia. *JLS*. 2006;10:193–198.
11. Felix EL, Michas C. Laparoscopic repair of spigelian hernias. *Surg Laparosc Endosc*. 1994;4:308–310.
12. Bittner JG, Edwards MA, Shah MB, MacFadyen BV Jr., Melinger JD. Mesh-free laparoscopic spigelian hernia repair. *Am Surg*. 2008;74:713–720.