

A case of congenital syphilis with Hutchinson's triad

Priyanka Singhal, Pankil Patel, Y. S. Marfatia

Department of Skin VD, Government Medical College and SSG Hospital, Vadodara, India

Address for correspondence:

Dr. Y. S. Marfatia, Department of Skin VD, Government Medical College and SSG Hospital, Vadodara, India. E-mail: ym11256@gmail.com

Abstract

Late congenital syphilis is a rare entity and its early diagnosis and treatment is essential to prevent significant morbidity. We are reporting a case of late congenital syphilis presenting with Hutchinson's triad at an age of 14 years.

Key words: Congenital syphilis, Hutchinson's triad

INTRODUCTION

Congenital syphilis is the oldest recognized congenital infection, and continues to account for extensive global perinatal morbidity and mortality. Globally just over 2 million pregnant women test positive for syphilis each year, comprising 1.5% of all pregnancies worldwide.^[1,2] This results in an estimated 692,100 to 1.53 million adverse pregnancy outcomes each year caused by syphilis.^[3-6] Approximately 650,000 of these pregnancy complications result in perinatal deaths (ie, deaths occurring from 22 weeks gestation through the first 7 days of life).

Late congenital syphilis (recognized 2 or more years after birth)^[7] is a very rare clinical entity. We are reporting here a case of late congenital syphilis who presented at the age of 14 years with Hutchinson's triad to emphasize that congenital syphilis still is not recognized early and antenatal screening is mandatory to prevent this serious, yet largely preventable disease.

CASE REPORT

A 14-year-old female was referred to us from the ENT department of our hospital for palatal perforation associated with regurgitation. She also had a complaint of diminished vision since 4 years and impaired hearing. There was no history or signs suggestive of sexual abuse. There was no history of STD in parents.

On examination, there was a perforation of about 1 cm diameter involving the hard palate. Her upper incisors were peg-shaped and widely spaced, suggestive of Hutchinson's teeth [Figure 1]. There was no lymphadenopathy. There was no apparent bony abnormality. No evidence of neurological or cardiovascular involvement. Her intelligence was apparently normal.

On investigating, her venereal disease research laboratory (VDRL) testing was reactive at 1:64 dilutions. She was nonreactive for HIV. Slit-lamp examination revealed dot-like corneal opacities suggestive of interstitial keratitis and audiogram showed sensory neural deafness. The findings of interstitial keratitis, sensory-neural deafness and Hutchinson's teeth completed the Hutchinson's triad in this patient. X-ray of legs was normal. CBC, electrocardiogram, X-ray chest, and ultrasonography abdomen were normal. Her parents were VDRL reactive. The girl was treated with three weekly doses of Benzathine penicillin 2.4 million units intramuscularly. Her parents were also treated with

Access this article online**Quick Response Code:****Website:**

www.ijstd.org

DOI:

10.4103/0253-7184.81252

How to cite this article:

Singhal P, Patel P, Marfatia YS. A case of congenital syphilis with Hutchinson's triad. Indian J Sex Transm Dis 2011;32:34-6.

same regimen. On follow-up, some healing of the perforation was observed.

DISCUSSION

Congenital syphilis, if not treated promptly and adequately, may result in significant physical sequelae in children. This case remained undiagnosed even after the presence of classical Hutchinson's triad age of 14 years. The diagnostic delay in this case led to the development of several irreversible stigmata, which could have been prevented by timely intervention.

Late congenital syphilis results primarily from chronic inflammation due to *T. pallidum*. This leads to many classical stigmata of syphilis-like bony prominence of forehead (Olympian brow), thickening of sternoclavicular portion of the clavicle, anterior bowing of the mild portion of tibia (saber shins), and scaphoid scapula result due to persistent or recurrent periostitis. Peg-shaped upper central permanent incisors and notched enamel (Hutchison teeth) are common. Saddle nose due to syphilitic rhinitis and a perforated nasal septum can occur. Other features of late congenital syphilis are Juvenile paresis, juvenile tabes dorsalis, aortitis, interstitial keratitis, and Clutton's joints. As many as one-fourth to one-third of patients older than 2 years have asymptomatic neurosyphilis.^[8]

Sir Jonathan Hutchinson (1828–1913) from England described a triad in late congenital syphilis consisting of notched incisors, interstitial keratitis, and eighth cranial nerve deafness. All the three findings were present in this case.

The patient also had palatal perforation for which the other differentials are TB, tertiary syphilis, typhoid, diphtheria, mucormycosis, actinomycosis, lymphoma, carcinoma, melanoma, Wegener's granulomatosis, SLE, midline lethal granulomas, sarcoidosis, and cocaine abuse. Treatment of late syphilis will not reverse the tissue damage but it may result in some improvement.

Eighth cranial nerve deafness seen in congenital syphilis, is of sudden onset and usually occurs around 8–10 years of age. As per a systematic review of pediatric sensorineural hearing loss in congenital syphilis by Chau *et al.* it was concluded that newborns with positive syphilis serology should have hearing screening performed at birth and receive treatment with an appropriate course of penicillin therapy. Longitudinal hearing screening is recommended for all pediatric patients with congenital syphilis, as further studies documenting

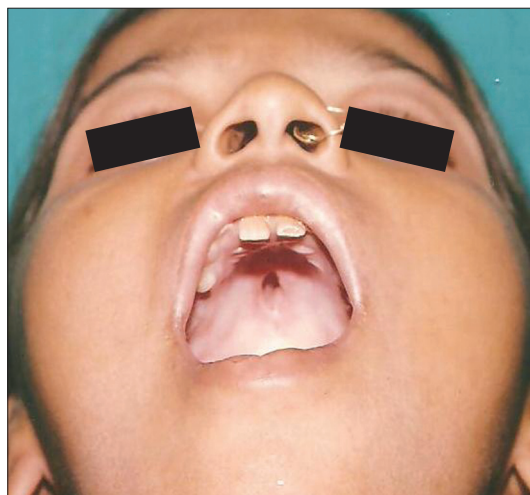


Figure 1: Palatal perforation and Hutchinson's teeth

longitudinal audiometric data for patients previously treated either fully or partly for congenital syphilis are required.^[9]

Interstitial keratitis due to congenital syphilis is commonly a late finding. Most cases of interstitial keratitis develop in patients aged 5–20 years. Congenital syphilitic interstitial keratitis is typically bilateral in 80% of cases. Uchiyama *et al* reported a rare case of Phthisis bulbi resulting from late congenital syphilis.^[10]

CONCLUSION

Although syphilis is one of the best-known STDs, for which effective treatment has been available since the introduction of penicillin in the mid-20th century, it still remains an important global health problem. Such reports of late congenital syphilis are a tragic reflection of pitfalls in the screening programs. More emphasis must be placed on primary prevention and appropriate screening programs so that maternal and neonatal syphilis can be identified and treated early, avoiding significant future morbidity.

REFERENCES

1. Schmid GP, Stoner BP, Hawkes S, Broutet N. The need and plan for global elimination of congenital syphilis. *Sex Transm Dis* 2007;34:S5-10.
2. Schmid G, Rowley J, Samuelson J, Tun Y., Guraiib M, Mathers C., *et al.* Global incidence and prevalence of four curable sexually transmitted infections (STIs): New estimates from WHO, in Proceedings of the 2nd Global HIV/AIDS Surveillance Meeting (ISSTD '09), London, UK, June–July 2009.
3. Watson-Jones D, Changalucha J. Syphilis in pregnancy in Tanzania. I. Impact of maternal syphilis on outcome of pregnancy. *J Infect Dis* 2002;186:940-7.
4. Watson-Jones D, Weiss HA, Changalucha JM, Todd J, Gumodoka B, Bulmer J, *et al.* Adverse birth outcomes in United Republic of Tanzania-impact and prevention of maternal risk factors. *Bull World*

- Health Organ 2007;85:9-18.
5. Schulz KF, Cates W Jr, O'Mara PR. Pregnancy loss, infant death, and suffering: Legacy of syphilis and gonorrhoea in Africa. *Genitourin Med* 1987;63:320-5.
 6. World Health Organization. Geneva, Switzerland: World Health Organization Global Burden of Disease Report, WHO; 2002.
 7. Larsen SA, Steiner BM, Rudolph AH. Laboratory diagnosis and interpretation of tests for syphilis. *Clin Microbiol Rev* 1995;8:1-21.
 8. Wile U, Mundt LK. Congenital syphilis: A statistical study with special regard to sex incidence. *Am J Syphilis Gonorrhoea Vener Dis* 1942;26:70-83.
 9. Chau J, Atashband S, Chang E, Westerberg BD, Kozak FK. A systematic review of pediatric sensorineural hearing loss in congenital syphilis. *Int J Pediatr Otorhinolaryngol* 2009;73:787-92.
 10. Uchiyama K, Tsuchihara K, Horimoto T, Karasawa T, Sugiyama K. Phthisis bulbi caused by late congenital syphilis untreated until adulthood. *Am J Ophthalmol* 2005;139:545-7.

Source of Support: Nil. **Conflict of Interest:** None declared.

MINUTIAE OF CLITORIS

Development

The clitoris is a sexual organ that is present only in female mammals

Its Latin genitive is *clitoridis*, as in "glans clitoridis"

Male homologue- penis

At the time of development of the urinary and reproductive organs, the previously undifferentiated genital tubercle develops into either a clitoris or penis, along with all other major organ systems.

Anatomy

1. Measures about 2.5 cm
2. The visible button-like portion is located near the anterior junction of the labia minora, above the opening of the urethra and vagina
3. It consists of glans, a body and two crura
 - a. The glans is covered by squamous epithelium and is richly supplied with nerves
 - b. Unlike the penis, the clitoris does not contain the distal portion of the urethra.

Functions

The clitoris is the most sensitive erogenous zone of the female, the stimulation of which may produce sexual excitement and clitoral erection

Its continuing stimulation may produce sexual pleasure in the female and orgasm, and is considered the key to females' sexual pleasure

Blood supply

- **Arterial supply:** pudendal, internal
- **Venous supply:** pudendal, deep external

Nerve supply

Neurovascular bundle (NVB) arising from the anteroinferior terminal portion of the inferior hypogastric plexus

Applied aspect

- **Ambiguity:** Some children are born with abnormal genitalia, making it difficult to distinguish their gender. The clitoris can be enlarged, appearing to be a small penis. The labia can be below the clitoris, giving the appearance of a scrotum. It can be unclear if the child has undescended testicles or just excess tissue in the genital area.
- **Enlargement:** An increase in size or swelling of the organ can be cause for concern. A deficiency of the 3-Beta-HSD enzyme results in abnormal sex organ development. An enlarged clitoris can also be caused by adrenal hyperplasia, congenital type 3.
- **Itching:** Abnormal itching of the clitoris is caused by vaginal infection or diabetes. Overexposure to heat, sunburn or chemicals can also cause irritation.
- **Pain:** Genital pain involving the clitoris may be a symptom of diabetes. A general infection of the vulva or vagina can also produce pain and inflammation of the clitoris. An injury to the genital area can produce nerve trauma or compression.
- **Cancer:** The symptoms of clitoral cancer are persistent genital itching, bleeding around the vulva, pain, or discoloration of the genital area. While most cancers of the genitalia affect the vulva, the clitoris can be affected as well.