

Video Article

# Dissection of Organs from the Adult Zebrafish

Tripti Gupta<sup>1</sup>, Mary C. Mullins<sup>1</sup>

<sup>1</sup>Department of Cell and Developmental Biology, University of Pennsylvania-School of Medicine

Correspondence to: Mary C. Mullins at [mullins@mail.med.upenn.edu](mailto:mullins@mail.med.upenn.edu)

URL: <http://www.jove.com/video/1717>

DOI: [doi:10.3791/1717](https://doi.org/10.3791/1717)

Keywords: Developmental Biology, Issue 37, adult, zebrafish, organs, dissection, anatomy

Date Published: 3/4/2010

Citation: Gupta, T., Mullins, M.C. Dissection of Organs from the Adult Zebrafish. *J. Vis. Exp.* (37), e1717, doi:10.3791/1717 (2010).

## Abstract

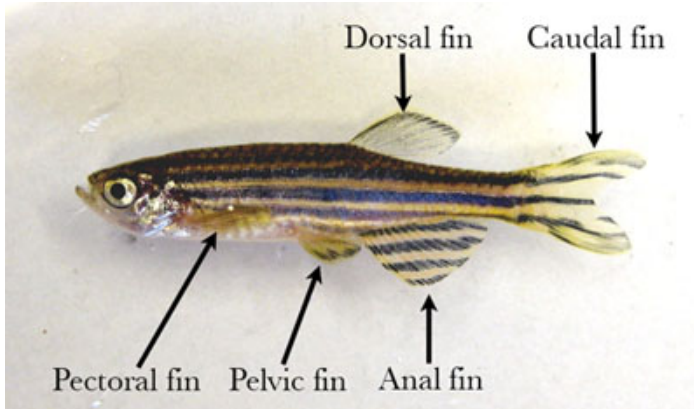
Over the last 20 years, the zebrafish has become a powerful model organism for understanding vertebrate development and disease. Although experimental analysis of the embryo and larva is extensive and the morphology has been well documented, descriptions of adult zebrafish anatomy and studies of development of the adult structures and organs, together with techniques for working with adults are lacking. The organs of the larva undergo significant changes in their overall structure, morphology, and anatomical location during the larval to adult transition. Externally, the transparent larva develops its characteristic adult striped pigment pattern and paired pelvic fins, while internally, the organs undergo massive growth and remodeling. In addition, the bipotential gonad primordium develops into either testis or ovary. This protocol identifies many of the organs of the adult and demonstrates methods for dissection of the brain, gonads, gastrointestinal system, heart, and kidney of the adult zebrafish. The dissected organs can be used for in situ hybridization, immunohistochemistry, histology, RNA extraction, protein analysis, and other molecular techniques. This protocol will assist in the broadening of studies in the zebrafish to include the remodeling of larval organs, the morphogenesis of organs specific to the adult and other investigations of the adult organ systems.

## Video Link

The video component of this article can be found at <http://www.jove.com/video/1717/>


## Protocol

1. A male zebrafish will be dissected first, followed by a female fish. Before beginning the dissection, anesthetize a fish in 0.2% Tricaine and then euthanize it by incubation in ice water for 15 minutes.
2. Begin by lightly patting the fish dry on a paper towel and placing it on a dissecting mat. Externally, zebrafish have single dorsal, caudal and anal fins and paired pectoral and pelvic fins (Figure 1).



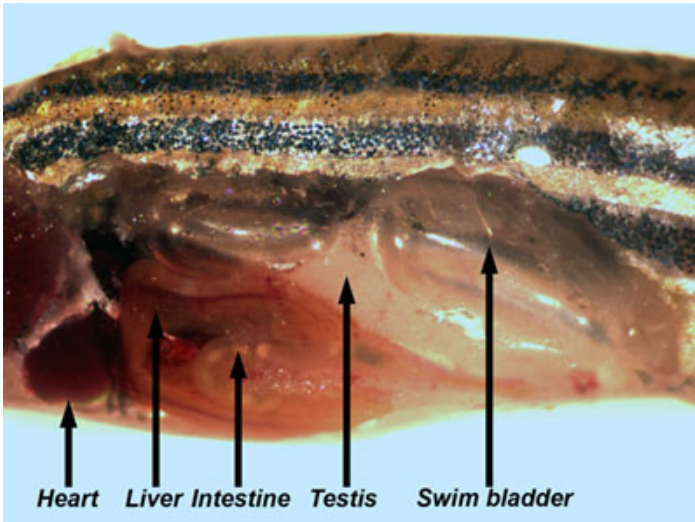
**Figure 1.** Adult male fish with fins labeled.

3. Pin the fish to the dissecting mat through the fleshy part of the tail and the ventral part of the eye socket.
4. Snip the skin on the belly of the fish just anterior to the anal fin. Cut the skin and underlying muscle along the belly from the anal fin to the operculum (the hard covering over the gill) (Figure 2, step 1).



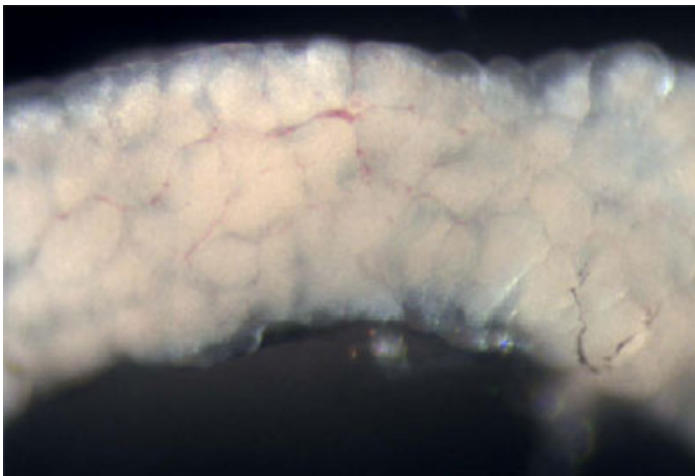
**Figure 2.** Steps in removing skin and body wall muscle to expose internal organs.

5. Next, remove the operculum and the pectoral fin, including the pectoral girdle (the thick, bony region at the base of the fin) (Figure 2, step 2). Cut the skin and underlying muscle beginning from above the now exposed gill posteriorly along the side of the fish and then down to the anal fin (Figure 2, step 3).
6. Carefully remove the skin and underlying muscle from the side of the fish. Many of the internal organs are now visible (Figure 3).



**Figure 3.** Adult male fish with body wall and muscle removed allowing the visualization of the internal organs.

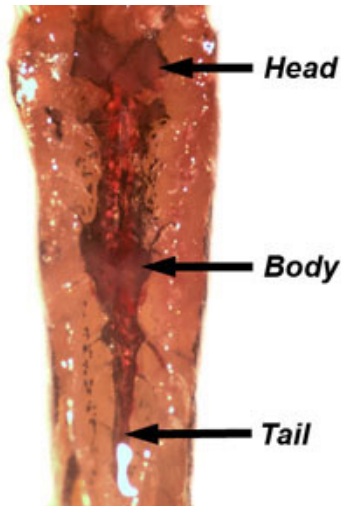
7. The testes are long, white, paired organs that are attached to the dorsal body wall. Remove a testis and place it in a dish of PBS. Examine the testis with reflected light to visualize the seminiferous tubules (Figure 4), which contain cysts with various stages of developing germ cells from spermatogonia to spermatids (Leal et al., 2009).



**Figure 4.** Dissection of a testis. The white roundish structures are the seminiferous tubules.

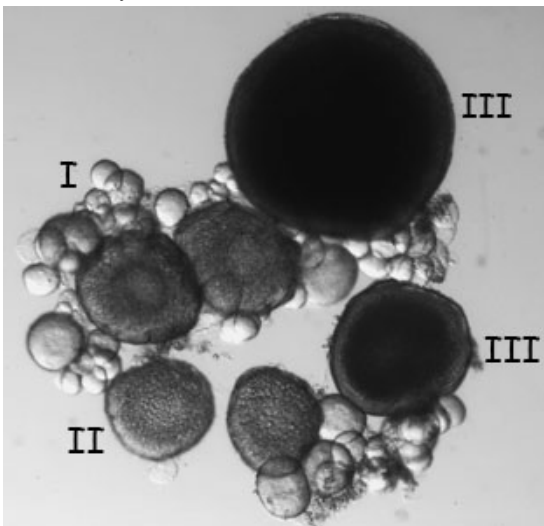
8. Next, remove the gastrointestinal system from the body cavity of the fish. The liver can be identified by its large size, lobed morphology, tannish color, and extensive vascularization. The gallbladder, a green translucent fluid-filled sac, and the spleen, which appears bright red, are found within the viscera.
9. Separate the intestine from the rest of the organs and stretch it out. The anterior, mid, and posterior regions of the intestine are defined by the height of the epithelial folds (Wallace et al., 2005).
10. Place a piece of the intestine in PBS and observe the epithelial folds using transmitted light.
11. Next, examine the swim bladder. The swim bladder consists of a posterior chamber, which is connected to the esophagus via the pneumatic duct, and an anterior chamber, which is connected to the inner ear through the Weberian apparatus (Finney et al., 2006).

12. Remove and discard the swim bladder. Unpin the fish and re-pin it ventral side up to dissect the kidney, which is located along the dorsal body wall. The kidney is a translucent pink structure associated with the dorsal aorta and pigmented cells. The kidney is divided into head, body, and tail regions (Figure 5). Dissect out a piece of the kidney and place it in PBS. Tease apart the kidney tissue to reveal the renal tubules.



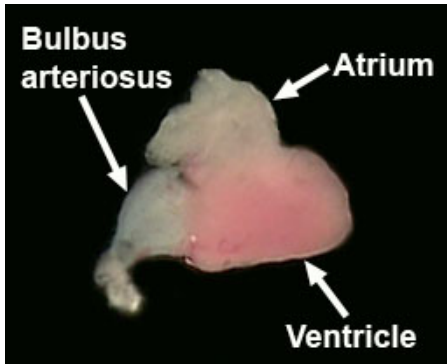
**Figure 5.** Location of head, body, and tail kidney along the dorsal body wall.

13. Dissect a female fish. As described previously, euthanize the fish in ice water and pat it dry before pinning it to the dissecting mat. Remove the skin from the side of the fish as previously demonstrated. The ovary is a bilobed structure that is suspended in the body cavity by a vascularized mesovarium.
14. Remove one lobe of the ovary, place it in PBS, and examine it with transmitted light. The oocytes can be teased apart using fine needles and then staged (Figure 6, Selman et al., 1993). Stage I oocytes are approximately 10 - 150 microns in size and translucent. Stage II oocytes are about 150 - 350 microns in size and defined by the appearance of cortical granules. Stage III oocytes are 350 - 750 microns in size and are opaque due to the accumulation of yolk. Mature stage IV and V oocytes are translucent and generally not found in the ovaries of females that have recently mated.



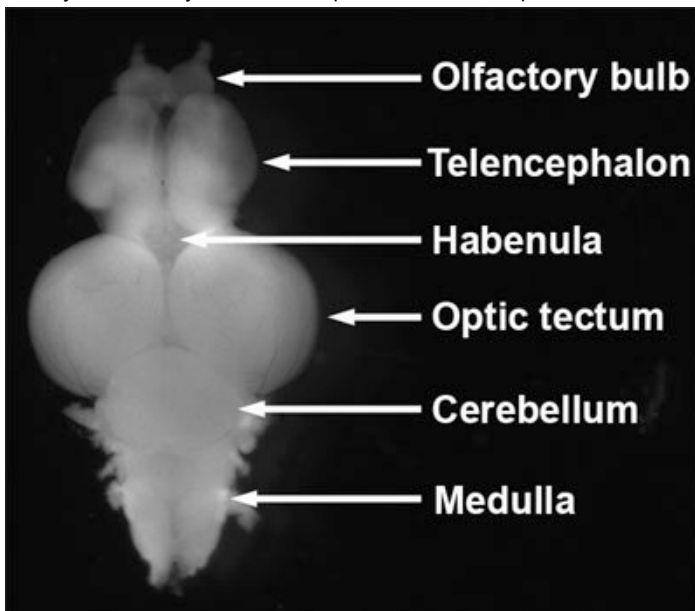
**Figure 6.** Live stage I, II, and III oocytes observed under a dissecting microscope with transmitted light.

15. Next, dissect the heart from the fish. The heart is located posterior and ventral to the gill. Begin by cutting out the heart and all of the surrounding tissue and placing it in PBS. Carefully dissect away the tissue surrounding the heart, being careful not to damage the delicate atrium.
16. Place the dissected heart into Ringer's solution to observe the heart beat. Identify the atrium, ventricle, and bulbus arteriosus (Figure 7, Hu et al., 2001).



**Figure 7.** Dissected adult heart.

17. Complete the dissection by removing the brain from the fish. Begin by unpinning the fish and removing the head with a razor blade. Remove as much soft tissue as possible from the ventral side of the skull with forceps. Remove the eyes using small spring scissors. Break open the skull and remove the bone from the ventral side of the brain. Now place the head in a dish of PBS and remove the skin and skull bones from the dorsal side of the brain.
18. Identify the olfactory bulbs, telencephalon, habenula, optic tectum, cerebellum and medulla (Figure 8, Wullimann et al., 1996; Schilling, 2002).



**Figure 8.** Dissected adult zebrafish brain. Dorsal view, anterior to top.

## Disclosures

Experiments on animals were performed in accordance with the guidelines and regulations set forth by the University of Pennsylvania Institutional Animal Care and Use Committee.

## Acknowledgements

This work was supported by NIH grant R01 HD050901 to MCM and American Cancer Society Postdoctoral Fellowship #PF-05-041-01-DDC to TG.

## References

1. Finney, J.L., Robertson, G.N., McGee, C.A., Smith, F.M., Croll, R.P. Structure and Autonomic Innervation of the Swim Bladder in the Zebrafish (*Danio rerio*). *J Comp Neurol.* 495, 587-606 (2006).
2. Hu, N., Yost, H.J., Clark, E.B. Cardiac morphology and blood pressure in the adult zebrafish. *Anat Rec.* 264, 1-12 (2001).
3. Leal, M.C., Cardoso, E.R., Nóbrega, R.H., Batlouni, S.R., Bogerd, J., França, L.R., Schulz, R.W. Histological and stereological evaluation of zebrafish (*Danio rerio*) spermatogenesis with an emphasis on spermatogonial generations. *Biol Reprod.* 81, 177-87 (2009).
4. Schilling, T.F. The morphology of larval and adult zebrafish. In *Zebrafish: A Practical Approach* (The Practical Approach Series, 261). Eds. Nusslein-Volhard, C., Dahm, R. Oxford University Press. (2002).

5. Selman, K., Wallace, R., Sarka, A., Qi, X. Stages of oocyte development in the Zebrafish, *Brachydanio rerio*. *J. Morphol.* 218, 203-224 (1993).
6. Wallace, K.N., Akhter, S., Smith, E.M., Lorent, K., Pack, M. Intestinal growth and differentiation in zebrafish. *Mech Dev.* 122, 157-173 (2005).
7. Wullimann, M.F., Rupp, B., and Reichert, H. *Neuroanatomy of the zebrafish brain : a topological atlas*. Birkhäuser Verlag, (1996).