

Idiopathic Transverse Myelitis and Neuromyelitis Optica: Clinical Profiles, Pathophysiology and Therapeutic Choices

Amer Awad^{1,*} and Olaf Stüve^{2,3}

¹Department of Neurology, Case Western Reserve University, Cleveland, OH, USA; ²Department of Neurology, University of Texas Southwestern Medical Center at Dallas, TX, USA; ³Neurology Section, VA North Texas Health Care System, Medical Service, Dallas, TX, USA

Abstract: Transverse myelitis is a focal inflammatory disorder of the spinal cord which may arise due to different etiologies. Transverse myelitis may be idiopathic or related/secondary to other diseases including infections, connective tissue disorders and other autoimmune diseases. It may be also associated with optic neuritis (neuromyelitis optica), which may precede transverse myelitis. In this manuscript we review the pathophysiology of different types of transverse myelitis and neuromyelitis optica and discuss diagnostic criteria for idiopathic transverse myelitis and risk of development of multiple sclerosis after an episode of transverse myelitis. We also discuss treatment options including corticosteroids, immunosuppressives and monoclonal antibodies, plasma exchange and intravenous immunoglobulins.

Keywords: Transverse myelitis, neuromyelitis optica, epidemiology, pathology, pathogenesis, treatment.

INTRODUCTION

Multiple sclerosis is the prototype of inflammatory disorders affecting the central nervous system. However, there are numerous inflammatory conditions, other than multiple sclerosis that have the central nervous system as their only or preferred target (Table 1). Early recognition of such syndromes is crucial for applying the appropriate therapy that can be quite different from that of multiple sclerosis. In this review we will focus the discussion on two important disorders closely related to multiple sclerosis: idiopathic transverse myelitis and neuromyelitis optica (Devic's disease). We will briefly discuss the epidemiology and clinical presentations of these diseases and provide detailed discussion on the pathophysiology and therapeutic approaches.

IDIOPATHIC TRANSVERSE MYELITIS

Transverse myelitis (TM) is a focal inflammation of the spinal cord of different etiologies. It can be idiopathic or related/secondary to other diseases. The percentage of idiopathic TM is expected to be declining due to the advances in neurodiagnostics and the discovery of new disease markers.

Epidemiology and Clinical Profiles

The annual incidence of TM in the United States is around 4.6 per million per year [1]. The incidence of idiopathic TM is about 1.34-4.6 per million per year [2]. However, a study by Young and his co-workers found much higher numbers (3-5 times higher) in the Australian population [2]. TM has a bimodal distribution with two distinct peaks: 10-19 and 30-39 years. It shows no racial,

familial or gender predilection [1, 3, 4]. About 28% of reported cases of TM are in pediatric population [5].

TM typically presents with acute to subacute myelopathy [6-12]. The symptoms usually progress over hours to few weeks. The thoracic cord is the most common to be affected for no clear reasons. Many patients present with flu-like symptoms prior to the myelopathy picture. The most common symptoms include: back pain (30-50%), lower limb paresthesias (80-95%), allodynia (80%), paraparesis (50%), bladder symptoms (almost 100%) and sensory level (80%).

The idiopathic TM proposed diagnostic criteria are shown in Table 2 [13]. Abnormal cord signal on spine magnetic resonance imaging (MRI) (Fig. 1) can be seen in around 75% (50-90%) [11, 14-17]. The cerebrospinal fluid (CSF) shows nonspecific signs of inflammation like elevated protein level and pleocytosis in about one half of adult patients, [1, 8, 17, 18] and about 80% of children with TM [14]. Oligoclonal bands in CSF are typically absent in non-MS related TM and if present are usually transient [17, 19]. TM is typically monophasic but relapsing TM does occur in about 20-30% [20-22]. Male gender, strict white matter involvement and normal CSF parameters seem to increase the risk of recurrence [23].

The most important findings that increase the chance of progression to MS include: abnormal brain MRI, incomplete (partial) iTM, the presence of oligoclonal bands in the CSF, abnormal visual and somatosensory evoked potentials and human leukocyte antigen (HLA) DR-2 status [2, 8, 24-28]. The rate of conversion to MS in patients with iTM with brain lesions ranges is 44-93% and without brain lesions is 15-44% [2]. Oligoclonal bands in CSF are frequent with iTM (~62% vs. 17%) [2].

Poor prognosticators include: back pain, rapid progression, cervical spine involvement, spinal shock, denervation

*Address correspondence to this author at the Department of Neurology, Case Western Reserve University, University Hospitals Case Medical Center, 11100 Euclid Ave. Cleveland, OH 44106, USA; Tel: 225-381-2670; Fax: 225-381-2671; E-mail: ameraldo@gmail.com

Table 1. Inflammatory Disorders Related to Multiple Sclerosis

1	Clinically isolated syndromes (optic neuritis, transverse myelitis)
2	Neuromyelitis optic (Devic’s disease)
3	Acute disseminated encephalomyelitis (ADEM)
4	Bickerstaff’s brain stem encephalitis
5	Neuro-Bahçet’s disease
6	Neurosarcoidosis
7	Neuro-Sjogren’s disease
8	Systemic lupus erythematosus (SLE)
9	Inflammatory ocular diseases
10	Central nervous system vasculitis
11	Arachnoiditis
12	Paraneoplastic encephalitic syndromes
13	Steroid-responsive encephalopathy (Hashimoto’s encephalopathy)
14	Infections (Inflammatory form of progressive multifocal leukoencephalopathy (PML), neurosyphilis, Whipple’s disease, human T-cell lymphoma-leukemia virus (HTLV-1), neuroberreliosis (Lyme’s disease), human immunodeficiency virus (HIV), neurobrucellosis, human herpes virus-6 (HHV-6), mycoplasma, subacute sclerosing panencephalitis (SSPE)

Table 2. Proposed Diagnostic Criteria for Acute Idiopathic Transverse Myelitis

Inclusion criteria
· Development of sensory, motor or autonomic dysfunction attributable to the spinal cord
· Bilateral signs and/or symptoms (though not necessarily symmetric)
· Clearly-defined sensory level
· Exclusion of extra-axial compressive etiology by neuroimaging (magnetic resonance imaging, or myelography; computerized tomography of spine not adequate)
· Inflammation within the spinal cord demonstrated by cerebrospinal fluid pleocytosis <i>or</i> Elevated IgG index <i>or</i> gadolinium enhancement. If none of the inflammatory criteria is met at symptom onset, repeat MRI and LP evaluation between 2-7 days following symptom onset meets criteria
· Progression to nadir between 4 hours to 21 days following the onset of symptoms (if patient awakens with symptoms, symptoms must become more pronounced from point of awakening)
Exclusion criteria
· History of previous radiation to the spine within the past 10 years
· Clear arterial distribution clinical deficit consistent with thrombosis of the anterior spinal artery
· Abnormal flow voids on the surface of the spinal cord consistent with arteriovenous malformation
· *Serologic or clinical evidence of connective tissue disease (sarcoidosis, Bahçet’s disease, Sjogren’s syndrome, systemic lupus erythematosus, mixed connective tissue disorder etc)
· *Central nervous system manifestations of syphilis, Lyme disease, human immunodeficiency virus (HIV), human T-cell lymphoma-leukemia virus(HTLV-1), mycoplasma, other viral infection (e.g. herpesviridae viruses , enteroviruses)
· *Brain magnetic resonance imaging abnormalities suggestive of multiple sclerosis
· *History of clinically apparent optic neuritis
* Do not exclude disease-associated acute transverse myelitis

on electromyography (EMG) and the presence of protein 14-3-3 in the CSF [9, 15, 29-31].

Pathology, Pathogenesis and Pathophysiology

Most of information on TM pathology comes from clinicopathological cases reports and autopsy studies [32-34]. All

patients who met the criteria for TM had inflammation. The lesions in acute TM are invariably limited to the spinal cord with no involvement of other structures in the central nervous system (CNS). The histopathology is characterized by demyelination and axonal loss in addition to gray matter involvement. Necrosis and cavitation can result in severe

cases. The cord involvement is usually central, uniform and symmetric in comparison to multiple sclerosis which typically affects the cord in a patchy way and the lesions are usually peripheral. Perivascular spread of monocytes; lymphocytes infiltrating focal areas of the cord along with astroglial and microglial activation are invariable findings on histopathology of TM. In some biopsies during the acute phases of TM, infiltrates of CD4⁺ and CD8⁺ T-lymphocytes were found to be prominent suggesting immune-mediated disease process. There is typically preservation of the subpial parenchyma suggesting ischemia as the ultimate cause of the cord lesions in TM. The pathology also differs depending on the etiology. For example necrotizing myelitis can be seen in NMO (see below) and paraneoplastic myelitis [35]. In MS and acute disseminated encephalomyelitis (ADEM) the lesions tend to have predilection to the white matter in comparison to the circumferential involvement in idiopathic TM [36].

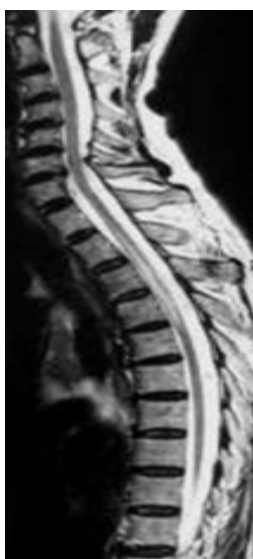

Fig. (1). T2 Sagittal spine MRI of a 30 year old lady presented to our hospital with left lower extremity weakness and low back pain showing the typical fusiform cord signal in TM.

Various infections precede 30-60% of the cases of TM [1, 3, 4, 7-9, 11, 37]. Reported infections include, but not limited to: herpesviridae, enteroviruses, influenza viruses, adenoviruses; coxsackie viruses; enteric cytopathogenic human orphan (ECHO) virus, hepatitis A virus; lymphocytic choriomeningitis virus (LCMV); mumps virus; measles virus, rubella virus, poliovirus, rubeola virus, dengue virus, Russian spring-summer encephalitis virus, varicella virus, mycoplasma pneumonia bacteria, legionella pneumonia bacteria, pulmonary tuberculosis, borrelia (Lyme disease), listeria, and bartonella (cat scratch disease) [4, 11, 38, 39]. About 30% of pediatric cases are preceded with immunizations within one month of disease onset [7, 11].

Infections can cause TM through direct tissue damage, [39-41] or by immune-mediated infection-triggered tissue damage which may be due to molecular mimicry or superantigen effect. The molecular mimicry theory is based on the fact that several infectious agents are capable of encoding molecular structures (e.g. proteins, glycolipids or proteogly-

cans) that mimic self antigens [4, 42-44]. Immune response to the mimic "pseudo-self" then may result in cross-reactive immune activation against self tissue. The immune response can be either T-cell mediated or antibody mediated. Superantigens are microbial peptides that are capable of inducing fulminant immune response by activating a large number of lymphocytes including autoreactive T- cells in a unique fashion by binding to the V β region of T cell receptor instead of highly variable peptide groove [45-49]. Superantigens are also capable of activating T- lymphocytes in the total absence of co-stimulatory molecules.

A non-microbial related immune dysfunction has been also proposed in the immunopathogenesis of TM. Some studies have described the presence of autoantibodies in TM [18, 22, 50]. Interleukin 6 (IL-6) levels were also markedly elevated in the spinal fluid of TM patients in comparison to control patients and to MS patients, and this also correlated with disability [4, 51]. IL-6 is secreted by astrocytes and microglia and binds to oligodendroglia and axons. High levels of IL-6 can cause direct tissue injury and indirect damage by inducing nitric oxide synthetase in microglia. Interestingly, Interferon-beta (IFN- β), a medication used to treat MS, was found to induce IL-6 [52]. IL-6 has probably a bell-shaped effect where at certain levels could cause damage and at different levels can induce repair [51, 53, 54].

One study that was conducted in Japan found that several patients with TM have much higher serum IgE levels than MS patients or controls pointing towards immune-mediated process as well [55]. Concordant with these findings, tissue biopsies of two patients with TM and elevated total and specific serum IgE disclosed the presence of antibody deposition within the spinal cord and perivascular infiltration with eosinophils that could induce tissue damage [56].

Current Therapies

The main therapies available for TM include: high dose intravenous methylprednisolone (IVMP), plasma exchange and/or intravenous cyclophosphamide. There are no placebo-controlled randomized trials to support the use of IVMP in TM despite the positive clinical experience. However, there are several small observational studies that documented clinical benefit of IVMP in TM, if given in the acute phase, in terms of faster recovery and disability in addition to good tolerability [57-62]. The rationale of using steroids in TM is based on its numerous effects on the immune system leading to a global immunosuppression. Some of these effects include but not limited to: inhibition of lymphocyte proliferation and differentiation, redistribution of lymphocytes, alteration of lymphokine function especially tumor necrosis factor (TNF), IL-1 and IL-2, and inhibition of macrophage function, in particular antigen presentation and processing.

In comparison to steroids, use of plasma exchange in TM is supported by randomized trials. It is commonly initiated in severe cases of TM and in cases unresponsive to pulse steroids. Plasma exchange is an effective way to remove "autoreactive antibodies" and other toxic molecules from the plasma and hence, it is a very common procedure in the acute and rescue treatment of autoimmune diseases. Several

studies have shown significant clinical benefit for plasma exchange in TM [63-66]. Based on the NMO literature (see below), early initiation of plasma exchange within 20 days of attack onset predicts greater likelihood of clinical response [65].

There is currently no solid evidence to support the use of immunosuppressive therapy in TM. Cyclophosphamide, an alkylating agent that showed some promising results in MS can be used in idiopathic TM, especially in severe cases [67]. A retrospective study of 13 patients with idiopathic TM, intravenous cyclophosphamide in combination with plasma exchange was shown to be superior to plasma exchange alone in patients with complete TM [66]. Cyclophosphamide, in addition to its antimetabolic effect, has significant immunosuppressive and immunomodulatory actions making it an effective treatment for immune-mediated disorders. It causes suppression of cell-mediated and humoral immunity through its actions on T cells and B cells [68]. In multiple sclerosis, for example, cyclophosphamide was shown to decrease the secretion of the pro-inflammatory cytokines like IFN- γ and IL-12 and increase the secretion of the anti-inflammatory cytokines like IL-4 and IL-10 in cerebrospinal fluid (CSF) and peripheral blood [69]. However, due to the significant side effects like gonadotoxicity and bladder toxicity its use should be individualized and carefully initiated and monitored. Other oral immunosuppressive agents like mycophenolate, azathioprine and methotrexate can also be considered in recurrent cases despite the lack of evidence. In our clinical experience we use IVMP alone if the patient presents with non-motor symptoms, plasma exchange in patients presenting with incomplete TM with motor symptoms and cyclophosphamide if the patient presents with complete TM. Cyclophosphamide, in our experience is a well-tolerated and a relatively safe medication if used appropriately and in the right clinical setting. We discussed cyclophosphamide in great details in a separate review that was recently published in 2009 [67].

Interferon- β (IFN- β) and glatiramer acetate (GA) have a well-established role in MS and they are FDA-approved for the treatment of MS. They also have well-documented benefit in clinically isolated syndromes *with brain lesions* [70-73]. In conclusion, IFN- β and GA would be ideal choices in patients with TM that carry a high risk of conversion to MS.

The ultimate therapy of TM would be targeted therapy once the targets are clearly defined. Like in all neurological disorders, the search for the ideal neuroprotection that can be used in combination with the treatments mentioned above probably provides the most practical treatment strategy at this time. The use of erythropoietin in TM is under investigation. Erythropoietin was shown to be neuroprotective in different models of nerve injury in animal studies, [74, 75] and clinical studies are planned to investigate the safety, tolerability and efficacy of erythropoietin in TM patients.

NEUROMYELITIS OPTICA SPECTRUM (DEVIC'S DISEASE)

Neuromyelitis optica (NMO) is an idiopathic, probably immune-mediated, destructive demyelinating syndrome of the CNS with predilection to optic nerves and spinal cord.

Epidemiology and Clinical Profiles

NMO has a significant female to male predominance (9:1), and affects mainly young people with a median age of onset in the late 30's [76-78]. In the United States it mainly affects Caucasians but the other racial groups are significantly afflicted in comparison to MS [76, 77, 79-81]. NMO does occur in children with an average age of 10 years (7-14 years) [82, 83]. Opticospinal MS (OSMS), which is *controversially* recognized as part of NMO spectrum, is prevalent in Japan [84]. NMO may account for 1% of inflammatory demyelinating disease (IDD) of the CNS among Caucasians, but represents almost 30% of total IDD in Japan [85].

Familial clusters of NMO have been described in scattered reports in the literature with no conclusive evidence [86, 87].

NMO is quite different from MS clinically, radiologically, pathologically and in terms of treatment approaches. The distinction is of paramount importance because management and prognosis are fundamentally different. Clinical onset is usually acute and in two thirds of cases, a prodrome of flu-like symptoms may precede neurologic deficits [82, 88]. Various viral and non-viral infectious have been seen to precede neurologic symptoms of NMO with no conclusive association [89-96].

The first manifestation of neuromyelitis optica is ON in up to three fourths of patients, TM in up to one third and concomitant ON and TM in up to one tenth of patients [88, 97]. The interval between visual and cord symptoms is extremely variable, ranging between days to years [88, 98, 99]. ON is unilateral in 65-85%, but bilateral simultaneous ON or sequential ON in rapid succession is more suggestive of NMO [100]. NMO-ON clinical features are similar to MS-related ON but more severe leading to complete visual loss in 40% of patients [101]. In 5 years, more than half of patients with relapsing NMO are blind in one or both eyes or require ambulatory help [100]. NMO-TM is usually severe, as well. It is typically longitudinally extensive TM (LETM); extending over 3 or more cord signals [101]. The spinal cord inflammation is usually symmetric causing symmetric involvement of motor and sensory tracts [101]. Cervical LETM in NMO may extend into the medulla resulting in nausea, persistent hiccups, and even fulminant respiratory failure [88, 102]. Lhermitte sign, tonic spasms and radicular pain are reported in one third of NMO patients [101, 103]. Lhermitte sign and the paroxysmal tonic spasm indicate a relapsing more than a monophasic course [101].

NMO is monophasic in 10-30% of cases and relapsing 60-90% of cases [101]. As mentioned above, NMO ON and TM attacks are typically more severe and recovery is less complete compared with MS [100]. The relapse rate is higher than in MS, frequency of a second episode within the first 2 years is also higher than in MS (82% vs. 62%) and the median time to reach expanded disability status scale (EDSS) of 6.0 is shorter than MS (7.0 years vs. 9.4 years) [97]. Relapses occur within 6 months of the initial attack in 55% of patients, within 18 months in 27%, and after 5 years in 18% [88]. The mean interval until a second attack is about 17

months [97]. In comparison to adults, children with NMO have fewer relapses [82, 104].

In contrast to MS, secondary progression is quite rare and progression only takes place during the attack and disability is a result of the clinical cumulative effect of relapses rather than secondary progression [100]. The monophasic form has a better prognosis than the relapsing form [97-99, 101]. The survival rate at 5 years may amount to 90% in the monophasic groups and 68% in the relapsing group. Poor outcome and mortality are directly related to high relapse rate during the first 2 years [97, 100, 105].

MR imaging of the spine is very helpful in diagnosing NMO. In the acute phase it typically shows LETM with a T2 cord signal with cord expansion and gadolinium enhancement (Fig. 2a) [106]. In the chronic stage the enhancement and expansion resolve while the T2 signal persists but the LETM regresses to less than 3 segments and breaks up into shorter fragments and the cord becomes atrophic (Fig. 2b) [106]. Up to 60% of NMO patients will develop non-specific asymptomatic subcortical white matter lesions at a mean follow up of 6+/-5 years [107]. Ten percent of patients have specific lesions in the diencephalon (thalamus, hypothalamus), corpus callosum, hypophysis, brainstem (periaqueductal) and around 10% of NMO patients will develop lesions that meet the specific MS criteria [107-109]. Magnetization transfer (MT) and diffusion tensor imaging (DTI) disclosed microscopic pathology in the normally appearing gray matter (NAGM) in the brain of patients with NMO [110].

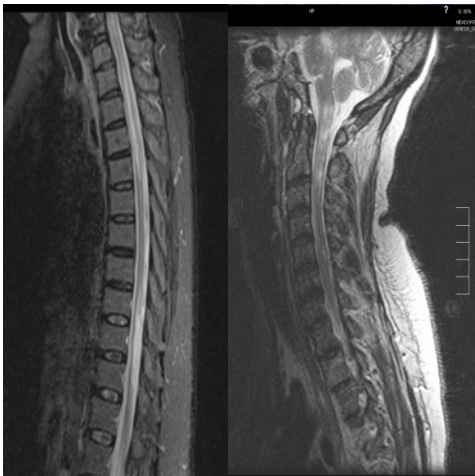


Fig. (2a, b). Fig. (2a) shows a T2 sagittal spine MRI of a 38 year-old woman who presented to our hospital with acute incomplete paraparesis displaying the typical LETM in acute NMO. Fig. (2b) shows a T2 sagittal spine MRI of a 51 year-old woman with chronic relapsing NMO showing the typical manifestations of chronic NMO including cord atrophy and patchy lesions.

Optical coherence tomography (OCT) is a relatively new noninvasive method of evaluating the thickness of the retinal nerve fiber layer (RNFL). The mean retinal nerve fiber layer thickness is significantly reduced in patients with NMO compared with controls and has good correlation with EDSS [111]. Findings on OCT could potentially differentiate NMO ON vs. MS ON. NMO ON is associated with a thinner

mean RNFL compared to MS and the superior and inferior quadrants were more severely affected in NMO than MS [112-114].

In terms of CSF studies, NMO profile is quite distinct from MS. The white blood cell count (WBC) is usually 50-1000 cells/mm³ vs. 0-50 in MS, shows neutrophilic predominance vs. lymphocytic predominance in MS [101]. CSF pleocytosis is more prominent during the acute attack of TM more than ON and has a specificity of 95% and sensitivity of less than 30% [101]. Patients with severe TM accompanied by marked CSF pleocytosis (more than 100 leukocytes/mm³) have typically poor outcome [88]. CSF oligoclonal bands are seen in 15-30% in NMO vs. 85% in MS and have low sensitivity and specificity in NMO [101]. An elevated IgG index is only seen in 20% of NMO patients [101]. Up to one half of patients with NMO have positive serological immunological markers like (antinuclear antibody (ANA), extractable nuclear antigens (ENAs), anti-thyroid antibodies, anti-cardiolipin antibodies, anti-parietal cell antibodies and acetylcholine receptor antibodies [101, 115-120].

Seropositivity for Sjögren's syndrome (SS)-A (anti-Ro) antibody is modestly predictive of relapse in patients with the first TM attack, seen in 77% of relapsing NMO vs. 33% of monophasic NMO [121]. For relapsing NMO, the odds ratio for having another autoimmune disease is increased by 10-fold [100]. Risk factors for recurrence include: NMO-IgG seropositivity, female gender, older age (>30 years), less severe motor impairment after the myelitic onset, longer interval between the first and second attack (>6 months) and systemic autoimmunity [88, 100, 101].

Diagnostic Criteria for NMO were initially proposed in 1999 [101]. However, the discovery of NMO-IgG antibody [122] revolutionized the diagnosis of NMO and the criteria were revised in 2006 (Table 3) [84]. In a cohort of patients examined between 1999 and 2005, the new criteria were 99% sensitive and 90% specific for neuromyelitis optica, compared to the previous criteria, which were 85% sensitive and 48% specific [123]. In summary, NMO antibody and MRI spine are the most important diagnostic tools for NMO.

Table 3. Revised Diagnostic Criteria for Definitive NMO

- | |
|---|
| <ol style="list-style-type: none"> 1. Optic neuritis 2. Acute myelitis 3. Two out of three supportive criteria that include: <ul style="list-style-type: none"> • Continuous spinal cord MRI lesion extending over 3 or more vertebral segments • Brain MRI not meeting diagnostic criteria for MS • NMO-seropositive status |
|---|

The discovery of NMO antibody has revolutionized the accuracy of NMO diagnosis and broadened the spectrum of NMO syndromes more than previously appreciated but its role in pathogenesis is controversial and unclear. NMO antibody was discovered by Lennon and co-workers 2004

[122]. Its sensitivity ranges from 58-76% and specificity ranges from 85- 99% [84, 122, 124, 125]. In a large study comparing the sensitivity and specificity of immunofluorescence (IF) and immunoprecipitation (IP) assays using green fluorescent protein-tagged Aquaporin-4 (AQP4), the sensitivity rates for NMO were higher using IF technique and improved by 5% using combined methods [126]. NMO antibody is also seen in syndromes closely related to NMO, for example: recurrent LETM (52%), recurrent isolated ON (25%), and the Japanese form of optic-spinal MS (58%) which expands NMO to syndromes rather than one disease though the associations are still debatable and not completely understood [122]. Its target antigen is the water channel aquaporin-4 (AQP-4). Aquaporins are involved in fluid balance and cell water homeostasis and AQP-4 is the most common type found in the CNS specifically on astrocytes foot processes, the abluminal surface of blood vessels (glia limitans) and concentrated in the periependymal regions of the brain [127-129]. We will discuss the role of NMO antibody in NMO pathogenesis in a separate section. In conclusion, NMO is a very specific marker that defines the NMO spectrum of disorders: complete NMO and incompletely developed (restricted) type of NMO [77, 122, 130]. Its role in pathogenesis is unclear. It was shown also to predict a relapsing course and a poor outcome in some studies [123, 131].

Pathology, Pathogenesis and Pathophysiology

Spinal cord specimens from patients with NMO typically show evidence of perivascular inflammatory demyelination with high proportion of polymorphonuclear cells (PMN) and eosinophils, deposition of IgM and complement C9 neoantigen in addition to hyalinization of spinal cord arteries with gray and white matter necrosis [102, 129, 132-135]. Contrary to MS lesions, there is rare infiltration with CD3⁺ and CD8⁺ lymphocytes [85]. Prominent vasculocentric IgG and complement deposits, with vascular proliferation and fibrosis are also typical findings in NMO and correspond to AQP-4 site of expression and might be related to humoral immune activation and a pathogenic NMO-IgG. The anterior optic pathway shows significant demyelination and cavitation in NMO specimens as well [98].

The etiology of neuromyelitis optica remains unknown. A possible role for autoimmunity in the pathogenesis is suggested by several observations. The overlap with other autoimmune diseases and the wide range of positive autoantibodies in the serum of patients with NMO, as mentioned above, suggests polyclonal B cell activation [132]. The discovery of the specific NMO antibody supports the autoimmune theory as well. The role of infections in NMO pathogenesis is not clear, but the various infections that may precede NMO neurological symptoms could theoretically induce immune dysregulation (see the section on infections and TM). The immunohistological findings of prominent infiltration with neutrophils, eosinophils, and IgM deposition in the lesions also support the immunological theory, especially the significant involvement of humoral immunity in the immunopathogenesis of NMO. A recent molecular study by

Pentón-Rol and co-workers found that the levels of IL-10 and tumor necrosis alpha (TNF- α) were undetectable pointing to immunoregulatory dysfunction [136]. The good clinical response to immunomodulatory treatments (see below) also supports the immune theory. Besides, increased number of myelin oligodendrocyte glycoprotein-specific B cells was also demonstrated in NMO pointing towards dysregulation of humoral immunity [137]. Very interestingly, several reports have described elevated prolactin levels in some patients with NMO spectrum [108, 138, 139]. The elevated prolactin levels were seen mostly in Asian and black women and was concordant with the presence of ON. The elevated prolactin could be a result or a contributing factor. The extension of inflammation to involve the hypothalamus could result in disinhibition of prolactin release. Prolactin, on the other hand, is a potent immune stimulant for T helper cell 1 (T_H1) cell responses that could be involved in the initiation or sustenance of the neuroinflammation [140]. Of note, elevated prolactin levels is not a unique finding to NMO and there are numerous reports of hyperprolactinemia in other autoimmune diseases especially SLE [141, 142].

The role of genetic factors in NMO is not determined yet. There is evidence, however, that NMO is associated with HLA alleles DR1*801, DP1 501, DPA1 202, DPB1*1501, DRB*03 but not with DRB1*1501 or DRB5*0101, which are classically associated with MS [143-146]. These findings may suggest a possible genetic role in the disease process.

The role of NMO Ig-G antibody in the immunopathogenesis of NMO is quite complicated and not well-understood. The observation that brain lesions in NMO occur in areas with high concentration of AQP-4 brought the attention to the role of the anti-AQP-4 antibody in the disease process [107]. However, there are several observations that argue against the pathogenic role of the antibody. Firstly, The brain lesions are not really the sine qua none of NMO and they're usually clinically insignificant despite the high density of AQP-4 in the brain. In addition, AQP-4 is present in the kidney and gastrointestinal tract, but involvement of these regions has not been described in neuromyelitis optica so far and AQP-4 does not explain the distribution of NMO lesions. Pathological studies have failed to demonstrate the presence of NMO antibody in NMO lesions [147, 148].

The NMO experience with animal models is very interesting. When human NMO-IgG antibody was given to rats, NMO pathology could not be reproduced, but when it was injected into animals induced for experimental autoimmune encephalomyelitis (EAE), NMO lesions were then reproduced. The conclusion that can be drawn from these findings is that a disruption of blood brain barrier may facilitate the pathogenic role (if any) of NMO antibody. The bottom line is that the pathogenic role of the AQP-4 antibody is unknown and needs to be studied more carefully before drawing any solid conclusion.

The relation between NMO and OSMS is controversial and debatable. For example, several reports argued that OSMS is quite distant from NMO from a pathologic point of view [132, 149, 150]. The immunologic studies found that

OSMS is mostly T helper cell 1 (T_H1)-related disease in comparison to NMO which is thought to be T helper cell 2 (T_H2) and B-lymphocyte-driven making them completely different diseases. Further studies are needed to clarify the relation between NMO and OSMS.

Current Therapies (Table 4)

There are currently no FDA-approved medications for NMO due to the lack of large double-blinded randomized placebo-controlled trials.

Intravenous pulse steroids (IVMP 1 gram IV every 24 hours for 5 days followed by oral steroid taper is the usual treatment of acute attacks of NMO [151]. The immunological effects of steroids are discussed in the TM section. Rescue treatment with plasma exchange is supported by several clinical trials [63, 65, 152]. Early initiation of plasma exchange within 20 days of attack onset predicts greater likelihood of clinical response [65]. There are few case reports of lymphocytapheresis as being effective in NMO as well [153]. Plasma exchange and lymphocytapheresis aim at removing the "pathogenic" factors from plasma as mentioned above in the TM section.

The most promising treatment for relapsing NMO is probably rituximab. Rituximab is a monoclonal antibody that targets cluster of differentiation (CD) 20+ cells but its exact mode of action remains unclear [154]. Possible actions may include: induction of antibody-dependent cell cytotoxicity (ADCC) and complement-dependent cytotoxicity, regulatory effects on cell cycle, increase antigen presentation, down-regulation of B-cell receptors and induction of B-cell apoptosis. An open label study of the effects of rituximab in NMO showed that 6/8 patients with worsening NMO refractory to prior therapy, treated with IV rituximab, remained relapse free for a 6-18-month follow up and the median at-

tack rate declined from 2.6 to 0 attacks per patient per year ($p=0.0078$) [155]. The typical dose used is 1000mg (1gm) or 375mg/m² IV infusion followed by monthly monitoring of CD19 count and once CD19 levels are detectable, rituximab is redosed [155]. Side effects of rituximab may include but not limited to: infusion-related reactions, increased risk for reactivation of tuberculosis (TB), hepatitis B virus (HBV) and JC virus [155]. Jacob and co-workers conducted a retrospective analysis of 25 patients with NMO of whom 23 had frequent relapses despite the use of medical therapy [156]. Infusions of rituximab at median intervals of 8 months decreased the median relapse rate after a median follow up of 19 months (0-3.2 (post-treatment) vs. 0.5-5 (pre-treatment) relapses, $P < .001$). Very recently, a trial of rituximab in 3 patients with NMO showed significant reduction of relapse rate [157]. The annualized relapse rate for the 3 patients during the year before rituximab therapy was 4, 5, and 6, respectively, and this decreased to 3, 1, and 0 in the year after therapy. In our clinical experience, we use one induction dose of rituximab and then we follow the CD19 counts and redose once the CD19 is detectable ($\geq 1\%$), typically every 6-9 months for ≤ 2 years. Weekly infusions of rituximab for 4 weeks as induction protocol have been used especially in treating rheumatologic disorders like refractory rheumatoid arthritis [158]. The natural course of the disease in NMO mandates *aggressive* and *emergent* treatment because the attacks carry a high risk of disability and in some cases the attacks can be fatal. It cannot be overemphasized that NMO should be treated aggressively since we have a very small room for trial and error. Studies comparing the efficacy and safety of different dosing regimens are needed to unify our approach in treating these patients.

In our experience, if a patient relapses while sufficiently treated with rituximab, we treat the acute exacerbation with high dose IV steroids in addition to plasma exchange and IV

Table 4. Management of Neuromyelitis Optica

Medication	Use	Typical dose	Evidence
High dose IV methylprednisolone	Acute	1 gm IV daily for 5 days with or without a taper	Observational studies
Plasma exchange	Acute as a rescue therapy	5 exchanges (each exchange 250 ml) over 5-10 days	Randomized trials in TM patients
Rituximab	Maintenance	1 gm (or 375 mg/m ²) IV every 1-2 weeks for 2-4 weeks then redoses based on CD19 count (typically every 6-8 month) for ≤ 2 years	Several open label and retrospective clinical trials
Azathioprine	Maintenance	2 mg/kg PO divided BID (typically 100 mg BID) for ≤ 2 years	Observational studies
Mycophenolate	Maintenance	1-3 gm PO daily divided BID or TID for ≤ 2 years	Retrospective trial
Methotrexate	Maintenance	5-15 mg PO weekly for ≤ 2 years	Open label trial
Mitoxantrone	Maintenance	12 mg/m ² every 3 months (maximum dose 140 mg/m ²)	Open label trial
Cyclophosphamide	Maintenance	0.5-1.5 mg/m ² (typically 1 gm) IV every month until absolute lymphocyte count $< 1000/\text{mm}^3$ (typically 6 cycles) or immunoablative dose of 200 mg/kg divided over 4 days	Open label trial
IVIg	Maintenance	2 gm/kg induction followed by 0.4-0.5 gm/kg every month	Case series

cyclophosphamide in refractory cases. After stabilizing the patient we would switch the patient to IV cyclophosphamide.

Other immunomodulatory therapies that have showed good results in NMO include: azathioprine, mitoxantrone, methotrexate, mycophenolate, cyclophosphamide and intravenous immunoglobulin (IVIG). Azathioprine (2-3 mg/kg/day) in combination with oral prednisone (1mg/kg/day) was used in an observational case series of 7 patients was shown to be effective in prevention of relapses in NMO [159]. The drug is a purine analog which is metabolized to 6-meraptopurine (MP) and ultimately, becomes incorporated into replicating DNA and can also block the de novo pathway of purine synthesis [160]. Its relative specificity to lymphocytes is explained by the lack of the salvage pathway of purine synthesis [160]. Mitoxantrone was also shown to be helpful in NMO [161]. Mitoxantrone is as a doxorubicin analogue that modulates the immune system by several mechanisms. It suppresses the proliferation of T cells, B cells, and macrophages, impairs antigen presentation and decreases the secretion of proinflammatory cytokines, enhances T-cell suppressor function and inhibits B-cell function and antibody production and inhibits macrophage-mediated myelin degradation [162]. Methotrexate was also tried in NMO and showed some benefit. Methotrexate, at lower doses, has been shown to be very effective for the management of many autoimmune disease due the inhibition of enzymes involved in purine metabolism, leading to accumulation of adenosine, or the inhibition of T cell activation and suppression of intercellular adhesion molecule expression by T cells [163]. Mycophenolate is another immunosuppressant that has been used in NMO patients. It was found to decrease relapse rate in a retrospective trial of 24 patients with NMO spectrum [164]. Mycophenolate mofetil is metabolized in the liver to the active moiety mycophenolic acid which then inhibits inosine monophosphate dehydrogenase, the enzyme that controls the rate of synthesis of guanine monophosphate in the de novo pathway of purine synthesis used in the proliferation of B and T lymphocytes [165]. As mentioned above, the lack of salvage pathway in lymphocytes renders them targets for the action of inhibitors of de novo pathway of purine synthesis. Immunoablative doses of cyclophosphamide were shown to control disease progression in intractable cases of NMO [166]. Immunological mechanisms of action of cyclophosphamide are described in the TM section. Using immunoablative doses of cyclophosphamide is an intriguing and relatively novel approach that had very promising results in MS as well [67]. Repeated IVIG infusions were also used in 2 patients with NMO and showed some positive results [167]. The exact mechanism by which IVIG suppresses inflammation has not been definitively established but is believed to involve the inhibitory Fc receptor which can lead to decreased antigen presentation [168]. IVIG may work *via* inducing an immune complex formation that binds Fc receptors on dendritic cells that probably mediate its anti-inflammatory effects [169]. It may also work by directly binding the pathogenic antibodies or *via* complement activation “complement scavenging effect” [170]. IVIG also reacts with a number of membrane receptors on T cells, B cells, and monocytes that are pertinent to autoreactivity and induction of tolerance to self [171]. A

recent report stated that IVIG application to activated T cells leads to their decreased ability to engage microglia [172].

Immunomodulators that are typically used in treating MS like IFN- β were found to be ineffective and even harmful in patients with NMO based on small trials [173]. Up to our knowledge, there is only one reported case of NMO that responded to GA [174]. Making decisions on single reported cases can be done but with extreme caution. Based on the current evidence, we cannot recommend using IFN- β and GA in the treatment of NMO. Since recovery is usually incomplete and the attack is more debilitating than in MS, there is a small room for trial and error when it comes to treatment of NMO and only the most effective treatment should be offered.

As we mentioned in the TM section, future therapeutic approaches should focus on neuroprotection and targeted therapy. There no ongoing clinical trials, up to our knowledge, studying neuroprotection in NMO.

REFERENCES

- [1] Jeffery, D.R., Mandler, R.N., Davis, L.E. Transverse myelitis. Retrospective analysis of 33 cases, with differentiation of cases associated with multiple sclerosis and parainfectious events. *Arch. Neurol.*, **1993**, *50*(5), 532-535.
- [2] Young, J., Quinn, S., Hurrell, M., Taylor, B. Clinically isolated acute transverse myelitis: prognostic features and incidence. *Mult. Scler.*, **2009**, *15*(11), 1295-302.
- [3] Christensen, P.B., Wermuth, L., Hinge, H.H., Bomers, K. Clinical course and long-term prognosis of acute transverse myelopathy. *Acta Neurol. Scand.*, **1990**, *81*(5), 431-435.
- [4] Krishnan, C., Kaplin, A.I., Deshpande, D.M., Pardo, C.A., Kerr, D.A. Transverse Myelitis: pathogenesis, diagnosis and treatment. *Front. Biosci.*, **2004**, *9*, 1483-1499.
- [5] Pidcock, F.S., Krishnan, C., Crawford, T.O., Salorio, C.F., Trovato, M., Kerr, D.A. Acute transverse myelitis in childhood: center-based analysis of 47 cases. *Neurology*, **2007**, *68*(18), 1474-1480.
- [6] Scott, T.F., Bhagavatula, K., Snyder, P.J., Chieffe, C. Transverse myelitis. Comparison with spinal cord presentations of multiple sclerosis. *Neurology*, **1998**, *50*(2), 429-433.
- [7] Paine, R.S., Byers, R.K. Transverse myelopathy in childhood. *Am. J. Dis. Child.*, **1953**, *85*(2), 151-163.
- [8] Lipton, H.L., Teasdall, R.D. Acute transverse myelopathy in adults. A follow-up study. *Arch. Neurol.*, **1973**, *28*(4), 252-257.
- [9] Ropper, A.H., Poskanzer, D.C. The prognosis of acute and subacute transverse myelopathy based on early signs and symptoms. *Ann. Neurol.*, **1978**, *4*(1), 51-59.
- [10] Dunne, K., Hopkins, I.J., Shield, L.K. Acute transverse myelopathy in childhood. *Dev. Med. Child Neurol.*, **1986**, *28*(2), 198-204.
- [11] Knebusch, M., Strassburg, H.M., Reiners, K. Acute transverse myelitis in childhood: nine cases and review of the literature. *Dev. Med. Child Neurol.*, **1998**, *40*(9), 631-639.
- [12] de Seze, J., Stojkovic, T., Breteau, G., Lucas, C., Michon-Pasturel, U., Gauvrit, J.Y., Hachulla, E., Mounier-Vehier, F., Pruvo, J.P., Leys, D., Destee, A., Hatron, P.Y., Vermersch, P. Acute myelopathies: Clinical, laboratory and outcome profiles in 79 cases. *Brain*, **2001**, *124*(Pt 8), 1509-1521.
- [13] Proposed diagnostic criteria and nosology of acute transverse myelitis. *Neurology*, **2002**, *59*(4), 499-505.
- [14] Miyazawa, R., Ikeuchi, Y., Tomomasa, T., Ushiku, H., Ogawa, T., Morikawa, A. Determinants of prognosis of acute transverse myelitis in children. *Pediatr. Int.*, **2003**, *45*(5), 512-516.
- [15] Kalita, J., Misra, U.K., Mandal, S.K. Prognostic predictors of acute transverse myelitis. *Acta Neurol. Scand.*, **1998**, *98*(1), 60-63.
- [16] Miller, D.H., McDonald, W.I., Blumhardt, L.D., du Boulay, G.H., Halliday, A.M., Johnson, G., Kendall, B.E., Kingsley, D.P., MacManus, D.G., Moseley, I.F., Rudge P., Sandercock P.A.G. Magnetic resonance imaging in isolated noncompressive spinal cord syndromes. *Ann. Neurol.*, **1987**, *22*(6), 714-723.

- [17] Austin, S.G., Zee, C.S., Waters, C. The role of magnetic resonance imaging in acute transverse myelitis. *Can. J. Neurol. Sci.*, **1992**, *19*(4), 508-511.
- [18] Tippett, D.S., Fishman, P.S., Panitch, H.S. Relapsing transverse myelitis. *Neurology*, **1991**, *41*(5), 703-706.
- [19] Kesselring, J., Miller, D.H., Robb, S.A., Kendall, B.E., Moseley, I.F., Kingsley, D., du Boulay, E.P., McDonald, W.I. Acute disseminated encephalomyelitis. MRI findings and the distinction from multiple sclerosis. *Brain*, **1990**, *113*(Pt 2), 291-302.
- [20] Ravaglia, S., Bastianello, S., Franciotta, D., Ceroni, M., Pichiecchio, A., Tavazzi, E., Moglia, A., Marchioni, E. NMO-IgG-negative relapsing myelitis. *Spinal Cord*, **2009**, *47*(7), 531-537.
- [21] Ungurean, A., Palfi, S., Dibo, G., Tiszlavicz, L., Vecsei, L. Chronic recurrent transverse myelitis or multiple sclerosis. *Funct. Neurol.*, **1996**, *11*(4), 209-214.
- [22] Pandit, L., Rao, S. Recurrent myelitis. *J. Neurol. Neurosurg. Psychiatry*, **1996**, *60*(3), 336-338.
- [23] Kim, K.K. Idiopathic recurrent transverse myelitis. *Arch. Neurol.*, **2003**, *60*(9), 1290-1294.
- [24] Bakshi, R., Kinkel, P.R., Mechtler, L.L., Bates, V.E., Lindsay, B.D., Esposito, S.E., Kinkel, W.R. Magnetic resonance imaging findings in 22 cases of myelitis: comparison between patients with and without multiple sclerosis. *Eur. J. Neurol.*, **1998**, *5*(1), 35-48.
- [25] Bashir, K., Whitaker, J.N. Importance of paraclinical and CSF studies in the diagnosis of MS in patients presenting with partial cervical transverse myelopathy and negative cranial MRI. *Mult. Scler.*, **2000**, *6*(5), 312-316.
- [26] Ford, B., Tampieri, D., Francis, G. Long-term follow-up of acute partial transverse myelopathy. *Neurology*, **1992**, *42*(1), 250-252.
- [27] Miller, D.H., Ormerod, I.E., Rudge, P., Kendall, B.E., Moseley, I.F., McDonald, W.I. The early risk of multiple sclerosis following isolated acute syndromes of the brainstem and spinal cord. *Ann. Neurol.*, **1989**, *26*(5), 635-639.
- [28] Morrissey, S.P., Miller, D.H., Kendall, B.E., Kingsley, D.P., Kelly, M.A., Francis, D.A., MacManus, D.G., McDonald, W.I. The significance of brain magnetic resonance imaging abnormalities at presentation with clinically isolated syndromes suggestive of multiple sclerosis. A 5-year follow-up study. *Brain*, **1993**, *116* (Pt 1), 135-146.
- [29] Kalita, J., Misra, U.K. Neurophysiological studies in acute transverse myelitis. *J. Neurol.*, **2000**, *247*(12), 943-948.
- [30] Misra, U.K., Kalita, J. Can electromyography predict the prognosis of transverse myelitis? *J. Neurol.*, **1998**, *245*(11), 741-744.
- [31] Irani, D.N., Kerr, D.A. 14-3-3 protein in the cerebrospinal fluid of patients with acute transverse myelitis. *Lancet*, **2000**, *355*(9207), 901.
- [32] Mirich, D.R., Kucharczyk, W., Keller, M.A., Deck, J. Subacute necrotizing myelopathy: MR imaging in four pathologically proved cases. *Am. J. Neuroradiol.*, **1991**, *12*(6), 1077-1083.
- [33] Nagaswami, S., Kepes, J., Foster, D.B., Twemlow, S.W. Necrotizing myelitis: a clinic-pathologic report of two cases associated with diplococcus pneumoniae and mycoplasma pneumoniae infections. *Trans. Am. Neurol. Assoc.*, **1973**, *98*, 290-292.
- [34] Katz, J.D., Ropper, A.H. Progressive necrotic myelopathy: clinical course in 9 patients. *Arch. Neurol.*, **2000**, *57*(3), 355-361.
- [35] Ojeda, V.J. Necrotizing myelopathy associated with malignancy. A clinicopathologic study of two cases and literature review. *Cancer*, **1984**, *53*(5), 1115-1123.
- [36] Van, Bogaert, L. Post-infectious encephalomyelitis and multiple sclerosis; the significance of perivenous encephalomyelitis. *J. Neuropathol. Exp. Neurol.*, **1950**, *9*(3), 219-249.
- [37] Altrocchi, P.H. Acute Transverse Myelopathy. *Arch. Neurol.*, **1963**, *9*, 111-119.
- [38] Lerer, R.J., Kalavsky, S.M. Central nervous system disease associated with Mycoplasma pneumoniae infection: report of five cases and review of the literature. *Pediatrics*, **1973**, *52*(5), 658-668.
- [39] Salgado, C.D., Weisse, M.E. Transverse myelitis associated with probable cat-scratch disease in a previously healthy pediatric patient. *Clin. Infect. Dis.*, **2000**, *31*(2), 609-611.
- [40] Baig, S.M., Khan, M.A. Cytomegalovirus-associated transverse myelitis in a non-immunocompromised patient. *J. Neurol. Sci.*, **1995**, *134*(1-2), 210-211.
- [41] Giobbia, M., Carniato, A., Scotton, P.G., Marchiori, G.C., Vaglia, A. Cytomegalovirus-associated transverse myelitis in a non-immunocompromised patient. *Infection*, **1999**, *27*(3), 228-230.
- [42] Olson, J.K., Eagar, T.N., Miller, S.D. Functional activation of myelin-specific T cells by virus-induced molecular mimicry. *J. Immunol.*, **2002**, *169*(5), 2719-2726.
- [43] Williamson, R.A., Burgoon, M.P., Owens, G.P., Ghausi, O., Leclerc, E., Firme, L., Carlson, S., Corboy, J., Parren, P.W., Sanna, P.P., Gilden, D.H., Burton, D. R. Anti-DNA antibodies are a major component of the intrathecal B cell response in multiple sclerosis. *Proc. Natl. Acad. Sci. USA*, **2001**, *98*(4), 1793-1798.
- [44] Levin, M.C., Lee, S.M., Kalume, F., Morcos, Y., Dohan, F.C., Jr., Hasty, K.A., Callaway, J.C., Zunt, J., Desiderio, D., Stuart, J.M. Autoimmunity due to molecular mimicry as a cause of neurological disease. *Nat. Med.*, **2002**, *8*(5), 509-513.
- [45] Kappler, J., Kotzin, B., Herron, L., Gelfand, E.W., Bigler, R.D., Boylston, A., Carrel, S., Posnett, D.N., Choi, Y., Marrack, P.V. beta-specific stimulation of human T cells by staphylococcal toxins. *Science*, **1989**, *244*(4906), 811-813.
- [46] Kotzin, B.L., Leung, D.Y., Kappler, J., Marrack, P. Superantigens and their potential role in human disease. *Adv. Immunol.*, **1993**, *54*, 99-166.
- [47] Webb, S.R., Gascoigne, N.R. T-cell activation by superantigens. *Curr. Opin. Immunol.*, **1994**, *6*(3), 467-475.
- [48] Acha-Orbea, H., MacDonald, H.R. Superantigens of mouse mammary tumor virus. *Annu Rev. Immunol.*, **1995**, *13*, 459-486.
- [49] Hong, S.C., Waterbury, G., Janeway CA, Jr. Different superantigens interact with distinct sites in the Vbeta domain of a single T cell receptor. *J. Exp. Med.*, **1996**, *183*(4), 1437-1446.
- [50] Garcia-Merino, A., Blasco, M.R. Recurrent transverse myelitis with unusual long-standing Gd-DTPA enhancement. *J. Neurol.*, **2000**, *247*(7), 550-551.
- [51] Kaplin, A.I., Deshpande, D.M., Scott, E., Krishnan, C., Carmen, J.S., Shats, I., Martinez, T., Drummond, J., Dike, S., Pletnikov, M., Keswani, S.C., Moran, T.H., Pardo, C.A., Calabresi PA, Kerr DA. IL-6 induces regionally selective spinal cord injury in patients with the neuroinflammatory disorder transverse myelitis. *J. Clin. Invest.*, **2005**, *115*(10), 2731-2741.
- [52] Byskosh, P.V., Reder, A.T. Interferon beta-1b effects on cytokine mRNA in peripheral mononuclear cells in multiple sclerosis. *Mult. Scler.*, **1996**, *1*(5), 262-269.
- [53] Ransohoff, R.M., Howe, C.L., Rodriguez, M. Growth factor treatment of demyelinating disease: at last, a leap into the light. *Trends Immunol.*, **2002**, *23*(11), 512-516.
- [54] Gadiant, R.A., Otten, U.H. Interleukin-6 (IL-6)--a molecule with both beneficial and destructive potentials. *Prog. Neurobiol.*, **1997**, *52*(5), 379-390.
- [55] Kira, J., Kawano, Y., Yamasaki, K., Tobimatsu S. Acute myelitis with hyperIgEaemia and mite antigen specific IgE: atopic myelitis. *J. Neurol. Neurosurg. Psychiatry*, **1998**, *64*(5), 676-679.
- [56] Kikuchi, H., Osoegawa, M., Ochi, H., Murai, H., Horiuchi, I., Takahashi, H., Yamabe, K., Iwaki, T., Mizutani, T., Oda, M., Kira, J. Spinal cord lesions of myelitis with hyperIgEemia and mite antigen specific IgE (atopic myelitis) manifest eosinophilic inflammation. *J. Neurol. Sci.*, **2001**, *183*(1), 73-88.
- [57] Defresne, P., Meyer, L., Tardieu, M., Scalais, E., Nuttin, C., De Bont, B., Loftus, G., Landrieu, P., Kadhim, H., Sebire, G. Efficacy of high dose steroid therapy in children with severe acute transverse myelitis. *J. Neurol. Neurosurg. Psychiatry*, **2001**, *71*(2), 272-274.
- [58] Kalita, J., Misra, U.K. Is methyl prednisolone useful in acute transverse myelitis? *Spinal Cord*, **2001**, *39*(9), 471-476.
- [59] Sebire, G., Hollenberg, H., Meyer, L., Huault, G., Landrieu, P., Tardieu, M. High dose methylprednisolone in severe acute transverse myelopathy. *Arch. Dis. Child*, **1997**, *76*(2), 167-168.
- [60] Dowling, P.C., Bosch, V.V., Cook, S.D. Possible beneficial effect of high-dose intravenous steroid therapy in acute demyelinating disease and transverse myelitis. *Neurology*, **1980**, *30*(7 Pt 2), 33-36.
- [61] Kennedy, P.G., Weir, A.I. Rapid recovery of acute transverse myelitis treated with steroids. *Postgrad. Med. J.*, **1988**, *64*(751), 384-385.
- [62] Lahat, E., Pillar, G., Ravid, S., Barzilai, A., Etzioni, A., Shahar, E. Rapid recovery from transverse myelopathy in children treated with methylprednisolone. *Pediatr. Neurol.*, **1998**, *19*(4), 279-282.

- [63] Weinshenker, B.G., O'Brien, P.C., Petterson, T.M., Noseworthy, J.H., Lucchinetti, C.F., Dodick D.W., Pineda, A.A., Stevens, L.N., Rodriguez, M. A randomized trial of plasma exchange in acute central nervous system inflammatory demyelinating disease. *Ann. Neurol.*, **1999**, *46*(6), 878-886.
- [64] Weinshenker, B.G. Plasma exchange for severe attacks of inflammatory demyelinating diseases of the central nervous system. *J. Clin. Apher.*, **2001**, *16*(1), 39-42.
- [65] Keegan, M., Pineda, A.A., McClelland, R.L., Darby, C.H., Rodriguez, M., Weinshenker, B.G. Plasma exchange for severe attacks of CNS demyelination: predictors of response. *Neurology*, **2002**, *58*(1), 143-146.
- [66] Greenberg, B.M., Thomas, K.P., Krishnan, C., Kaplin, A.I., Calabresi, P.A., Kerr, D.A. Idiopathic transverse myelitis: corticosteroids, plasma exchange, or cyclophosphamide. *Neurology*, **2007**, *68*(19), 1614-1617.
- [67] Awad A, Stüve O. Review: Cyclophosphamide in multiple sclerosis: scientific rationale, history and novel treatment paradigms. *Ther. Adv. Neurol. Disord.*, **2009**, *2*, 357-368.
- [68] Kim, Y.H., Choi, B.K., Oh, H.S., Kang, W.J., Mittler, R.S., Kwon, B.S. Mechanisms involved in synergistic anticancer effects of anti-4-1BB and cyclophosphamide therapy. *Mol. Cancer Ther.*, **2009**, *8*(2), 469-478.
- [69] Smith, D.R., Balashov, K.E., Hafler, D.A., Khoury, S.J., Weiner, H.L. Immune deviation following pulse cyclophosphamide/methylprednisolone treatment of multiple sclerosis: increased interleukin-4 production and associated eosinophilia. *Ann. Neurol.*, **1997**, *42*(3), 313-318.
- [70] Comi, G., Filippi, M., Barkhof, F., Durelli, L., Edan, G., Fernandez, O., Hartung, H., Seeltrayers, P., Sorensen, P.S., Rovaris, M., Martinelli, V., Hommes, O.R. Effect of early interferon treatment on conversion to definite multiple sclerosis: a randomised study. *Lancet*, **2001**, *357*(9268), 1576-1582.
- [71] Comi, G., Martinelli, V., Rodegher, M., Momiola, L., Bajenaru, O., Carra, A., Elovaara, I., Fazekas, F., Hartung, H.P., Hillert, J., King, J., Komoly, S., Lubetzki, C., Montalban, X., Myhr, K.M., Ravnborg, M., Rieckmann, P., Wynn, D., Young, C., Filippi, M. Effect of glatiramer acetate on conversion to clinically definite multiple sclerosis in patients with clinically isolated syndrome (PreCISe study): a randomised, double-blind, placebo-controlled trial. *Lancet*, **2009**, *374*(9700), 1503-1511.
- [72] O'Connor, P. The effects of intramuscular interferon beta-1a in patients at high risk for development of multiple sclerosis: a post hoc analysis of data from CHAMPS. *Clin. Ther.*, **2003**, *25*(11), 2865-2874.
- [73] Jacobs, L.D., Beck, R.W., Simon, J.H., Kinkel, R.P., Brownschidle, C.M., Murray, T.J., Simonian, N, A., Slasor, P.J., Sandrock, A.W. Intramuscular interferon beta-1a therapy initiated during a first demyelinating event in multiple sclerosis. CHAMPS Study Group. *N. Engl. J. Med.*, **2000**, *343*(13), 898-904.
- [74] Siren, A.L., Radyushkin, K., Boretius, S., Kammer, D., Riechers, C.C., Natt, O., Sargin, D., Watanabe, T., Sperling, S., Michaelis, T., Price, J., Meyer, B., Frahm, J., Ehrenreich, H. Global brain atrophy after unilateral parietal lesion and its prevention by erythropoietin. *Brain*, **2006**, *129*(Pt 2), 480-489.
- [75] Xiong, Y., Lu, D., Qu, C., Goussev, A., Schallert, T., Mahmood, A., Chopp, M. Effects of erythropoietin on reducing brain damage and improving functional outcome after traumatic brain injury in mice. *J. Neurosurg.*, **2008**, *109*(3), 510-521.
- [76] Wingerchuk D.M. Neuromyelitis optica: current concepts. *Front. Biosci.*, **2004**, *9*, 834-840.
- [77] Wingerchuk, D.M., Lennon, V.A., Lucchinetti, C.F., Pittock, S.J., Weinshenker, B.G. The spectrum of neuromyelitis optica. *Lancet Neurol.*, **2007**, *6*(9), 805-815.
- [78] de Seze, J., Lebrun, C., Stojkovic, T., Ferriby, D., Chatel, M., Vermersch, P. Is Devic's neuromyelitis optica a separate disease? A comparative study with multiple sclerosis. *Mult. Scler.*, **2003**, *9*(5), 521-525.
- [79] Mirsattari, S.M., Johnston, J.B., McKenna, R., Del Bigio, M.R., Orr, P., Ross, R.T., Power, C. Aborigines with multiple sclerosis: HLA types and predominance of neuromyelitis optica. *Neurology*, **2001**, *56*(3), 317-323.
- [80] Cabre, P., Heinzllef, O., Merle, H., Buisson, G.G., Bera, O., Bellance, R., Vernant, J.C., Smadja, D. MS and neuromyelitis optica in Martinique (French West Indies). *Neurology*, **2001**, *56*(4), 507-514.
- [81] Osuntokun, B.O. The pattern of neurological illness in tropical Africa. Experience at Ibadan, Nigeria. *J. Neurol. Sci.*, **1971**, *12*(4), 417-442.
- [82] Jeffery, A.R., Buncic, J.R. Pediatric Devic's neuromyelitis optica. *J. Pediatr. Ophthalmol. Strabismus*, **1996**, *33*(5), 223-229.
- [83] Lotze, T.E., Northrop, J.L., Hutton, G.J., Ross, B., Schiffman, J.S., Hunter, J.V. Spectrum of pediatric neuromyelitis optica. *Pediatrics*, **2008**, *122*(5), e1039-47.
- [84] Wingerchuk, D.M., Lennon, V.A., Pittock, S.J., Lucchinetti, C.F., Weinshenker, B.G. Revised diagnostic criteria for neuromyelitis optica. *Neurology*, **2006**, *66*(10), 1485-1489.
- [85] Lalive, P.H. Autoantibodies in inflammatory demyelinating diseases of the central nervous system. *Swiss Med. Wkly.*, **2008**, *138*(47-48), 692-707.
- [86] Braley, T., Mikol, D.D. Neuromyelitis optica in a mother and daughter. *Arch. Neurol.*, **2007**, *64*(8), 1189-1192.
- [87] Yamakawa, K., Kuroda, H., Fujihara, K., Sato, S., Nakashima, I., Takeda, A., Suzuki, K., Itoyama Y. Familial neuromyelitis optica (Devic's syndrome) with late onset in Japan. *Neurology*, **2000**, *55*(2), 318-320.
- [88] Whitham, R.H., Brey, R.L. Neuromyelitis optica: two new cases and review of the literature. *J. Clin. Neuroophthalmol.*, **1985**, *5*(4), 263-269.
- [89] Williamson, P.M. Neuromyelitis optica following infectious mononucleosis. *Proc. Aust. Assoc. Neurol.*, **1975**, *12*, 153-155.
- [90] Ahasan, H.A., Rafiqueuddin, A.K., Chowdhury, M.A., Azhar, M.A., Kabir, F. Neuromyelitis optica (Devic's disease) following chicken pox. *Trop. Doct.*, **1994**, *24*(2), 75-76.
- [91] Keefe, R.J. Neuromyelitis optica with increased intracranial pressure. *AMA Arch. Ophthalmol.*, **1957**, *57*(1), 110-111.
- [92] Li, W., Minohara, M., Piao, H., Matsushita, T., Masaki, K., Matsuoka, T., Isobe, N., Su, J.J., Ohyagi, Y., Kira, J. Association of anti-Helicobacter pylori neutrophil-activating protein antibody response with anti-aquaporin-4 autoimmunity in Japanese patients with multiple sclerosis and neuromyelitis optica. *Mult. Scler.*, **2009**, *15*(12), 1411-1421.
- [93] Blanche, P., Diaz, E., Gombert, B., Sicard, D., Rivoal, O., Brezin, A. Devic's neuromyelitis optica and HIV-1 infection. *J. Neurol. Neurosurg. Psychiatry*, **2000**, *68*(6), 795-796.
- [94] Silber, M.H., Willcox, P.A., Bowen, R.M., Unger, A. Neuromyelitis optica (Devic's syndrome) and pulmonary tuberculosis. *Neurology*, **1990**, *40*(6), 934-938.
- [95] Willcox, R.A., Burrow, J., Slee, M., Craig, J., Thyagarajan, D. Neuromyelitis optica (Devic's disease) in a patient with syphilis. *Mult. Scler.*, **2008**, *14*(2), 268-271.
- [96] Chusid, M.J., Williamson, S.J., Murphy, J.V., Ramey, L.S. Neuromyelitis optica (Devic disease) following varicella infection. *J. Pediatr.*, **1979**, *95*(5 Pt 1), 737-738.
- [97] Ghezzi, A., Bergamaschi, R., Martinelli, V., Trojano, M., Tola, M.R., Merelli, E., Mancardi, L., Gallo, P., Filippi, M., Zaffaroni, M., Comi, G. Clinical characteristics, course and prognosis of relapsing Devic's Neuromyelitis Optica. *J. Neurol.*, **2004**, *251*(1), 47-52.
- [98] Mandler, R.N., Davis, L.E., Jeffery, D.R., Kornfeld, M. Devic's neuromyelitis optica: a clinicopathological study of 8 patients. *Ann. Neurol.*, **1993**, *34*(2), 162-168.
- [99] O'Riordan JI, Gallagher HL, Thompson AJ, Howard RS, Kingsley DP, Thompson EJ, McDonald WI, Miller DH. Clinical, CSF, and MRI findings in Devic's neuromyelitis optica. *J. Neurol. Neurosurg. Psychiatry*, **1996**, *60*(4), 382-387.
- [100] Wingerchuk, D.M., Weinshenker, B.G. Neuromyelitis optica: clinical predictors of a relapsing course and survival. *Neurology*, **2003**, *60*(5), 848-853.
- [101] Wingerchuk, D.M., Hogancamp, W.F., O'Brien, P.C., Weinshenker, B.G. The clinical course of neuromyelitis optica (Devic's syndrome). *Neurology*, **1999**, *53*(5), 1107-1114.
- [102] Misu, T., Fujihara, K., Nakashima, I., Sato, S., Itoyama, Y. Intractable hiccup and nausea with periaqueductal lesions in neuromyelitis optica. *Neurology*, **2005**, *65*(9), 1479-1482.
- [103] Al-Araji, A.H., Oger, J. Reappraisal of Lhermitte's sign in multiple sclerosis. *Mult. Scler.*, **2005**, *11*(4), 398-402.
- [104] Banwell, B., Tenenbaum, S., Lennon, V.A., Ursell, E., Kennedy, J., Bar-Or, A., Weinshenker, B.G., Lucchinetti, C.F., Pittock, S.J.

- Neuromyelitis optica-IgG in childhood inflammatory demyelinating CNS disorders. *Neurology*, **2008**, *70*(5), 344-352.
- [105] Bergamaschi, R., Tonietti, S., Franciotta, D., Candeloro, E., Tavazzi, E., Piccolo, G., Romani, A., Cosi, V. Oligoclonal bands in Devic's neuromyelitis optica and multiple sclerosis: differences in repeated cerebrospinal fluid examinations. *Mult. Scler.*, **2004**, *10*(1), 2-4.
- [106] Filippi, M., Rocca, M.A. MR imaging of Devic's neuromyelitis optica. *Neurol. Sci.*, **2004**, *25*(Suppl 4), S371-S373.
- [107] Pittock, S.J., Weinschenker, B.G., Lucchinetti, C.F., Wingerchuk, D.M., Corboy, J.R., Lennon, V.A. Neuromyelitis optica brain lesions localized at sites of high aquaporin 4 expression. *Arch. Neurol.*, **2006**, *63*(7), 964-968.
- [108] Vernant, J.C., Cabre, P., Smadja, D., Merle, H., Caubarrere, I., Mikol, J., Poser, C.M. Recurrent optic neuromyelitis with endocrinopathies: a new syndrome. *Neurology*, **1997**, *48*(1), 58-64.
- [109] Fardet, L., Genereau, T., Mikaeloff, Y., Fontaine, B., Seilhean, D., Cabane, J. Devic's neuromyelitis optica: study of nine cases. *Acta Neurol. Scand.*, **2003**, *108*(3), 193-200.
- [110] Rocca, M.A., Agosta, F., Mezzapesa, D.M., Martinelli, V., Salvi, F., Ghezzi, A., Bergamaschi R, Comi, G., Filippi, M. Magnetization transfer and diffusion tensor MRI show gray matter damage in neuromyelitis optica. *Neurology*, **2004**, *62*(3), 476-478.
- [111] de Seze, J., Blanc, F., Jeanjean, L., Zephir, H., Labauge, P., Bouyon, M., Ballonzoli, L., Castelnuovo, G., Fleury, M., Defoort, S., Vermersch, P., Speeg, C. Optical coherence tomography in neuromyelitis optica. *Arch. Neurol.*, **2008**, *65*(7), 920-923.
- [112] Green, A.J., Cree, B.A. Distinctive retinal nerve fibre layer and vascular changes in neuromyelitis optica following optic neuritis. *J. Neurol. Neurosurg. Psychiatry*, **2009**, *80*(9), 1002-1005.
- [113] Naismith, R.T., Tutlam, N.T., Xu, J., Shepherd, J.B., Klawiter, E.C., Song, S.K., Cross A, H. Optical coherence tomography is less sensitive than visual evoked potentials in optic neuritis. *Neurology*, **2009**, *73*(1), 46-52.
- [114] Ratchford, J.N., Quigg, M.E., Conger, A., Frohman, T., Frohman, E., Balcer, L.J., Calabresi, P.A., Kerr, D.A. Optical coherence tomography helps differentiate neuromyelitis optica and MS optic neuropathies. *Neurology*, **2009**, *73*(4), 302-308.
- [115] Furukawa, Y., Yoshikawa, H., Yachie, A., Yamada, M. Neuromyelitis optica associated with myasthenia gravis: characteristic phenotype in Japanese population. *Eur. J. Neurol.*, **2006**, *13*(6), 655-658.
- [116] Karussis, D., Leker, R.R., Ashkenazi, A., Abramsky, O. A subgroup of multiple sclerosis patients with anticardiolipin antibodies and unusual clinical manifestations: do they represent a new nosological entity? *Ann. Neurol.*, **1998**, *44*(4), 629-634.
- [117] Kister, I., Gulati, S., Boz, C., Bergamaschi, R., Piccolo, G., Oger, J., Swerdlow, M.L. Neuromyelitis optica in patients with myasthenia gravis who underwent thymectomy. *Arch. Neurol.*, **2006**, *63*(6), 851-856.
- [118] Cree, B.A., Goodin, D.S., Hauser, S.L. Neuromyelitis optica. *Semin. Neurol.*, **2002**, *22*(2), 105-122.
- [119] Jacob, S., Zarei, M., Kenton, A., Allroggen, H. Gluten sensitivity and neuromyelitis optica: two case reports. *J. Neurol. Neurosurg. Psychiatry*, **2005**, *76*(7), 1028-1030.
- [120] Jacobi, C., Stingele, K., Kretz, R., Hartmann, M., Storch-Hagenlocher, B., Breitbart, A., Wildemann, B. Neuromyelitis optica (Devic's syndrome) as first manifestation of systemic lupus erythematosus. *Lupus*, **2006**, *15*(2), 107-109.
- [121] Hummers, L.K., Krishnan, C., Casciola-Rosen, L., Rosen, A., Morris, S., Mahoney, J.A., Kerr, D.A., Wigley, F.M. Recurrent transverse myelitis associates with anti-Ro (SSA) autoantibodies. *Neurology*, **2004**, *62*(1), 147-149.
- [122] Lennon, V.A., Wingerchuk, D.M., Kryzer, T.J., Pittock, S.J., Lucchinetti, C.F., Fujihara, K., Nakashima, I., Weinschenker, B.G. A serum autoantibody marker of neuromyelitis optica: distinction from multiple sclerosis. *Lancet*, **2004**, *364*(9451), 2106-2112.
- [123] Weinschenker, B.G., Wingerchuk, D.M., Vukusic, S., Linbo, L., Pittock, S.J., Lucchinetti, C.F., Lennon, V.A. Neuromyelitis optica IgG predicts relapse after longitudinally extensive transverse myelitis. *Ann. Neurol.*, **2006**, *59*(3), 566-569.
- [124] Jarius, S., Paul, F., Franciotta, D., Waters, P., Zipp, F., Hohlfeld, R., Vincent, A., Wildemann, B. Mechanisms of disease: aquaporin-4 antibodies in neuromyelitis optica. *Nat. Clin. Pract. Neurol.*, **2008**, *4*(4), 202-214.
- [125] Nakashima, I., Fujihara, K., Miyazawa, I., Misu, T., Narikawa, K., Nakamura, M., Watanabe, S., Takahashi, T., Nishiyama, S., Shiga, Y., Sato, S., Weinschenker, B.G., Itoyama, Y. Clinical and MRI features of Japanese patients with multiple sclerosis positive for NMO-IgG. *J. Neurol. Neurosurg., Psychiatry*, **2006**, *77*(9), 1073-1075.
- [126] McKeon, A., Fryer, J.P., Apiwatanakul, M., Lennon, V.A., Hinson, S.R., Kryzer, T.J., Lucchinetti C.F., Weinschenker, B.G., Wingerchuk, D.M., Shuster, E.A., Pittock, S.J. Diagnosis of neuromyelitis spectrum disorders: comparative sensitivities and specificities of immunohistochemical and immunoprecipitation assays. *Arch. Neurol.*, **2009**, *66*(9), 1134-1138.
- [127] Agre, P., Kozono, D. Aquaporin water channels: molecular mechanisms for human diseases. *FEBS Lett.*, **2003**, *555*(1), 72-78.
- [128] Nielsen, S., Nagelhus, E.A., Amiry-Moghaddam, M., Bourque, C., Agre, P., Ottersen, O.P. Specialized membrane domains for water transport in glial cells: high-resolution immunogold cytochemistry of aquaporin-4 in rat brain. *J. Neurosci.*, **1997**, *17*(1), 171-180.
- [129] Lennon, V.A., Kryzer, T.J., Pittock, S.J., Verkman, A.S., Hinson, S.R. IgG marker of optic-spinal multiple sclerosis binds to the aquaporin-4 water channel. *J. Exp. Med.*, **2005**, *202*(4), 473-477.
- [130] Weinschenker, B.G. Neuromyelitis optica: what it is and what it might be. *Lancet*, **2003**, *361*(9361), 889-890.
- [131] Matiello, M., Lennon, V.A., Jacob, A., Pittock, S.J., Lucchinetti, C.F., Wingerchuk, D.M., Weinschenker, B.G. NMO-IgG predicts the outcome of recurrent optic neuritis. *Neurology*, **2008**, *70*(23), 2197-200.
- [132] Lucchinetti, C.F., Mandler, R.N., McGavern, D., Bruck, W., Gleich, G., Ransohoff, R.M., Trebst, C., Weinschenker, B., Wingerchuk, D., Parisi, J.E., Lassmann, H. A role for humoral mechanisms in the pathogenesis of Devic's neuromyelitis optica. *Brain*, **2002**, *125*(Pt 7), 1450-1461.
- [133] Ortiz de Zarate, J.C., Tamaroff, L., Sica, R.E., Rodriguez, J.A. Neuromyelitis optica versus subacute necrotic myelitis. II. Anatomical study of two cases. *J. Neurol. Neurosurg. Psychiatry*, **1968**, *31*(6), 641-645.
- [134] Lefkowitz, D., Angelo, J.N. Neuromyelitis optica with unusual vascular changes. *Arch. Neurol.*, **1984**, *41*(10), 1103-1105.
- [135] Roemer, S.F., Parisi, J.E., Lennon, V.A., Benarroch, E.E., Lassmann, H., Bruck, W., Mandler, R.N., Weinschenker, B.G., Pittock, S.J., Wingerchuk, D.M., Lucchinetti, C.F. Pattern-specific loss of aquaporin-4 immunoreactivity distinguishes neuromyelitis optica from multiple sclerosis. *Brain*, **2007**, *130*(Pt 5), 1194-1205.
- [136] Penton-Rol, G., Cervantes-Llanos, M., Martinez-Sanchez, G., Cabrera-Gomez, J.A., Valenzuela-Silva, C.M., Ramirez-Nunez, O., Casanova-Orta, M., Robinson-Agramonte, M.A., Lopategui-Cabezas, I., Lopez-Saura, P.A. TNF-alpha and IL-10 downregulation and marked oxidative stress in Neuromyelitis Optica. *J. Inflamm. (Lond)*, **2009**, *6*, 18.
- [137] Correale, J., Fiol, M. Activation of humoral immunity and eosinophils in neuromyelitis optica. *Neurology*, **2004**, *63*(12), 2363-2370.
- [138] Yamasaki, K., Horiuchi, I., Minohara, M., Osoegawa, M., Kawano, Y., Ohyagi, Y., Yamada, T., Kira, J. Hyperprolactinemia in optico-spinal multiple sclerosis. *Intern. Med.*, **2000**, *39*(4), 296-299.
- [139] Kira, J. A novel feature disclosed in optico-spinal multiple sclerosis in Asians. *Intern. Med.*, **2000**, *39*(4), 272.
- [140] Kerr, D.A., Ayetey, H. Immunopathogenesis of acute transverse myelitis. *Curr. Opin. Neurol.*, **2002**, *15*(3), 339-347.
- [141] Ferrari, C., Boghen, M., Paracchi, A., Rampini, P., Raiteri, F., Benco, R., Romussi, M., Codecasa, F., Mucci, M., Bianco, M. Thyroid autoimmunity in hyperprolactinaemic disorders. *Acta Endocrinol. (Copenh)*, **1983**, *104*(1), 35-41.
- [142] Kramer, C.K., Tourinho, T.F., de Castro, W.P., da Costa, Oliveira, M. Association between systemic lupus erythematosus, rheumatoid arthritis, hyperprolactinemia and thyroid autoantibodies. *Arch. Med. Res.*, **2005**, *36*(1), 54-58.
- [143] Kira, J., Kanai, T., Nishimura, Y., Yamasaki, K., Matsushita, S., Kawano, Y., Hasuo, K., Tobimatsu, S., Kobayashi, T. Western versus Asian types of multiple sclerosis: immunogenetically and clinically distinct disorders. *Ann. Neurol.*, **1996**, *40*(4), 569-574.
- [144] Yamasaki, K., Horiuchi, I., Minohara, M., Kawano, Y., Ohyagi, Y., Yamada, T., Mihara, F., Ito, H., Nishimura, Y., Kira, J. HLA-DPB1*0501-associated optico-spinal multiple sclerosis: clinical,

- neuroimaging and immunogenetic studies. *Brain*, **1999**, *122* (Pt 9), 1689-1696.
- [145] Brum, D.G., Barreiram, A.A., dos Santos AC, Kaimen-Maciel DR, Matiello M, Costa RM, Deghaide, N.H., Costa, L.S., Louzada-Junior, P., Diniz, P.R., Comini-Frota, E.R., Mendes-Junior, C. T., Donadi, E.A. HLA-DRB association in neuromyelitis optica is different from that observed in multiple sclerosis. *Mult. Scler.*, **2010**, *16*(1), 21-29.
- [146] Haase, C.G. [Devic's neuromyelitis optica. Disease or variants of multiple sclerosis?]. *Nervenarzt*, **2001**, *72*(10), 750-754.
- [147] Sinclair, C., Kirk, J., Herron, B., Fitzgerald, U., McQuaid, S. Absence of aquaporin-4 expression in lesions of neuromyelitis optica but increased expression in multiple sclerosis lesions and normal-appearing white matter. *Acta Neuropathol.*, **2007**, *113*(2), 187-194.
- [148] Misu, T., Fujihara, K., Nakamura, M., Murakami, K., Endo, M., Konno, H., Itoyama, Y. Loss of aquaporin-4 in active perivascular lesions in neuromyelitis optica: a case report. *Tohoku J. Exp. Med.*, **2006**, *209*(3), 269-275.
- [149] Eikelenboom, M.J., Killestein, J., Uitdehaag, B.M., Polman, C.H. Opticospinal multiple sclerosis: a pathogenetically distinct form? *Mult. Scler.*, **2004**, *10*(3), 334-335.
- [150] Kira, J. Multiple sclerosis in the Japanese population. *Lancet Neurol.*, **2003**, *2*(2), 117-127.
- [151] Wingerchuk, D.M., Weinshenker, B.G. Neuromyelitis Optica. *Curr. Treat Options Neurol.*, **2005**, *7*(3), 173-182.
- [152] Ruprecht, K., Klinker, E., Dintelmann, T., Rieckmann, P., Gold, R. Plasma exchange for severe optic neuritis: treatment of 10 patients. *Neurology*, **2004**, *63*(6), 1081-1083.
- [153] Nozaki, I., Hamaguchi, T., Komai, K., Yamada, M. Fulminant Devic disease successfully treated by lymphocytapheresis. *J. Neurol. Neurosurg. Psychiatry*, **2006**, *77*(9), 1094-1095.
- [154] Shaw, T., Quan, J., Totoritis, M.C. B cell therapy for rheumatoid arthritis: the rituximab (anti-CD20) experience. *Ann. Rheum. Dis.*, **2003**, *62*(Suppl 2), ii55-ii59.
- [155] Cree, B.A., Lamb, S., Morgan, K., Chen, A., Waubant, E., Genain, C. An open label study of the effects of rituximab in neuromyelitis optica. *Neurology*, **2005**, *64*(7), 1270-1272.
- [156] Jacob, A., Weinshenker, B.G., Violich, I., McLinskey, N., Krupp, L., Fox, R.J., Wingerchuk, D.M., Boggild, M., Constantinescu, C.S., Miller, A., De Angelis, T., Matiello, M., Cree, B.A. Treatment of neuromyelitis optica with rituximab: retrospective analysis of 25 patients. *Arch. Neurol.*, **2008**, *65*(11), 1443-1448.
- [157] Imamura, H., Tanaka, M., Kitagawa, N., Tahara, M., Oono, M., Tanaka, K., Konishi, T. [Trial of rituximab in three patients with neuromyelitis optica]. *Rinsho Shinkeigaku*, **2009**, *49*(8), 457-462.
- [158] Higashida, J., Wun, T., Schmidt, S., Naguwa, S.M., Tuscano, J.M. Safety and efficacy of rituximab in patients with rheumatoid arthritis refractory to disease modifying antirheumatic drugs and anti-tumor necrosis factor-alpha treatment. *J. Rheumatol.*, **2005**, *32*(11), 2109-2115.
- [159] Mandler, R.N., Ahmed, W., Dencoff, J.E. Devic's neuromyelitis optica: a prospective study of seven patients treated with prednisone and azathioprine. *Neurology*, **1998**, *51*(4), 1219-1220.
- [160] Elion, G.B. The George Hitchings and Gertrude Elion Lecture. The pharmacology of azathioprine. *Ann. N. Y. Acad. Sci.*, **1993**, *685*, 400-407.
- [161] Weinstock-Guttman, B., Ramanathan, M., Lincoff, N., Napoli, S.Q., Sharma, J., Feichter, J., Bakshi, R. Study of mitoxantrone for the treatment of recurrent neuromyelitis optica (Devic disease). *Arch. Neurol.*, **2006**, *63*(7), 957-963.
- [162] Fox, E.J. Mechanism of action of mitoxantrone. *Neurology*, **2004**, *63*(12 Suppl 6), S15-S18.
- [163] Johnston, A., Gudjonsson, J.E., Sigmundsdottir, H., Ludviksson, B.R., Valdimarsson, H. The anti-inflammatory action of methotrexate is not mediated by lymphocyte apoptosis, but by the suppression of activation and adhesion molecules. *Clin. Immunol.*, **2005**, *114*(2), 154-163.
- [164] Jacob, A., Matiello, M., Weinshenker, B.G., Wingerchuk, D.M., Lucchinetti, C., Shuster, E., Carter, J., Keegan, B.M., Kantarci, O.H., Pittock, S.J. Treatment of neuromyelitis optica with mycophenolate mofetil: retrospective analysis of 24 patients. *Arch. Neurol.*, **2009**, *66*(9), 1128-1133.
- [165] Ransom, J.T. Mechanism of action of mycophenolate mofetil. *Ther. Drug Monit.*, **1995**, *17*(6), 681-684.
- [166] Mok, C.C., To, C.H., Mak, A., Poon, W.L. Immunoablative cyclophosphamide for refractory lupus-related neuromyelitis optica. *J. Rheumatol.*, **2008**, *35*(1), 172-174.
- [167] Bakker, J., Metz, L. Devic's neuromyelitis optica treated with intravenous gamma globulin (IVIg). *Can. J. Neurol. Sci.*, **2004**, *31*(2), 265-267.
- [168] Nimmerjahn, F., Ravetch, J.V. The antiinflammatory activity of IgG: the intravenous IgG paradox. *J. Exp. Med.*, **2007**, *204*(1), 11-15.
- [169] Siragam, V., Crow, A.R., Brinc, D., Song, S., Freedman, J., Lazarus, A.H. Intravenous immunoglobulin ameliorates ITP via activating Fc gamma receptors on dendritic cells. *Nat. Med.*, **2006**, *12*(6), 688-692.
- [170] Spycher, M., Matozan, K., Minnig, K., Zehnder, R., Miescher, S., Hoeflerer, L., Rieben, R. *In vitro* comparison of the complement-scavenging capacity of different intravenous immunoglobulin preparations. *Vox Sang*, **2009**, *97*(4), 348-354.
- [171] Bayry, J., Thirion, M., Misra, N., Thorenoor, N., Delignat, S., Lacroix-Desmazes, S., Bellon, B., Kaveri, S., Kazatchkine, M.D. Mechanisms of action of intravenous immunoglobulin in autoimmune and inflammatory diseases. *Neurol. Sci.*, **2003**, *24* (Suppl 4), S217-S221.
- [172] Janke, A.D., Yong, V.W. Impact of IVIg on the interaction between activated T cells and microglia. *Neurol. Res.*, **2006**, *28*(3), 270-274.
- [173] Warabi, Y., Matsumoto, Y., Hayashi, H. Interferon beta-1b exacerbates multiple sclerosis with severe optic nerve and spinal cord demyelination. *J. Neurol. Sci.*, **2007**, *252*(1), 57-61.
- [174] Bergamaschi, R., Uggetti, C., Toniatti, S., Egitto, M.G., Cosi, V. A case of relapsing neuromyelitis optica treated with glatiramer acetate. *J. Neurol.*, **2003**, *250*(3), 359-361.