

Glomerular Expression of Kidney Injury Molecule-1 and Podocytopenia in Diabetic Glomerulopathy

Xueying Zhao^a Yuanyuan Zhang^a Lingyun Li^a David Mann^a John D. Imig^b
Nerimiah Emmett^a Gary Gibbons^a Li-Ming Jin^c

^aDepartment of Physiology, Morehouse School of Medicine, Atlanta, Ga., ^bDepartment of Pharmacology and Toxicology, Medical College of Wisconsin, Milwaukee, Wisc., and ^cDepartment of Internal Medicine, University of California, Davis, Calif., USA

Key Words

Albuminuria · Kidney injury molecule-1 · Parietal epithelial cells · Podocytes · Glomerulopathy

Abstract

Background/Aims: Studies have shown that kidney injury molecule-1 (KIM-1) is upregulated in damaged renal proximal tubules. In this study, we examined KIM-1 expression in glomerular epithelial cells in diabetic glomerulopathy. **Methods:** Renal histology, immunostaining and Western blot for protein level, and real-time PCR for mRNA expression of KIM-1 and podocyte markers were evaluated in untreated or losartan-treated Zucker lean (Fa/+) and Zucker diabetic fatty (Fa/Fa) rats. **Results:** The diabetic rats showed an increased glomerular expression of KIM-1. KIM-1 staining was localized primarily in the hyperplastic parietal epithelium of Bowman's capsule in the early stages of diabetes with subsequent increase in KIM-1-positive cells in the glomerular tuft in the more advanced stages. The increase in glomerular KIM-1 was associated with a decrease in podocytes in Fa/Fa rats. Antiproteinuric treatment with losartan attenuated podocytopenia and decreased renal expression of KIM-1 in treated diabetic rats. In an in vitro study, albumin overload increased KIM-1 protein in the primary cultures of rat glo-

merular epithelial cells. **Conclusion:** These results show that glomerular KIM-1 expression was increased, in proportion to the extent of proteinuria and podocytopenia in the diabetic animals, supporting that KIM-1 could be used as a potential biomarker for glomerular injury in proteinuric kidney disease.

Copyright © 2011 S. Karger AG, Basel

Introduction

Diabetic nephropathy in humans is characterized by increased urinary albumin excretion (microalbuminuria), which often progresses to proteinuria and glomerular and tubulointerstitial fibrosis over the long term [1]. Proteinuria not only serves as a clinical indicator/marker of injury to the kidney, but also plays a central role in the pathogenesis of progressive renal dysfunction. In the past decade, studies have highlighted the importance of podocytes in the pathogenesis of proteinuric diseases including diabetic nephropathy [2–4]. Interestingly, recent studies suggest that parietal epithelial cells (PECs) of Bowman's capsule have the capacity to differentiate into podocytes during diseases, and play a role as a second glomerular barrier for limiting filtered albumin from ex-

iting the urinary space [5, 6]. Moreover, Suzuki et al. [7] found that PEC hyperplasia was accompanied by progressive podocytopenia in cellular/collapsing focal segmental glomerulosclerosis (FSGS), suggesting glomerular epithelial interactions.

Kidney injury molecule-1 (KIM-1), a type 1 membrane protein, is expressed at negligible levels in normal kidney tissue, but massively induced in dedifferentiated proximal tubule epithelial cells in proteinuric, toxic and ischemic kidney diseases [8–10]. In rodents and humans, the ischemic or toxic insults to the kidney cleave the KIM-1 ectodomain, which is quantified in the urine as a biomarker for acute kidney injury [8–10]. In fact, a strong correlation between the level of tubular and urinary KIM-1 and the extent of proteinuria has been demonstrated in adriamycin-induced nephropathy [8]. However, these studies did not establish whether microalbuminuria (or proteinuria) directly promotes KIM-1 expression in renal epithelial cells. Also, it remains unclear whether glomerular epithelial cells express KIM-1 and if so which type of epithelial cell expresses this protein.

Therefore, in the current study we assessed changes in glomerular KIM-1 expression in Zucker diabetic fatty rat, an animal model of type 2 diabetes mellitus, which spontaneously develops proteinuria and FSGS with increasing age. We also examined the effect of therapeutic antiproteinuric intervention with losartan, an angiotensin II type 1 (AT1) receptor antagonist, on renal expression and urinary excretion of KIM-1. Multilabeled immunocytochemistry was performed to establish possible correlation between KIM-1 induction and podocyte loss. Using primary cultured rat glomerular epithelial cells, we further examined the modulation of KIM-1 protein by albumin.

Animals and Methods

Animals

Six-week-old male Zucker lean (Fa/+) and Zucker diabetic fatty (Fa/Fa) rats were purchased from Charles River Laboratories (Wilmington, Mass., USA). Rats were housed in a temperature-controlled room with a 12:12-hour light-dark cycle and free access to Purina 5008 rat chow and water. Urine was collected over a 24-hour period in metabolic cages and stored at -80°C until use. Blood glucose was monitored using the Accu-chek glucometer by tail-vein blood sampling. For glucose tolerance test, 6–8 rats per group were fasted at 8:00 a.m. for 6 h and then injected with glucose (2 g/kg i.p.). Blood samples were collected from the tail vein at time 0 (before injection) and at 15, 30, 45, 60, 90 and 120 min after glucose injection for glucose determinations.

In one set of experiments, 12-week-old Fa/+ and Fa/Fa animals were treated with losartan (30 mg/kg/day in drinking water) for

8 weeks. Animals were housed in the animal care facility at the Morehouse School of Medicine that is AAALAC accredited. All animal protocols were approved by the Institutional Animal Care and Use Committee and were in accordance with the requirements stated in the National Institutes of Health *Guide for the Care and Use Laboratory Animals*.

Urinary Protein, Creatinine, Plasma Insulin and Systolic Blood Pressure Measurements

Urinary protein to creatinine ratios were assessed as an index for kidney injury. Total protein was measured by the Bradford method (Bio-Rad Protein Assay Kit; Bio-Rad Laboratories, Hercules, Calif., USA). Urine creatinine was measured by the modified kinetic Jaffé reaction. The urine protein to creatinine ratio was obtained by dividing the urine protein concentration by the urine creatinine concentration, both expressed in mg/dl. The plasma insulin concentration was measured by enzyme immunoassay using a rat insulin ELISA kit (Merckodia, Winston Salem, N.C., USA). Systolic blood pressure was measured in conscious rats by tail-cuff plethysmography.

Histology and Immunohistochemical Staining

Routine HE staining was performed on kidney paraffin sections. For immunohistochemical analysis, paraffin sections were incubated with goat anti-TIM-1/KIM-1/HAVCR antibody (R&D Systems, Minneapolis, Minn., USA). Slides were then incubated with ABC-AP (alkaline phosphatase) (Vector, Burlingame, Calif., USA) reagents and ABC red substrate (Vector).

For immunofluorescent staining, 5- μm -thick cryostat sections of OCT-embedded kidney samples were used. To study the localization of KIM-1 in the glomeruli, the sections were incubated with a mixture of two or three antibodies overnight: goat anti-KIM-1 antibody, guinea pig anti-nephrin antibody (Fitzgerald, Concord, Mass., USA), and rabbit anti-Wilms tumor (WT)-1 (Santa Cruz Biotechnology, Santa Cruz, Calif., USA), rabbit anti-claudin-1 antibody (Invitrogen) and mouse anti-desmin (Dako-Cytomation, Denmark). As a negative control, the sections were exposed to nonimmune IgG (in replacement of primary antibodies) with the same secondary antibodies, and no specific staining occurred. The sections were observed and imaged by a Leica confocal microscope.

Immunoblot Analysis

Equal amounts of proteins from rat urine or cultured cells were separated by electrophoresis. The blots were incubated with goat anti-KIM-1 antibody. Detection was accomplished by enhanced chemiluminescence Western blotting (ECL; GE Healthcare, Piscataway, N.J., USA). Band intensity was measured densitometrically, and the values were normalized to β -actin internal controls. Values are expressed as relative optical density (ROD).

TaqMan and Quantitative Real-Time PCR Analysis

Total RNA was prepared from isolated glomeruli by using ultra-pure TRIzol reagent according to the manufacturer's instructions (GIBCO-BRL, Grand Island, N.Y., USA). KIM-1, nephrin, secreted phosphoprotein-1 (SPP-1), monocyte chemotactic protein-1 (MCP-1), and β -actin gene-specific TaqMan probe and primer sets were obtained from Applied Biosystems (Applied Biosystems Inc., Foster City, Calif., USA) as Assays-on-Demand gene expression products. The Assays-on-Demand identification

numbers were Rn00597703_m1 for KIM-1, Rn00575235_m1 for nephrin, Rn00563571_m1 for SPP-1, Rn00580555_m1 for MCP-1 (CCL2), and 4331182 for rat β -actin endogenous control. Each sample was run in triplicate, and the comparative threshold cycle (C_t) method was used to quantify fold increase ($2^{-\Delta\Delta C_t}$) compared with lean controls.

Cell Culture

Glomeruli were isolated from Sprague-Dawley rat kidneys by a modified procedure as described previously [11]. The glomerular tissue fragments were collected and suspended in DMEM/F12 medium (Invitrogen), supplemented with 5% fetal bovine serum, penicillin and streptomycin. To test the effects of high glucose or albumin on KIM-1 expression, 80% confluent cells (day 6) were washed with serum-free DMEM and incubated in DMEM/F12 with high glucose or bovine serum albumin (BSA, Sigma) at varying concentrations (0, 1, 5, 10 or 20 mg/ml) for an additional 72 h. This preparation of BSA has been shown to be essentially fatty acid free and very low endotoxin by the manufacturing company and the range of albumin concentrations is similar to that used in previous studies [12–14]. For immunostaining, the cells were fixed and incubated with primary antibodies of goat anti-KIM-1 and rabbit anti-ZO-1 (Invitrogen).

Statistical Analysis

Data are expressed as mean \pm SEM. Student's t test was used for comparison between the two groups. Comparisons among multiple groups were performed by one-way ANOVA followed by Student's unpaired t test. Statistical significance was set at $p < 0.05$.

Results

Metabolic Values

Blood glucose of the Fa/Fa animals began to increase at week 8, reached a peak at week 12 and remained at this higher level thereafter (fig. 1a). 7-week-old Fa/Fa animals had higher plasma insulin (Fa/Fa $5.56 \pm 0.31 \mu\text{g/l}$ vs. Fa/+ $0.80 \pm 0.16 \mu\text{g/l}$) and developed glucose intolerance (fig. 1c), though their blood glucose was still normal (fig. 1a). From 7 to 19 weeks of age, Fa/Fa rats were heavier than their Fa/+ littermates (fig. 1b). Kidney weight and glomerular size were also markedly increased in the diabetic Fa/Fa rats (fig. 1d, e). Figure 1f demonstrates a progressive loss of renal function in the diabetic animals as evidenced by an increase in urinary protein to creatinine ratio in the Fa/Fa rats between the ages of 7 and 20 weeks.

KIM-1 Protein Expression in the Glomeruli of Fa/Fa Rats

As shown in figure 2a, the percentages of glomeruli with PEC proliferation and hyperplasia were significantly increased in the diabetic rats. For the Fa/Fa group, the percentage of glomeruli with parietal hyperplasia in-

creased from 30% in the 7-week-old rats to 38% in the 12-week-old and 44% in the 20-week-old animals, whereas the percentage in Fa/+ animals did not change significantly with increasing age (fig. 2d). Within each age group, the percentage of glomeruli with parietal hyperplasia was significantly greater in the Fa/Fa rats than that in the Fa/+ group.

In agreement with our previous finding [15], tubular KIM-1 staining was progressively increased in the Fa/Fa animals during the progression of proteinuria. Interestingly, we also observed an increase in KIM-1-positive cells in the glomeruli of diabetic animals (fig. 2). Immunostaining revealed that most of the hyperplastic PECs were KIM-1 positive in Fa/Fa animals, whereas very few hyperplastic PECs expressed KIM-1 protein in Fa/+ lean rats. In addition to its expression in the parietal layer of Bowman's capsule, KIM-1-positive cells were also observed in the glomerular tuft of Fa/Fa animals at the ages of 12 and 20 weeks. As shown in figure 2e, the percentages of glomeruli with KIM-1-positive staining in the Fa/Fa rats increased from 19% at week 7 to 27% at week 12 and 43% at week 20, compared with 6, 6 and 9% in the Fa/+ rats at the age of 7, 12 and 20 weeks, respectively.

Glomerular KIM-1 Induction in Association with a Decrease in Normal Podocyte Markers in the Fa/Fa Animals

To visualize the localization of KIM-1 and podocyte-specific proteins, we carried out multiple labeling for KIM-1, nephrin and Wilms tumor (WT)-1, markers of podocytes in vivo [16]. A few interesting observations were made in the diabetic rats at the age of 7–28 weeks. First, WT-1 and nephrin staining was normal in 7-week-old Fa/Fa rats when KIM-1-positive cells were mainly present in the parietal epithelium of Bowman's capsule. Second, a decrease in nephrin staining was observed in the glomerular tuft area next to hyperplastic KIM-1-positive parietal epithelium in 12-week-old Fa/Fa rats (fig. 3b). The number and the distribution area of podocytes in the glomerular tuft were further decreased in the glomeruli of 20- and 28-week-old Fa/Fa rats (fig. 3c, d). Accompanying the loss of podocytes, there was an increase in cells staining positive for KIM-1 in nephrin-negative tuft area in the damaged glomeruli.

Double staining was also performed for KIM-1 and the PEC protein claudin-1 [5], as well as KIM-1 and the podocyte injury marker desmin [17]. As shown in figure 4a, cells positive for both KIM-1 and claudin-1 were detected along the parietal layer of Bowman's capsule in the Fa/Fa animals. A significant colocalization of KIM-1 and

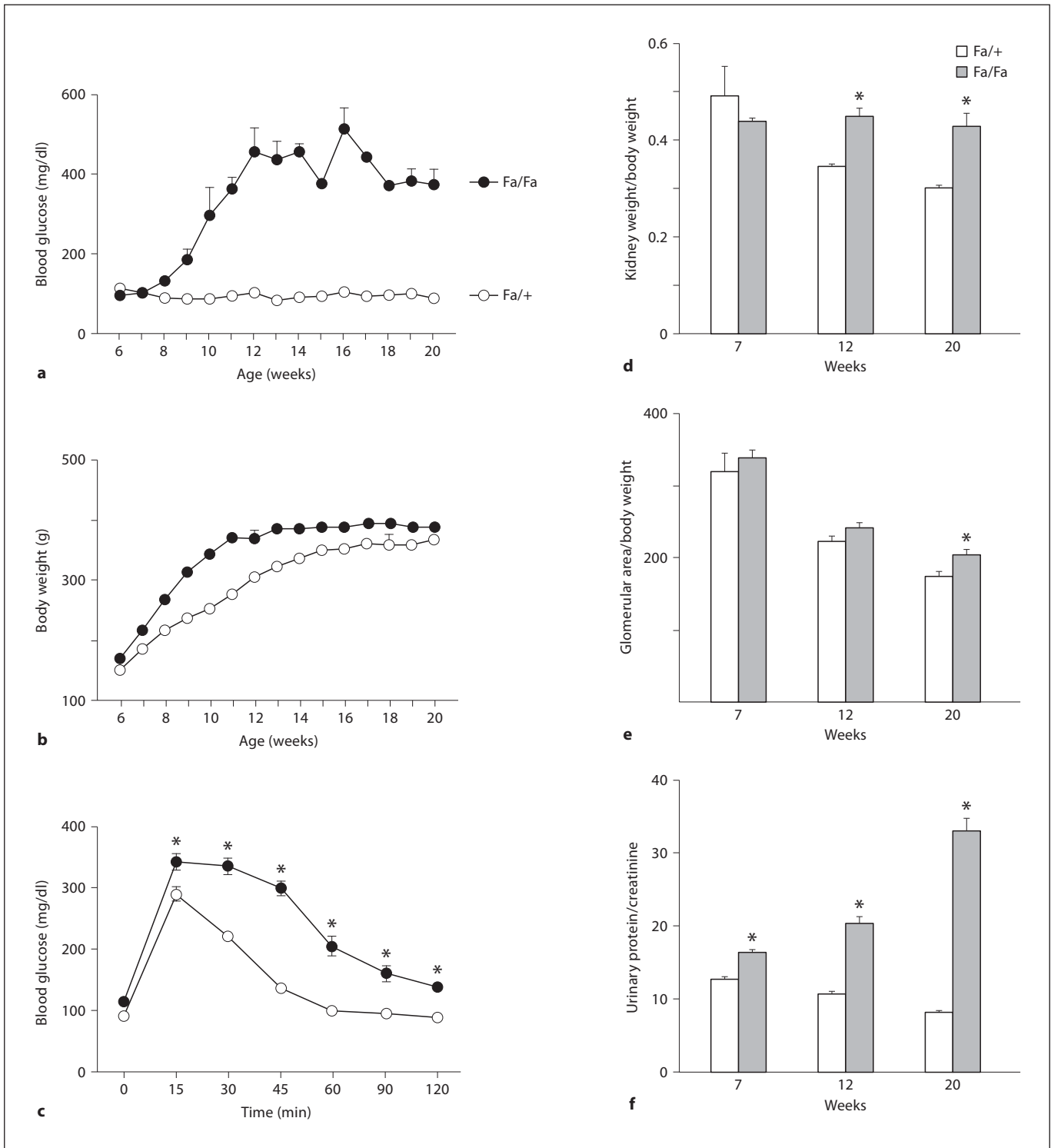
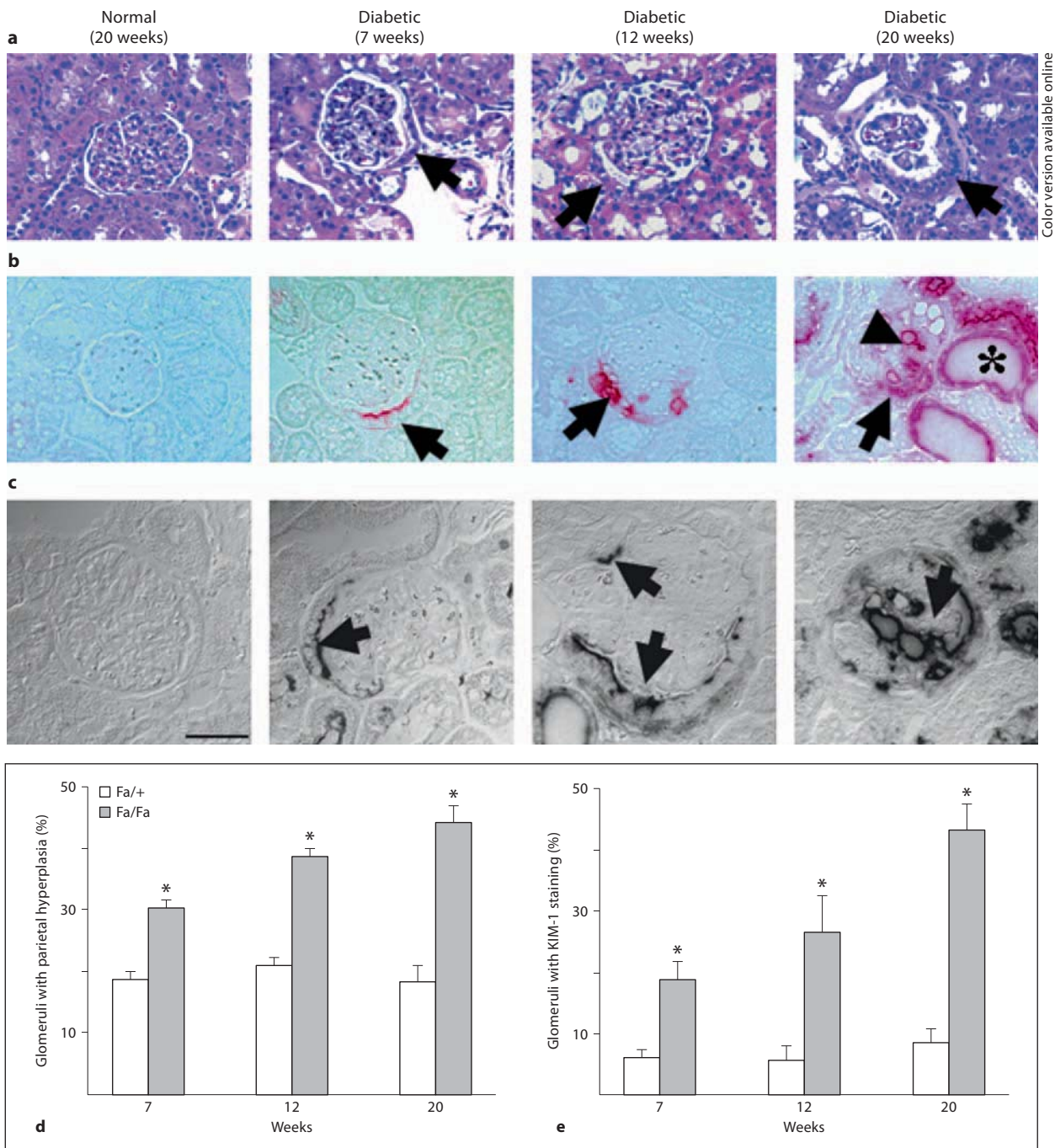


Fig. 1. Metabolic values in the Zucker lean (Fa/+) and Zucker diabetic fatty (Fa/Fa) animals. Nonfasting blood glucose levels (**a**) and body weight (**b**) were measured at weekly intervals. **c** Blood glucose responses to an intraperitoneal glucose challenge were determined in 7-week-old Fa/+ and Fa/Fa rats. **d** and **e** present the ratios of left kidney weight (**d**) and glomerular surface area (**e**) to

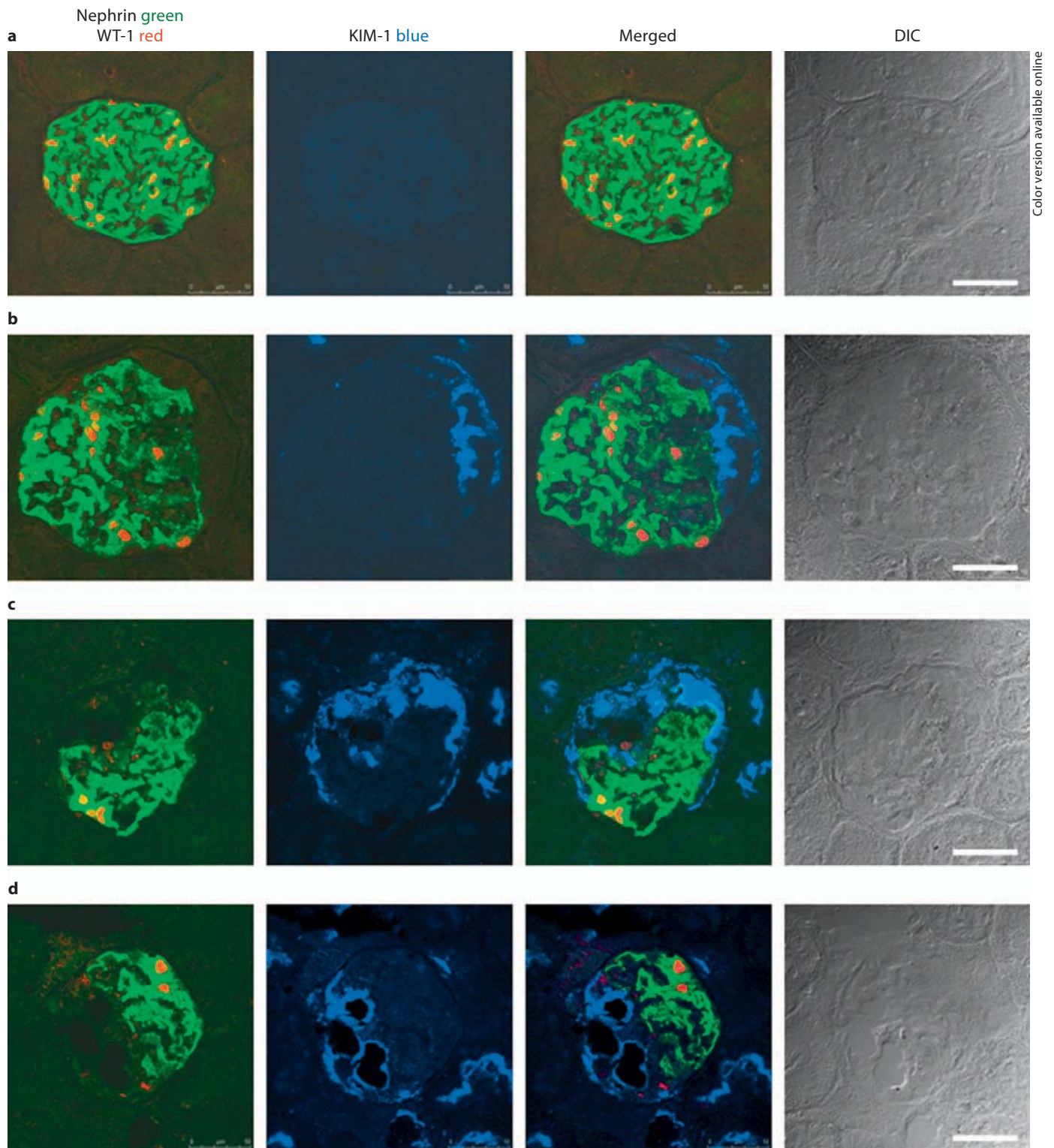
total body weight. **f** The urinary protein to creatinine ratio was obtained by dividing the urinary protein concentration by the urine creatinine concentration, both expressed in mg/dl. Values are mean \pm SEM. $n = 5-10$ animals/group. * $p < 0.05$ vs. Fa/+ littermates.



Color version available online

Fig. 2. Increased parietal epithelial hyperplasia and KIM-1-positive staining in the glomeruli of diabetic animals. **a** Representative HE staining images show increased cuboidal (hyperplastic) PECs (arrow) of Bowman's capsule in Zucker diabetic fatty rats compared to Zucker lean normal controls. Note the presence of a visceral-parietal epithelial bridge in the glomerulus of diabetic rats (12 weeks). **b** KIM-1 red-positive staining in the hyperplastic parietal epithelium (arrow), glomerular tuft (arrow head), and proximal tubular epithelium (*) in the diabetic animals. Original magnification $\times 400$. **c** Confocal DIC images of KIM-1 (arrow) in the glomeruli of Zucker diabetic kidneys. No KIM-1 staining in

the glomerulus of normal Fa/+ rats. In 7-week-old diabetic Fa/Fa rats, KIM-1-specific staining (black) was seen in the apical membrane of hyperplastic PECs. Increased KIM-1 staining was also observed in the glomerular tuft in connection with KIM-1-positive parietal epithelium in the kidney section of 20-week-old Fa/Fa rats. DIC = Differential interference contrast. Scale bar = 50 μ m. **d**, **e** Quantitative analysis of the percentage of glomeruli with parietal hyperplasia (**d**) or KIM-1-positive staining (**e**) in the Zucker lean (Fa/+) and diabetic fatty (Fa/Fa) rats at the ages of 7–20 weeks. Values are mean \pm SEM. $n = 5$ –6 animals/group. * $p < 0.05$ vs. Fa/+ littermates.



Color version available online

Fig. 3. Representative confocal images of triple staining for nephrin (green), WT-1 (red) and KIM-1 (blue) in the glomeruli of Zucker animals. **a** Normal glomerulus presents nephrin- and WT-1-positive but KIM-1-negative staining. **b–d** Decreased

nephrin and WT-1 in association with an increase in KIM-1 blue staining in the glomeruli of Fa/Fa diabetic animals at the age of 12 (**b**), 20 (**c**) and 28 (**d**) weeks. Scale bars = 50 μ m. Colors refer to the online version only.

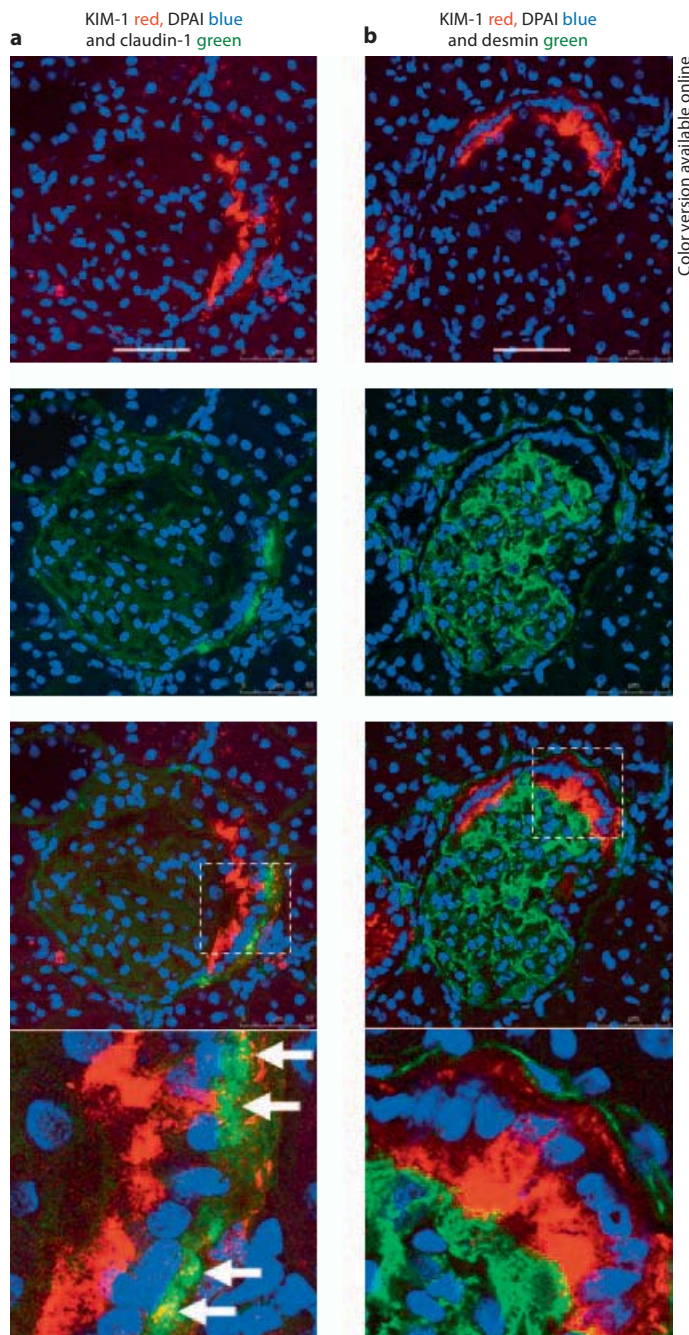


Fig. 4. Representative confocal images of double staining for KIM-1 with claudin-1 (PEC marker) or KIM-1 with desmin (podocyte injury marker) in the glomeruli of 20-week-old Fa/Fa rats. **a** Colocalization of KIM-1 (red) and claudin-1 (green) was seen in the basolateral membrane of PECs (white arrows). **b** There was no significant overlap between KIM-1 (red) and desmin (green) in the parietal epithelium of Bowman's capsule. Scale bars = 50 μ m. Colors refer to the online version only.

claudin-1 was observed in the basolateral compartment of hyperplastic PECs. In contrast, there was no significant overlap between KIM-1 and desmin in the parietal epithelium of Bowman's capsule (fig. 4b).

Glomerular KIM-1, Nephryn, SPP-1 and MCP-1 mRNA Expression

A 2-fold increase in glomerular KIM-1 and a 3-fold decrease in nephryn mRNA were found in 7-week-old Fa/Fa rats prior to the development of hyperglycemia. Greater changes in KIM-1 and nephryn genes were observed in the diabetic animals with severe proteinuria (20 weeks, fig. 5a, b). As expected, mRNA expression of glomerular SPP-1 and MCP-1, the pro-inflammatory cytokines, was also significantly increased after the development of hyperglycemia (fig. 5c, d).

Effects of Losartan Treatment

Losartan reduced systolic blood pressure (losartan-treated Fa/Fa 110 ± 3 mm Hg vs. untreated Fa/Fa 137 ± 3 mm Hg, $n = 4-7$) but did not affect blood glucose (losartan-treated Fa/Fa 462 ± 30 mg/dl vs. untreated Fa/Fa 433 ± 24 mg/dl) in the diabetic animals. There was a great attenuation in glomerular KIM-1 mRNA in proportion to a reduction of proteinuria in losartan-treated Fa/Fa rats (fig. 6a, b). Accordingly, the percentages of glomeruli with parietal hyperplasia or KIM-1-positive staining were markedly decreased in treated-Fa/Fa rats (fig. 6c, d). Western blot revealed that urinary KIM-1 was increased in 12- and 20-week-old Fa/Fa rats (fig. 6e), which was prevented by losartan (fig. 6f). As expected, losartan treatment ameliorated podocyte loss (fig. 7A, B) and significantly reduced SPP-1 and MCP-1 mRNA in the glomeruli of diabetic animals (fig. 7C, D).

Effects of Albumin and High Glucose on KIM-1 in Primary Glomerular Epithelial Cells

Our *in vivo* studies demonstrated a strong correlation between the level of glomerular KIM-1 mRNA and the degree of proteinuria ($r = 0.88$). To further evaluate the effect of albumin on KIM-1 expression, we cultured primary epithelial cells from rat glomeruli using established methods [11, 18]. Incubation of primary glomerular epithelial cells with BSA resulted in a significant increase in KIM-1 protein (fig. 8a). In contrast, KIM-1 was only slightly upregulated in high glucose-treated cells (fig. 8b). Using dual labeling, we found that cytosolic expression of KIM-1 was accompanied by disruption of normal characteristic ZO-1 staining at cell-cell contact in glomerular epithelial monolayer (fig. 8c).

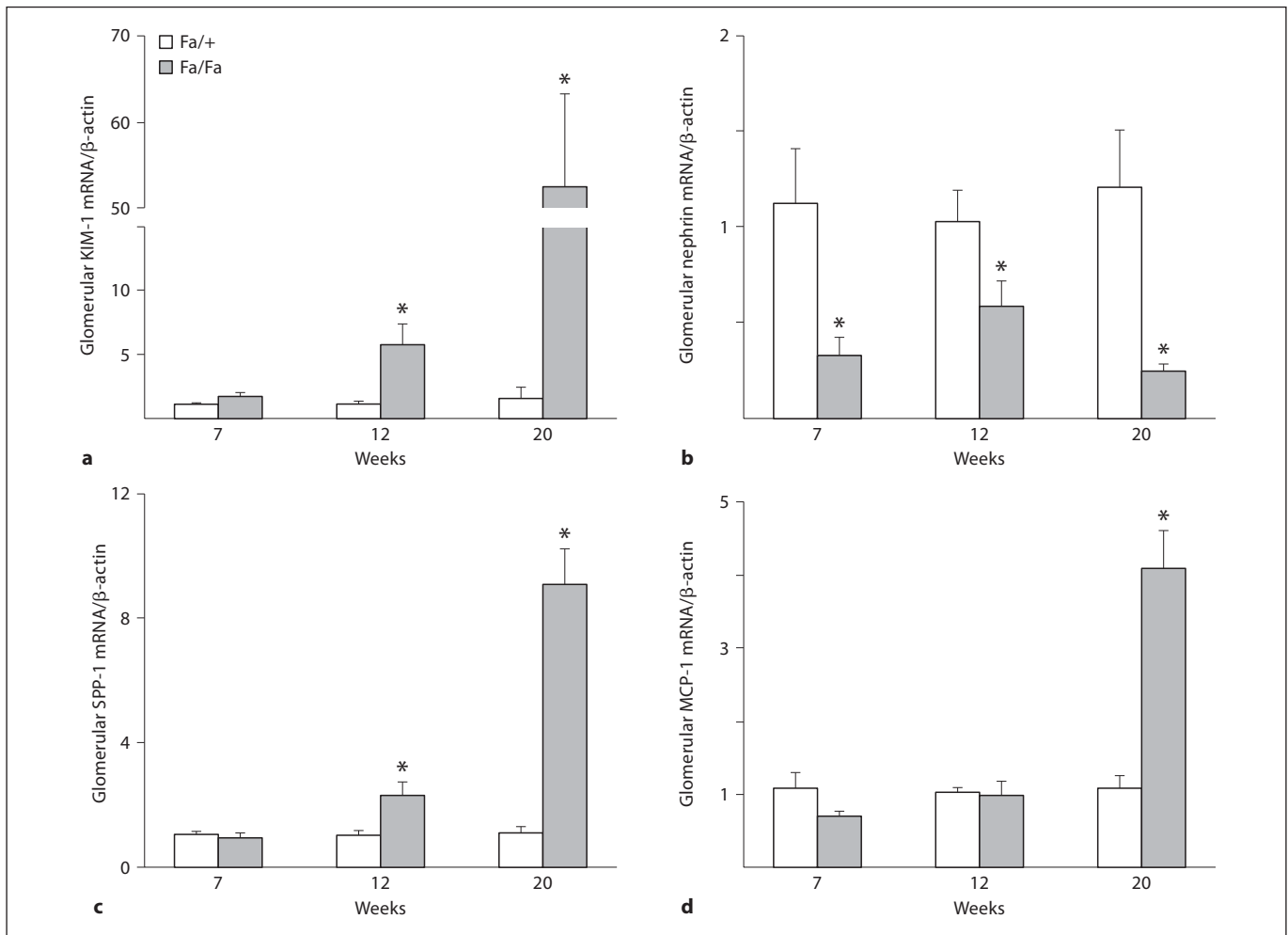


Fig. 5. mRNA levels of glomerular KIM-1, nephrin, SPP-1 and MCP-1. Glomerular KIM-1 (a), nephrin (b), SPP-1 (c) and MCP-1 (d) mRNA levels were evaluated by TaqMan real-time PCR. Values are mean \pm SEM. n = 5–7 animals/group. * p < 0.05 vs. Fa/+ littermates.

Discussion

In this report, we extended our early study on KIM-1 expression in damaged tubules of diabetic animals [19], and revealed that KIM-1 was also expressed in glomerular epithelial cells in diabetic kidney disease. Our results show that glomerular KIM-1-positive cells were initially localized in the hyperplastic parietal epithelium of Bowman's capsule in the early stages of diabetes. There was a significant increase in cells positive for KIM-1 staining in the glomerular tuft with disease progression and massive proteinuria. Multiple labeling for KIM-1 and nephrin indicated a strong correlation between glomerular KIM-1 induction and podocyte loss in damaged glomeruli. Fur-

thermore, antiproteinuric treatment with AT1 receptor antagonist attenuated diabetes-related KIM-1 expression, in association with a reduction of pro-inflammatory markers and an improvement of podocytopenia and renal function in the diabetic animals.

Tubular KIM-1 expression in both acute and chronic kidney diseases has been well established [8–10, 20–24]. Consistent with previous findings, a progressive increase in tubular expression and urinary excretion of KIM-1 was observed in the Fa/Fa diabetic rats. Additionally, the present study demonstrates that glomerular epithelial cells also express KIM-1. Fa/Fa animals had increased PEC proliferation and hyperplasia, morphologically similar to proximal tubular epithelia, from 7 to 20 weeks of age. The

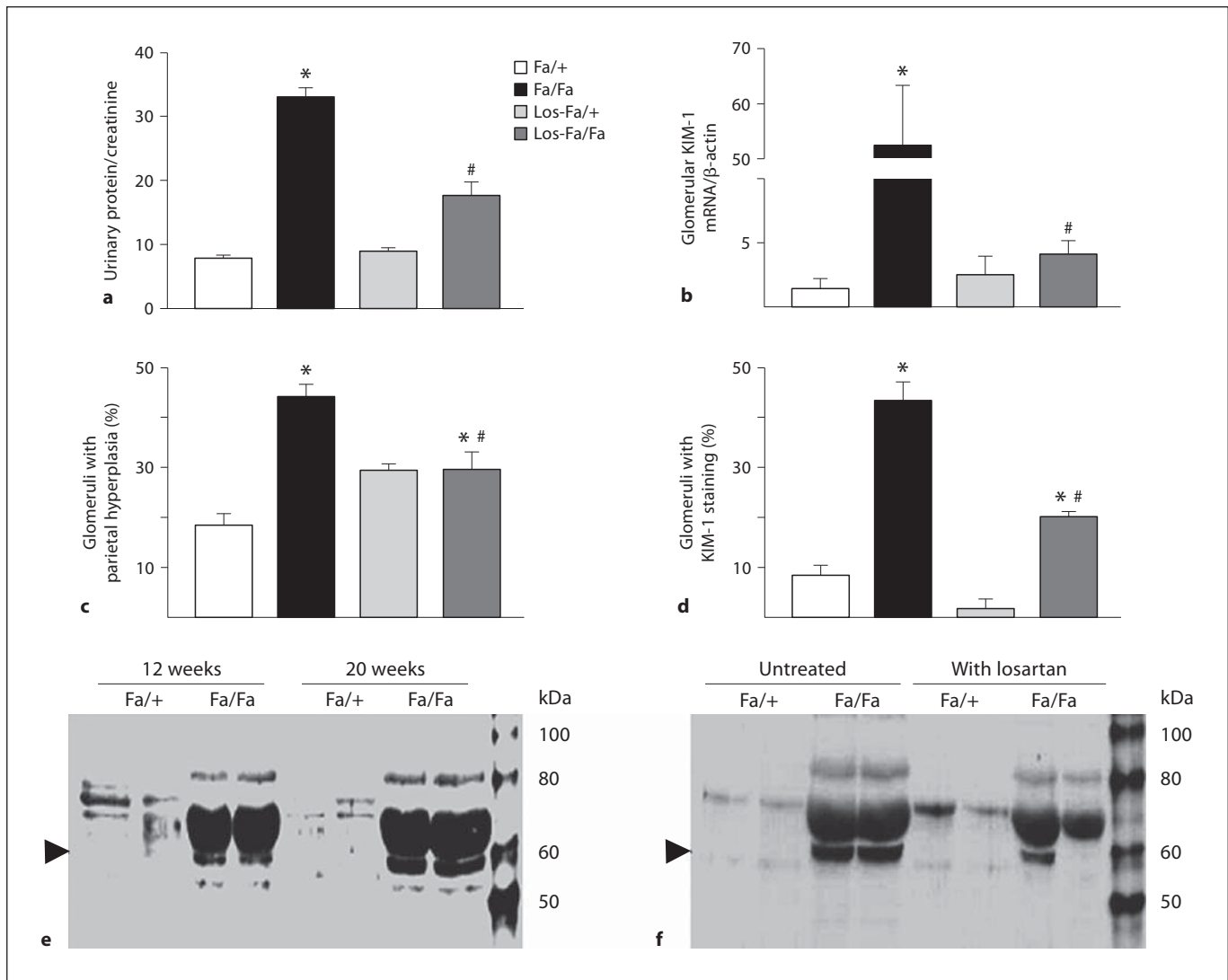


Fig. 6. Effects of losartan treatment on KIM-1 expression and urinary protein excretion. 12-week-old Zucker rats were treated with losartan (Los-Fa/+ and Los-Fa/Fa) for 8 weeks and their urinary protein to creatinine ratio (a), glomerular KIM-1 mRNA (b), percentage of glomeruli with parietal hyperplasia (c), and percentage of glomeruli with KIM-1-positive staining (d) were compared with those in untreated Fa/+ or Fa/Fa groups. e Representative

Western blot image shows a progressive increase in urinary KIM-1 protein (~60 kDa, arrowhead) in 12- to 20-week-old Fa/Fa diabetic rats compared to the Fa/+ normal controls. f Urinary excretion of KIM-1 in the diabetic rats was attenuated markedly by losartan treatment. Values are mean ± SEM. n = 4–7 animals/group. * p < 0.05 vs. normal Fa/+ group; # p < 0.05 vs. untreated Fa/Fa group.

lack of lotus tetragonolobus lectin staining in hyperplastic PECs, however, suggests that they are not proximal tubule cells encroaching into Bowman's capsule in rat kidneys (data not shown). In the absence of microalbuminuria, only few hyperplastic PECs expressed KIM-1 in Fa/+ lean controls. In contrast, the cells double-positive for KIM-1 and claudin-1 were robustly increased in the hyperplastic parietal epithelium of Bowman's capsule in the Fa/Fa

animals. The increase in KIM-1 expression prior to the development of hyperglycemia suggests that KIM-1 is a sensitive marker for early PEC activation. As expected, albuminuria occurs early in 7-week-old Fa/Fa rats. It is conceivable that hyperplastic (or proliferative) PECs are extremely sensitive to an elevation of albumin in the Bowman's space and express KIM-1 upon activation. This concept is supported by our in vivo and in vitro findings

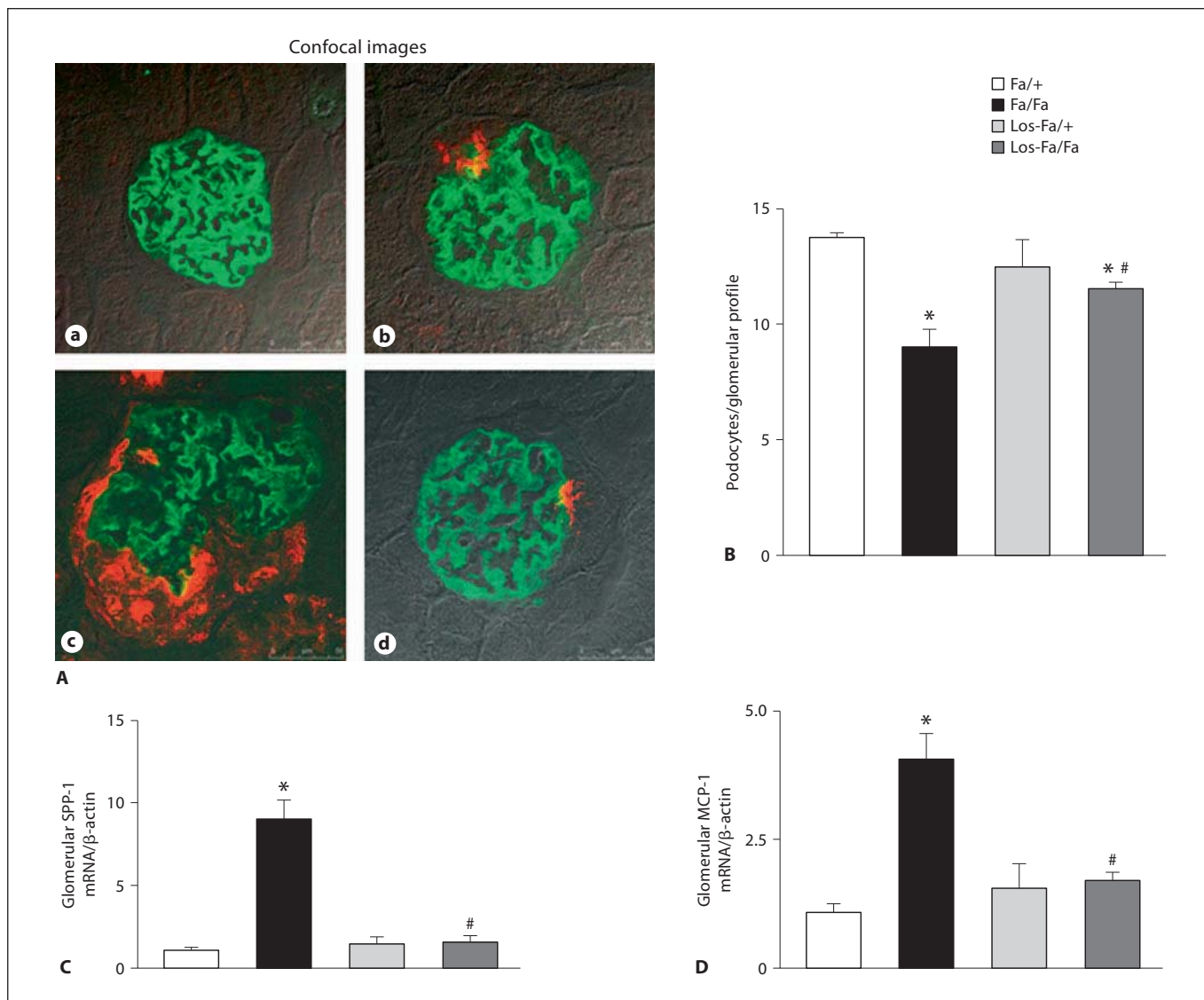


Fig. 7. Effects of losartan on expression of nephrin and inflammatory markers. **A** Representative confocal images of double staining for nephrin (green) and KIM-1 (red) in the glomeruli of 20-week-old Fa/+ normal controls (**a**), 12-week-old Fa/Fa (**b**), untreated 20-week-old Fa/Fa (**c**) and losartan-treated Fa/Fa (**d**) rats. Colors refer to the online version only. **B** Bar graph presents the number of podocytes per glomerular section in 20-week-old un-

treated (Fa/+ and Fa/Fa) and losartan-treated (Los-Fa/+ and Los-Fa/Fa) animals. **C, D** Impact of losartan on mRNA levels of SPP-1 and MCP-1. The diabetes-related increase in renal expression of SPP-1 (**C**) and MCP-1 (**D**) genes was prevented by chronic treatment with losartan. Values are mean \pm SEM. $n = 4-7$ animals/group. * $p < 0.05$ vs. Fa/+ normal control; # $p < 0.05$ vs. untreated Fa/Fa diabetic group.

showing an attenuation of parietal hyperplasia and glomerular KIM-1 expression after antiproteinuric treatment in the diabetic animals and a striking induction of KIM-1 in primary cultured glomerular epithelial cells in response to albumin overload. Although KIM-1 in the primary cultures of rat glomerular epithelial cells was increased slightly after high glucose treatment, the fact that

losartan administration reduced proteinuria but did not change blood glucose suggests that urinary glucose may play a minor role in activation and impairment of renal epithelial cells in this rat model of type 2 diabetes mellitus.

While KIM-1 protein was primarily present along the parietal epithelium of Bowman's capsule in 7-week-old Fa/Fa rats, there was a significant increase in the number of

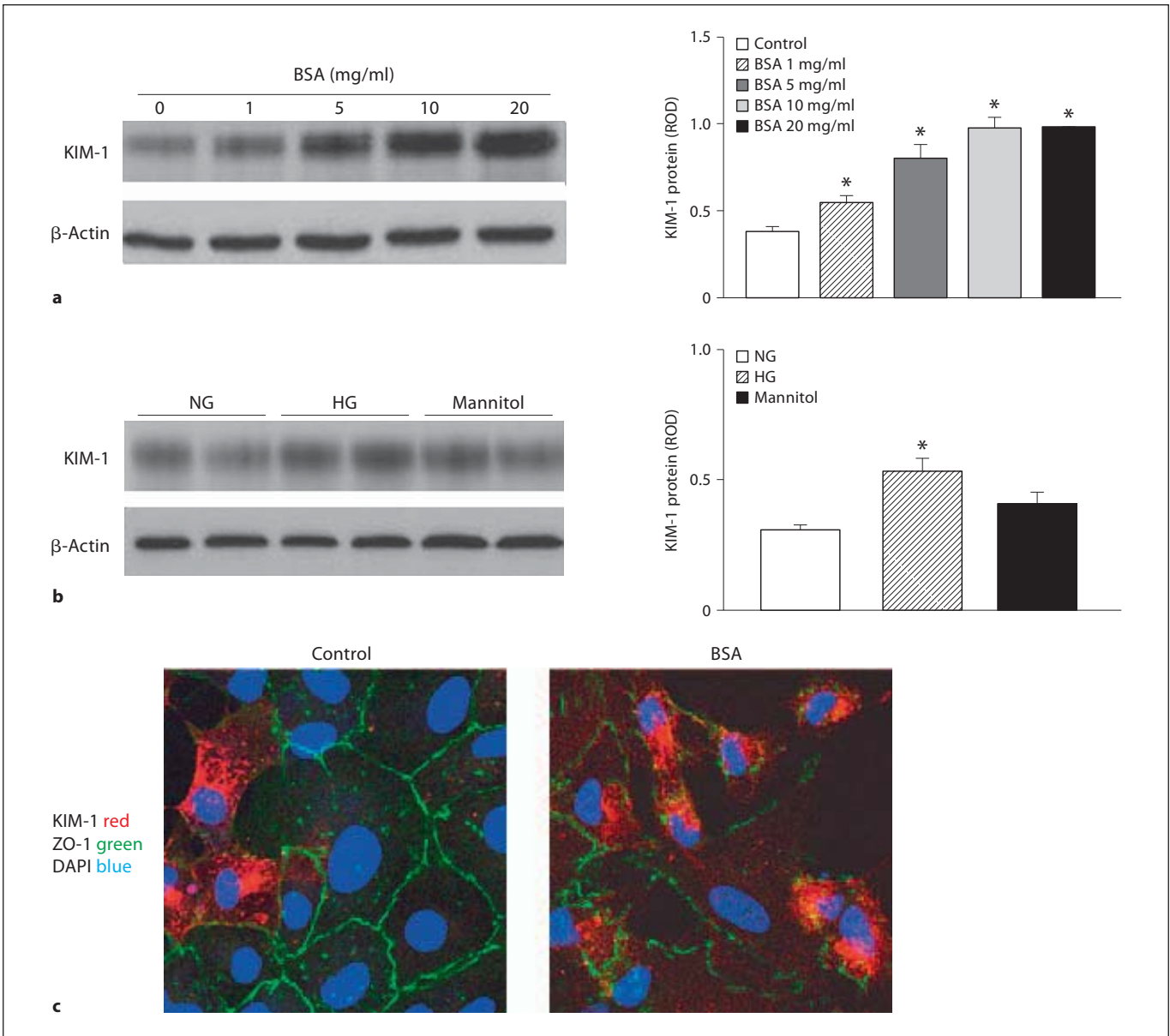


Fig. 8. KIM-1 protein expression in primary cultures of rat glomerular epithelial cells in response to bovine serum albumin (BSA) and high glucose (HG) stimulation. **a** Western blot analysis shows that BSA (1–20 mg/ml) treatment resulted in a dose-dependent increase in KIM-1 protein in glomerular epithelial cells in primary culture. **b** KIM-1 protein was modestly increased following 72-hour incubation with high glucose. 4–6 epithelial

cultures were treated for each condition; * $p < 0.05$ vs. untreated control group. **c** Confocal images show that primary cultured glomerular epithelial cells express KIM-1, which was markedly increased in the presence of 10 mg/ml albumin. Expression of KIM-1 was accompanied by disruption of normal characteristic ZO-1 staining at cell-cell contact of epithelial monolayer. Scale bars = 25 μm . NG = Normal glucose.

cells positive for KIM-1 staining in the glomerular tuft in the diabetic rats at the age of 20–28 weeks. Since podocytopenia has been reported in both diabetic and non-diabetic proteinuric kidney diseases [2, 3, 7, 25, 26], we next asked whether KIM-1 induction was associated with

podocyte loss in the damaged glomeruli. To this end, we performed triple immunostaining for KIM-1, nephrin and WT-1, to evaluate their colocalization in the glomeruli of diabetic animals. Initially, the reduction of nephrin protein was detected in the podocytes next to the hyper-

plastic PECs expressing KIM-1 in 12-week-old diabetic animals. Thereafter, both WT-1 and nephrin were further decreased in the glomerular tuft of diabetic animals. Interestingly, within a single glomerulus, we often observed strong KIM-1 expression in the tuft area with less nephrin and WT-1 staining. Together, our results demonstrate a tight correlation between the expression level of KIM-1 in the glomerular tuft and the extent of loss of podocyte differentiation markers in the damaged glomeruli.

One might ask the cell origin of visceral KIM-1-positive cells. One possibility is that damaged podocytes lose their normal markers and begin to express cell injury markers, such as KIM-1. Another is that KIM-1-expressing PECs move to the glomerular tuft. These two notions are supported by a recent study showing that cells in the glomerular tuft coexpress both podocyte and PEC proteins in several different experimental nephropathy [5]. In this study, cells positive for both KIM-1 and claudin-1 (PEC marker) were present in the parietal epithelium of the Fa/Fa rats. The great majority of KIM-1-positive cells were initially restricted within the parietal epithelium of Bowman's capsule with subsequent increase in the glomerular tuft. Sometimes, a clear connection was seen between visceral and parietal KIM-1-expressing cells. These data suggest that the visceral KIM-1-positive cells are mobile PECs. Indeed, Appel et al. [27] provided evidence that PECs possess the capability to migrate onto the glomerular tuft via the vascular stalk, where they differentiate into podocytes under normal conditions. Additionally, PEC migration and hyperplasia combined with progressive podocytopenia have been shown in cellular/collapsing FSGS [7]. However, not all KIM-1-expressing cells in the glomerular tuft were positive for claudin-1 staining (data not shown). Thus we cannot exclude the possibility that podocytes undergo trans-differentiation and express KIM-1 protein, though no significant overlap between KIM-1 and desmin was detected in the glomeruli of Fa/Fa animals. In fact, previous reports have indicated that dedifferentiated (dysregulated) podocytes characterized by loss of podocyte markers are no longer growth restricted and regain the ability to proliferate in FSGS and HIV-associated nephropathy [28].

Our *in vivo* data indicate a strong positive correlation between glomerular KIM-1 mRNA and the level of urine protein in the diabetic animals. Furthermore, antiproteinuric treatment with AT1 receptor antagonist ameliorated the diabetes-related increase in renal expression and urinary excretion of KIM-1. It is possible that microalbuminuria (or mild proteinuria) could trigger the expression of KIM-1 in activated renal epithelial cells. Therefore, we

further performed an *in vitro* study to examine the action of albumin overload on KIM-1 expression in cultured glomerular epithelial cells. We observed that KIM-1 protein was robustly induced in response to albumin stimulation in primary cultured glomerular epithelial cells. Based on our *in vivo* and *in vitro* observations, we speculate that initial mild microalbuminuria resulting from increased glomerular sieving caused by changes in transglomerular pressure and/or glomerular basement membrane activates glomerular and tubular epithelial cells leading to KIM-1 expression, podocyte loss, overt proteinuria and renal scarring in diabetic metabolic syndrome. This notion is supported by a reduction of blood pressure in association with an improvement of renal structure and function in losartan-treated Fa/Fa diabetic rats. However, our results do not exclude a direct regulatory action of AT1 receptor blockade on renal epithelial cells.

The selective expression by injured epithelial cells provides the foundation for KIM-1's use as a biomarker. More recently, studies by Ichimura et al. [10] have raised the exciting possibility that KIM-1 might be important in renal pathogenesis. They demonstrated that KIM-1 is a phosphatidylserine receptor and plays a predominant role in the uptake of apoptotic cells by renal tubular epithelium [10]. Interestingly, our preliminary experiments show that KIM-1 promotes the uptake of FITC-labeled bovine serum albumin by renal epithelial cells in primary culture (data not shown). Therefore, it is possible that KIM-1 may work as a scavenger of filtered proteins by endocytotic process in proteinuric kidney disease. Further studies are warranted to evaluate the functional consequences of KIM-1 expression in proteinuric nephropathy.

Taken together, the current study demonstrates the expression of KIM-1 in parietal and visceral epithelial cells in the glomeruli of diabetic animals. The increase in KIM-1 was associated with proteinuria and podocytopenia, which was attenuated by AT1 receptor antagonist. Our results support that glomerular KIM-1 expression, especially in the tuft area, could be used to predict glomerular epithelial cell activation and injury in proteinuric kidney disease.

Acknowledgements

The authors would like to thank Dr. Yan Xiao and Andrew Shaw for their technical assistance in immunostaining preparation. This work was supported by the American Heart Association Scientist Development Grant, Satellite Healthcare Norman S. Coplon Extramural Research Grant, NIH/NCRR G12-RR03034 and U54RR026137, and NIH HL59699.

References

- 1 de Zeeuw D, Remuzzi G, Parving HH, et al: Albuminuria, a therapeutic target for cardiovascular protection in type 2 diabetic patients with nephropathy. *Circulation* 2004; 110:921–927.
- 2 Siu B, Saha J, Smoyer WE, et al: Reduction in podocyte density as a pathologic feature in early diabetic nephropathy in rodents: prevention by lipoid acid treatment. *BMC Nephrol* 2006;7:6.
- 3 Stitt-Cavanagh E, MacLeod L, Kennedy C: The podocyte in diabetic kidney disease. *Sci World J* 2009;9:1127–1139.
- 4 Hoshi S, Shu Y, Yoshida F, et al: Podocyte injury promotes progressive nephropathy in Zucker diabetic fatty rats. *Lab Invest* 2002; 82:25–35.
- 5 Ohse T, Vaughan MR, Kopp JB, et al: De novo expression of podocyte proteins in parietal epithelial cells during experimental glomerular disease. *Am J Physiol Renal Physiol* 2010;298:F702–F711.
- 6 Ohse T, Chang AM, Pippin JW, et al: A new function for parietal epithelial cells: a second glomerular barrier. *Am J Physiol Renal Physiol* 2009;297:F1566–F1574.
- 7 Suzuki T, Matsusaka T, Nakayama M, et al: Genetic podocyte lineage reveals progressive podocytopenia with parietal cell hyperplasia in a murine model of cellular/collapsing focal segmental glomerulosclerosis. *Am J Pathol* 2009;174:1675–1682.
- 8 Kramer AB, van Timmeren MM, Schuur TA, et al: Reduction of proteinuria in adriamycin-induced nephropathy is associated with reduction of renal kidney injury molecule (Kim-1) over time. *Am J Physiol Renal Physiol* 2009;296:F1136–F1145.
- 9 Bonventre JV: Kidney injury molecule-1 (KIM-1): a urinary biomarker and much more. *Nephrol Dial Transplant* 2009;24: 3265–3268.
- 10 Ichimura T, Asselton EJ, Humphreys BD, et al: Kidney injury molecule-1 is a phosphatidylserine receptor that confers a phagocytic phenotype on epithelial cells. *J Clin Invest* 2008;118:1657–1668.
- 11 Yaoita E, Kurihara H, Sakai T, et al: Phenotypic modulation of parietal epithelial cells of Bowman's capsule in culture. *Cell Tissue Res* 2001;304:339–349.
- 12 Wang Y, Chen J, Chen L, et al: Induction of monocyte chemoattractant protein-1 in proximal tubule cells by urinary protein. *J Am Soc Nephrol* 1997;8:1537–1545.
- 13 Zoja C, Donadelli R, Colleoni S, et al: Protein overload stimulates RANTES production by proximal tubular cells depending on NF-kappa B activation. *Kidney Int* 1998;53: 1608–1615.
- 14 Erkan E, De Leon M, Devarajan P: Albumin overload induces apoptosis in LLC-PK(1) cells. *Am J Physiol Renal Physiol* 2001; 280:F1107–F1114.
- 15 Zhao X, Li LY: PPAR-alpha agonist fenofibrate induces renal CYP enzymes and reduces blood pressure and glomerular hypertrophy in Zucker diabetic fatty rats. *Am J Nephrol* 2008;28:598–606.
- 16 Sanden SK, Wiggins JE, Goyal M, et al: Evaluation of a thick and thin section method for estimation of podocyte number, glomerular volume, and glomerular volume per podocyte in rat kidney with Wilms' tumor-1 protein used as a podocyte nuclear marker. *J Am Soc Nephrol* 2003;14:2484–2493.
- 17 Canadillas S, Ortega R, Estepa JC, et al: Darbepoetin-alpha treatment enhances glomerular regenerative process in the Thy-1 glomerulonephritis model. *Am J Physiol Renal Physiol* 2010;299:F1278–F1287.
- 18 Ohse T, Pippin JW, Vaughan MR, et al: Establishment of conditionally immortalized mouse glomerular parietal epithelial cells in culture. *J Am Soc Nephrol* 2008;19:1879–1890.
- 19 Li L, Emmett N, Mann D, et al: Fenofibrate attenuates tubulointerstitial fibrosis and inflammation through suppression of nuclear factor-kappaB and transforming growth factor-beta1/Smad3 in diabetic nephropathy. *Exp Biol Med (Maywood)* 2010;235:383–391.
- 20 Chaturvedi S, Farmer T, Kapke GF: Assay validation for KIM-1: human urinary renal dysfunction biomarker. *Int J Biol Sci* 2009;5: 128–134.
- 21 Kramer AB, van der Meulen EF, Hamming I, et al: Effect of combining ACE inhibition with aldosterone blockade on proteinuria and renal damage in experimental nephrosis. *Kidney Int* 2007;71:417–424.
- 22 Kuehn EW, Park KM, Somlo S, et al: Kidney injury molecule-1 expression in murine polycystic kidney disease. *Am J Physiol Renal Physiol* 2002;283:F1326–F1336.
- 23 van Timmeren MM, Bakker SJ, Vaidya VS, et al: Tubular kidney injury molecule-1 in protein-overload nephropathy. *Am J Physiol Renal Physiol* 2006;291:F456–F464.
- 24 de Borst MH, van Timmeren MM, Vaidya VS, et al: Induction of kidney injury molecule-1 in homozygous Ren2 rats is attenuated by blockade of the renin-angiotensin system or p38 MAP kinase. *Am J Physiol Renal Physiol* 2007;292:F313–F320.
- 25 Kelly DJ, Aaltonen P, Cox AJ, et al: Expression of the slit-diaphragm protein, nephrin, in experimental diabetic nephropathy: differing effects of anti-proteinuric therapies. *Nephrol Dial Transplant* 2002;17:1327–1332.
- 26 Langham RG, Kelly DJ, Cox AJ, et al: Proteinuria and the expression of the podocyte slit diaphragm protein, nephrin, in diabetic nephropathy: effects of angiotensin converting enzyme inhibition. *Diabetologia* 2002; 45:1572–1576.
- 27 Appel D, Kershaw DB, Smeets B, et al: Recruitment of podocytes from glomerular parietal epithelial cells. *J Am Soc Nephrol* 2009; 20:333–343.
- 28 Yang Y, Gubler MC, Beaufils H: Dysregulation of podocyte phenotype in idiopathic collapsing glomerulopathy and HIV-associated nephropathy. *Nephron* 2002;91:416–423.