



Acute disseminated encephalomyelitis in children: differential diagnosis from multiple sclerosis on the basis of clinical course

Yun Jin Lee, MD

Department of Pediatrics, Pusan National University Children's Hospital, Pusan National University School of Medicine, Yangsan, Korea

Acute disseminated encephalomyelitis (ADEM) is a demyelinating disease of the central nervous system (CNS) that typically presents as a monophasic disorder associated with multifocal neurologic symptoms and encephalopathy. ADEM is considered an autoimmune disorder that is triggered by an environmental stimulus in genetically susceptible individuals. The diagnosis of ADEM is based on clinical and radiological features. Most children with ADEM initially present with fever, meningeal signs, and acute encephalopathy. The level of consciousness ranges from lethargy to frank coma. Deep and subcortical white-matter lesions and gray-matter lesions such as thalami and basal ganglia on magnetic resonance imaging (MRI) are associated with ADEM. In a child who presents with signs of encephalitis, bacterial and viral meningitis or encephalitis must be ruled out. Sequential MRI is required to confirm the diagnosis of ADEM, as relapses with the appearance of new lesions on MRI may suggest either multiphasic ADEM or multiple sclerosis (MS). Pediatric MS, defined as onset of MS before the age of 16, is being increasingly recognized. MS is characterized by recurrent episodes of demyelination in the CNS separated in space and time. The McDonald criteria for diagnosis of MS include evidence from MRI and allow the clinician to make a diagnosis of clinically definite MS on the basis of the interval preceding the development of new white matter lesions, even in the absence of new clinical findings. The most important alternative diagnosis to MS is ADEM. At the initial presentation, the 2 disorders cannot be distinguished with certainty. Therefore, prolonged follow-up is needed to establish a diagnosis.

Key words: Acute disseminated encephalomyelitis, Multiple sclerosis, Children, Child

Received: 18 April 2011, Accepted: 11 May 2011

Corresponding author: Yun-Jin Lee, MD

Department of Pediatrics, Pusan National University Children's Hospital, Pusan National University School of Medicine, Beomeo-ri, Mulgeum-eup, Yangsan 626-770, Korea
Tel: +82-55-360-2180, Fax: +82-55-360-2181

E-mail: jinnyeye@hanmail.net

Copyright © 2011 by The Korean Pediatric Society

This is an open-access article distributed under the terms of the Creative Commons Attribution Non-Commercial License (<http://creativecommons.org/licenses/by-nc/3.0/>) which permits unrestricted non-commercial use, distribution, and reproduction in any medium, provided the original work is properly cited.

Introduction

Acute disseminated encephalomyelitis (ADEM) is an immune mediated disease of the central nervous system (CNS) that produces multiple inflammatory lesions in the brain and spinal cord, particularly in the white matter. ADEM should be distinguished from other central inflammatory demyelinating disorders of children, including multiple sclerosis (MS) and clinically isolated syndromes that include optic neuritis, transverse myelitis, and neuromyelitis optica (Devic's disease). Most of these disorders are thought to be caused by immune system dysregulation triggered by an infectious or other environmental agent in a genetically susceptible host.

ADEM is often preceded by a viral or bacterial infection, usually in the form of a nonspecific upper respiratory infection. In 3 previous studies, an antecedent infection was identified in 72 to 77 percent of ADEM patients¹⁻³. In general, patients will present within 1 month of this initial illness. Numerous causative pathogens have been identified to date. Viruses that have been implicated include coronavirus, coxsackie virus, cytomegalovirus, Epstein-Barr virus, herpes simplex virus, hepatitis A virus, human immunodeficiency virus, influenza virus, measles virus, rubella virus, varicella zoster virus, and West Nile virus⁴⁻¹¹. Other organisms associated include *Borrelia burgdorferi*, *Chlamydia*, *Leptospira*, *Mycoplasma pneumoniae*, *Rickettsia*, and beta-hemolytic *Streptococcus*^{4,12}.

Less than 5 percent of all ADEM cases follow immunization. Postvaccinal ADEM has been associated with immunization for rabies, hepatitis B, influenza, Japanese B encephalitis, diphtheria/pertussis/tetanus, measles, mumps, rubella, pneumococcus, polio, smallpox, and varicella¹². No infectious agent is isolated in most cases. Currently, measles, mumps, and rubella vaccination are most often associated with postvaccination ADEM. It is important to recognize the significant difference between the incidence of ADEM associated with the live measles vaccination (1 to 2 per million) and the incidence of ADEM previously associated with the measles virus infection (1 in 1,000)¹³.

The pathogenesis of ADEM is incompletely understood. The proposed mechanism of ADEM is that myelin autoantigens, such as myelin basic protein, proteolipid protein, and myelin oligodendrocyte protein, share antigenic determinants with those of an infecting pathogen¹². This model is supported by studies of lymphocytes in children with ADEM. In 1 report, the frequency of T cell reactivity to myelin basic protein was 10 times higher in patients with ADEM than in those with encephalitis or normal controls⁵.

MS is usually thought to be a disease of young adults. However, pediatric MS, defined as onset of MS before the age of 16, is being increasingly recognized. MS presents before the age of 16

in approximately 5 percent of patients^{14,15}. In less than 1 percent of patients, the onset of MS occurs before the age of 10 years¹⁶. In addition, pediatric MS affects girls more than boys, with a female to male ratio of 2.8¹⁷. Since pediatric MS is rare, a child with recurrent episodes of acute neurologic symptoms and white matter lesions on magnetic resonance imaging (MRI) might be originally misdiagnosed with one of several other disorders, including leukodystrophies, vasculopathies, lymphoma, mitochondrial defects, and other metabolic disorders, rather than MS.

Clinical features

Neurologic symptoms of ADEM commonly appear 4 to 13 days after the infection or vaccination¹⁻³. Fever, headache, vomiting, and meningismus are often seen at the time of initial presentation and may persist during hospitalization^{2,18}. Encephalopathy is a characteristic feature and may progress rapidly in association with multifocal neurologic deficits⁴. Progression of initial neurologic signs to maximum deficits usually occurs within 4 to 7 days^{1,3}. The level of consciousness ranges from subtle lethargy to frank coma. The altered mental status often raises concern regarding the risk of seizures, although these occur in only one-third of patients^{3,19}.

In addition to encephalopathy, the most common neurologic features of ADEM include long tract (pyramidal tract) signs, acute hemiparesis, cerebellar ataxia, cranial neuropathies, including optic neuritis, and spinal cord dysfunction (transverse myelitis)^{2-4,18,19}. Symptoms of optic neuritis include vision loss, pain with eye movement, and an afferent pupillary defect. Inflammation of the optic disc may be seen by direct funduscopic examination if there is extensive involvement of the optic nerve. The imaging of the optic nerve with a gadolinium-enhanced MRI of the brain and orbits is a more sensitive means to diagnose optic neuritis in these patients. Symptoms of transverse myelitis include flaccid paralysis of the legs with a change in sensory level on examination. Bowel and bladder involvement secondary to spinal cord disease results in constipation and urinary retention. The arms can be involved if the demyelinating lesion affects the cervical cord. Respiratory failure may appear with high cervical lesions that extend into the brainstem. Aphasia, movement disorders, and sensory deficits are unusual. The severe phase of ADEM generally lasts from 2 to 4 weeks. Children may show deterioration in their condition after hospital admission, and most of them develop new neurologic signs. Patients usually recover completely from the acute illness, although some have neurologic sequelae.

MS is a clinical diagnosis and is characterized by spatially and temporally distinct recurrent episodes of demyelination in the CNS.

Acute inflammation and demyelination in a critical area of the brain, optic nerves, or spinal cord can induce a corresponding neurologic deficit. There are no clinical signs that are unique to this disorder, but some are highly characteristic (Table 1²⁰). Common symptoms of MS are listed in Table 2²⁰. A European observational study of 394 children with pediatric-onset MS and 1,775 patients with adult-onset MS showed that children were more likely than adults to present with isolated optic neuritis, an isolated brainstem syndrome, or symptoms of encephalopathy¹⁷.

Table 1. Clinical Features of Multiple Sclerosis

Features suggestive of multiple sclerosis	
Relapses and remissions	
Onset between ages 15 and 50	
Optic neuritis	
Lhermitte's sign	
Internuclear ophthalmoplegia	
Fatigue	
Uhthoff's phenomenon	
Features not suggestive of multiple sclerosis	
Steady progression	
Onset before age 10 or after age 50	
Cortical deficits such as aphasia, apraxia, alexia, neglect	
Rigidity, sustained dystonia	
Convulsions	
Early dementia	
Deficit developing within minutes	

Table 2. Presenting Symptoms in Multiple Sclerosis

Symptoms	Female	Male	Total
Sensory in limbs	33.2	25.1	30.7
Visual loss	16.3	15.1	15.9
Motor (subacute)	8.3	10.4	8.9
Diplopia	6.0	8.5	6.8
Gait disturbance	3.2	8.3	4.8
Motor (acute)	4.4	4.2	4.3
Balance problems	2.5	4.0	2.9
Sensory in face	2.9	2.5	2.8
Lhermitte's sign (electric shock-like sensations that run down the back and/or limbs upon flexion of the neck)	1.6	2.3	1.8
Vertigo	1.8	1.5	1.7
Bladder problems	0.9	1.1	1.0
Limb ataxia	0.9	1.3	1.0
Acute transverse myelopathy	0.8	0.6	0.7
Pain	0.3	0.8	0.5
Other	2.6	2.5	2.5
Polysymptomatic onset	14.5	11.9	13.7

Values are presented as %.

A clinically isolated syndrome (CIS) is defined as a single mono-symptomatic attack compatible with MS, such as optic neuritis. An episode of CIS can produce diagnostic and therapeutic dilemmas (Fig. 1), since the vast majority of children will not have a recurrence after a single demyelinating event of the CNS. The value of examinations, including brain MRI, cerebrospinal fluid (CSF) analyses, and other laboratory studies to identify those at high risk of recurrence, is unclear²¹.

Diagnosis of ADEM

The diagnosis of ADEM is based on clinical and radiological features⁴. There is no specific biological marker or confirmatory test. ADEM should be suspected in a child who develops multifocal neurologic abnormalities with encephalopathy (e.g., confusion, excessive irritability, or an altered level of consciousness), especially if onset occurs one to two weeks after a viral infection or vaccination.

The MRI abnormalities seen in ADEM are best defined using T2-weighted images and fluid-attenuated inversion recovery (FLAIR) sequences (Fig. 2). Contrast enhancement is sometimes seen in acute lesions. Lesions associated with ADEM are typically bilateral but may be asymmetric and tend to be poorly marginated. Almost all patients have multiple lesions in the deep and subcortical white matter, while the periventricular white matter is generally spared. The thalami and basal ganglia are frequently affected (Fig. 2), and lesions in these locations are often symmetrical^{13,22}. Brainstem and spinal cord abnormalities on MRI are common in ADEM¹². The number of lesions varies, and their diameters range from <5 mm to 5 cm^{1,3}.

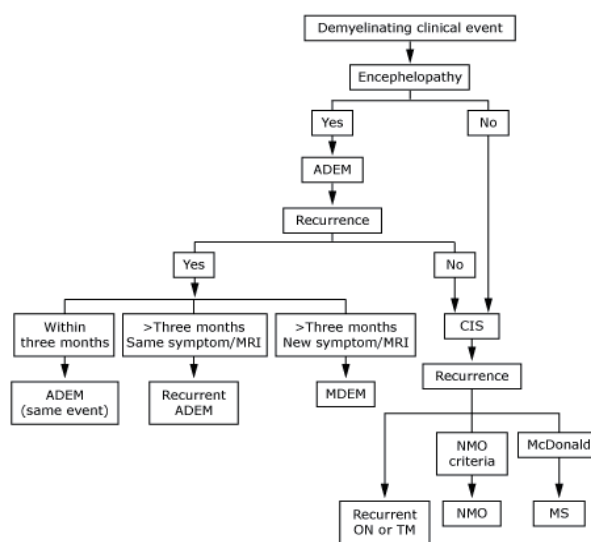


Fig. 1. Diagnosis of a demyelinating clinical event. ADEM, acute disseminated encephalomyelitis; CIS, clinically isolated syndrome; MRI, magnetic resonance imaging; MDEM, multiphase disseminated encephalomyelitis; MS, multiple sclerosis; NMO, neuromyelitis optica; ON, optic neuritis; TM, transverse myelitis.

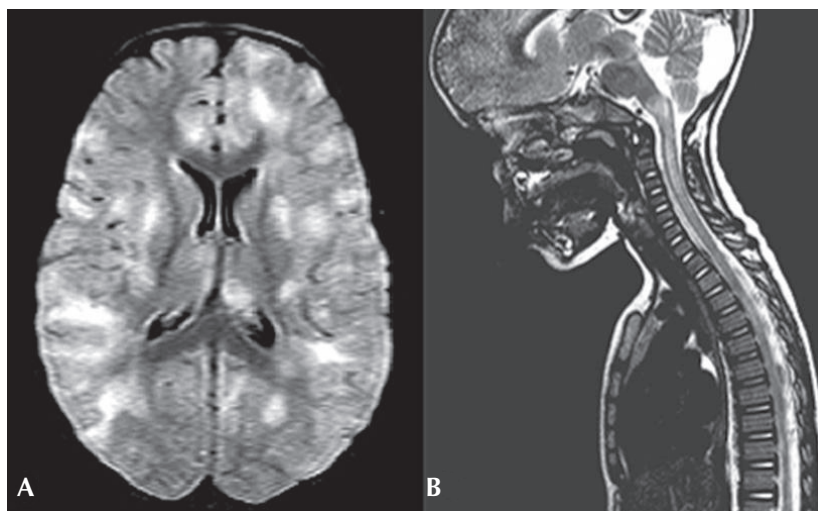


Fig. 2. (A) An axial fluid-attenuated inversion recovery magnetic resonance imaging (MRI) of the brain in a child with acute disseminated encephalomyelitis demonstrates multifocal areas of hyperintensity in both cerebral hemispheres involving cortical gray matter, centrum semiovale, and deep gray nuclei. (B) A saggital T2-weighted MRI of the spine in the same child demonstrates high signal intrinsic to the spinal cord, consistent with longitudinally extensive transverse myelitis.

In the spinal cord, large confluent intramedullary lesions that extend over multiple segments are common^{3,12}, and the degree of contrast enhancement is variable. Abnormal findings on MRI may progress over a relatively short period of time, consistent with progression of the disease. Sequential imaging by MRI is sometimes required to confirm the diagnosis of ADEM, as the occurrence of relapses, with new lesions on MRI, is not compatible with a diagnosis of monophasic ADEM, and suggests that the correct diagnosis is either multiphasic ADEM or MS, based upon the clinical symptoms and neuroimaging findings⁴.

Analysis of CSF reveals pleocytosis and/or increased protein concentration in the majority of patients with ADEM^{1,2}. However, the CSF can also be normal. Oligoclonal bands in CSF are seen in some patients with ADEM, but are a nonspecific finding more often associated with multiple sclerosis. Evaluation for infectious agents includes viral cultures of samples from the throat and nasopharynx, stool, and CSF, and serologic testing for influenza, Epstein-Barr virus, herpes, varicella, mycoplasma, cytomegalovirus, and rubella. These studies are rarely positive¹².

Diagnostic criteria for ADEM in children have been proposed by the International Pediatric Multiple Sclerosis Study Group (Table 3)²³. The major criteria are a clinical attack of CNS demyelinating disease with acute or subacute onset, polysymptomatic neurologic features, and encephalopathy. Encephalopathy as a presenting symptom is essential for a diagnosis of ADEM, according to the Study Group criteria²³. Encephalopathy is defined as including either behavioral changes, such as lethargy or irritability, or more severe alterations in the level of consciousness, such as coma. The onset of

Table 3. Diagnostic Criteria of Acute Disseminated Encephalomyelitis (ADEM)

Clinical features	
First clinical attack of inflammatory or demyelinating disease in the CNS	
Acute or subacute onset	
Affects multifocal areas of the CNS	
Polysymptomatic presentation	
Must include encephalopathy:	
Acute behavioral change such as confusion or irritability and/or	
Alteration in consciousness ranging from somnolence or coma	
Attack should be followed by improvement on clinical and/or neuro-radiologic (MRI) measures	
Sequelae may include residual deficits	
No other etiologies can explain the event	
ADEM relapses (with new or fluctuating symptoms, signs or MRI findings) occurring within three months of the inciting ADEM episode are considered part of the same acute event. In addition, ADEM relapses that occur during a steroid taper or within four weeks of completing a steroid taper are considered part of the initial inciting ADEM episode.	
Lesion Characteristics on MRI FLAIR and T2 weighted images	
Large (>1 to 2 cm in size) multifocal, hyperintense, bilateral, asymmetric lesions in the supratentorial or infratentorial white matter. Rarely, brain MRI shows a single large (≥1 to 2 cm) lesion predominantly affecting white matter.	
Gray matter, especially basal ganglia and thalamus, may be involved	
Spinal cord MRI may show confluent intramedullary lesion(s) with variable enhancement, in addition to the abnormalities on brain MRI	
No radiologic evidence of previous destructive white matter changes	

Encephalopathy is a required feature for the diagnosis of ADEM, but is not a typical feature of multiple sclerosis. In addition, a cerebrospinal fluid pleocytosis ≥ 50 white blood cells/mm can be observed in ADEM, whereas this finding is highly atypical for multiple sclerosis. CNS, central nervous system; MRI, magnetic resonance imaging; FLAIR, fluid-attenuated inversion recovery.

encephalopathy almost directly corresponds to the occurrence of the disease state. This feature helps to differentiate ADEM from other clinically isolated syndromes that are related to recurrence of MS and will lead to a subsequent MS diagnosis. Brain MRI criteria for ADEM diagnosis include focal or multifocal lesions predominantly involving the white matter, without evidence of previous white-matter changes.

The diagnostic criteria can also distinguish between monophasic ADEM with early relapses, and recurrent forms of ADEM²³⁾ on the basis of the following conditions:

- A single clinical episode of ADEM, monophasic ADEM, may evolve over as long as 3 months²³⁾. Any new and fluctuating symptoms occurring within 3 months of the initial event are considered to be part of the same event. In addition, symptoms that appear during tapering of glucocorticoid therapy, or within 1 month of completing a glucocorticoid taper, are considered to be part of the same episode.

- Recurrent ADEM refers to the recurrence, 3 or more months after the first ADEM event, of the same symptoms that occurred at the time of the initial presentation. The MRI findings are similar to those seen at the initial event and are without new lesions, although there may be enlargement of the original lesions.

- Multiphasic ADEM describes recurrent disease that fulfills criteria for ADEM but involves new anatomic areas of the CNS upon recurrence. Symptoms and signs are different from those in the initial event. The MRI must show new lesions not present during the first attack and demonstrate complete or partial resolution of the lesions

associated with the first ADEM episode.

Diagnosis of pediatric MS

Until 2006, the Poser criteria were considered the most useful in making a diagnosis of pediatric MS²⁴⁾. In 2007, the Pediatric Multiple Sclerosis Study Group proposed new working definitions for pediatric MS and related demyelinating diseases such as ADEM²³⁾. The working group suggested use of the 2001 McDonald Criteria to make a diagnosis of pediatric MS²⁵⁾. The McDonald criteria integrate MRI findings and allow the physician to make a diagnosis of clinically definite MS based upon the time interval preceding the development of new white matter lesions, even in the absence of new clinical findings (Tables 4, 5)^{25,26)}. The McDonald criteria for dissemination in space (Table 4) specify a minimal number of lesions, with or without MRI contrast enhancement, being present in specific areas of the CNS including periventricular, juxtacortical, infratentorial, and spinal cord regions.

The McDonald criteria were revised in 2005 for adult-onset MS²⁶⁾, but these revisions have not been applied to pediatric MS. A main difference between the revised McDonald criteria and the 2007 Study Group criteria for pediatric MS concerns the time required between clinical attacks or the development of new MRI lesions to qualify for the "dissemination in time." The revised McDonald criteria require a minimum of only 30 days to elapse prior to the development of a new MRI lesion to qualify as dissemination in time,

Table 4. International Panel on Multiple Sclerosis (MS) Diagnostic Criteria

Clinical presentation	Additional data needed for MS diagnosis
≥2 attacks; objective clinical evidence of ≥2 lesions	None (however, if tests such as MRI or CSF analysis are undertaken and are negative, extreme caution should be taken before making the diagnosis). Alternative diagnoses must be considered and there must be no better explanation for the clinical procedure.
≥2 attacks; objective clinical evidence of 1 lesion	Dissemination in space, demonstrated by: MRI* or ≥ 2 MRI-detected lesions consistent with MS plus positive CSF (determined by oligoclonal bands that are different from any such bands in the serum, or by a raised immunoglobulin G index) or await further clinical attack implicating a different site
One attack; objective clinical evidence of ≥2 lesions	Dissemination in time, demonstrated by: MRI† or second clinical attack
One attack; objective clinical evidence of one lesion (monosymptomatic presentation; clinically isolated syndrome)	Dissemination in space, demonstrated by: MRI* or ≥2 MRI-detected lesions consistent with MS plus positive CSF as defined above and Dissemination in time, demonstrated by: MRI† or second clinical attack implicating a different site
Insidious neurological progression suggestive of MS	Positive CSF as defined above and Dissemination in space, demonstrated by: ≥9 T2 lesions in the brain or 2 or more lesions in the spinal cord or 4 to 8 brain plus 1 spinal cord lesion or abnormal visual evoked potential (delay with a well preserved wave form, typical of MS) associated with 4 to 8 brain lesions or with fewer than 4 brain lesions plus 1 spinal cord lesion demonstrated by MRI and Dissemination in time, demonstrated by: MRI† or continued progression for 1 year

MRI, magnetic resonance imaging; CSF, cerebrospinal fluid; MS, multiple sclerosis.

*MRI criteria include 3 or 4 of the following: 1 gadolinium enhancing lesion or 9 T2 hyperintense lesions if there is no gadolinium enhancing lesion; at least 1 infratentorial lesion; at least 1 juxtacortical lesion; at least 3 periventricular lesions; 1 spinal cord lesion can be substituted for 1 brain lesion. †For MRI dissemination in time criteria, see Table 3.

while the 2007 pediatric MS criteria demand that a minimum of 3 months must pass between clinical events or the appearance of new MRI lesions²³.

A characteristic pattern of MS on MRI would include multiple well-demarcated lesions in the periventricular, juxtacortical, infratentorial, and spinal cord white matter. These areas of demyelination are best recognized using T2-weighted sequences. T2 FLAIR image sequences are the most sensitive in this evaluation,

Table 5. International Panel on Multiple Sclerosis (MS) MRI Criteria for Dissemination in Time

First scan three or more months after onset of clinical event

A gadolinium-enhancing lesion not at the site implicated in the original event demonstrates dissemination in time.

If there is no enhancing lesion at this time, a follow-up scan is required (recommended to be performed 3 months later). A new T2 or gadolinium-enhancing lesion on the follow-up scan demonstrates dissemination in time.

First scan less than three months after onset of clinical event

A second scan should be performed 3 months after the onset of the clinical event. A new gadolinium-enhancing lesion on this scan demonstrates dissemination in time.

If there is no new enhancing lesion on the second scan, another follow-up scan is required (at least 3 months after the first scan). A new T2 or enhancing lesion on this third scan demonstrates dissemination in time.

MRI, magnetic resonance imaging.

especially for periventricular lesions (Fig. 3). T1-weighted sequences may reveal "black holes" that represent complete tissue loss resulting from a previous inflammatory event (Fig. 3). Enhancement of active areas of inflammation and blood-brain barrier compromise can be seen using T1 gadolinium contrast sequences. Retrospective studies suggest that children with MS onset have more T2 bright lesions in the posterior fossa and more gadolinium-enhancing lesions than adults²⁷. Further, the lesions in children were more likely to show reversibility on follow-up MRI than lesions in adults, suggesting better recovery of demyelination in children.

Detection of increased specific immunoglobulins present only in the CSF is often useful for supporting the diagnosis of MS in adult patients. A CSF sample is considered potentially positive for MS based upon the finding of either oligoclonal immunoglobulin G (IgG) bands or an increased IgG index²⁵. In children, the utility of CSF oligoclonal bands in MS diagnosis has been questioned¹. However, positive CSF findings, when associated with new lesions on follow-up MRI, can be used to make the diagnosis of MS even in the case of a single clinical attack²⁵.

Conclusions

In the case of a child who presents with neurologic abnormalities,

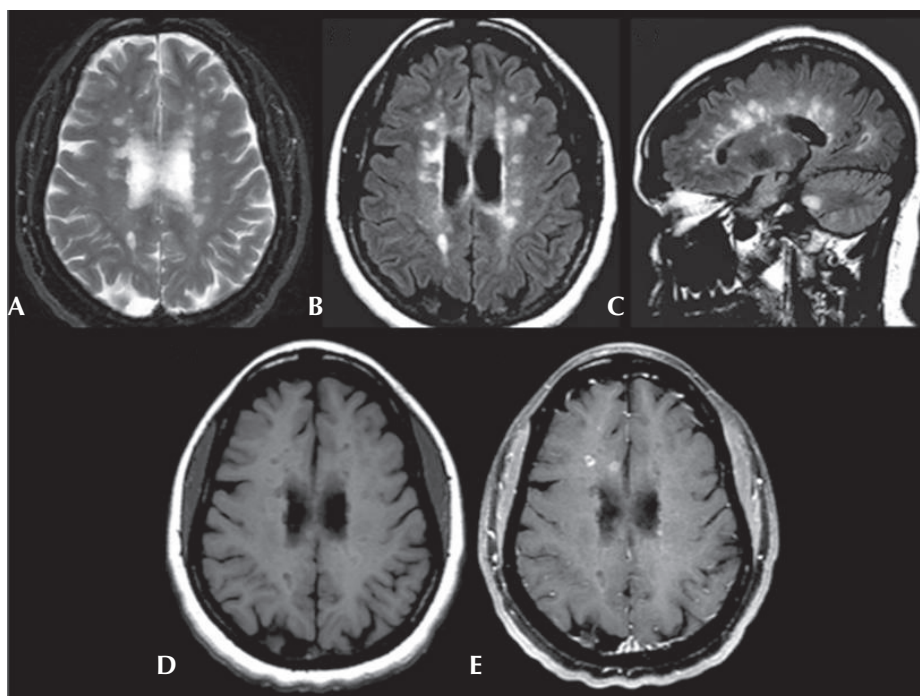


Fig. 3. Axial T2-weighted (A) and axial fluid-attenuated inversion recovery (FLAIR) (B) images show multiple, ovoid shaped, hyperintense foci in the periventricular area, consistent with multiple sclerosis plaques. Sagittal FLAIR (C) image also shows these lesions to be radiating out from the corpus callosum. Axial precontrast T1-weighted (D) image shows that many of these lesions are hypointense, consistent with black holes. Axial postgadolinium fat saturated T1-weighted (E) image shows that some of these plaques enhance in a ring-like fashion consistent with active plaques.

including signs of encephalitis, bacterial and viral meningitis or encephalitis must be considered and ruled out. In the setting of nonspecific CSF abnormalities and identification of white-matter lesions on MRI, other inflammatory demyelinating disorders should be considered. These include ADEM, MS, optic neuritis, transverse myelitis, neuromyelitis optica, and other rare disorders. At initial onset, ADEM and MS cannot be distinguished absolutely. In children, subsequent attacks of MS may not occur for months or years. Furthermore, a small number of children with ADEM may finally develop MS, but it is difficult to accurately predict in which patients this will occur. Therefore, prolonged follow-up is required to establish a diagnosis.

References

- Dale RC, de Sousa C, Chong WK, Cox TC, Harding B, Neville BG. Acute disseminated encephalomyelitis, multiphasic disseminated encephalomyelitis and multiple sclerosis in children. *Brain* 2000;123 Pt 12:2407-22.
- Hynson JL, Kornberg AJ, Coleman LT, Shield L, Harvey AS, Kean MJ. Clinical and neuroradiologic features of acute disseminated encephalomyelitis in children. *Neurology* 2001;56:1308-12.
- Tenembaum S, Chamoles N, Fejerman N. Acute disseminated encephalomyelitis: a long-term follow-up study of 84 pediatric patients. *Neurology* 2002;59:1224-31.
- Tenembaum S, Chitnis T, Ness J, Hahn JS; International Pediatric MS Study Group. Acute disseminated encephalomyelitis. *Neurology* 2007;68(16 Suppl 2):S23-36.
- Pohl-Koppe A, Burchett SK, Thiele EA, Hafler DA. Myelin basic protein reactive Th2 T cells are found in acute disseminated encephalomyelitis. *J Neuroimmunol* 1998;91:19-27.
- Stüve O, Zamvil SS. Pathogenesis, diagnosis, and treatment of acute disseminated encephalomyelitis. *Curr Opin Neurol* 1999;12:395-401.
- Caldemeyer KS, Smith RR, Harris TM, Edwards MK. MRI in acute disseminated encephalomyelitis. *Neuroradiology* 1994;36:216-20.
- Kim SC, Jang HJ, Han DJ. Acute disseminated encephalomyelitis after renal transplantation in patients with positive Epstein-Barr virus antibody. *Transplant Proc* 1998;30:3139.
- Apak RA, Köse G, Anlar B, Turanlı G, Topaloğlu H, Ozdirim E. Acute disseminated encephalomyelitis in childhood: report of 10 cases. *J Child Neurol* 1999;14:198-201.
- Huber S, Kappos L, Fuhr P, Wetzels S, Steck AJ. Combined acute disseminated encephalomyelitis and acute motor axonal neuropathy after vaccination for hepatitis A and infection with *Campylobacter jejuni*. *J Neurol* 1999;246:1204-6.
- Murthy JM. MRI in acute disseminated encephalomyelitis following Semple antirabies vaccine. *Neuroradiology* 1998;40:420-3.
- Stonehouse M, Gupte G, Wassmer E, Whitehouse WP. Acute disseminated encephalomyelitis: recognition in the hands of general paediatricians. *Arch Dis Child* 2003;88:122-4.
- Fenichel GM. Neurological complications of immunization. *Ann Neurol* 1982;12:119-28.
- Boiko A, Vorobeychik G, Paty D, Devonshire V, Sadovnick D; University of British Columbia MS Clinic Neurologists. Early onset multiple sclerosis: a longitudinal study. *Neurology* 2002;59:1006-10.
- Duquette P, Murray TJ, Pleines J, Ebers GC, Sadovnick D, Weldon P, et al. Multiple sclerosis in childhood: clinical profile in 125 patients. *J Pediatr* 1987;111:359-63.
- Gadoth N. Multiple sclerosis in children. *Brain Dev* 2003;25:229-32.
- Renoux C, Vukusic S, Mikaeloff Y, Edan G, Clanet M, Dubois B, et al. Natural history of multiple sclerosis with childhood onset. *N Engl J Med* 2007;356:2603-13.
- Brass SD, Caramanos Z, Santos C, Dilenge ME, Lapierre Y, Rosenblatt B. Multiple sclerosis vs acute disseminated encephalomyelitis in childhood. *Pediatr Neurol* 2003;29:227-31.
- Davis LE, Booss J. Acute disseminated encephalomyelitis in children: a changing picture. *Pediatr Infect Dis J* 2003;22:829-31.
- Paty D, Studney D, Redekop K, Lublin F. MS COSTAR: a computerized patient record adapted for clinical research purposes. *Ann Neurol* 1994;36 Suppl:S134-5.
- Neuteboom RF, Boon M, Catsman Berrevoets CE, Vles JS, Gooskens RH, Stroink H, et al. Prognostic factors after a first attack of inflammatory CNS demyelination in children. *Neurology* 2008;71:967-73.
- Baum PA, Barkovich AJ, Koch TK, Berg BO. Deep gray matter involvement in children with acute disseminated encephalomyelitis. *AJNR Am J Neuroradiol* 1994;15:1275-83.
- Krupp LB, Banwell B, Tenembaum S; International Pediatric MS Study Group. Consensus definitions proposed for pediatric multiple sclerosis and related disorders. *Neurology* 2007;68(16 Suppl 2):S7-12.
- Poser CM, Paty DW, Scheinberg L, McDonald WI, Davis FA, Ebers GC, et al. New diagnostic criteria for multiple sclerosis: guidelines for research protocols. *Ann Neurol* 1983;13:227-31.
- McDonald WI, Compston A, Edan G, Goodkin D, Hartung HP, Lublin FD, et al. Recommended diagnostic criteria for multiple sclerosis: guidelines from the International Panel on the diagnosis of multiple sclerosis. *Ann Neurol* 2001;50:121-7.
- Polman CH, Reingold SC, Edan G, Filippi M, Hartung HP, Kappos L, et al. Diagnostic criteria for multiple sclerosis: 2005 revisions to the "McDonald Criteria". *Ann Neurol* 2005;58:840-6.
- Waubant E, Chabas D, Okuda DT, Glenn O, Mowry E, Henry RG, et al. Difference in disease burden and activity in pediatric patients on brain magnetic resonance imaging at time of multiple sclerosis onset vs adults. *Arch Neurol* 2009;66:967-71.